

En face OCT analysis of Bietti's crystalline dystrophy

Shilo Voichanski^{a,b}, Neda Abraham^a, Ahmad Santina^a, David Sarraf^{a,c,*}

^a Retinal Disorders and Ophthalmic Genetics Division, Stein Eye Institute, University of California Los Angeles, Los Angeles, CA, USA

^b Vitreoretinal Division, Ophthalmology Department, Shaare Zedek Medical Center, Jerusalem, Israel

^c Greater Los Angeles VA Healthcare Center, Los Angeles, CA, USA

ARTICLE INFO

Keywords:

Bietti crystalline dystrophy
en-face OCT

ABSTRACT

Objective: To describe the multimodal imaging features, including en face optical coherence tomography (OCT), of Bietti's crystalline dystrophy (BCD).

Methods: Wide field fundus photography, autofluorescence (FAF) imaging, and cross sectional and en face OCT were performed in a case of BCD. The level of the crystals in the retina were analyzed.

Results: A 42-year-old patient was referred for retinal evaluation with nyctalopia, photophobia and metamorphopsia. Retinal examination and wide field color fundus photography were remarkable for bilateral crystalline deposits in the posterior pole and midperipheral retina. Wide field FAF showed extensive nummular atrophy of the retinal pigment epithelium (RPE) in the macula and periphery. Spectral-domain (SD) OCT illustrated bilateral chorioretinal atrophy in the macula. En face SD OCT captured the hyperreflective crystals in various retinal layers, depending on the selected segmentation. The patient was diagnosed with BCD and genetic testing confirmed the diagnosis (CYP4V positive for two variants).

Conclusion: In this case report, we describe the multimodal imaging features of Bietti's Crystalline Dystrophy. Wide field FAF illustrated diffuse nummular RPE atrophy in the posterior pole and periphery and en face OCT captured the hyperreflective crystals in different layers of the retina.

1. Introduction

Bietti's crystalline dystrophy (BCD) was first described by Bietti in 1937 as a tapetoretinal degeneration characterized by yellow-white intraretinal crystals in the posterior pole and midperiphery associated with atrophy of the retinal pigment epithelium (RPE) and choroidal sclerosis¹. While it is a rare autosomal recessive ocular disease, BCD is relatively more common in East Asia.²

The onset of BCD is typically during the third decade.³ Patients usually present with nyctalopia, decreased visual acuity, and constriction of visual fields.⁴ The disease is slowly progressive, leading to severe visual impairment later in life, usually in the fifth or sixth decades.⁵

Yellow-white intraretinal crystals of the posterior pole and periphery, associated with RPE atrophy, are notable with retinal examination. Outer corneal crystals at the limbus can be detected in 50 % of cases⁶. Histopathological studies show significant damage to the RPE and choriocapillaris associated with choroidal atrophy and focal hypertrophy and hyperplasia of the RPE with migration of RPE cells into the retina⁶. The gene responsible for BCD is cytochrome P450 4V2

(CYP4V2) which encodes a protein involved in fatty acid metabolism.⁷

In this report, we present the multimodal imaging features of BCD and highlight the role of en face OCT which can illustrate the macular crystals at different levels of the retina.

2. Case report

A 42-year-old Asian male patient presented to our retina clinic complaining of nyctalopia and metamorphopsia in both eyes for many years, with more recent impairment of adaptation to bright light conditions. He was diagnosed with macular degeneration 20 years prior, but past medical history was otherwise unremarkable and he denied any history of pentosan polysulfate or hydroxychloroquine exposure. Family history was only remarkable for a father with macular degeneration.

Best-corrected visual acuity was 20/20 in the right eye and 20/40 in the left eye. The anterior segment was normal in both eyes with no crystals detected at the corneal limbus. Fundus examination of each eye revealed multiple punctate drusen-like deposits in the posterior pole and midperipheral retina that exhibited a subtle refractile quality.

* Corresponding author. Retinal Disorders and Ophthalmic Genetics Division, Stein Eye Institute, University of California Los Angeles, 100 Stein Plaza, Los Angeles, CA, 90095, USA.

E-mail address: dsarraf@ucla.edu (D. Sarraf).

<https://doi.org/10.1016/j.ajoc.2023.101963>

Received 27 June 2023; Received in revised form 7 November 2023; Accepted 19 November 2023

Available online 25 November 2023

2451-9936/© 2023 Published by Elsevier Inc. This is an open access article under the CC BY-NC-ND license (<http://creativecommons.org/licenses/by-nc-nd/4.0/>).

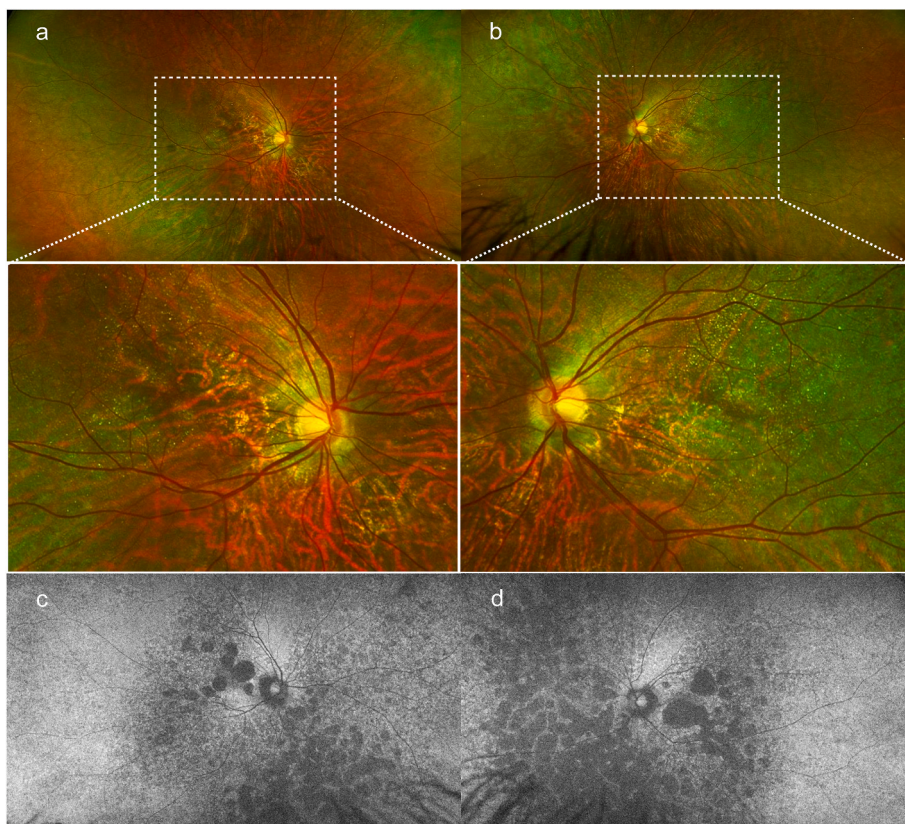


Fig. 1. Wide-field color fundus images of the right and left eyes (a and b) in a patient with Bietti's crystalline dystrophy (BCD) show extensive areas of retinal pigment epithelial (RPE) atrophy in the posterior pole that are associated with punctate drusen-like deposits that have a subtle refractile quality. Wide-field fundus autofluorescent images of the right and the left eyes (c and d) in the same patient with BCD show widespread patchy areas of hypoautofluorescent RPE atrophy extending from the posterior pole to the periphery of each eye. (For interpretation of the references to color in this figure legend, the reader is referred to the Web version of this article.)

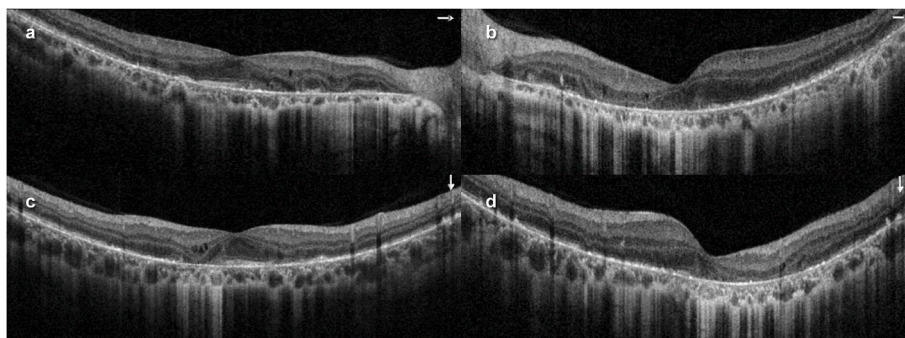


Fig. 2. Cross sectional spectral-domain optical coherence tomography (SD OCT) horizontal (a) and vertical (c) B-scans of the right eye, and horizontal (b) and vertical (d) B-scans of the left eye show patchy areas of complete retinal and outer retinal atrophy (CRORA) associated with overlying retinal degenerative cysts in the middle retinal layer (i.e. the inner nuclear layer) and diffuse choroidal thinning. Note the hyperreflective dots (i.e. crystals) in the middle and outer retinal layers and RPE.

Prominent choroidal vessels were noted within the areas of RPE atrophy (Fig. 1).

Wide field FAF confirmed the presence of extensive nummular hypoautofluorescent RPE atrophy in the posterior pole and extending to the midperiphery of each eye. SD OCT analysis showed outer retinal and RPE disruption and patchy areas of complete RPE and outer retinal atrophy (CRORA) associated with diffuse choroidal thinning. Hyperreflective dots were noted in various retinal layers but were predominantly located in the outer retina and RPE (Fig. 2). En face SD OCT co-localized the hyperreflective crystals at various levels of the retina, depending on the selected segmentation (Fig. 3). Of note, several

hyperreflective deposits that were detected with cross sectional and en face OCT were not identified with retinal examination or color fundus photography (Fig. 3).

Full Field Electroretinogram (ERG) demonstrated 50 % reduction in rod and cone amplitudes in both eyes consistent with Bietti crystalline dystrophy.

Genetic testing was done by next-generation sequencing (NGS) by Invitae, which is a CLIA (Clinical Laboratory Improvement Amendments) certified laboratory, using the Invitae Inherited Retinal Disorders Panel. Testing was positive for one pathogenic variant (c.802-8_810delinsGC) and one variant of uncertain significance (VUS)

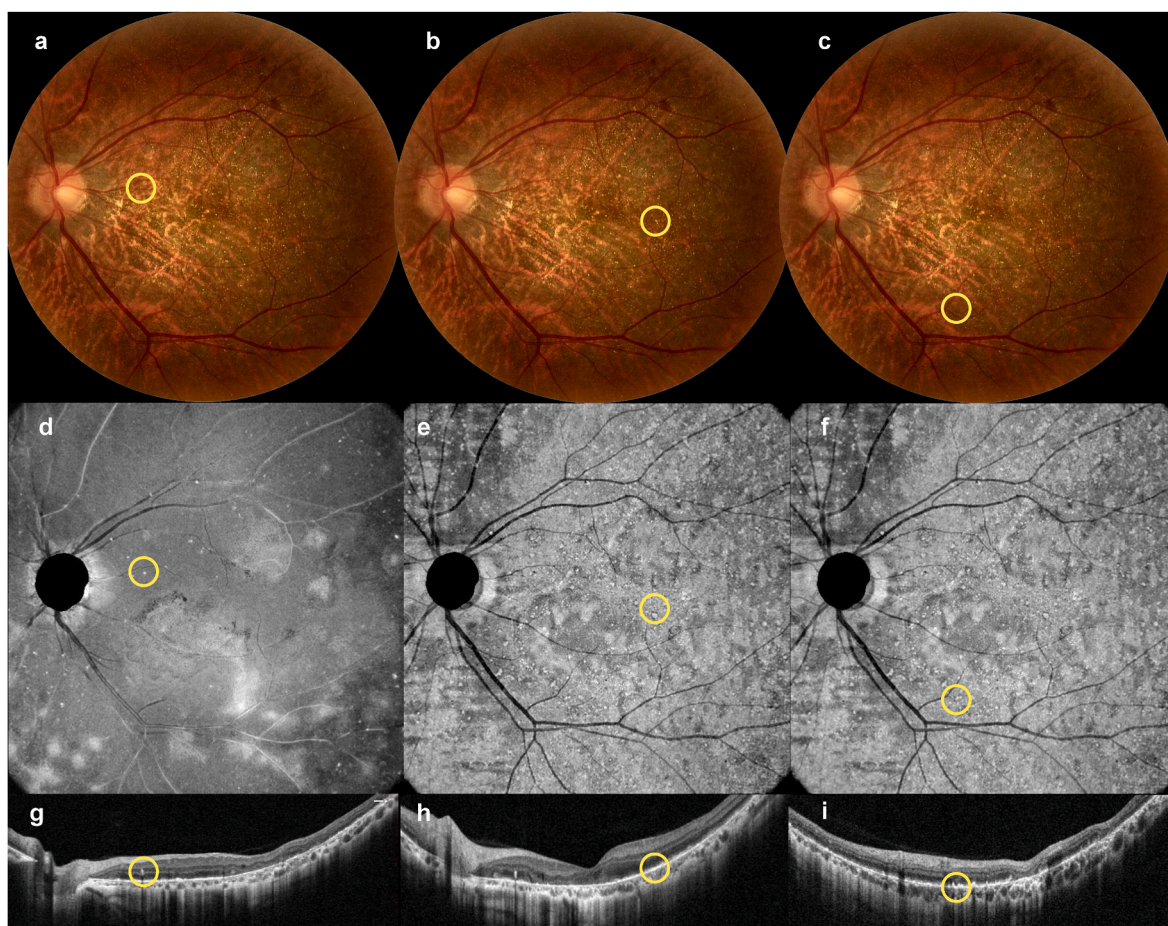


Fig. 3. Pseudo color fundus images with corresponding en face and cross-sectional optical coherence tomography co-localizes the refractile crystalline deposits to the various retinal layers as shown with the yellow circles. Deep capillary plexus segmentation (d) captures the hyperreflective intraretinal deposits in the middle retinal layer (g) and outer retinal segmentation (e, f) captures the crystalline deposits adjacent to the RPE layer (h,i). Some deposits were detected only with en face OCT (f) and were not identified in the pseudo color fundus image (c). (For interpretation of the references to color in this figure legend, the reader is referred to the Web version of this article.)

(c.1507G > C,p.Gly503Arg) in the *cytochrome P4V2 (CYP4V2) gene* consistent with autosomal recessive *Bietti's crystalline dystrophy*. Variants were validated by Sanger sequencing.

3. Discussion

Crystalline retinopathy can be associated with a wide variety of disorders including genetic, toxic, degenerative, iatrogenic, or idiopathic etiologies.^{8,9} Crystals may be located in the preretinal, intraretinal, or subretinal layers or in the choroid depending on the condition and may be scattered in the macula and posterior pole or throughout the retinal periphery.¹⁰ Our patient was diagnosed with BCD, based on the multimodal retinal features and genetic testing. Other diseases that should be considered in the differential diagnosis are cystinosis, hyperoxalosis, and drug-associated crystalline dystrophies. This patient's past medical and drug history were noncontributory.

Meyer et al. reported the OCT findings of BCD and described hyperreflective crystalline deposits in the retina and RPE associated with thickening of the RPE-choriocapillaris complex.¹¹ Querques et al. captured the hyperreflective deposits in all layers of the retina with cross sectional OCT.¹² Halford et al. found that the majority of crystals are located in the RPE/Bruch membrane complex with OCT, with a small number of crystals identified elsewhere in the retina, but not in the choroid.¹³

Near-infrared reflectance imaging may provide an effective illustration of the crystals.¹⁴ Kumar et al. presented a case with multimodal

imaging in which the crystals were best captured with red-free and en face OCT at the level of RPE.¹⁵ En face OCT is a specialized technique that requires dense volumetric scanning and can provide depth resolved colocalization of retinal abnormalities.¹⁶ We applied en face OCT in this case to identify the hyperreflective crystalline deposits at various levels of the retina with different segmentation slabs. This modality captured the crystals more readily than retinal examination and color fundus photography. In conjunction with cross sectional OCT, en face OCT allows the reviewer to screen the entire volumetric scan for easier detection of the macular findings.

In summary, we present the multimodal imaging features of BCD the diagnosis of which was confirmed with genetic testing (positive for two variants of the *CYP4V* gene). While multiple subtle refractile drusen like deposits could be detected with retinal examination and color fundus photography, cross sectional and en face OCT considerably facilitated diagnosis with the capture of the characteristic hyperreflective crystals at different levels of the retina.

Funding

Research To Prevent Blindness (RPB) Inc (DS), New York NY.

Authorship

All authors attest that they meet the current ICMJE criteria for Authorship.

Declaration of competing interest

The authors declare that they have no competing interests.

Acknowledgements

None.

References

- Harrison RJ, Acheson RR, Dean-Hart JC. Bietti's tapetoretinal degeneration with marginal corneal dystrophy (crystalline retinopathy): case report. *Br J Ophthalmol*. 1987;71:220–223.
- Ng DSC, Lai TYY, Ng TK, Pang CP. Genetics of bietti crystalline dystrophy. *Asia-pac J Ophthalmol*. 2016;5(4):245e52.
- Ng DSC, Lai TYY, Ng TK, Pang CP. Genetics of bietti crystalline dystrophy. *Asia-pac J Ophthalmol*. 2016;5(4):245e52.
- Atmaca LS, Muftuoglu O, Atmaca-Sonmez P. Peripapillary choroidal neovascularization in Bietti crystalline retinopathy. *Eye*. 2007;21(6):839.
- Okialda KA, Stover NB, Weleber RG, Kelly EJ. Bietti crystalline dystrophy [cited 2015 Oct 13]; Available from: <http://www.ncbi.nlm.nih.gov/books/NBK91457/>; 2012.
- Richards BW, Brodstein DE, Nussbaum JJ, Ferencz JR, Maeda K, Weiss L. Autosomal dominant crystalline dystrophy. *Ophthalmology*. 1991;98:658–665.
- Li A, Jiao X, Munier FL, et al. Bietti crystalline corneoretinal dystrophy is caused by mutations in the novel gene CYP4V2. *Am J Hum Genet*. 2004;74:817–826.
- Kovach JL, Isildak H, Sarraf D. Crystalline retinopathy: unifying pathogenic pathways of disease. *Surv Ophthalmol*. 2019 Jan-Feb;64(1):1–29. <https://doi.org/10.1016/j.survophthal.2018.08.001>.
- Drenser K, Sarraf D, Jain A, Small KW. Crystalline retinopathies. *Surv Ophthalmol*. 2006 Nov-Dec;51(6):535–549. <https://doi.org/10.1016/j.survophthal.2006.08.006>. PMID: 17134644.
- Doshi RR, Fortun JA, Kim BT, Dubovy SR, Rosenfeld PJ. Pseudocystic foveal cavitation in tamoxifen retinopathy. *Am J Ophthalmol*. 2014;157(6):1291e8. e3.
- Meyer CH, Rodrigues EB, Mennel S, Schmidt JC. Optical coherence tomography in a case of Bietti's crystalline dystrophy. *Acta Ophthalmol Scand*. 2004;82:609–612.
- Querques G, Quijano C, Bouzitou-Mfoumou R, Soubrane G, Souied EH. In-vivo visualization of retinal crystals in Bietti's crystalline dystrophy by spectral domain optical coherence tomography. *Ophthalmic Surg Laser Imag*. 2010:1–3.
- Halford S, Liew G, Mackay DS, et al. Detailed phenotypic and genotypic characterization of bietti crystalline dystrophy. *Ophthalmology*. 2014;121(6):1174e84.
- Fuerst NM, Serrano L, Han G, et al. Detailed functional and structural phenotype of Bietti crystalline dystrophy associated with mutations in CYP4V2 complicated by choroidal neovascularization. *Ophthalmic Genet*. 2016;37(4):445e52.
- Kumar V, Gadkar A. Multimodal imaging of Bietti's crystalline dystrophy. *Indian J Ophthalmol*. 2018 Jul;66(7):1024–1026. https://doi.org/10.4103/ijo.IJO_39_18. PMID: 29941763; PMCID: PMC6032734.
- Ghasemi Falavarjani K, Phasukkijwatana N, Freund KB, et al. En face optical coherence tomography analysis to assess the spectrum of perivenular ischemia and paracentral acute middle maculopathy in retinal vein occlusion. *Am J Ophthalmol*. 2017 May;177:131–138. <https://doi.org/10.1016/j.ajo.2017.02.015>. Epub 2017 Feb 22. PMID: 28237415.