



# Delayed-onset pressure-induced interlamellar stromal keratitis (PISK) and interface epithelial ingrowth 10 years after laser-assisted in situ keratomileusis

Guillermo Raul Vera-Duarte, Jesus Guerrero-Becerril, Carlos Adolfo Müller-Morales, Arturo Ramirez-Miranda, Alejandro Navas, Enrique O. Graue-Hernandez\*

Instituto de Oftalmología Fundación Conde de Valenciana FAP, Department of Cornea, external disease and Refractive Surgery, Chimalpopoca 14, Colonia Obrera, Cuauhtémoc, 06800, Mexico City, Mexico

## ARTICLE INFO

### Keywords:

Pressure-induced interlamellar stromal keratitis  
Interface fluid syndrome steroid-induced ocular hypertension  
Diffuse lamellar keratitis  
Laser-assisted in situ keratomileusis

## ABSTRACT

**Purpose:** To report a case of pressure-induced interlamellar stromal keratitis (PISK) 10 years after laser assisted in situ keratomileusis (LASIK).

**Observations:** A case of a 36-year-old man who underwent LASIK and presented with PISK 10 years later. Before presenting to our department he consulted elsewhere for red eye, decreased visual acuity, foreign body sensation, and pain on the RE for 1 week. He was then prescribed topical prednisolone six times per day and was lost to follow-up. On examination and after 1 month of continuous use of steroids uncorrected distance visual acuity (UCDV) was 20/400 in the right eye (RE) and 20/20 in the left eye (LE). Best corrected visual acuity was 20/80 on the RE. The Goldmann intraocular pressure (IOP) was 26 and 17 mmHg in the RE and LE, respectively. Slit lamp biomicroscopy revealed fluid in the interface and epithelial ingrowth. Fundoscopic examination results were normal in both eyes. Treatment was initiated with topical brimonidine tartrate 0.2%, timolol 0.5%, and dorzolamide 2.0% BID. Once the pressure was controlled the patient was scheduled for mechanical debridement of the epithelial ingrowth with significant improvement of UCVA (20/25).

**Conclusions:** Refractive surgeons should be aware of PISK as a potential complication of LASIK even years after the procedure. Intraocular pressure can be misleading, and diligent and careful examination are key to diagnosis and treatment of this potentially blinding complication.

## 1. Introduction

Laser in situ keratomileusis (LASIK) is the most scrutinized and studied laser vision correction procedure.<sup>1</sup> Interface epithelial ingrowth is a rare complication and can impair vision significantly. Although most reported cases are mild and visually insignificant, mechanical removal may be necessary in some cases.<sup>2</sup> Another rare complication of LASIK<sup>1</sup> is interface fluid syndrome (IFS), also known as pressure-induced interlamellar stromal keratitis (PISK), characterized by fluid collection at the flap interface due to elevated intraocular pressure, which was described by Belin et al. as a type of interface haze and edema that occurs several weeks to months after LASIK.<sup>3</sup> We describe a case of PISK and epithelial ingrowth 10 years after refractive surgery.

## 2. Case report

A 36-year-old male patient presented to the Department of Cornea and Refractive Surgery at the Instituto de Oftalmología Fundación Conde de Valenciana IAP, in Mexico City, reporting blurred vision in his right eye for 2 years. He had undergone LASIK in both eyes (OU) 10 years ago with no other relevant medical history. He was examined 1 month prior to his visit and was treated with topical prednisolone 1% drops every 3 hours.

Upon clinical examination, uncorrected distance visual acuity (UCDV) was 20/400 in the right eye (RE), which improved to 20/80 with a pinhole, and 20/20 in the left eye (LE). The Goldmann intraocular pressure (IOP) was 26 and 17 mmHg in the RE and LE, respectively. RE refraction was +3.00 = -2.00 × 30. Slit lamp biomicroscopy revealed a

\* Corresponding author. Instituto de Oftalmología Fundación Conde de Valenciana F.A.P., Chimalpopoca 14, Colonia Obrera, Cuauhtémoc, 06800, Mexico.  
E-mail addresses: [guilermoveraduarte@gmail.com](mailto:guilermoveraduarte@gmail.com) (G.R. Vera-Duarte), [jesusgro\\_90@hotmail.com](mailto:jesusgro_90@hotmail.com) (J. Guerrero-Becerril), [mumolfo@gmail.com](mailto:mumolfo@gmail.com) (C.A. Müller-Morales), [arturoramir@gmail.com](mailto:arturoramir@gmail.com) (A. Ramirez-Miranda), [dr.alejandronavas@gmail.com](mailto:dr.alejandronavas@gmail.com) (A. Navas), [egraueh@gmail.com](mailto:egraueh@gmail.com) (E.O. Graue-Hernandez).

<https://doi.org/10.1016/j.ajoc.2023.101874>

Received 22 November 2022; Received in revised form 23 May 2023; Accepted 11 June 2023

Available online 22 June 2023

2451-9936/© 2023 Published by Elsevier Inc. This is an open access article under the CC BY-NC-ND license (<http://creativecommons.org/licenses/by-nc-nd/4.0/>).

large temporal patch of intraepithelial growth reaching the visual axis, fluid accumulation between the flap and stromal bed, sub-epithelial edema, and microbullae (Fig. 1A), on the LE no remarkable findings were noted. The LASIK flap was intact with a superior hinge in both eyes. Fundoscopic examination results were normal in both eyes. Oculus Pentacam curvature sagittal map demonstrating irregular astigmatism in the same area as the intraepithelial ingrowth (Fig. 1A). Pachymetry map (Fig. 2B) and optical coherence tomography (OCT) revealed a central corneal thickness of 579  $\mu\text{m}$  interface opacities and fluid collection in the interface (Fig. 2C). Prednisolone was stopped and combined Brimonidine Tartrate 0.2%, Timolol 0.5% and Dorzolamide 2.0% BID was started (KrytanteK, Laboratorios Sophia, Mexico).

After 36 h of treatment, the patient reported improvement in vision and a decrease in symptoms. On examination, an uncorrected visual acuity of 20/200 improved to 20/40 with refraction and IOP of 14 mmHg with no visible interface fluid detectable on clinical examination. Pressure-lowering medications were continued for 1 month and eventually tapered and discontinued after 3 months. However, because of glare and irregular astigmatism, the patient was scheduled for interface debridement 6 months after initial presentation. (Fig. 1 B, C); Briefly, topical 0.5% tetracaine was administered immediately prior to the procedure. A sterile drape and wire lid speculum was placed on the right eye. The flap was lifted using a LASIK spatula. Epithelial ingrowth was scraped from the posterior surface of the flap and stromal bed using a blunt photorefractive keratectomy spatula. Both stromal faces (both stromal and flap surfaces) were exposed to a micro sponge with 50% alcohol and then 0.02% mitomycin for 40 seconds. After repositioning

the flap, the interface was irrigated with a balanced saline solution followed by 0.5% moxifloxacin, and a bandage contact lens was placed. The patient was treated postoperatively with 0.5% moxifloxacin and 1% prednisolone acetate QID. Once the epithelium healed, the bandage contact lens was removed. On the first day after the intervention, the UCVA in the RE was 20/30 and 1 week after the surgery it was 20/20 (Fig. 1 D, E, F). Topical steroids were tapered over a 2-week period.

### 3. Discussion

PISK after LASIK is a rare but visually threatening postoperative complication. Diffuse lamellar keratitis (DLK) also known as “Sands of Sahara Syndrome” and pressure-induced interlamellar stromal keratitis (PISK)<sup>3</sup> are both LASIK complications with potential overlapping clinical manifestations<sup>4-6</sup> and has to be considered as differential diagnosis, due to the clinical aggravation that can follow the use of steroids in PISK.<sup>4</sup> DLK is an idiopathic interface inflammation that typically occurs within the first postoperative week, with clinical features that range from asymptomatic infiltration confined to the interface to stromal necrosis.<sup>4,5</sup> Inflammatory mononuclear cells and granulocytes, typically seen in patients with DLK, are absent in patients with PISK<sup>6</sup> [6]. We suspect DLK was the initial diagnosis done elsewhere and thus intensive topical steroids were prescribed.

PISK is a disorder with a DLK-like interface haze caused by steroid-induced ocular hypertension after LASIK<sup>6</sup> and the presence of fluid at the interface between the flap and the stromal bed. Kurian et al. demonstrated the findings of confocal microscopy in a patient with

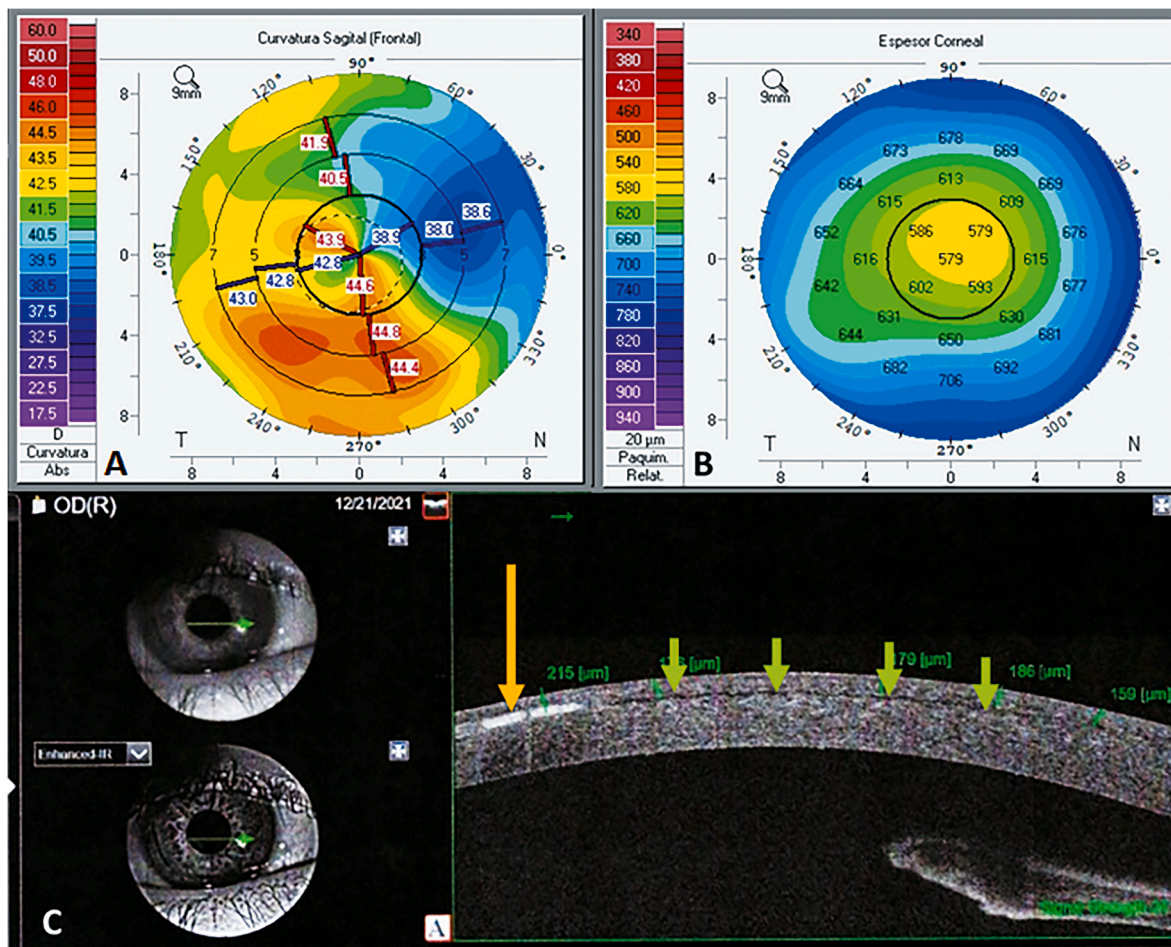
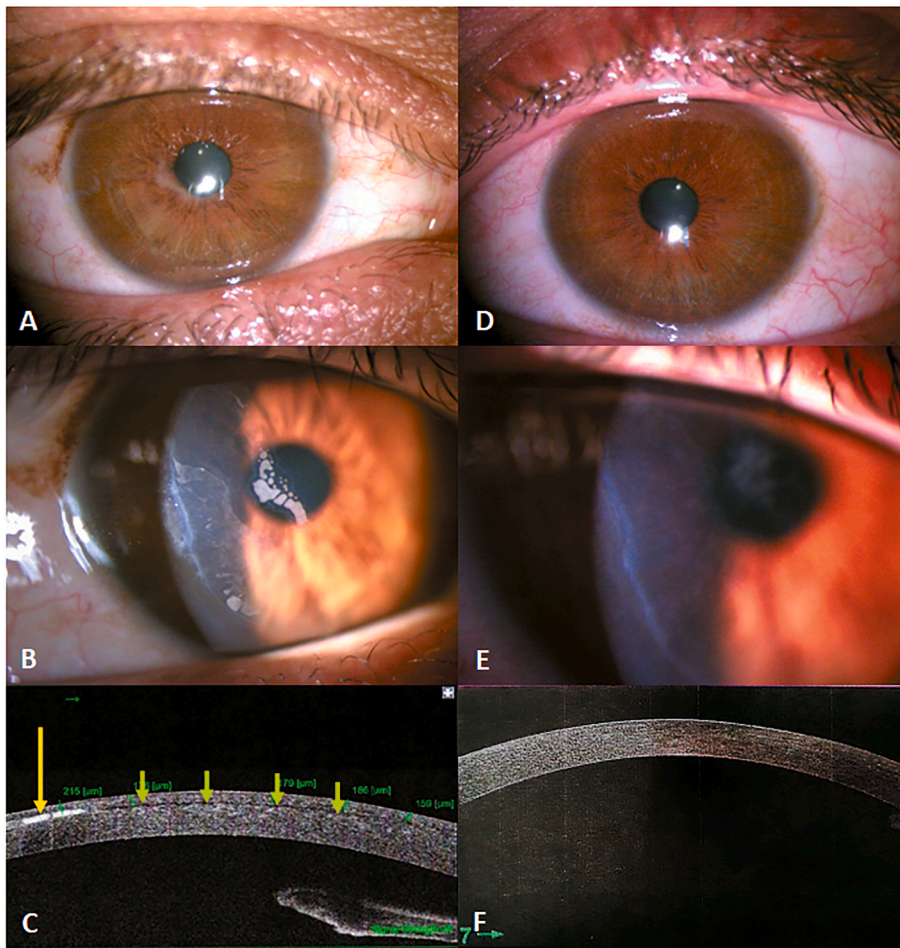


Fig. 1. A) Curvature sagittal map showing irregular astigmatism in the same area as the intraepithelial ingrowth. B) Corneal thickness map reporting a central pachymetry of 579  $\mu\text{m}$ . C) Optical coherence tomography of the Right Eye showing the fluid accumulated between the flap and the stromal bed.





**Fig. 2.** A) General illumination slit-lamp image showing intraepithelial growth around pupil margin (arrow).

B) Diffuse illumination showing epithelial ingrowth and irregular flap border (arrow). C) Anterior segment OCT showing interface fluid (green arrows) and intraepithelial ingrowth (yellow arrow). D) 1 week after procedure showing general illumination without epithelial ingrowth. E) Diffuse illumination 1 week after procedure with residual edema (arrow) and without epithelial ingrowth. F) 1 week after procedure AS-OCT without fluid or epithelial ingrowth. (For interpretation of the references to colour in this figure legend, the reader is referred to the Web version of this article.)

interface haze and elevated IOP after LASIK who had microlacunae, which was thought to be a consequence of stromal edema.<sup>7</sup> The clinical findings are not associated with an accumulation of inflammatory cells but are caused by edema.

PISK is diagnosed by careful examination, with observation of the interface where fluid may accumulate. It may be essential in follow-up examinations to assess resolution of fluid collection using anterior segment OCT<sup>9</sup> or high-resolution Scheimpflug imaging.<sup>9</sup> Intraocular pressure may be misleading<sup>10,11</sup> as PISK may masquerade with falsely low IOP readings. Many refractive surgeons do not measure IOP on the first day after corneal refractive surgery because of concerns about causing further insult to the corneal epithelium. However, IOP should be measured during subsequent postoperative visits. Therefore, in the presence of low IOP and interface fluid syndrome IOP lowering medications should be considered. Some authors recommend performing an OCT scan if SMILE or LASIK is performed if a patient presents with an unexplainable vision loss or if there is an increase in IOP compared with the previous visit.<sup>12</sup> Kim et al. underscore the significance of intraocular pressure (IOP) management in post-refractive surgery eyes, particularly after LASIK, as a means to mitigate potential complications.<sup>13</sup>

The treatment of PISK involves cessation of steroids and initiation of IOP-lowering medications. Beta-blockers are the first-choice medications and, in case of IOP-lowering insufficient response, perhaps IV mannitol or oral diuretics. Unlu et al. emphasized that there have been several publications detailing PISK regarding the use of antiglaucoma medications and discontinuation of topical steroids in its management.<sup>14</sup> Untreated elevated IOP can lead to optic nerve damage, and it is essential to differentiate DLK from PISK because the latter worsens with steroids, which is the typical treatment for DLK.<sup>15</sup>

Epithelial ingrowth after LASIK has been reported to occur in 0–20% of cases, with a cumulative mean of 4.3% in a review of LASIK publications.<sup>5,16,17</sup> Most cases are self-limited, occurring at the edge of the flap and extending inward less than 0.5 mm, without clinical relevance. Surgical removal is required when epithelial ingrowth approaches the edge of the pupil and decreases vision or induces nighttime glare. However, for symptomatic patients, treatment options may include laser ablation or surgical lifting of the flap and scraping of the cells. This case report involved mechanical removal with complete resolution of the symptoms.

Patients with endothelial cell dysfunction are likely to be more susceptible to the development of IFS due to compromised fluid movement out of the corneal stroma, thus facilitating the accumulation of fluid beneath the LASIK flap.<sup>18–21</sup>

Finally, pressure-induced interlamellar stromal keratitis is an important sight-threatening interfacial complication after LASIK. This entity can occur either in the early postoperative period or as late as several months after the procedure.<sup>22</sup> It is unusual for PISK to present as late as 10 years after the procedure, and we hypothesized that intraepithelial ingrowth created a fistula, creating a “space” that facilitated the entrance of fluid towards the LASIK interface. Lee et al. reported an interesting case of a post-LASIK patient presenting with PISK 9 years after the procedure, where the patient had a history of HLA-B27 negative spondyloarthritis, the patient had an episode of uveitis and steroids were added to the treatment and PISK developed, and the clinical course improved after reduction of the steroid.<sup>23</sup>

#### 4. Conclusions

Refractive surgeons should recognize these similar entities, consider them as differential diagnoses, and indicate appropriate management. Usually, PISK is known as an early postoperative complication; however, in this report, we describe the first case of PISK 10 years after LASIK surgery associated with epithelial ingrowth, which is the latest onset reported in the literature (to the knowledge of the authors).

#### Funding

There is no funding received for this work.

#### Patient consent

The patient provided written consent regarding the publication of the present case report.

#### Acknowledgments and disclosures

No funding or grant support

Conflicts of interest:none.

All authors have no financial disclosure.

All authors attest that they meet the current ICMJE criteria for Authorship.

#### Declaration of competing interest

The authors declare that they have no known competing financial interests or personal relationships that could have appeared to influence the work reported in this paper.

#### References

- Moshirfar M, Bennett P, Ronquillo Y. Laser in situ keratomileusis. In: *StatPearls*. StatPearls Publishing; 2023. <http://www.ncbi.nlm.nih.gov/books/NBK55970/>. Accessed May 23, 2023.
- Güell JL, Verdaguer P, Mateu-Figueras G, et al. Epithelial ingrowth after LASIK: visual and refractive results after cleaning the interface and suturing the lenticule. *Cornea*. 2014;33(10):1046–1050. <https://doi.org/10.1097/ICO.0000000000000214>.
- Belin MW, Hannush SB, Yau CW, Schultze RL. Elevated intraocular pressure-induced interlamellar stromal keratitis. *Ophthalmology*. 2002;109(10):1929–1933. [https://doi.org/10.1016/s0161-6420\(02\)01163-6](https://doi.org/10.1016/s0161-6420(02)01163-6).
- Smith RJ, Maloney RK. Diffuse lamellar keratitis. A new syndrome in lamellar refractive surgery. *Ophthalmology*. 1998;105(9):1721–1726. [https://doi.org/10.1016/S0161-6420\(98\)99044-3](https://doi.org/10.1016/S0161-6420(98)99044-3).
- Lin RT, Maloney RK. Flap complications associated with lamellar refractive surgery. *Am J Ophthalmol*. 1999;127(2):129–136. [https://doi.org/10.1016/s0002-9394\(98\)00320-1](https://doi.org/10.1016/s0002-9394(98)00320-1).
- Tourtas T, Kopsachilis N, Meiller R, Kruse FE, Cursiefen C. Pressure-induced interlamellar stromal keratitis after laser in situ keratomileusis. *Cornea*. 2011;30(8):920–923. <https://doi.org/10.1097/ICO.0b013e3182031fec>.
- Kurian M, Shetty R, Shetty BK, Devi SAV. In vivo confocal microscopic findings of interlamellar stromal keratopathy induced by elevated intraocular pressure. *J Cataract Refract Surg*. 2006;32(9):1563–1566. <https://doi.org/10.1016/j.jcrs.2006.03.041>.
- Jia Z, Zhao S, Wei R, Huang Y, Zhang C, Yang R. Interface fluid syndrome: a potential lifelong complication after LASIK. A case report. *Am J Ophthalmol Case Rep*. 2018;11:23–25. <https://doi.org/10.1016/j.ajoc.2018.04.020>.
- Faria-Correia F, Ramos I, Valbon B, Luz A, Roberts CJ, Ambrósio R. Scheimpflug-based tomography and biomechanical assessment in pressure-induced stromal keratopathy. *J Refract Surg Thorofare NJ*. 1995. 2013;29(5):356–358. <https://doi.org/10.3928/1081597X-20130129-03>.
- Arimoto A, Shimizu K, Shoji N, Enomoto K, Kohara M. Underestimation of intraocular pressure in eyes after laser in situ keratomileusis. *Jpn J Ophthalmol*. 2002;46(6):645–649. [https://doi.org/10.1016/s0021-5155\(02\)00555-5](https://doi.org/10.1016/s0021-5155(02)00555-5).
- Shoji N, Ishida A, Haruki T, Matsumura K, Kasahara M, Shimizu K. Interface fluid syndrome induced by uncontrolled intraocular pressure without triggering factors after LASIK in a glaucoma patient. *Medicine (Baltim)*. 2015;94(39), e1609. <https://doi.org/10.1097/MD.0000000000001609>.
- Moshirfar M, Somani AN, Vaidyanathan U, Ronquillo YC, Hoopes PC. Pressure-induced interlamellar stromal keratitis after small-incision lenticule extraction procedure: a case report. *Cornea*. 2020;39(2):254–257. <https://doi.org/10.1097/ICO.0000000000002196>.
- Kim CY, Jung YH, Lee EJ, Hyon JY, Park KH, Kim TW. Delayed-onset interface fluid syndrome after LASIK following phacotrabeculectomy. *BMC Ophthalmol*. 2019;19(1):74. <https://doi.org/10.1186/s12886-019-1077-2>.
- Unlu M, Hondur AM, Korkmaz S, Kumova D, Yuksel E. Pharmacologic management of pressure-induced stromal keratopathy after LASIK. *Optom Vis Sci Off Publ Am Acad Optom*. 2016;93(7):757–759. <https://doi.org/10.1097/OPX.0000000000000853>.
- Siddharthan K, Pooja C, Prabhakar G. Pressure-induced stromal keratopathy after laser-assisted *In situ* keratomileusis with high intraocular pressure in disguise. *TNOA J Ophthalmic Sci Res*. 2020;58(1):27–29. <https://www.tnoajournal.com/article.asp?issn=2589-4528;year=2020;volume=58;issue=1;page=27;epage=29;aulast=Siddharthan>.
- Walker MB, Wilson SE. Incidence and prevention of epithelial growth within the interface after laser in situ keratomileusis. *Cornea*. 2000;19(2):170–173. <https://doi.org/10.1097/00003226-200003000-00009>.
- Condon P, Mulhern M, Fulcher T, Foley-Nolan A, O'Keefe M. Laser intrastromal keratomileusis for high myopia and myopic astigmatism. *Br J Ophthalmol*. 1997;81(3):199–206.
- Ravipati A, Pradeep T, Donaldson KE. Interface fluid syndrome following LASIK surgery - a retrospective pooled analysis and systematic review of the literature. *J Cataract Refract Surg*. 2023. <https://doi.org/10.1097/j.jcrs.0000000000001214>. Published online May 4.
- Hertsenberg AJ, Funderburgh JL. Stem cells in the Cornea. *Prog Mol Biol Transl Sci*. 2015;134:25–41. <https://doi.org/10.1016/bs.pmbts.2015.04.002>.
- Ortega-Usobiaga J, Martin-Reyes C, Llovet-Osuna F, Damas-Mateache B, Baviera-Sabater J. Interface fluid syndrome in routine cataract surgery 10 years after laser in situ keratomileusis. *Cornea*. 2012;31(6):706–707. <https://doi.org/10.1097/ICO.0b013e3182254020>.
- Kasım B, Koçluk Y, Burcu A. Interface fluid syndrome secondary to endothelial failure due to toxic anterior segment syndrome after cataract surgery. *Eur J Ophthalmol*. 2019;29(3):NP1–NP4. <https://doi.org/10.1177/1120672118800241>.
- Cabral-Macias J, García-De la Rosa G, Rodríguez-Matilde DF, et al. Pressure-induced stromal keratopathy after laser in situ keratomileusis: acute and late-onset presentations. *J Cataract Refract Surg*. 2018;44(10):1284–1290. <https://doi.org/10.1016/j.jcrs.2018.06.053>.
- Lee V, Sulewski ME, Zaidi A, Nichols CW, Bunya VY. Elevated intraocular pressure-induced interlamellar stromal keratitis occurring 9 years after laser in situ keratomileusis. *Cornea*. 2012;31(1):87–89. <https://doi.org/10.1097/ICO.0b013e31821140fa>.