

## Simple bone cyst recurred in adjacent areas: A case report

Jin-Soo Kim <sup>1,\*</sup>

<sup>1</sup>Department of Oral and Maxillofacial Radiology, College of Dentistry, Chosun University, Gwangju, Korea

### ABSTRACT

Simple bone cyst is a pseudocyst that typically occurs in patients during their second and third decades of life. This benign entity is an empty or fluid-filled cavity that lacks a true epithelial lining. Simple bone cysts are often asymptomatic and are commonly found in mandibular body, predominantly in the posterior region. The treatment of simple bone cysts can be influenced by factors such as the patient's age, the size of the lesion, and the presence or absence of symptoms. In the case of a simple bone cyst in the mandible that is small and symptomless, a watchful waiting approach may be appropriate. However, if the cyst is large and symptomatic, surgical treatment is recommended. This report presents a radiological examination of a simple bone cyst that developed around the root of the mandibular first molar in a 36-year-old female patient. The cyst recurred in adjacent areas despite surgical treatment. (*Imaging Sci Dent* 2023; 53: 383-8)

**KEY WORDS:** Bone Cyst; Recurrence; Radiography, Panoramic; Cone-Beam Computed Tomography

Simple bone cyst is a pseudocyst that typically manifests during the second decade of life.<sup>1</sup> This benign entity is an empty or fluid-filled cavity within the mandible, devoid of a true epithelial lining. Instead, the simple bone cyst is encased in connective tissue and may be empty or hold a small quantity of blood or consanguineous fluid. The pathogenesis of the simple bone cyst remains unclear,<sup>1,2</sup> leading to its description in the literature under a variety of names, including solitary bone cyst,<sup>2</sup> hemorrhagic bone cyst,<sup>3</sup> extravasation cyst,<sup>4</sup> progressive bone cavity,<sup>5</sup> traumatic bone cyst,<sup>6</sup> idiopathic bone cavity,<sup>7</sup> and unicameral bone cyst.<sup>8</sup> The multitude of names applied to this lesion reflects the lack of understanding of its true etiology and pathogenesis.<sup>9</sup>

Simple bone cysts are typically asymptomatic<sup>10,11</sup> and commonly located in the mandibular body of the jaw.<sup>12</sup> However, there have been reports of several atypical lesions located in the mandibular condyle, ramus, or both.<sup>13-15</sup> Some patients with these lesions may also experience symp-

toms such as pain, swelling, or tooth sensitivity. Less common symptoms of this lesion include root resorption, buccal and lingual bony expansion, fistula formation, paresthesia, delayed eruption of permanent teeth, and pathologic fracture of the mandible.<sup>9</sup>

Radiographically, these lesions present as radiolucent, unilocular areas with scalloped margins,<sup>6</sup> and they rarely show expansion of the cortical bone.<sup>7,16</sup> For these reasons, these lesions are usually detected during radiographic exams carried out for other reasons<sup>17</sup> or routine radiographic examinations.<sup>18</sup> A radiographic assessment is useful for predicting the prognosis of simple bone cysts. A scalloped margin, absent lamina dura, nodular bone expansion, and/or multiple cavities are radiographic features that may suggest an increased risk for recurrence.<sup>19</sup>

The most frequently recommended treatment for a simple bone cyst is surgical exploration, followed by curettage of the bony walls.<sup>20</sup> Surgical exploration serves a dual purpose: it is both a diagnostic maneuver and a therapeutic procedure, as it induces bleeding in the cavity walls. This bleeding, in turn, allows for the formation of a clot, which is eventually replaced by bone. Some authors have also reported instances of spontaneous resolution.<sup>9,21</sup> While careful curettage of the lesion typically results in progressive bone regeneration and a favorable prognosis, boasting an

This study was supported by research funding from Chosun University Dental Hospital, 2021.

Received July 3, 2023; Revised August 18, 2023; Accepted August 27, 2023

Published online October 24, 2023

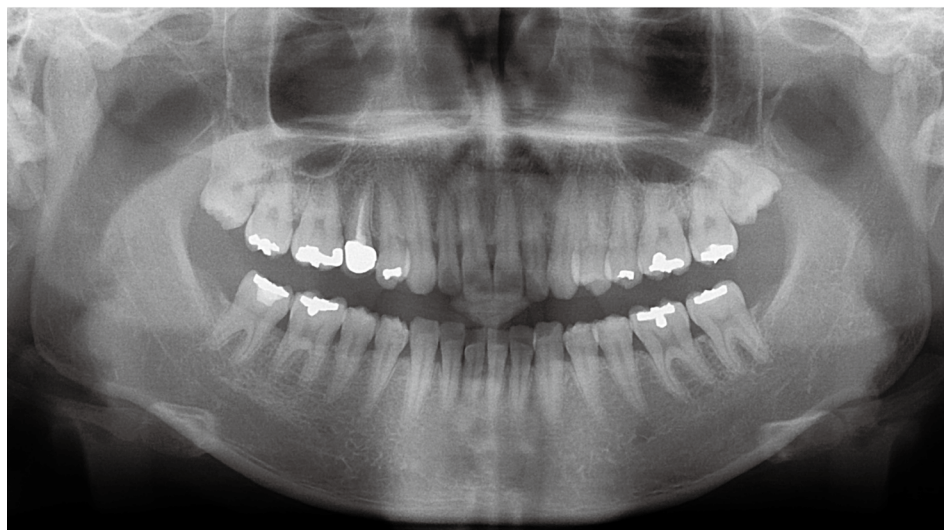
\*Correspondence to : Prof. Jin-Soo Kim

Department of Oral and Maxillofacial Radiology, College of Dentistry, Chosun University, Chosundaegil 7, Dong-gu, Gwangju 61452, Korea  
Tel) 82-62-220-3886, E-mail) hidds@chosun.ac.kr

Copyright © 2023 by Korean Academy of Oral and Maxillofacial Radiology

This is an Open Access article distributed under the terms of the Creative Commons Attribution Non-Commercial License (<http://creativecommons.org/licenses/by-nc/3.0>) which permits unrestricted non-commercial use, distribution, and reproduction in any medium, provided the original work is properly cited.

Imaging Science in Dentistry · pISSN 2233-7822 eISSN 2233-7830



**Fig. 1.** A panoramic radiograph shows slightly generalized alveolar bone resorption at the first visit.

almost negligible recurrence rate,<sup>12</sup> the recurrence rates of simple bone cysts have been a subject of debate and have been reported to vary significantly.<sup>22</sup>

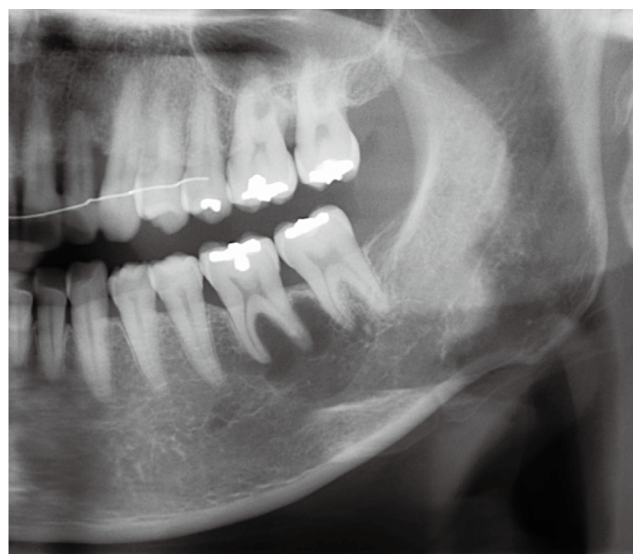
The purpose of this report was to present a case of a simple bone cyst around the root of a mandibular molar that had been present for many years, had not healed, and had migrated to the root of an adjacent tooth and recurred, as observed on panoramic radiographs and cone-beam computed tomography.

### Case Report

The study protocol received approval from the Ethics Committee of Chosun University Dental Hospital (approval no. CUDHIRB 2307 002). The committee also granted an exemption for the requirement of written informed consent.

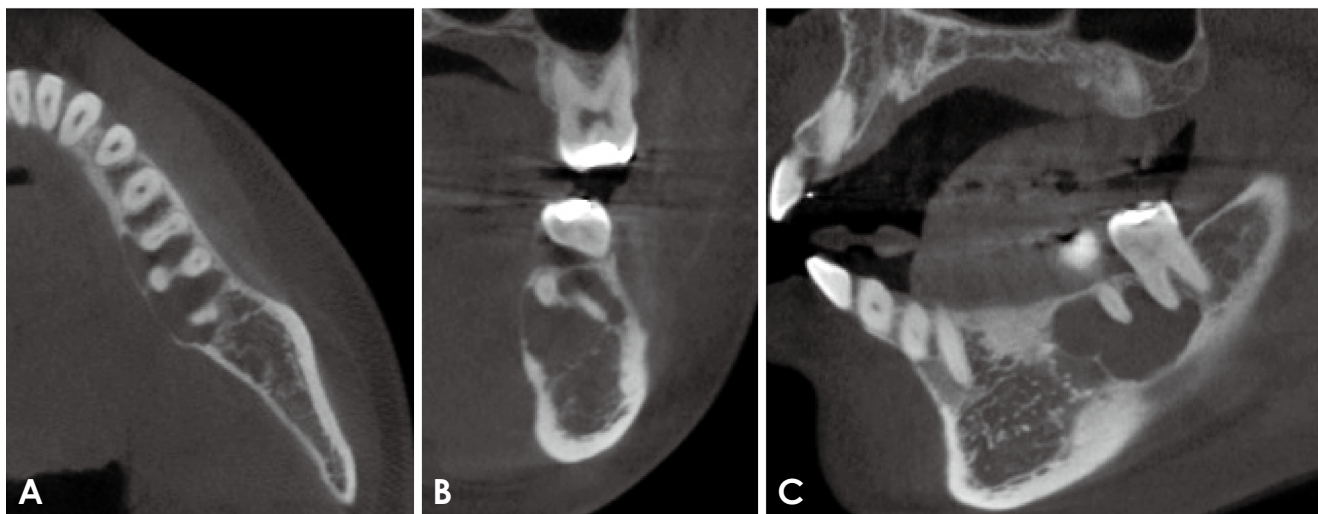
Sixteen years ago, a 25-year-old female patient visited for a third molar extraction. A panoramic radiograph was performed to facilitate the extraction of the maxillary right third molar. Generally, no significant abnormalities were detected, except for the impaction of the third molars on both sides of the maxilla and minor alveolar bone loss in the alveolar crest area (Fig. 1). The patient's maxillary right third molar was successfully extracted, and 4 years later, the maxillary left third molar was also extracted.

Seven years ago, the patient returned to the hospital due to gingival recession in the maxillary anterior teeth. She received periodontal treatment for this, as well as for periodontitis in both the upper and lower posterior teeth. Concurrently, she underwent a 10-month orthodontic treatment to align her maxillary anterior teeth while still receiving periodontal therapy.



**Fig. 2.** A cropped panoramic radiograph taken 11 years later shows a well-defined radiolucency around the roots of the left mandibular first molar.

Five years ago, when the patient was 36 years old and 2 years had passed since receiving periodontal treatment, she visited the hospital for a regular check-up and a panoramic radiograph was taken. This radiograph revealed a radiolucent image around the root of the patient's mandibular left first molar (Fig. 2). The border of this image was relatively clear, and a scalloped margin was visible around the tooth root. To further investigate, cone-beam computed tomography (CBCT) imaging was performed, and a histopathological examination was conducted. The CBCT imaging showed a clear radiolucency around the roots of the mandibular left first molar and the mesial root of the second

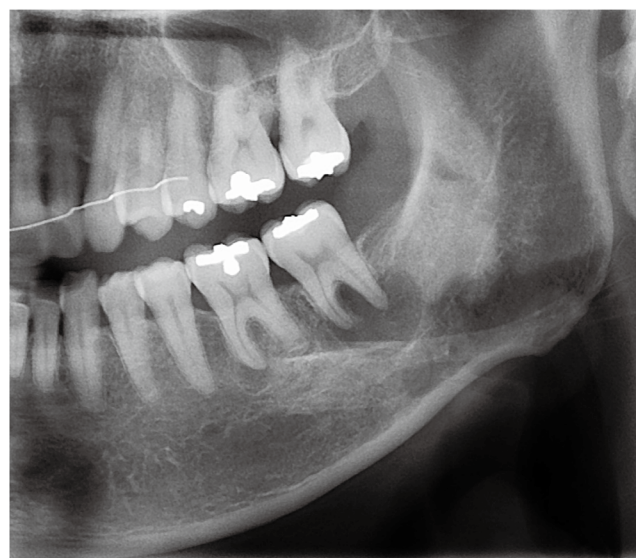


**Fig. 3.** Cone-beam computed tomographic images taken 11 years later. A and B. Axial and coronal images show that the lingual cortical bone is slightly swollen and thinned. C. A sagittal image shows a lesion with a scalloped border involving the root of the mandibular first molar and part of the mesial root of the second molar.

molar. This was accompanied by lingual expansion and cortical bone thinning (Fig. 3). For the histopathological examination, the lesion was accessed from below the apex of the mandibular left first molar. The examination revealed no tissue inside the lesion, with only a thin epithelium present in some areas of the margin. Based on the histopathological examination, the lesion was diagnosed as a simple bone cyst. Given the small size of the lesion, it was decided to continue monitoring the situation without initiating any specific treatment.

Upon continued observation, the lesion increased in size and showed no signs of healing, prompting a repeated histopathological examination. The examination revealed that the lesion was filled with graft material. When the lesion area was excised for further histopathological analysis, it was found to be hollow, much like before, with almost no intestinal epithelium present. Following specimen collection, the lesion area was subjected to curettage. Platelet-rich fibrin (PRF) and Ateloplug M (Hyundai Bioland Co., Cheongju, Korea) were then inserted into the lesion area, and the bone window area was covered with a PRF membrane.

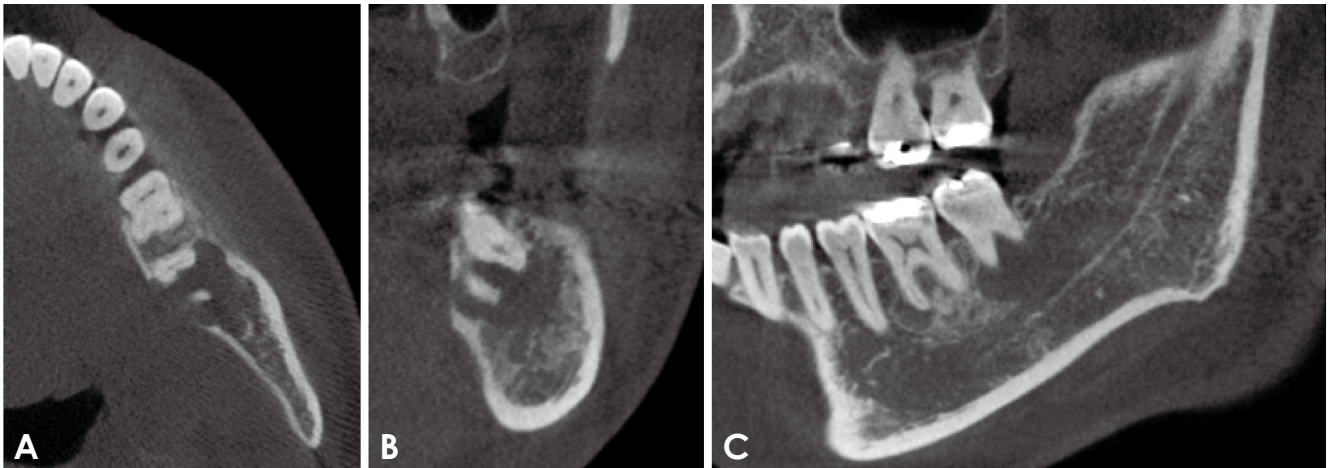
Three years ago, a panoramic radiograph taken after a hospital visit showed that the existing lesion seemed to have disappeared. However, new lesions were observed around the mesial root of the mandibular left first molar and the root of the second molar (Fig. 4). Subsequently, CBCT was conducted, followed by another histopathological examination.



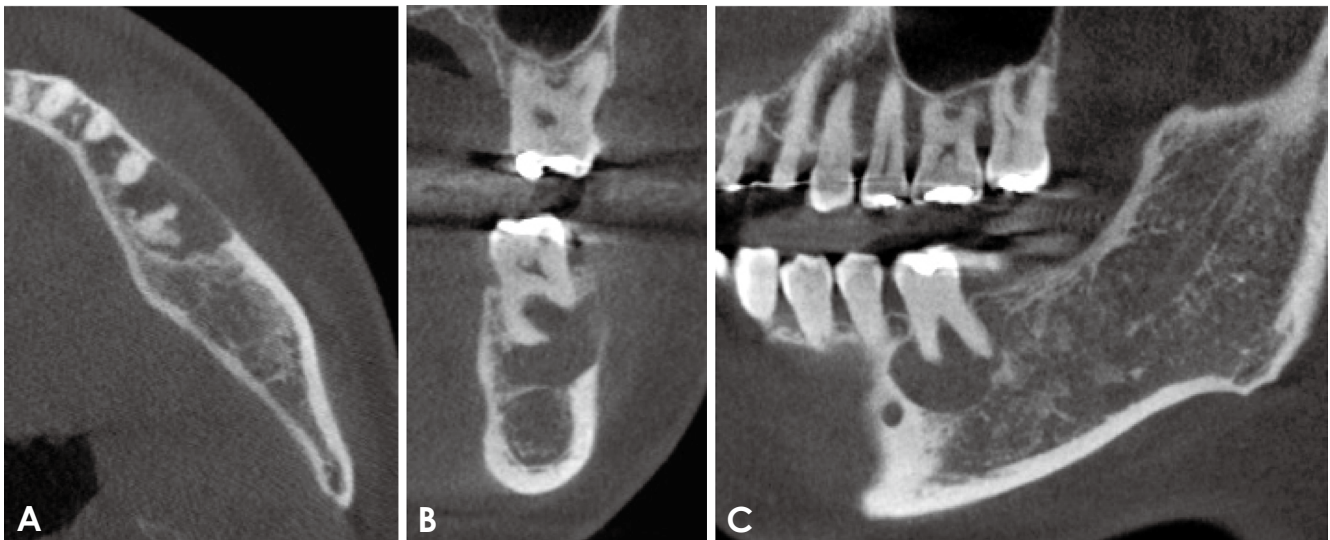
**Fig. 4.** A cropped panoramic radiograph taken 3 years later shows a well-defined radiolucency around the root of the left mandibular first molar and second molar. The area where the previous lesion was located appears to have relatively well-formed bone.

CBCT showed a radiolucency involving the periapical root of the mandibular left first molar and the root of the second molar (Fig. 5). The previously identified lesion appeared to be relatively filled with bone and extended lingually, accompanied by thinning of the cortical bone. However, the bulging of the cortical bone was not as pronounced as it was in earlier observations. Upon opening the lesion for histopathological examination, the interior was





**Fig. 5.** Cone-beam computed tomographic images taken 3 years later. Axial (A), coronal (B), and sagittal (C) images show a lesion around the mesial root of the mandibular first molar and a lesion involving the root of the second molar. The images show that the lingual cortical bone is slightly swollen and partially lost (A and B).



**Fig. 6.** Cone-beam computed tomographic images taken 1 years later. Axial (A), coronal (B), and sagittal (C) images show that the size of the radiolucent image has increased and the buccal cortical bone has become thinner.

found to be empty. As in the previous procedure, the lesion area was curetted, and PRF and Ateloplug M were inserted into the lesion site. The histopathological examination confirmed the lesion to be a simple bone cyst.

Approximately 2 years ago, at a recall visit, a CBCT scan was conducted. The scan revealed that the lesion had not only increased in size but had also expanded to the buccal area. Additionally, the buccal cortical bone had become thinner (Fig. 6). Following this, the lesion area was curetted, and PRF and Ateloplug M were once again injected into the lesion.

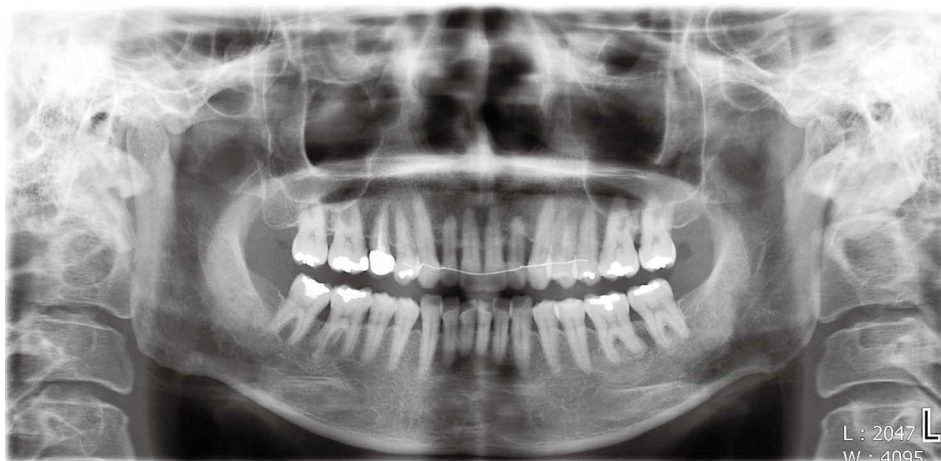Lastly, a radiolucency was no longer observed in the

panoramic radiograph taken when the patient visited for a regular check-up (Fig. 7).

## Discussion

Simple bone cysts are most frequently diagnosed in patients during their second and third decades of life.<sup>23</sup> However, in 15% of cases, they are found in individuals over the age of 40.<sup>24</sup> These cysts are most commonly observed in the posterior mandible.<sup>12,25</sup>

A simple bone cyst is a pseudocyst that lacks a lining epithelium, and it often needs to be differentiated from true



**Fig. 7.** A panoramic radiograph taken 2 years later shows that healing of the lesion is confirmed by the formation of new bone trabecula.

cysts due to the different treatments required for each condition.<sup>18</sup> A study investigating the liquid contents of simple bone cysts in the mandible confirmed that all 19 examined cysts were filled with fluid, as verified both radiographically and surgically.<sup>17</sup> The findings indicated that the cavities of simple bone cysts are filled with a serum-like fluid, not blood. The fluid contents of simple bone cysts may have been inaccurately characterized in previous literature, particularly if a correct aspiration procedure was not performed. In this instance, the internal space was examined histopathologically on three separate occasions and was found to be empty. In some instances, no lining epithelium was observed. In this particular case, the internal space was devoid of any contents, and the epithelial lining was barely observable.

In the majority of cases, the cyst remains asymptomatic and is often detected by panoramic radiography during routine radiographic examinations.<sup>17</sup> Simple bone cysts are characterized by areas of well-defined unilocular radiolucency with typical scalloping borders on radiographs.<sup>9,26,27</sup> Another radiographic feature of simple bone cysts is the extensive spread of the lesion without causing bone expansion; the cortical bone tends to thin due to intraosseous erosion.<sup>20</sup> This characteristic can be observed in the computed tomographic images of the case presented here, which showed lingual cortical thinning, no displacement or resorption of adjacent teeth, and preservation of the lamina dura.

The treatment approach for simple bone cysts can be influenced by several factors, including the patient's age, the size of the lesion, the presence or absence of symptoms, the lesion's location, and its impact on the bone, specifically the extent of bone reaction. In cases where a simple bone cyst is found in the mandible, and it is small and asymp-

tomatic, conservative treatment is typically recommended. This involves intraoral treatment at the lesion site, along with the administration of antibiotics and anti-inflammatory drugs.<sup>28,29</sup> Alternatively, a wait-and-see approach may be adopted. Follow-up involves periodic radiographic examination of the affected bone. If the cyst is large and symptomatic, it is generally advised to make an incision in the lesion area, excise the cyst, and perform bone grafting on the resultant bone defect. The prognosis for simple bone cysts is generally favorable, but there is a risk of recurrence, necessitating regular post-treatment examinations and monitoring.<sup>21</sup> In some cases, radiographic follow-up without surgery has demonstrated spontaneous healing.<sup>28,30</sup> There have also been cases where the lesion resolved following aspiration of the cavity or surgical exploration without curettage.<sup>3,31</sup> Therefore, a scalloped margin can indicate a potential recurrence, but it should not be mistaken for the interdental scalloping that occurs with an intact lamina dura. The correlation between bone expansion and recurrence rate has not been thoroughly explored. However, the recurrence rate was found to be higher in cases with bone expansion compared to those without. Furthermore, the characteristics of the expansion (whether smooth or nodular) played a significant role in prognosis prediction. In a study related to recurrence, Swei et al.<sup>19</sup> reported a recurrence rate of 26.6%. The total number of cases that healed and those that recurred were 102 and 37, respectively. Patients who experienced recurrence were older than those who healed, and recurrence was more common in women than in men.

In this case, the interior of the lesion was excised and filled with bone graft material to track its progression. However, there was a propensity for recurrence in the vicinity of the original lesion. It is suggested that even for smaller lesions, a more aggressive treatment approach may be requi-

red to reduce the risk of recurrence. Additionally, it is imperative to conduct radiological examinations in all instances to assess for potential recurrence.

**Conflicts of Interest:** None

## References

1. Jundt G. Simple bone cyst. In: Barnes L, Eveson JW, Reichart P, Sidransky D. World Health Organization Classification of tumours, pathology and genetics of head and neck tumours. Lyon: IARC Press; 2005. p. 327.
2. Rushton MA. Solitary bone cysts in the mandible. *Br Dent J* 1946; 81:37-49.
3. Howe GL. 'Haemorrhagic cysts' of the mandible. I. *Br J Oral Surg* 1965; 3: 55-76.
4. Boyne PJ. Treatment of extravasation cysts with freeze-dried homogenous bone grafts. *J Oral Surg (Chic)* 1956; 14: 206-12.
5. Whinery JG. Progressive bone cavities of the mandible: a review of the so-called traumatic bone cyst and a report of three cases. *Oral Surg Oral Med Oral Pathol* 1955; 8: 903-16.
6. MacDonald-Jankowski DS. Traumatic bone cysts in the jaws of a Hong Kong Chinese population. *Clin Radiol* 1995; 50: 787-91.
7. Velez I, Siegel MA, Mintz SM, Rolle R. The relationship between idiopathic bone cavity and orthodontic tooth movement: analysis of 44 cases. *Dentomaxillofac Radiol* 2010; 39: 162-6.
8. Evans J, Shamrock AG, Blake J. Unicameral bone cyst [Internet]. Treasure Island: StatPearls; 2023 [updated 2023 Jul 4; cited 2023 Sep 10]. Available from: <https://www.ncbi.nlm.nih.gov/books/NBK470587>.
9. Xanthinaki AA, Choupis KI, Tosios K, Pagkalos VA, Papanikolaou SI. Traumatic bone cyst of the mandible of possible iatrogenic origin: a case report and brief review of the literature. *Head Face Med* 2006; 2: 40.
10. Forssell K, Forssell H, Happonen RP, Neva M. Simple bone cyst. Review of the literature and analysis of 23 cases. *Int J Oral Maxillofac Surg* 1988; 17: 21-4.
11. Hansen LS, Sapone J, Sproat RC. Traumatic bone cysts of jaws: report of sixty-six cases. *Oral Surg Oral Med Oral Pathol* 1974; 37: 899-910.
12. Cortell-Ballester I, Figueiredo R, Berini-Aytés L, Gay-Escoda C. Traumatic bone cyst: a retrospective study of 21 cases. *Med Oral Patol Oral Cir Bucal* 2009; 14: E239-43.
13. Shigematsu H, Fujita K, Watanabe K. Atypical simple bone cyst of the mandible. A case report. *Int J Oral Maxillofac Surg* 1994; 23: 298-9.
14. Magliocca KR, Edwards SP, Helman JI. Traumatic bone cyst of the condylar region: report of 2 cases. *J Oral Maxillofac Surg* 2007; 65: 1247-50.
15. Kim KA, Koh KJ. Recurrent simple bone cyst of the mandibular condyle: a case report. *Imaging Sci Dent* 2013; 43: 49-53.
16. Beasley JD 3rd. Traumatic cyst of the jaws: report of 30 cases. *J Am Dent Assoc* 1976; 92: 145-52.
17. Choi SY, Boboeva O, Ham JY, An CH, Lee ST, Kim JW, et al. Analysis of the fluid contents of simple bone cyst in the mandible. *Sci Rep* 2022; 12: 10083.
18. Surej Kumar LK, Kurien N, Thaha KA. Traumatic bone cyst of mandible. *J Maxillofac Oral Surg* 2015; 14: 466-9.
19. Suei Y, Taguchi A, Nagasaki T, Tanimoto K. Radiographic findings and prognosis of simple bone cysts of the jaws. *Dentomaxillofac Radiol* 2010; 39: 65-71.
20. Brunet-Llobet L, Lahor-Soler E, Mashala EI, Miranda-Rius J. Continuous surgical decompression for solitary bone cyst of the jaw in a teenage patient. *Case Rep Dent* 2019; 2019: 9137507.
21. Kuttenger JJ, Farmand M, Stöss H. Recurrence of a solitary bone cyst of the mandibular condyle in a bone graft. A case report. *Oral Surg Oral Med Oral Pathol* 1992; 74: 550-6.
22. Suei Y, Taguchi A, Tanimoto K. Simple bone cyst of the jaws: evaluation of treatment outcome by review of 132 cases. *J Oral Maxillofac Surg* 2007; 65: 918-23.
23. Chrcanovic BR, Gomez RS. Idiopathic bone cavity of the jaws: an updated analysis of the cases reported in the literature. *Int J Oral Maxillofac Surg* 2019; 48: 886-94.
24. Freedman GL, Beigleman MB. The traumatic bone cyst: a new dimension. *Oral Surg Oral Med Oral Pathol* 1985; 59: 616-8.
25. You MS, Kim DY, Ahn KM. Surgical management of idiopathic bone cavity: case series of consecutive 27 patients. *J Korean Assoc Oral Maxillofac Surg* 2017; 43: 94-9.
26. Copete MA, Kawamata A, Langlais RP. Solitary bone cyst of the jaws: radiographic review of 44 cases. *Oral Surg Oral Med Oral Pathol Oral Radiol Endod* 1998; 85: 221-5.
27. Sabino-Bezerra JR, Santos-Silva AR, Jorge J Jr, Gouvêa AF, Lopes MA. Atypical presentations of simple bone cysts of the mandible: a case series and review of literature. *J Craniomaxillofac Surg* 2013; 41: 391-6.
28. Sapp JP, Stark ML. Self-healing traumatic bone cysts. *Oral Surg Oral Med Oral Pathol* 1990; 69: 597-602.
29. Battisti MP, Soares MQ, Rubira CM, Bullen IR, Lauris JR, Damante JH. Assessment of spontaneous resolution of idiopathic bone cavity. *J Appl Oral Sci* 2018; 26: e20170288.
30. Damante JH, Da S Guerra EN, Ferreira Jr O. Spontaneous resolution of simple bone cysts. *Dentomaxillofac Radiol* 2002; 31: 182-6.
31. Chapman PJ, Romaniuk K. Traumatic bone cyst of the mandible; regression following aspiration. *Int J Oral Surg* 1985; 14: 290-4.