

Iatrogenic flexor tendon rupture caused by misdiagnosing sarcoidosis-related flexor tendon contracture as tenosynovitis: A case report

Rui Yan, Zhe Zhang, Long Wu, Zhi-Peng Wu, He-De Yan

Specialty type: Medicine, research and experimental

Provenance and peer review: Unsolicited article; Externally peer reviewed.

Peer-review model: Single blind

Peer-review report's scientific quality classification

Grade A (Excellent): 0
Grade B (Very good): 0
Grade C (Good): C
Grade D (Fair): 0
Grade E (Poor): 0

P-Reviewer: Bernardes A, Portugal

Received: August 26, 2023

Peer-review started: August 26, 2023

First decision: November 9, 2023

Revised: November 18, 2023

Accepted: December 7, 2023

Article in press: December 7, 2023

Published online: December 26, 2023



Rui Yan, The Second Clinical Medical College, Zhejiang Chinese Medical University, Hangzhou 310053, Zhejiang Province, China

Zhe Zhang, Long Wu, Zhi-Peng Wu, Department of Orthopedics (Division of Hand Surgery), The Second Affiliated Hospital and Yuying Children's Hospital of Wenzhou Medical University, Wenzhou 325026, Zhejiang Province, China

He-De Yan, Department of Hand Surgery, The Second Affiliated Hospital and Yuying Children's Hospital of Wenzhou Medical University, Wenzhou 325026, Zhejiang Province, China

Corresponding author: He-De Yan, MD, PhD, Director, Department of Hand Surgery, The Second Affiliated Hospital and Yuying Children's Hospital of Wenzhou Medical University, No. 666 Oushi Road, Dongtou District, Wenzhou 325026, Zhejiang Province, China.
yanhede@hotmail.com

Abstract

BACKGROUND

Sarcoidosis is a multisystem disease characterized by granuloma formation in various organs. Sarcoidosis-related flexor tendon contractures are uncommon in clinical settings. This contracture is similar to stenosing tenosynovitis and potentially leads to misdiagnosis and mistreatment. Herein, we report a rare case of sarcoidosis-related finger flexor tendon contracture that was misdiagnosed as tenosynovitis.

CASE SUMMARY

A 44-year-old woman presented to our department with flexion contracture of the right ring and middle fingers. The patient was misdiagnosed with tenosynovitis and underwent acupotomy release of the A1 pulley of the middle finger in another hospital that resulted in iatrogenic rupture of both the superficial and profundus flexors. Radiological presentation showed multiple sarcoid involvements in the pulmonary locations and ipsilateral forearm. A diagnosis of sarcoidosis was made based on the presence of non-caseating granulomas with tubercles consisting of Langhans giant cells with lymphocyte infiltration on biopsy, and the patient underwent surgical repair for the contracture. After 2 mo, the patient experienced another spontaneous rupture of the repaired middle

finger tendon and underwent surgical re-repair. Satisfactory results were achieved at the 10 mo follow-up after reoperation.

CONCLUSION

Sarcoidosis-related finger contractures are rare; thus, caution should be exercised when dealing with such patients to avoid incorrect treatment.

Key Words: Sarcoidosis; Finger; Contracture; Iatrogenic; Misdiagnosis; Case report

©The Author(s) 2023. Published by Baishideng Publishing Group Inc. All rights reserved.

Core Tip: Finger contracture due to tenosynovitis is frequently encountered in clinical settings. However, misdiagnosis can occur when rare causes such as sarcoidosis are neglected. Here, we report a case in which such a misdiagnosis led to an iatrogenic injury. The mainstream treatment method for contractures related to sarcoidosis is surgical excision of muscular lesions, with varied outcomes in several case reports. In our case, considering the contracture lesion at the flexor digitorum profundus (FDP) and the initial iatrogenic tendon rupture, cross-lengthening of the flexor digitorum superficialis and FDP was attempted to restore flexion and achieve satisfactory results.

Citation: Yan R, Zhang Z, Wu L, Wu ZP, Yan HD. Iatrogenic flexor tendon rupture caused by misdiagnosing sarcoidosis-related flexor tendon contracture as tenosynovitis: A case report. *World J Clin Cases* 2023; 11(36): 8512-8518

URL: <https://www.wjgnet.com/2307-8960/full/v11/i36/8512.htm>

DOI: <https://dx.doi.org/10.12998/wjcc.v11.i36.8512>

INTRODUCTION

Granulomatous involvement of the skeletal muscles (also known as granulomatous myopathy) is common in patients with sarcoidosis, and most cases are asymptomatic[1]. However, cases of finger flexion contractures are extremely rare. To the best of our knowledge, only a few cases of such contractures have been reported in the English literature[2-6].

Contracture of finger flexors is frequently observed in tenosynovitis (also known as trigger finger) in clinical settings [7]. Trigger finger is caused by inflammation and constriction of the retinacular sheath through which the flexor tendons run as they pass from the palm of the hand to the finger, leading to pain and movement restriction. The management of tenosynovitis is well established, ranging from conservative to surgical treatment[7-9]. Because finger contractures of other causes, such as sarcoidosis, are rare, misdiagnosis of tenosynovitis could occur, leading to empirical treatment with poor outcomes or severe complications.

Herein, we present a patient with finger contractures who was misdiagnosed with trigger finger and received acupotomy release[10,11] (similar to percutaneous release), resulting in iatrogenic rupture of both the superficial and profundus flexors of the right middle finger. We also conducted a systematic literature review of finger contractures caused by sarcoidosis.

CASE PRESENTATION

Chief complaints

A 44-year-old healthy woman presented to our hand surgery department with spontaneous flexor tendon rupture of the right middle finger and contracture of the right ring finger.

History of present illness

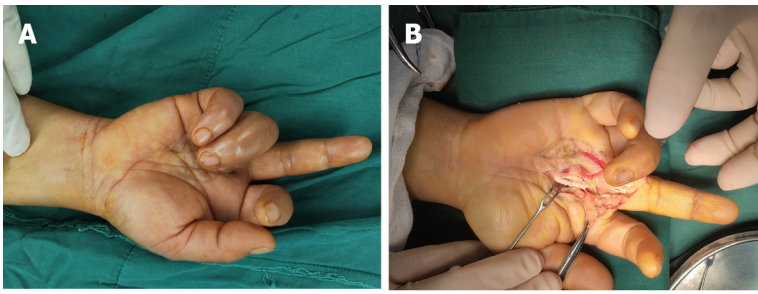
The patient was diagnosed with tenosynovitis of the right ring finger and middle finger at a local hospital and underwent acupotomy release of her middle finger 2 wk prior to admission. Five days after the release, a sudden complete loss of active flexion of the right middle finger was observed during routine domestic activities. Two months after the surgery, re-rupture of the repaired middle finger tendon was encountered when the patient was pulling on her pants.

History of past illness

The patient denied any past illnesses.

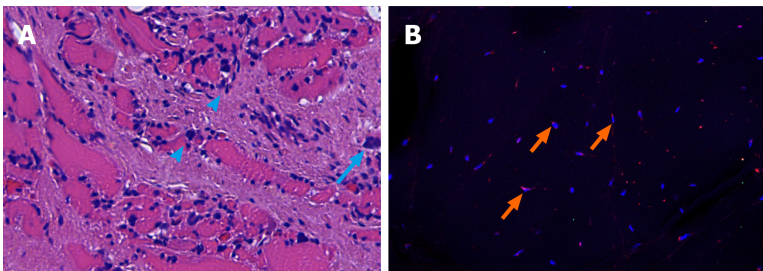
Personal and family history

The patient denied any personal or family history of related diseases.



DOI: 10.12998/wjcc.v11.i36.8512 Copyright ©The Author(s) 2023.

Figure 1 Findings during the first surgery. A: The extended middle finger and flexed ring finger before exploration; B: Intraoperative view of the rupture of both flexor digitorum superficialis and flexor digitorum profundus tendon at the metacarpophalangeal joint of the middle finger.



DOI: 10.12998/wjcc.v11.i36.8512 Copyright ©The Author(s) 2023.

Figure 2 Results of hematoxylin and eosin staining and immunofluorescence staining of the flexor digitorum profundus muscle. A: Interstitial diffuse infiltration of scattered lymphocytes (arrowheads) and multinucleated giant cells (arrow) in the muscle tissue; B: The cells were stained for nuclei (DAPI, blue) and CD68 (red). This highlights the giant cells that are positively immunostained for CD68 (arrows).

Physical examination

Loss of active flexion of the right middle finger and contracture of the right ring finger were observed. There was no swelling, tenderness, or numbness of the digits. No other positive findings were observed during systematic physical examination. During the operation, all lacerations of the flexor digitorum superficialis (FDS) and flexor digitorum profundus (FDP) of the right middle finger were identified in Zone II around the metacarpophalangeal (MCP) joint (Figure 1). Significantly, a high level of tension and loss of elasticity were observed at the proximal end of the FDP, whereas the proximal FDS seemed normal in tension and elasticity.

Laboratory examinations

Initial laboratory studies revealed high alkaline phosphatase (116 U/L, normal range: 35–100 U/L) and normal serum creatinine, creatine phosphokinase, and calcium levels. No further positive findings were noted in the laboratory examinations.

Histopathology revealed granulomatous involvement in the FDP muscles and tendons, showing a typical sarcoid shape with tubercles consisting of Langhans' giant cells and lymphocytes (Figure 2).

Imaging examinations

High-resolution computed tomography (CT) revealed widespread nodules in both the lungs (Figure 3).

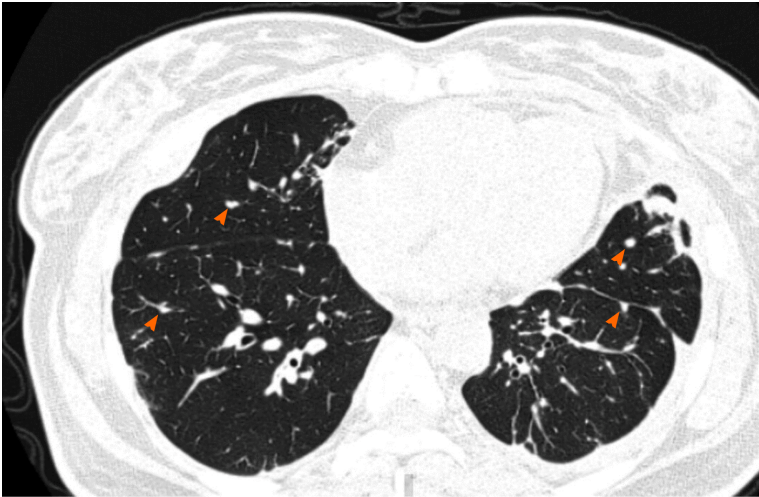
Magnetic resonance imaging (MRI) revealed a central dark star surrounded by a peripheral high-signal area in the right forearm muscles on axial images and a three-stripe pattern on coronal and sagittal images, typical of sarcoid myopathy (Figure 4)[12–14].

FINAL DIAGNOSIS

The patient was diagnosed with sarcoidosis-related flexor tendon contractures and iatrogenic flexor tendon rupture.

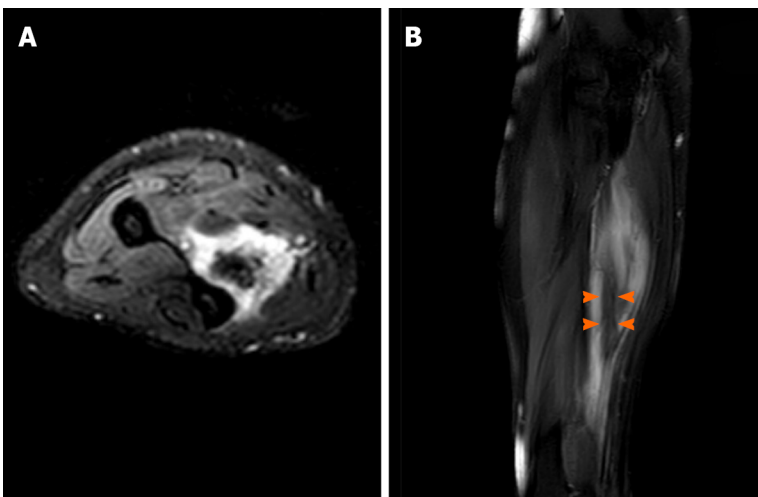
TREATMENT

During the first surgical exploration, the distal FDP of the middle finger was anastomosed with the proximal end of the FDS to restore flexion. Surprisingly, the ring finger remained in contracture after complete open release of the A1 pulley,



DOI: 10.12998/wjcc.v11.i36.8512 Copyright ©The Author(s) 2023.

Figure 3 High-resolution computed tomographic section showing widespread nodules (arrowheads) in both lungs.



DOI: 10.12998/wjcc.v11.i36.8512 Copyright ©The Author(s) 2023.

Figure 4 Magnetic resonance imaging revealing a lesion located at the flexor digitorum profundus muscle. A: T2-weighted fat saturated axial image of the forearm shows a nodule of increased signal intensity, while the center structure shows decreased signal intensity; B: T2-weighted fat saturated sagittal image of the forearm shows an inner stripe of decreased signal intensity (arrowheads) and outer stripes of increased signal intensity.

indicating that the contracture was not due to tenosynovitis. No further intraoperative intervention was performed after discussion with the patient. Routine postoperative management was performed, including splinting for 4 wk and corresponding rehabilitation.

Unfortunately, 2 mo after the operation, re-rupture of the repaired tendon was encountered when the patient was pulling on her pants (Figure 5A). Repeat operations were performed on the right middle and ring fingers. Anastomoses of the proximal FDS to the distal FDP using tendon grafting were performed for the middle finger and direct repair was performed for the ring finger (Figure 5B).

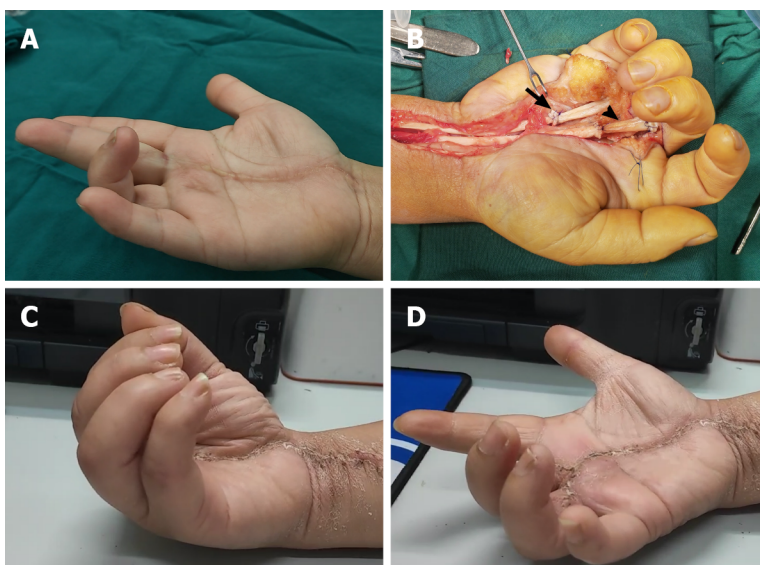
OUTCOME AND FOLLOW-UP

The patient partially regained the motion of her middle finger, while contracture of her right ring finger persisted after the first surgical attempt. After reoperation, the patient could use the hand without discomfort despite persistent mild stiffness at the 10 mo follow-up (Figure 5C and D).

Table 1 Literature review of published cases of flexor contractures associated with sarcoidosis

Ref.	Sex	Age	Affected hands	Affected fingers	Treatment	Outcomes of contractures
Warburg[20]	F	56	L and R	All fingers	None	NA
Simmonds and Hoffbrand[19]	F	58	L and R	3 rd fingers	Prednisolone and dapsone	Worsened
	M	65	R	4 th finger	Steroids, and Azathioprine	Cured after duration of 6 yr
Ikeda <i>et al</i> [2] and Tada <i>et al</i> [4]	F	63	R	2-4 th fingers	Granulomatous lesion excision	Worsened two years postoperatively
Motomiya <i>et al</i> [5]	F	61	L and R	5 th fingers	Granulomatous lesion excision	NA
Bowers <i>et al</i> [3]	M	14	L	3-5 th fingers	Occupational therapy	Improved
Ueba and Obara[18]	F	58	L and R	4, 5 th fingers	Granulomatous lesion excision	Cured at a follow-up of 2.5 yr
Walter <i>et al</i> [21]	M	36	L and R	3-5 th fingers	Low-dose thalidomide therapy	Markedly improved

F: Female; M: Male; L: Left hand; R: Right hand; NA: Not available.



DOI: 10.12998/wjcc.v11.i36.8512 Copyright ©The Author(s) 2023.

Figure 5 The second surgery and follow-up. A: The extended middle finger and flexed ring finger before reexploration; B: Intraoperative view of the repaired tendons of the middle and ring fingers. Arrow: The repaired site of the ring finger with suturing the distal end of the flexor digitorum profundus to the proximal end of the flexor digitorum superficialis. Arrowhead: The repaired site of the middle finger with tendon grafting; C and D: Range of active motion of the affected fingers 10 mo after reoperation.

DISCUSSION

In the present case, surgery was performed when the patient presented with an iatrogenic rupture. Sarcoidosis was not considered until the second surgical attempt and was confirmed after MRI and chest CT. After the re-rupture, a comprehensive medical history revealed an additional experience of mild discomfort with tenderness on physical examination around the forearm flexor muscles, indicating a muscular lesion. Furthermore, tenosynovitis should have been ruled out because the patient denied experiencing pain or triggering around the MCP joint or had a history of aggravation after housework.

Although contractures due to sarcoidosis are extremely rare, neglecting these distinct symptoms and the absence of a systematic examination resulted in misdiagnosis and subsequent mistreatment.

The diagnosis of sarcoidosis is not well established, but is recommended according to three major aspects: A compatible clinical and/or radiological presentation, histological evidence of non-necrotizing granulomatous inflammation in one or more tissues, and exclusion of alternative causes of granulomatous disease[15].

Chest radiography has been the cornerstone of sarcoidosis diagnosis since 1961, when Scadding[16] proposed a standardized staging system. Chest CT is currently the reference standard for the assessment of pulmonary findings and mediastinal lymph nodes[17]. In our case, MRI and biopsy revealed lesions in the forearm muscles, whereas a clear diagnosis of sarcoidosis was made only after CT imaging.

The treatment of sarcoidosis-related contractures has been reported in several case reports with varied results[2-5,18-21] (Table 1).

Acute sarcoid myopathy improves with systemic treatment in most patients, while patients with chronic sarcoid myopathy commonly experience severe disability such as flexor contractures and seldom recover after corticosteroid, immunosuppressive, or anti-tumor necrosis factor- α treatment[22,23]. Surgical intervention has been attempted in such chronic cases of finger contractures[2,4,5,18]. In 1996, Ikeda *et al*[2] reported that contractures due to sarcoidosis could be successfully treated by surgical excision of the lesion. However, in 2009, they reported that even with complete excision of the granulomatous lesion, a new lesion may appear in a previously healthy area; therefore, radical cure by surgery alone is difficult[4]. Conservative treatments have also been reported. Walter *et al*[21] reported a case in which the contractures improved after 9 mo of treatment with low-dose thalidomide. Bowers reported a 14-year-old patient who improved with occupational therapy[3]. Notably, while in previous cases, biopsy tests focused on forearm muscles, our biopsy results revealed a lesion at the tendon as well.

Coincidentally, Motomiya *et al*[5] also reported a patient with sarcoidosis-related flexor contracture who was initially misdiagnosed with trigger finger and underwent open surgery. Fortunately, the tendon was fully exposed during the operation, and the misdiagnosis of tenosynovitis was realized. In our case, the patient was misdiagnosed with tenosynovitis and treated by acupotomy (a type of blind release) during the first visit to a local hospital. The operation did not provide further information about the contracture, inevitably resulting in iatrogenic flexor rupture when pursuing complete finger flexion. Therefore, the treatment of tenosynovitis using acupotomy should be performed with great caution in preoperative diagnosis.

In our case, because of the initial iatrogenic flexor tendon rupture, tendon grafting was performed to repair the FDP tendon by connecting the proximal end of the FDS to the distal FDP. Notably, open surgery of the digit revealed normal tension at the FDS, and the FDS muscle was later proven to be free of lesions based on biopsy results; thus, this surgery was able to partially restore flexion to the affected fingers. In conclusion, this method was adapted because of the initial attempt to repair the tendon rupture and achieved satisfactory results in alleviating the contractures at the 10 mo follow-up.

CONCLUSIONS

Sarcoid involvement of the musculoskeletal system that causes finger contractures is rare and can lead to misdiagnosis if clinicians are not aware. Our case shows that finger contracture release by connecting the normal proximal end of the FDS to the distal FDP may be an option for such cases, although the management of sarcoidosis-related flexor contractures remains controversial, with varied outcomes based on a literature review.

ACKNOWLEDGEMENTS

We thank Dr. Mazhar Ali Raza for the editing assistance.

FOOTNOTES

Author contributions: Yan R and Zhang Z prepared the initial draft of this manuscript and made subsequent revisions; Wu L and Wu ZP performed the data collection and manuscript review and editing; Yan HD performed the conceptualization and validation of the study and acquired funding of the report; all authors have reviewed and approved the final manuscript.

Supported by Zhejiang Provincial Natural Science Foundation of China, No. LY23H090009; Clinical Research Foundation of the Second Affiliated Hospital Wenzhou Medical University, No. SAHoWMU-CR2018-08-417.

Informed consent statement: The study participant provided written informed consent before study enrollment.

Conflict-of-interest statement: The authors have no conflicts of interest related to this manuscript.

CARE Checklist (2016) statement: The authors have read the CARE Checklist (2016), and the manuscript was prepared and revised according to the CARE Checklist (2016).

Open-Access: This article is an open-access article that was selected by an in-house editor and fully peer-reviewed by external reviewers. It is distributed in accordance with the Creative Commons Attribution NonCommercial (CC BY-NC 4.0) license, which permits others to distribute, remix, adapt, build upon this work non-commercially, and license their derivative works on different terms, provided the original work is properly cited and the use is non-commercial. See: <https://creativecommons.org/licenses/by-nc/4.0/>

Country/Territory of origin: China

ORCID number: He-De Yan 0000-0003-1276-3059.

S-Editor: Lin C

L-Editor: Wang TQ

P-Editor: Lin C

REFERENCES

- 1 Baydur A, Pandya K, Sharma OP, Kanel GC, Carlson M. Control of ventilation, respiratory muscle strength, and granulomatous involvement of skeletal muscle in patients with sarcoidosis. *Chest* 1993; **103**: 396-402 [PMID: 8432126 DOI: 10.1378/chest.103.2.396]
- 2 Ikeda K, Saito M, Sueyoshi Y, Ichizen H, Tomita K. Flexion contracture of fingers due to sarcoidosis--a case report. *Acta Orthop Scand* 1996; **67**: 623-625 [PMID: 9065081 DOI: 10.3109/17453679608997770]
- 3 Bowers B, Patel AM, Mirza N, Seidman RJ. Paediatric contracturing granulomatous myositis. *Scand J Rheumatol* 2008; **37**: 394-395 [PMID: 18821276 DOI: 10.1080/03009740802093878]
- 4 Tada K, Ikeda K, Tomita K. Flexion contracture of the fingers caused by sarcoidosis: an 11-year follow-up. *Scand J Plast Reconstr Surg Hand Surg* 2009; **43**: 171-173 [PMID: 19401937 DOI: 10.1080/02844310701510306]
- 5 Motomiya M, Iwasaki N, Kawamura D. Finger flexion contracture due to muscular involvement of sarcoidosis. *Hand Surg* 2013; **18**: 85-87 [PMID: 23413857 DOI: 10.1142/S0218810413720015]
- 6 Thulasidoss K, Sridharan S, Ashokan L, Chandra P. A Rare Case of Sarcoidosis Presenting as Diffuse Contracturing Granulomatous Myositis on Fluorodeoxyglucose Positron Emission Tomography/Computed Tomography. *Indian J Nucl Med* 2018; **33**: 148-151 [PMID: 29643679 DOI: 10.4103/ijnm.IJNM_154_17]
- 7 Giugale JM, Fowler JR. Trigger Finger: Adult and Pediatric Treatment Strategies. *Orthop Clin North Am* 2015; **46**: 561-569 [PMID: 26410644 DOI: 10.1016/j.ocl.2015.06.014]
- 8 Vasiliadis AV, Itsiopoulos I. Trigger Finger: An Atraumatic Medical Phenomenon. *J Hand Surg Asian Pac Vol* 2017; **22**: 188-193 [PMID: 28506168 DOI: 10.1142/S021881041750023X]
- 9 Huisstede BM, Gladdines S, Randsdorp MS, Koes BW. Effectiveness of Conservative, Surgical, and Postsurgical Interventions for Trigger Finger, Dupuytren Disease, and De Quervain Disease: A Systematic Review. *Arch Phys Med Rehabil* 2018; **99**: 1635-1649.e21 [PMID: 28860097 DOI: 10.1016/j.apmr.2017.07.014]
- 10 Li D, Wang X, Fang T, Chen Y, Xiang S, Qi J, Liang C, Ren C, Zhao X, Qiu Z, Liu F, Yan X. Acupotomy in the treatment of tenosynovitis of hand flexor tendons: A systematic review and meta-analysis. *Medicine (Baltimore)* 2022; **101**: e31504 [PMID: 36397432 DOI: 10.1097/MD.00000000000031504]
- 11 Shen Y, Zhou Q, Sun X, Li S, Zhang W. Percutaneous Release of the First Extensor Tendon Compartment in De Quervain's Disease by Acupotomy with US-Guidance: A Cadaveric Study. *J Pain Res* 2022; **15**: 3995-4005 [PMID: 36579178 DOI: 10.2147/JPR.S375309]
- 12 Otake S, Banno T, Ohba S, Noda M, Yamamoto M. Muscular sarcoidosis: findings at MR imaging. *Radiology* 1990; **176**: 145-148 [PMID: 2353084 DOI: 10.1148/radiology.176.1.2353084]
- 13 Otake S. Sarcoidosis involving skeletal muscle: imaging findings and relative value of imaging procedures. *AJR Am J Roentgenol* 1994; **162**: 369-375 [PMID: 8310929 DOI: 10.2214/ajr.162.2.8310929]
- 14 Venkata Ramanan R, Pudhiavan A, Venkataramanan A. The "cluster of black pearls" sign of sarcoid lymphadenopathy: a new sign on thin-section contrast-enhanced multidetector CT. *Clin Radiol* 2017; **72**: 729-736 [PMID: 28655404 DOI: 10.1016/j.crad.2017.03.031]
- 15 Sève P, Pacheco Y, Durupt F, Jamilloux Y, Gerfaud-Valentin M, Isaac S, Bousset L, Calender A, Androdias G, Valeyre D, El Jammal T. Sarcoidosis: A Clinical Overview from Symptoms to Diagnosis. *Cells* 2021; **10** [PMID: 33807303 DOI: 10.3390/cells10040766]
- 16 SCADDING JG. Prognosis of intrathoracic sarcoidosis in England. A review of 136 cases after five years' observation. *Br Med J* 1961; **2**: 1165-1172 [PMID: 14497750 DOI: 10.1136/bmj.2.5261.1165]
- 17 Nunes H, Brillet PY, Valeyre D, Brauner MW, Wells AU. Imaging in sarcoidosis. *Semin Respir Crit Care Med* 2007; **28**: 102-120 [PMID: 17330195 DOI: 10.1055/s-2007-970336]
- 18 Ueba Y, Obara A. Sarcoidosis manifested by gradual flexion contracture of fingers. *Hand* 1974; **6**: 91-94 [PMID: 4825404 DOI: 10.1016/0072-968x(74)90018-7]
- 19 Simmonds NJ, Hoffbrand BI. Contracturing granulomatous myositis: a separate entity. *J Neurol Neurosurg Psychiatry* 1990; **53**: 998-1000 [PMID: 2283532 DOI: 10.1136/jnnp.53.11.998]
- 20 WARBURG M. A case of symmetrical muscular contractures due to sarcoidosis. *J Neuropathol Exp Neurol* 1955; **14**: 313-315 [PMID: 14392482 DOI: 10.1097/00005072-195507000-00008]
- 21 Walter MC, Lochmüller H, Schlotter-Weigel B, Meindl T, Müller-Felber W. Successful treatment of muscle sarcoidosis with thalidomide. *Acta Myol* 2003; **22**: 22-25 [PMID: 12966701]
- 22 Le Roux K, Streichenberger N, Vial C, Petiot P, Feasson L, Bouhour F, Ninet J, Lachenal F, Broussolle C, Sève P. Granulomatous myositis: a clinical study of thirteen cases. *Muscle Nerve* 2007; **35**: 171-177 [PMID: 17068767 DOI: 10.1002/mus.20683]
- 23 Androdias G, Maillot D, Marignier R, Pinède L, Confavreux C, Broussolle C, Vukusic S, Sève P. Mycophenolate mofetil may be effective in CNS sarcoidosis but not in sarcoid myopathy. *Neurology* 2011; **76**: 1168-1172 [PMID: 21444902 DOI: 10.1212/WNL.0b013e318212aafb]



Published by **Baishideng Publishing Group Inc**
7041 Koll Center Parkway, Suite 160, Pleasanton, CA 94566, USA

Telephone: +1-925-3991568

E-mail: bpgoffice@wjgnet.com

Help Desk: <https://www.f6publishing.com/helpdesk>

<https://www.wjgnet.com>

