

Erratum to: *DUSP22*-rearranged ALK-negative anaplastic large cell lymphoma is a pathogenetically distinct disease but can have variable clinical outcome

Kerry J. Savage^{1,2} and Graham W. Slack^{1,3}

¹Centre for Lymphoid Cancer, BC Cancer; ²University of British Columbia and Division of Medical Oncology, BC Cancer and ³University of British Columbia and Department of Pathology, BC Cancer, Vancouver, Canada


Correspondence: K.J. Savage
ksavage@bccancer.bc.ca

Received: September 13, 2023.

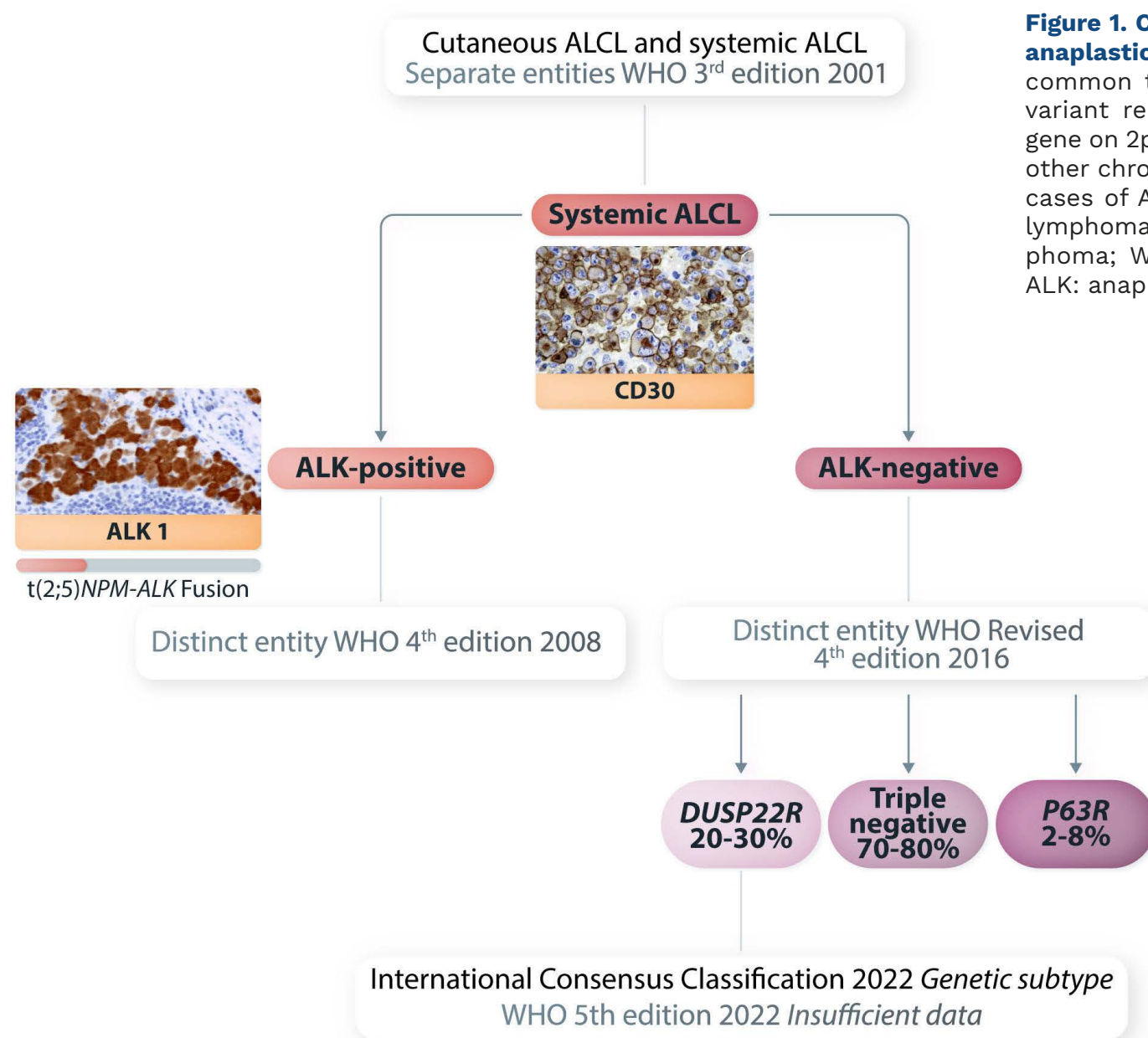
Accepted: September 13, 2023.

<https://doi.org/10.3324/haematol.2023.284289>

©2024 Ferrata Storti Foundation

Published under a CC BY-NC license 

We made non-substantive typographical corrections and the following substantive changes to the original figure of our editorial “*DUSP22*-rearranged ALK-negative anaplastic large cell lymphoma is a pathogenetically distinct disease but can have variable clinical outcome”: WHO 2nd edition 2001 is changed to WHO 3rd edition 2001; WHO 3rd edition 2008 is changed to WHO 4th edition 2008; and WHO 4th edition 2016 is changed to WHO Revised 4th edition 2016.



References

1. Savage KJ, Slack GW. *DUSP22*-rearranged ALK-negative anaplastic large cell lymphoma is a pathogenetically distinct disease but can have variable clinical outcome. *Haematologica*. 2023;108(6):1463–1467.