

Syndrome of the month

Journal of Medical Genetics 1988, **25**, 557-560

Russell-Silver syndrome

MICHAEL A PATTON

Regional Genetics Service, St George's Hospital Medical School, Cranmer Terrace, London SW17 0RE.

In 1953, Silver *et al*¹ reported two unrelated children with congenital hemihypertrophy, low birth weight, short stature, and raised gonadotrophins. The following year Russell² described five unrelated children with extreme intrauterine growth retardation and characteristic facial features. These children had remained small and in two cases there was body asymmetry. The characteristic features he described were triangular shaped face with a broad forehead and pointed, small chin, together with a wide, thin, 'shark-like' mouth.

Although each author emphasised rather different features, the composite features have been identified as the Russell-Silver syndrome,³ and attempts to separate the Silver syndrome from the Russell syndrome, depending on whether asymmetry is present or absent, have not generally been accepted.

The syndrome has been described at least 150 times in published reports⁴ and is a well recognised cause of intrauterine growth retardation. It has been reported in all racial groups.^{4 5}

Clinical features

PREGNANCY AND BIRTH WEIGHT

Intrauterine growth retardation is the rule in this syndrome. Obstetric complications do not appear to be more frequent in pregnancies with this syndrome.⁶ The vast majority of affected children are born at term and are extremely light for dates with birth weights below the 3rd centile for gestation (range 1.2 to 2.5 kg).⁶ The birth length may also be reduced but the head circumference may be appropriate for gestation, giving the appearance of a disproportionately large head.

NEONATAL PERIOD

Excessive perspiration and tachypnoea because of hypoglycaemia may be seen in the neonatal period.⁴ The mechanism for this might be a depletion of liver

glycogen stores, as is seen in other light for dates babies or may have a different metabolic basis. Snow *et al*⁷ reported a two and a half year old boy with the Russell-Silver syndrome who had afebrile convulsions occurring early in the morning owing to ketotic hypoglycaemia.⁷

CRANIOFACIAL FEATURES (FIGS 1 AND 2)

The head is large in relation to the body length. The biparietal diameter is increased and the anterior fontanelle may be delayed in closing. The disproportionately large head has been referred to as 'pseudohydrocephalic'.^{8 9} Clinically it can be distinguished from hydrocephalus by the growth of the head circumference parallel to the appropriate centile and by the normal fontanelle pressure.

The forehead is broad and bossed and the lower

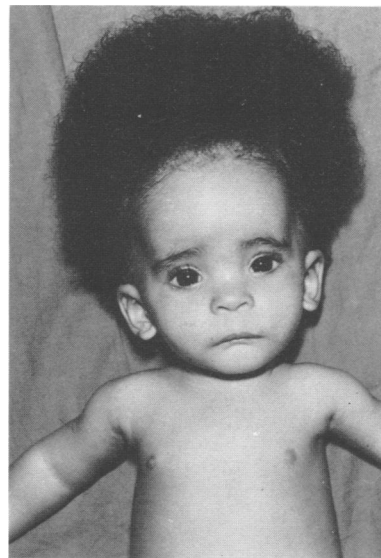


FIG 1 *Facial features of Russell-Silver syndrome in a West Indian infant.*

Received for publication 5 November 1987.

Revised version accepted for publication 19 February 1988.

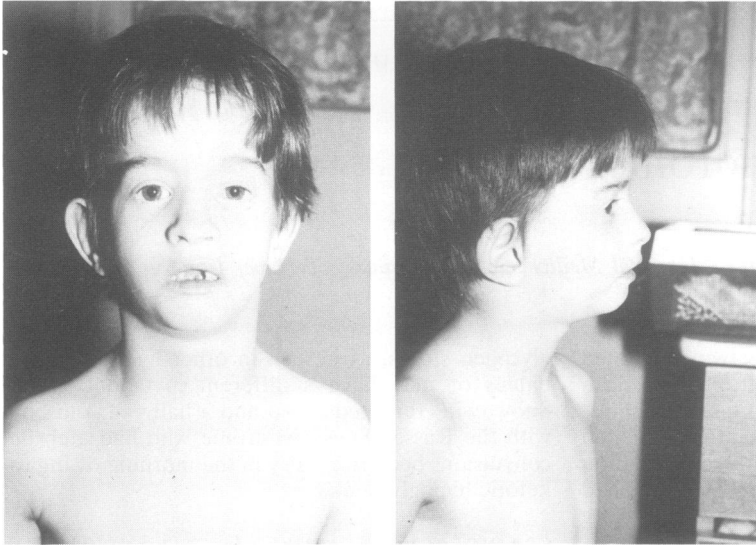


FIG 2 Frontal and lateral photographs of a child with Russell-Silver syndrome.

portion of the face is relatively small with a pointed chin, giving the inverted triangular facial appearance described by Russell.² The nose may be slightly beaked. The mouth is wide and downturned at the edges. The vermillion border of the lips is thin especially on the upper lip.

The eyes appear relatively large and the sclera may show a bluish hue.

The palate is narrow and high arched. Cleft palate has been reported.⁵

The ears are below the maximum diameter of the skull and may protrude slightly.

LIMBS

Clinically apparent limb asymmetry occurs in 60% of patients reported (fig 3). Although Silver *et al*¹ originally described this feature as hemihypertrophy, it has been unclear whether the asymmetry is the result of hemihypertrophy, hemiatrophy, or a disturbance of the normal range of symmetry. There have been few measurements of limb length to resolve this issue. Tanner *et al*⁶ in a careful anthropometric study of limb length in 39 subjects with Russell-Silver syndrome found a continuity in the variation of limb length between the normal controls

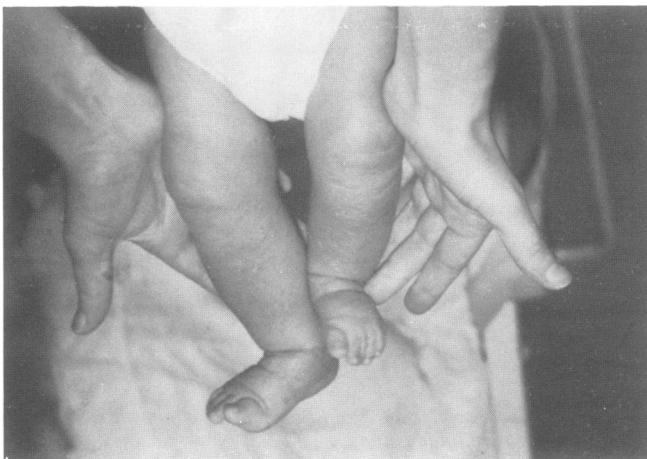

FIG 3 Limb asymmetry appears in 60% of patients. It is important to exclude congenital dislocation of the hips as a cause of the asymmetry.

and those with the Russell-Silver syndrome, leading them to the conclusion that the cause of the asymmetry is a disturbance in the control of symmetry. In the reported cases there are certainly no examples showing similar degrees of hemihypertrophy as is seen in Klippel-Trenaunay-Weber syndrome and there is no increase in anomalies known to be associated with hemihypertrophy such as Wilms' tumour or mental retardation.

One point of practical significance to remember in assessing asymmetry in the legs is that congenital dislocation of the hip has been reported as an associated feature in this syndrome.

Short fifth fingers with clinodactyly are frequent findings, but unfortunately rather non-specific. There is one report of oligodactyly.¹⁰

POSTNATAL GROWTH

There is no 'catch-up' in the fetal growth retardation. Children continue to grow parallel to the centiles but about -3 SD below the mean.^{6 11} The final predicted height in the study of Tanner *et al*⁶ was 153.5 cm in males and 147 cm in females. In the adult cases reported the final adult heights have been below the predicted estimate (males 149.5 cm, females 138 cm).^{5 12 13} The retardation in the bone age matches the retardation in growth.

Growth hormone deficiency is not the cause of the growth delay, although coexistent growth hormone deficiency has been reported.¹⁴ For those without a demonstrable deficiency of growth hormone, therapeutic trials of growth hormone have not corrected the growth pattern.⁶

The children remain thin with a lack of subcutaneous fat which can be confirmed by measurement.⁶

PSYCHOMOTOR DEVELOPMENT

Normal intelligence is the rule in this syndrome. There may, however, be some delay in the early motor milestones owing to the decreased muscle bulk and relatively large head.

GENITALIA

Genital abnormalities such as cryptorchidism or hypospadias are frequent. Ambiguous genitalia in males have been reported on three occasions.^{4 15 16} Pubertal development is normal.

Raised urinary gonadotrophin levels were a feature in the original paper,¹ but no consistent abnormality in gonadotrophin levels has been found in this syndrome.

OTHER FEATURES

Occasional café au lait patches may be seen. Other features have been reported occasionally and may

be coincidental. They include cardiac conduction defects, atrial septal defect, pulmonary stenosis, renal asymmetry, and cystic fibrosis.

DIFFERENTIAL DIAGNOSIS

The dysmorphic features of this syndrome are relatively 'soft' and this may lead to inappropriate diagnosis.¹⁴ It may be that there is heterogeneity within the syndrome. The differential diagnosis includes the following.

(1) Intrauterine growth retardation owing to placental insufficiency. The Russell-Silver syndrome should be distinguishable from the effects of placental insufficiency (table). Chronic intrauterine growth retardation leads to a decrease in all growth parameters, that is, a 'perfect miniature', and is followed in most cases by catch up growth in the first year of life. Late intrauterine growth retardation, especially in the postmature fetus, leads to a thin, low birth weight baby with normal length and head circumference.¹⁷

(2) Chromosomal mosaicism. The phenotype has been reported in patients with mosaic trisomy 18,¹⁸ a diploid-triploid mosaicism,¹⁹ and a 45,X/46,XY mosaicism.¹⁶ Consideration should be given to examining skin fibroblasts in addition to peripheral blood, especially where there is mental retardation or sexual ambiguity.

(3) 3-M syndrome.²⁰ This autosomal recessive syndrome has several features in common with the Russell-Silver syndrome, including intrauterine growth retardation, relatively large head, and short fifth fingers. It can be distinguished from the Russell-Silver syndrome by the presence of prominent heels, tall vertebral bodies, and the facial features, which include a broad, fleshy nose and a hatchet shaped profile.

(4) X linked short stature with skin pigmentation (Partington).²¹ This syndrome has been described as a variant of the Russell-Silver syndrome. There is a diffuse brown pigmentation with some achromic patches.

(5) Neonatal progeroid (Rautenstrauch).²² This syndrome has pseudohydrocephalus, generalised deficiency of subcutaneous fat, and natal teeth.

TABLE Comparison of the clinical features seen in intrauterine growth retardation (IUGR) and Russell-Silver syndrome.

	Chronic IUGR	Late IUGR	Russell-Silver syndrome
Birth weight			
Birth length		N	
OFC		N	N
Subcutaneous fat			
Symmetry	Yes	Yes	No
Catch up growth	2/3rds	Rapid	None

Genetics and aetiology

A comprehensive genetic analysis of the syndrome by Escobar *et al*⁵ identified a number of familial cases of the syndrome which had been reported. In over 150 cases there were four instances of recurrence in sibs, and five instances where another member or members of the family showed some of the features of the syndrome suggesting possible autosomal dominant inheritance with variable expression. These reports represent a small minority of the reported cases. As the syndrome is neither fatal nor associated with a significant risk of infertility, more two generation families would be expected if the syndrome were the result of an autosomal dominant mutation. Perhaps the best way of determining if there is a risk of recurrence for offspring will be to follow up prospectively one of the well studied cohorts, such as that by Tanner *et al*.⁶

In the meantime, since the syndrome clearly represents a form of intrauterine growth retardation, the application of new techniques of studying fetal growth are likely to be informative. Serial ultrasound measurements in utero, tests on placental function or blood flow, and studies on new growth factors such as somatomedins might all be helpful in unravelling the aetiology of this syndrome.

The patient group for the Russell-Silver syndrome in the UK is *c/o* Mrs Gill Howarth, 10 Christmas Pie Avenue, Normandy, Guildford, Surrey. I would like to thank Dr Baraitser for the illustrations and Mrs S Willoughby for secretarial help.

References

- ¹ Silver HK, Kiyasu W, George J, Deamer WC. Syndrome of congenital hemihypertrophy, shortness of stature and elevated urinary gonadotrophins. *Pediatrics* 1953;12:368-76.
- ² Russell A. A syndrome of "intrauterine" dwarfism recognisable at birth with cranio-facial dysostosis, disproportionately short arms, and other anomalies. *Proc R Soc Med* 1954;47:1040-4.
- ³ Black J. Low birth weight dwarfism. *Arch Dis Child* 1961;36:633-44.
- ⁴ Marks LJ, Bergeson PS. The Russell-Silver syndrome. *Am J Dis Child* 1977;131:447-51.
- ⁵ Escobar V, Gleiser S, Weaver DD. Phenotypic and genetic analysis of the Silver-Russell syndrome. *Clin Genet* 1978;13:278-88.
- ⁶ Tanner JM, Lejarraga H, Cameron N. The natural history of the Silver-Russell syndrome: a longitudinal study of thirty-nine cases. *Pediatr Res* 1975;9:611-23.
- ⁷ Snow R, Sarkis M, Cornblath M. Ketotic hypoglycaemia in a Russell dwarf. *J Pediatr* 1966;69:121-5.
- ⁸ Szalay GC. Pseudohydrocephalus in dwarfs: the Russell dwarf. *J Pediatr* 1963;63:622-33.
- ⁹ Fitch N, Pinsky L. The lateral facial profile of the Silver-Russell dwarf. *J Pediatr* 1972;80:827-9.
- ¹⁰ Keepen LD, Rennet OM. Silver-Russell syndrome with absence of digits and syndactyly of the fingers. *Clin Genet* 1983;24:453-5.
- ¹¹ Angel MV, Zachman M, Prader A. Silver-Russell syndrome. Observations on 20 patients. *Helv Paediatr Acta* 1979;34:297-308.
- ¹² Rimoin DC. The Silver syndrome in twins. *Brith Defects* 1969;5:183-6.
- ¹³ Abramowicz HK, Nitowsky HM. Reproductive ability of an adult female with Silver-Russell syndrome. *J Med Genet* 1977;14:134-6.
- ¹⁴ Saal HM, Pagon RA, Pipin MG. Re-evaluation of Russell-Silver syndrome. *J Pediatr* 1985;107:733-7.
- ¹⁵ Haslam RH, Berman W, Heller RM. Renal abnormalities in the Russell-Silver syndrome. *Pediatrics* 1973;51:216-22.
- ¹⁶ Tulinuis H, Tryggvason K, Hauksdottir H. 45X/46XY chromosome mosaic with features of the Russell-Silver syndrome: a case report with a review of the literature. *Dev Med Child Neurol* 1972;14:161-72.
- ¹⁷ Davies DP. In: Davies J, Dobbing J, eds. *Scientific foundations of paediatrics*. 2nd ed. London: Heineman, 1983.
- ¹⁸ Chauvel PJ, Moore CM, Haslam RH. Trisomy 18 mosaicism with features of Russell-Silver syndrome. *Dev Med Child Neurol* 1975;17:220-43.
- ¹⁹ Ferrier P, Ferrier S, Stalder G, Buhler E, Bamatter F, Klein D. Congenital asymmetry associated with diploid-triploid mosaicism and large satellites. *Lancet* 1964;i:80-2.
- ²⁰ Winter RM, Baraitser M, Grant DB, Preece MA, Hall CM. The 3-M syndrome. *J Med Genet* 1984;21:124-8.
- ²¹ Partington MW. X-linked short stature with skin pigmentation: evidence for heterogeneity of the Russell-Silver syndrome. *Clin Genet* 1986;29:151-6.
- ²² Wiedermann HR. An unidentified neonatal progeroid syndrome: follow up report. *Eur J Pediatr* 1979;130:65-70.

Correspondence and requests for reprints to Dr M A Patton, Regional Genetics Service, St George's Hospital Medical School, Cranmer Terrace, London SW17 0RE.