

the fourth and fifth toes with absence of the other toes, and the left foot had a smaller midline cleft with absence of only the third toe. Moerman *et al*<sup>4</sup> reported a case of trisomy 18 syndrome with a 'lobster claw' deformity of the left foot. Neither of these cases had published illustrative *x* rays.

The present case differs from those previously reported in having a deep cleft of both feet between the hallux and the other toes, which were syndactylous. The *x* ray (fig 3) confirms that the cleft is between the hallux and the other toes and shows loss of the second ray of the left foot, with hypoplasia of the third ray, and hypoplasia of both these rays on the right. As such, the deformity is analogous to the type I split hand/split foot anomaly described by Tentamy and McKusick,<sup>7</sup> but the hypoplasia of the marginal rays makes it closer to the atypical variety of Lange.

Other chromosomal syndromes which have been associated with foot anomalies similar to those found in trisomy 18 include duplications of 9p, 10q24→qter, and 14p (syndactyly of the second and third toes), and trisomy 13 (cleft between first and second toes, syndactyly).<sup>1</sup> A number of syndromes have occasionally exhibited clefting of the feet; these include Carpenter syndrome, De Lange syndrome, ectrodactyly-ectodermal dysplasia-clefting syndrome, Goltz syndrome, Jarcho-Levin syndrome, Miller syndrome, and Pfeiffer syndrome.<sup>1</sup> The *x* ray appearance of our case distinguishes it from the classical familial split hand/split foot anomaly (following autosomal dominant, recessive, or X linked recessive inheritance),<sup>7,8</sup> as well as from the autosomal dominant split hand and split foot anomaly described among the Wadoma tribe of Eastern Zimbabwe and the Talaunda of Botswana.<sup>9</sup>

There are certain features in the present case which appear to be an exaggerated form of the foot anomalies more commonly described in trisomy 18

syndrome. A wide gap between the hallux and the other toes with a tendency to syndactyly of the latter is frequent in the trisomy 18 syndrome, while dorsiflexion of the hallux is also a common feature.<sup>2</sup> As such, our case may represent the extreme end of this maldevelopment spectrum.

We wish to thank Dr M Ossip for referring the infant to us for investigation. Dr K A Margolius of the Department of Anatomical Pathology, SAIMR, performed the necropsy. DC wishes to acknowledge the support of a South African Medical Research Council Post-Internship Scholarship.

#### References

- 1 Smith DW. *Recognizable patterns of human malformations*. Philadelphia: Saunders, 1982.
- 2 Schinzel A. *Catalogue of unbalanced chromosome aberrations in man*. Berlin: Walter de Gruyter, 1983:628-33.
- 3 Butler LJ, Snodgrass GJAI, France NE, Sinclair L, Russell A. E(16-18) trisomy syndrome: analysis of 13 cases. *Arch Dis Child* 1965;40:600-11.
- 4 Moerman P, Frys JP, Goddeeris P, Lauweryns JM. Spectrum of clinical and autopsy findings in trisomy 18 syndrome. *J Genet Hum* 1982;30:17-38.
- 5 Christianson AL, Nelson MM. Four cases of trisomy 18 syndrome with limb reduction malformations. *J Med Genet* 1984;21:293-7.
- 6 Ramirez-Castro JL, Bersu ET. Anatomical analysis of the developmental effects of aneuploidy in man—the 18-trisomy syndrome. II. Anomalies of the upper and lower limbs. *Am J Med Genet* 1978;3:285-306.
- 7 Tentamy S, McKusick V. *The genetics of hand malformations*. New York: Alan R Liss, 1978:36-71.
- 8 Mufti MH, Wood SK. Ectrodactyly in sisters and half sisters. *J Med Genet* 1987;24:220-4.
- 9 Viljoen DL, Beighton P. The split-hand and split-foot anomaly in a Central African Negro population. *Am J Med Genet* 1984;19:545-52.

Correspondence and requests for reprints to Dr Renee Bernstein, Department of Human Genetics, South African Institute for Medical Research, PO Box 1038, Johannesburg 2000, South Africa.

## Deletion of band 5q21 in association with a de novo translocation involving 2p and 5q

JAR-FEE YUNG\*, NANCY WILLIAMSON†, I SALAFSKY‡, AND J J HOO\*

\*Department of Pediatrics, University of Illinois, Chicago; †Rockford Memorial Hospital, Rockford; and ‡Division of Genetics, Department of Pediatrics, Evanston Hospital, Evanston, Illinois, USA.

**SUMMARY** A six month old girl with developmental delay and dysmorphic features was found to have a translocation involving 2p and 5q as well as a deletion of band 5q21.

Acquired interstitial deletion 5q of bone marrow cells has frequently been found in haematological disorders.<sup>1</sup> Constitutional interstitial deletion of 5q is, however, relatively rare. To our knowledge, there have been only 10 previous published cases of interstitial deletion 5q.<sup>2-10</sup> We report here a child with coloboma of the right eye, dysmorphic facial

features, and developmental delay, whose karyotype showed a small interstitial deletion 5q in addition to a de novo translocation involving 2p and 5q.

**Case report**

The proband, the first child of healthy parents, was born at 38 weeks of gestation by caesarean section because of cephalopelvic disproportion and fetal distress. The birth weight was 2640 g. Coloboma of the right eye and coarse facies were noted at birth (fig 1). Computerised tomography of the brain was reported to be normal.

Re-evaluation at the age of six months showed that her weight was 5.2 kg (below the 5th centile), her length was 62 cm (at the 10th centile), and her

head circumference was 41 cm (between the 10th and 25th centile). She had an upturned nose with anteverted nostrils. Her right eye was slightly smaller than the left and the palpebral fissures measured 2 cm and 2.3 cm respectively. The coloboma of the right eye extended from the iris to the retina. There were no other obvious dysmorphic features. She was hypotonic with poor head control. Her motor development was about three and a half months delayed.

**CYTOGENETIC STUDIES**

Chromosome analysis with G banding of peripheral lymphocytes showed a translocation involving a 2p and 5q. In order to determine the breakpoints precisely, the analysis was repeated with high resolution chromosome preparation using bromodeoxyuridine as the blocking agent (GBG banding).<sup>11</sup> Cells at the 550 band stage were

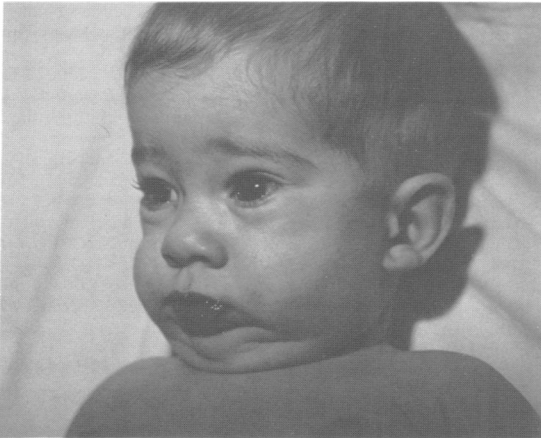

FIG 1 The proband aged six months.

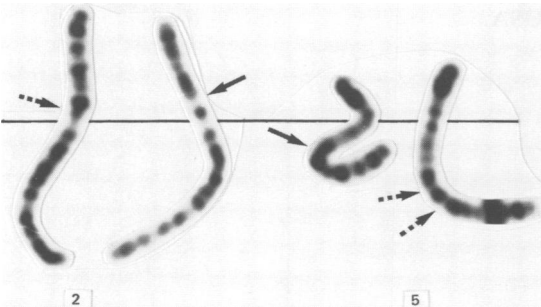


FIG 2 Partial karyotype showing the chromosome pairs 2 and 5. The translocated chromosomes are placed on the inside of each pair. Dotted arrows denote the presumed breakpoints and the solid arrows denote the actual reannealing points.

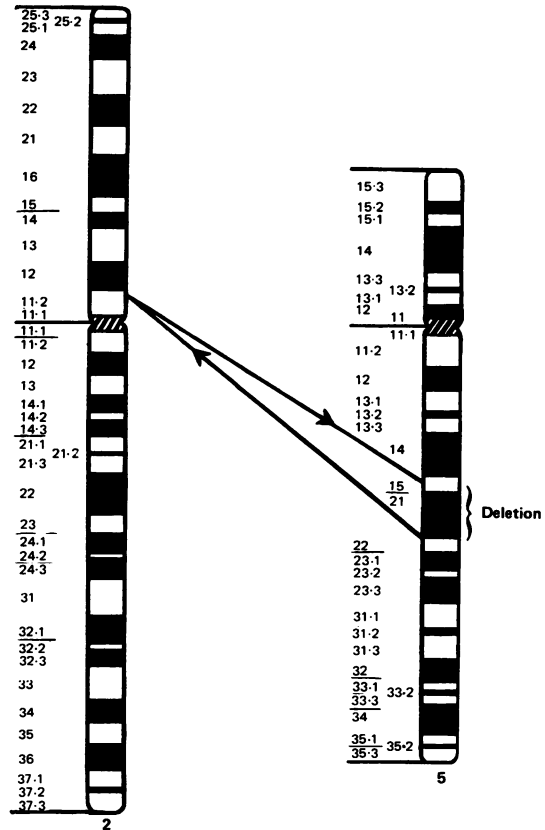


FIG 3 Diagrams of chromosomes 2 and 5 at the 550 band stage, according to ISCN 1985, showing the translocation sites and the deleted segment.

analysed. The presence of a translocation involving a 2p and a 5q was confirmed and the breakpoints appeared to be at band p11.2 on chromosome 2 and at bands q15 and q22 on chromosome 5 (figs 2 and 3) with the small segment consisting of band 5q21 missing. The missing band 5q21 did not appear to have merged with another band and there was no evidence for an insertion of band 5q21 into another chromosome. The karyotype of the child was interpreted as 46,XX,t(2;5)(5qter→q22::2p11.2→qter;5pter→q15::2p11.2→pter),del(5)(q15q22). The chromosomes of both parents were normal.

### Discussion

To our knowledge, at least 10 cases of interstitial deletion 5q have been previously published. Their breakpoints are within the segment 5q13→q31, which contains three G positive metaphase bands (q14, q21, and q23) of almost equal size. Owing to the similarity of these three positive bands, it is rather difficult to determine definitively which band(s) has been missing. Hence, it is also virtually impossible to delineate any meaningful karyotype-phenotype correlation from these previous cases.

The above difficulty might be resolved using high resolution chromosome preparations, as bands q14, q21, and q23 will show appreciably distinctive subband patterns, especially band q23 (ISCN 1985<sup>12</sup>). Our high resolution preparation was not quite optimal, as the q14 band and the q21 band remained undivided and were similar in size. However, in conjunction with the translocation, we confidently interpret the missing band in our patient as being band q21.

As in the other 10 cases, our patient had developmental delay and growth retardation. In contrast to the previously reported patients, the only major malformation was the unilateral coloboma of

the right eye. The question of whether a deletion in the 5q13→q31 segment could be associated with Gardner syndrome<sup>8</sup> will certainly remain unanswered until further confirmatory cases are reported.

### References

- 1 Van de Berghe H, Vermaelen K, Mecucci C, Barbieri D, Tricot G. The 5q- anomaly. *Cancer Genet Cytogenet* 1985;17:189-225.
- 2 Silengo MC, Luzzatti L, Centerwall WR, Costello JM, Parslow M. Interstitial deletion of the long arm of chromosome no 5 in two unrelated children with congenital anomalies and mental retardation. *Clin Genet* 1981;19:174-80.
- 3 Katano T, Murakami M, Kadotani T. Further cytogenetic studies on 105 cases from genetic counselling. *Proc Japan Acad* 1980;56:263-7.
- 4 Felding I, Kistoffersson U. A child with interstitial deletion of chromosome no 5. *Hereditas* 1980;93:337-9.
- 5 Stoll C, Levy JM, Roth MP. Interstitial deletion of the long arm of chromosome 5 in a deformed boy: 46,XY,del(5)(q13q15). *J Med Genet* 1980;17:486-7.
- 6 Pescia G, Gaide AC, Jillard E. Syndrome dysmorphique, débilite mentale et delétion interstitielle des bras longs d'un chromosome 5. *Ann Genet (Paris)* 1978;21:161-3.
- 7 Kucerova M, Polivkova Z. 46,XX,del(5)(pter to q15::q22 to qter). In: Borgaonkar OS, Lillard DR, eds. *Repository of chromosomal variants and anomalies in man*. Fifth listing. Denton, Texas: North Texas University, 1978: 56.
- 8 Herrera L, Kakati S, Gibas L, Pietrzak E, Sandberg AA. Gardner syndrome in a man with a interstitial deletion of 5q. *Am J Med Genet* 1986;25:473-6.
- 9 Harprecht-Beato W, Kaiser P, Steuber E, Reinhard W. Interstitial deletion in the long arm of chromosome no. 5. *Clin Genet* 1983;23:167-71.
- 10 Ohdo S, Madokoro H, Hayakawa K. Interstitial deletion of the long arm of chromosome 5: 46,XX,del(5)(q13q22). *J Med Genet* 1982;19:479.
- 11 Dutrillaux B, Viegas-Pequignot E. High resolution R- and G-banding on the same preparation. *Hum Genet* 1981;57:93-5.
- 12 ISCN (1985). An international system for human cytogenetic nomenclature. *Birth Defects* 1985;21:No. 1.

Correspondence and requests for reprints to Dr Jar-Fee Yung, Department of Pediatrics, University of Illinois, 840 S Wood Street, Chicago, Illinois 60612, USA.