

# HAIR BALLS IN CATS

## A normal nuisance or a sign that something is wrong?



Martha Cannon

### Just how limited is our knowledge?

Vomiting of hair balls (fur balls) is a common problem in domestic cats, to the extent that it is considered by many owners to be a normal feline behaviour that is not worthy of veterinary attention. Studies into this common phenomenon are lacking, but while many authors consider that elimination of hair balls can be a normal mechanism for the clearance of accumulated fur,<sup>1–4</sup> it must also be recognised that frequent elimination of hair balls is often an indication of excessive fur ingestion or of underlying gastrointestinal disease.<sup>1,4</sup>

There is a significant lack of published information regarding the

incidence and causes of hair balls in cats and regarding the efficacy of commonly used treatments and preventives. A search of peer-reviewed veterinary journals (using the search terms 'feline' and 'hair ball', 'fur ball' or 'trichobezoar') identified only one series of five cases<sup>5</sup> and 13 single case reports

published between 1946 and 2010.<sup>6–19</sup> There is also scant information regarding normal gastric processing of food and dietary fibre in the cat and no published information regarding gastric processing in cats that frequently produce hair balls.

Many owners believe that vomiting of hair balls is a normal feline behaviour that is not worthy of veterinary attention.

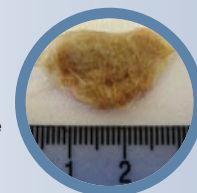
### Incidence of hair balls

We know from experience that hair balls are a common problem in pet cats and that longhaired cats tend to be affected more often than short-haired cats, but to the author's knowledge there are no published data to quantify this. An epidemiological survey of a large number of cats would be required to shed more light on this and was beyond the scope of this article. However, to produce a 'rough and ready' answer, two separate polls of cat owners were conducted in the author's cat-only veterinary clinic (see box on page 22).

**Practical relevance:** Vomiting of hair balls is a common problem in domestic cats, to the extent that it is considered by many owners and veterinarians to be a normal feline behaviour. Whether this is ever the case remains unclear but in most shorthaired cats the frequent elimination of hair balls is an indicator of an underlying chronic disease that is causing increased ingestion of fur or altered gastrointestinal motility. Pruritic skin disease, flea infestation and/or an underlying dietary intolerance are common contributing factors that should not be overlooked.

**Evidence base:** Studies concerning this common problem are lacking and there are no previously published data regarding the incidence of hair balls in pet cats or potential predisposing causes. Although a range of commercial hair ball control diets are available there is no objective information in the public domain regarding their efficacy. Similarly, no studies have evaluated the success of other commonly recommended preventive strategies.

**Clinical challenges:** Despite the lack of evidence-based information, veterinarians are faced with the day-to-day challenge of helping owners to limit the extent to which their cats produce hair balls. The problem is at best an unpleasant nuisance for both cat and owner, and at worst may be a cause of significant morbidity and even, in rare cases, mortality.



## Incidence of hair balls in longhaired and shorthaired cats

In order to gain an approximation of how common it is for domestic cats to bring up hair balls, two polls were conducted:

### POLL 1: Incidence of hair ball elimination in apparently healthy shorthaired cats

Veterinarians and veterinary nurses working in our first opinion cat-only veterinary clinic were asked to question owners of apparently healthy shorthaired cats about the incidence of hair ball vomiting in their cats. Cats with a known history of chronic skin or gastrointestinal disease were excluded from this poll.

Respondents reported that:

- ❖ 35/48 cats (73%) had never been known to bring up a hair ball
- ❖ 8/48 cats (17%) brought up a hair ball about once a year
- ❖ 5/48 cats (10%) brought up two or more hair balls per year

### POLL 2: Comparison of longhaired and shorthaired cats with regard to the frequency of hair ball elimination

To compare the frequency of hair ball elimination in longhaired and shorthaired cats, we needed to access a larger sample size in a reasonable time period. To this end we conducted an email poll of cat owners, accepting that this would not produce responses from an unbiased sample, but making an assumption that similar biases would apply to owners of shorthaired versus longhaired cats. Note that we asked owners only to provide information for cats that were healthy, with no history of chronic skin or gastrointestinal disease. However, this was based on the owners' opinions, with no veterinary involvement and no review of the cats' clinical records.

Respondents reported that:

- ❖ 37/87 shorthaired cats (43%) had never been known to bring up a hair ball, compared with 9/38 longhaired cats (24%)
- ❖ 27/87 shorthaired cats (31%) brought up only one hair ball per year, compared with 8/38 longhaired cats (21%)
- ❖ 23/87 shorthaired cats (26%) brought up more than two hair balls per year, compared with 21/38 longhaired cats (55%)

This survey suggested that frequent elimination of hair balls is twice as common in longhaired cats as in shorthaired cats.

Results of these two polls suggest that:

- ❖ There is an overall incidence of hair ball vomiting of around 10% in otherwise apparently healthy shorthaired cats.
- ❖ Frequent elimination of hair balls is around twice as common in longhaired cats as in shorthaired cats.



## Fur ingestion

Cats are fastidious in their grooming habits and, when living in groups, co-grooming is also an important social bonding behaviour. In a study in which five female cats were observed over a 360 h period, grooming

Time spent grooming accounts for around 25% of a cat's waking hours.


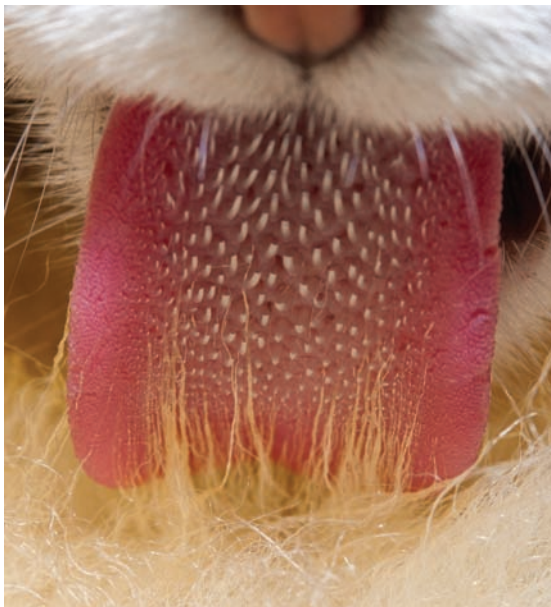


Figure 1 The barbs on a cat's tongue encourage ingestion of fur when grooming. Images courtesy of Marc C Perkins



**Figure 2** Large volume of undigested hair in the stool of a longhaired cat that was presented at the author's clinic for dematting

behaviour occupied an average of 3.6 h per day.<sup>20</sup> Since 9.6 h were spent sleeping, this meant that the time spent grooming accounted for around 25% of the cats' waking hours.

Given the amount of time devoted to grooming, and the barbed structure of the feline tongue (Figure 1), it is not surprising that cats ingest large amounts of fur every day, most of which passes through the gastrointestinal tract and is expelled as undigested hair within the faeces.<sup>20</sup> In the majority of cases the fur is passed in a normally formed stool with no unpleasant consequences for the cat. Where excessive amounts of fur are being ingested there may be a large volume of hair in the stool (Figure 2); in some cases this may cause inflammation of the colonic mucosa resulting in 'hair-related colitis' – a potential cause of innocent fresh blood in the rectum of an otherwise well cat (R Malik, personal communication, 2012).

## Is elimination of hair balls a normal physiological process?

Birds of prey regurgitate indigestible food matter as an essential part of the digestion process (see below) – so could elimination of hair balls in cats be an example of a similar physiological mechanism for dealing with fur swallowed during grooming? This seems unlikely, not least because if it were the case we would expect it to be a very common behaviour in domestic cats, wild cats and feral cats. With regards to domestic pets, the first of the aforementioned straw polls (see page 22) would suggest that only 10% of otherwise healthy shorthaired cats regularly bring up

hair balls. Evidence for the incidence in feral cats and wild cats is scant, but while hair balls do occasionally occur in these populations they appear to be an unusual phenomenon (see below).

So unlike birds of prey, which reliably regurgitate a pellet of indigestible food material after every meal, and indeed are unable to eat again until they have cleared the pellet, it is clear that the majority of cats, large and small, rarely if ever bring up a hair ball. This must cast doubt on the suggestion that elimination of hair balls is a normal physiological process.

### Birds of prey

The formation and egestion of pellets of indigestible material is a part of the normal digestive process of birds and is particularly well developed in raptors and owls.<sup>21</sup> The process is very different to that which is involved in a cat bringing up a hair ball.

As birds of prey cannot chew their food, small prey animals are swallowed whole and larger prey items are torn into smaller pieces before being swallowed. Digestion of food starts in the proventriculus (glandular stomach), while the ventriculus (muscular stomach, or gizzard) acts as a grinding chamber and as a filter, allowing softer and soluble elements to pass down the digestive tract but holding back larger insoluble elements of the diet. The indigestible matter (fur, feathers, bones, etc) is held in the ventriculus for 6–10 h, during which time it becomes consolidated into a pellet which must be ejected before the bird can eat again. The cycle of pellet ejection is regular and birds frequently return to a favourite roost site to perform this function. Just prior to the action of ejection the bird appears uncomfortable and is unwilling to fly but the actual process of ejection is not associated with any retching or any abdominal muscle contraction.<sup>22</sup>

### Feral cats

There is even less information available on feral cats and hair balls than there is for pet cats. Feral cats that depend solely on wildlife for food live secretive lives and avoid areas inhabited by humans; those colonies that are more closely observed tend to be supplement-fed by human caretakers and/or to supplement their diets by scavenging, thus introducing 'low quality' dietary factors which may significantly alter their gastrointestinal function.

In a study of a population of shorthaired cats living freely in Portsmouth Dockyard in the UK,<sup>23</sup> stomach contents were examined during the post-mortem examination of 14 cats that were found dead. Hair was observed in the stomachs of four cats (29%) but in only one case was the large amount of hair contained in the stomach found to be forming into hair balls. Twenty-three faecal samples were also analysed from this population of cats and all but one were found to contain hair, often in large quantities, suggesting that passage of fur through the intestinal tract was more common than retention in the stomach. Observation of this group of cats indicated that food put out for them was their most important food source and comprised wet and dry commercial cat food, raw fish, cooked meat and sausages.

### Zoo cats

Published data are lacking but, anecdotally at least, it does appear that hair balls rarely occur in zoo cat populations. Occasional reports of hair balls in large cat species crop up in the media<sup>24</sup> and elsewhere,<sup>25,26</sup> but in an informal survey of a number of veterinarians with responsibility for the care of both large and small wild cat species in UK zoos, all those that replied indicated that they had not been aware of any of the cats under their care ever vomiting a hair ball. Although these are captive populations, the wild cats in question are being fed raw meat and carcasses rather than commercially processed food.



## What causes hair balls?

All cats swallow large amounts of fur each day through normal grooming behaviour but most do not bring up hair balls on a regular basis, nor do they suffer any apparent discomfort as the indigestible hair passes through the gastrointestinal tract. Hair balls are thought to occur when there is either an excess of hair being ingested, or altered upper gastrointestinal motility.

### Excessive hair ingestion

In this scenario the capacity of the stomach to pass all the hair into the small intestine is presumably overwhelmed. Longhaired cats are more commonly affected than shorthaired cats but factors other than extended hair length may also lead to excessive hair ingestion. For example:

- ❖ Flea infestation is a common cause of increased grooming behaviour, resulting in increased hair ingestion in any cat and not limited to those with flea allergic dermatitis.
- ❖ Pruritic skin disease.
- ❖ Overgrooming due to pain and/or anxiety.

### Altered upper gastrointestinal motility

Chronic gastrointestinal disease or increased sympathetic nervous stimulation secondary to other factors such as chronic pain and/or stress can alter upper gastrointestinal motility.

- ❖ In the author's experience frequent vomiting of hair balls is a common feature in the clinical history of shorthaired cats suffering from chronic gastrointestinal disease (eg, due to a dietary intolerance or inflammatory bowel disease). Appropriate management of the primary gastrointestinal disease frequently results in significant reduction of hair ball vomiting.
- ❖ In pet rabbits, gastrointestinal stasis is a common problem that can result in large accumulations of fur and food forming in the stomach or caecum. This is most commonly associated with feeding a poor diet, especially one that is low in fibre and/or inappropriately high in carbohydrate or protein. Other factors such as chronic stress, pain, dehydration and obesity may also contribute to the gastrointestinal stasis.<sup>27</sup>

In shorthaired cats regular vomiting of hair balls may therefore be an indication of primary gastrointestinal disease, flea infestation or other skin disease but many owners will mistakenly believe it to be normal behaviour and will rarely bring the problem to the attention of their veterinarian.

**Owners should be questioned about hair ball elimination during history taking at routine visits, and as part of the initial assessment of cats presenting with gastrointestinal signs or occult weight loss.**



Owners should be questioned about hair ball elimination during history taking at routine visits and as part of the initial assessment of cats presenting with gastrointestinal signs or occult weight loss. In these cases a previous history of frequent hair ball elimination should alert the veterinarian to the potential for chronic gastrointestinal disease. This may be important when deciding whether or not to investigate the case further or to recommend long-term dietary modification, versus instituting short-term palliative treatment for what may initially appear to be an acute gastrointestinal upset.

### Consequences of hair balls

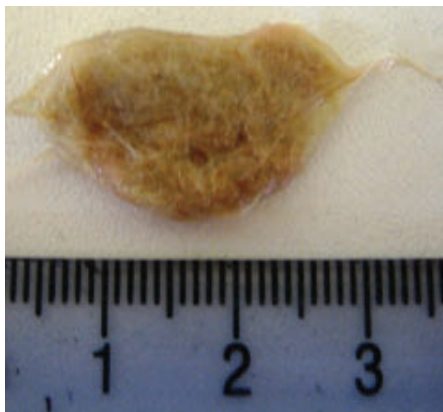
In the majority of cases a hair ball that forms in the stomach and reaches a size that is too large to pass into the duodenum is eventually eliminated by vomiting. Owners will frequently describe this action as 'coughing up' a hair ball, and further questioning is important to make the distinction between chronic coughing and frequent hair ball elimination.

Occasionally the hair ball cannot be ejected by vomiting and, although clinical experience tells us that this is rare, these are the cases that tend to be presented to the veterinarian for investigation and treatment – and indeed that make their way into the veterinary literature. Justly so, as a hair ball that is not eliminated by vomiting can cause significant morbidity and even potentially mortality by one of three routes:

- ❖ Passage into the small intestine where it may cause **partial or complete intestinal obstruction** leading to vomiting and abdominal discomfort. Physical examination is likely to reveal dilated loops of small intestine proximal to the obstruction and, if the hair ball is large enough, a palpable 'mass'. Since gastrointestinal masses in the cat are most commonly neoplastic the owner may be given an erroneously poor prognosis unless appropriate investigations are undertaken.<sup>4</sup>
- ❖ Entrapment in the oesophagus producing signs of **oesophageal obstruction** and

potentially leading to oesophagitis and oesophageal stricture. In the few published reports of oesophageal hair balls,<sup>7,8,10,13</sup> co-existing oesophageal disease is a frequent finding. In such cases it may be difficult to establish whether the hair ball caused oesophageal damage or whether it became entrapped because of pre-existing oesophageal disease. The latter possibility should be investigated once the oesophageal hair ball has been cleared.

❖ **Vomiting into the nasopharynx** (Figure 3) producing sudden-onset sneezing, retching and subsequent halitosis as well as nasal discharge.<sup>6</sup>



**Figure 3** A matt of fur retrieved from the nasopharynx of a cat that was presented at the author's clinic for investigation of acute-onset sneezing

Smaller hair balls may pass through the stomach and then cause partial intestinal obstruction, with associated discomfort, but may eventually be passed in the faeces resulting in complete resolution of clinical signs.<sup>9</sup>

Hair balls that are retained in the gastrointestinal tract for a prolonged length of time may become partly mineralised. These are generally larger and harder than 'normal' hair balls and therefore more difficult to pass, or to vomit. So, although much less common, when they do occur they are more frequently associated with severe clinical signs.

### Gastric processing of food and fur

It is suggested that the tendency of cats to form hair balls may be in part due to a relative lack of 'housekeeper contractions' sweeping through the stomach and proximal small intestine during periods of fasting.<sup>2</sup> In most species interdigestive migrating motor complexes (IMMCs) arise in the empty stomach and travel through the intestinal tract, facilitating the passage of indigestible material from stomach to colon. In cats, activity resembling IMMCs has only been identified in the distal small intestine.<sup>28</sup> Instead, studies of conscious fasting cats have identified the presence of migrating spike complexes (MSCs), which travel caudally through the distal bowel at a rate of approximately 1 mm/s and are associated with intense prolonged contraction of the local bowel.<sup>29</sup> MSCs have been proposed to be the functional equivalent of IMMCs in the cat but again were found to be infrequent in the duodenum and absent from the gastric antrum.<sup>30</sup> This apparent lack of 'housekeeper contractions' arising from the

stomach in the interdigestive period may lead to relatively poor gastric peristalsis when the stomach is empty, although this has not been demonstrated in vivo. Indeed, a study of the rate of gastric clearance of barium-impregnated polyspheres (BIPS) found that gastric emptying time was more rapid in fasted cats than in fed cats.<sup>31</sup>

Gastric emptying following feeding comprises an initial liquid phase followed by a slower solid phase, the latter being of relevance to clearance of food and fur from the stomach. The rate of emptying of ingesta from the stomach appears to be similar in cats and dogs,<sup>32</sup> and is highly variable and also dependent on the type of food fed.

Solid-phase gastric emptying time in conscious cats measured radiographically has been variously reported to be  $11.6 \pm 0.9$  h,<sup>33</sup> and from 4 h for cats fed high moisture foods to 14–16 h for cats fed on dry food.<sup>32</sup> Scintigraphic methods have also been used to monitor the rate of gastric emptying of solid food in normal cats: in a study using dry food the mean gastric emptying half-time was found to be  $2.47 \pm 0.71$  h,<sup>34</sup> and a study comparing dry food with canned food confirmed that gastric emptying time was significantly longer for dry food than for canned food, and was longer if the meal size was larger.<sup>35</sup>

The effect of dietary fibre on gastric emptying has been assessed in one feline study,<sup>36</sup> which showed similar times taken to empty the stomach to 50% and 20% of initial filling irrespective of whether the diet was high in fibre or low in fibre. However, kibble shape was found to be relevant in that triangular kibbles were significantly slower to clear from the stomach than round kibbles despite there being no correlation between the surface area of the food and the gastric emptying time. This study also found that larger meal size was associated with slower gastric emptying, in agreement with the findings of Goggin et al.<sup>35</sup> However, there were conflicting findings with regards to the effect of water intake: Goggin's study found that water intake had a significant effect on gastric emptying time, while Armbrust et al found no significant effect of water intake on gastric emptying.<sup>36</sup> Finally, gastric emptying rate does not appear to alter with increasing age.<sup>37</sup>



**Frequent elimination of hair balls is an indication of excessive fur ingestion or of underlying gastrointestinal abnormality.**

## Diet and hairballs

A cat's diet may, in the light of the above, have a significant bearing on the frequency with which hair balls form in the stomach.

### Diet-responsive gastrointestinal disease

Diet-responsive chronic gastrointestinal disease is common in the pet cat population and affected cats may present with vomiting, nausea (eg, frequent ingestion of grass to stimulate vomiting) and/or diarrhoea. In some cases weight loss will be the only clinical sign and this may be associated with either increased or decreased appetite.

Frequent vomiting of hair balls may be one of the manifestations of diet-responsive gastrointestinal disease and feeding an appropriate exclusion diet may resolve the underlying problem and in doing so eliminate the tendency to vomit hair balls.

### Hair ball control diets

Where underlying gastrointestinal disease is not a contributory factor, other dietary approaches to management may be helpful. Commercial diets formulated to reduce the incidence of hair balls contain increased levels of insoluble fibre with the aim of improving gastric motility and gastric emptying. There are no published studies that directly demonstrate this correlation in conscious cats, but a 2-week study into the use of a palatable chew containing psyllium (a source of soluble fibre) and slippery elm (used in herbal medicine as an emollient, expectorant and diuretic) reported a 29% reduction in clinical signs associated with hair balls (coughing, retching and vomiting), although there was no significant reduction in actual vomiting.<sup>38</sup>

Hair ball control diets may also employ an increased kibble size because 'radiographic gastrointestinal transit studies indicate that a larger kibble size is associated with an increased tendency for hairballs to exit the stomach and be passed in the faeces'.<sup>39</sup> However, the studies to which this statement refers are not within the public domain.

Published data regarding the efficacy of hair ball control diets are lacking, but the experience of cat owners feeding hair ball control diets, manufactured by a number of different nutrition companies, would seem to support a degree of efficacy for these products. Client surveys undertaken by Hill's Pet Nutrition during the development of their adult feline hair ball control diet supported a claim that the diet helped to avoid the formation of

**Hair balls are more common in longhaired cats than in shorthaired cats, presumably due to the artificially increased length of the fur.**



hair balls (C Rushton, personal communication, 2012), but these unpublished surveys are uncontrolled and have not been subject to peer review, so further work is needed in this area.

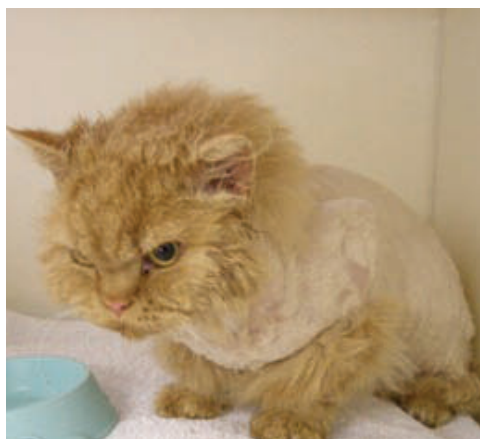### 'Natural diets'

Proponents of the feeding of raw carnivorous diets and diets based on meat on the bone contend that this also has a significant effect in reducing the incidence of hair balls, as well as promoting dental and skin health, among other benefits. Published data are again lacking and currently the debate rages as to which nutritional approach is best – premium quality commercial diets versus 'natural' raw meat and bone diets. No doubt readers will have their own opinions, and until controlled studies are undertaken we can only rely on anecdotal reports from both camps.

### Other preventive strategies

For cats that regularly or intermittently suffer with hair balls preventive treatment is indicated. Consideration of the possible presence of underlying disease is the initial priority and dietary manipulation may also be an effective means of control, as previously discussed; whether one advocates the use of commercial hair ball control diets or the feeding of raw meat on the bone will, for the time being, depend on personal preference. Beyond this, a number of other approaches can also be adopted and, as ever in this field, in the absence of any studies there is currently no evidence base to support one approach over another.

**Figure 4** A Selkirk Rex cat with a 'lion clip', which may help to reduce the incidence of hair balls



### Reducing the ingestion of loose hair

Hair balls are more common in longhaired cats than in shorthaired cats, presumably due to the artificially increased length of the fur. Daily grooming to remove as much loose hair as possible may help to reduce the amount of excess hair being ingested. In severe cases, clipping the coat ('lion clipping', Figure 4) may also help by shortening the fur to a length more akin to that which the gastrointestinal tract has evolved to handle.



### Encouraging efficient gastric emptying

Physiological studies suggest that cats have limited 'housekeeper contractions' helping to sweep indigestible material from the stomach.<sup>28–30</sup> Furthermore, gastric emptying appears to be quicker when the stomach is handling small meals rather than large meals.<sup>35,36</sup> This combination of factors has led to the advice that more frequent feeding of small meals throughout the day may improve upper gastrointestinal motility, which may in turn help to reduce the incidence of hair balls.

### Gastric lubricants

Daily use of inert oils (eg, liquid paraffin) or flavoured paraffin wax pastes can provide a lubricant effect that helps to move strands of fur from the stomach into the duodenum, from where they will be processed into the faeces rather than condensing into a hair ball.

As liquid paraffin is relatively tasteless and odourless it can be safely dosed to most cats when mixed with food. Owners should be advised not to attempt to syringe liquid paraffin into their cat's mouth, as accidental inhalation can lead to severe lipid-induced pneumonia. In humans, this is recognised as a significant issue, especially in paediatric medicine, but also as an occupational hazard for fire eaters<sup>40</sup> and even as a consequence of the over-enthusiastic use of lip gloss.<sup>41</sup> How commonly exogenous lipid pneumonia occurs in cats is unclear – there are no published case reports describing the problem but nonetheless we know it to be an entirely avoidable hazard that can have serious consequences (Figure 5).

Concerns have also been raised that the addition of inert oils to the food may reduce the availability of fat-soluble vitamins. Studies in human patients on long-term treatment with liquid paraffin do not show any clinically significant effects in this regard;<sup>42</sup> nevertheless, where flavoured paraffin waxes or liquid paraffin are given long term on a daily basis, it may be prudent to ensure that at least one meal per day is left unadulterated.

### Medical management

The use of lifelong medication to reduce the incidence of hair balls should not be necessary. Before resorting to such measures a diligent search for any underlying disease must be undertaken, and dietary manipulation, use of gastric lubricants and clipping of long-haired cats should be employed.

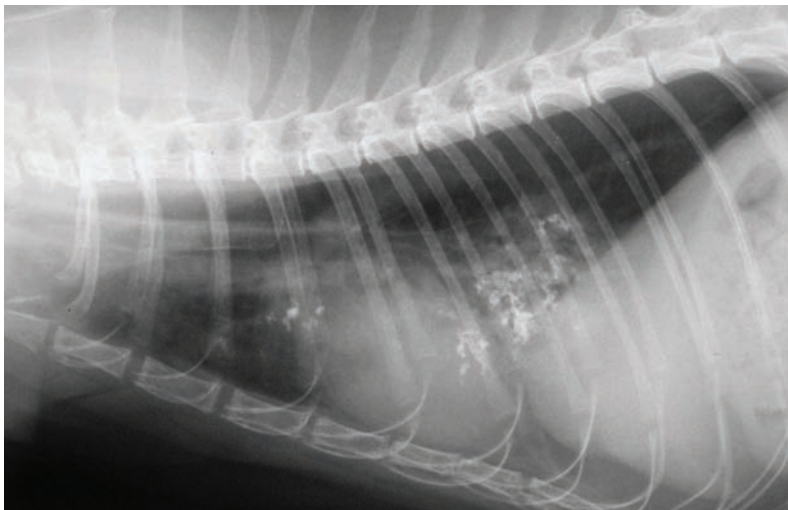
Medications that may promote more effective gastric emptying in cats include metoclopramide, cisapride and ranitidine.

- ❖ **Metoclopramide** (0.2–0.4 mg/kg q6h PO)<sup>43</sup> has a prokinetic effect on the stomach in cats, resulting in increased antral contractility.<sup>44</sup> Its practical utility as a long-term preventive treatment may be limited by its short half-life, requiring oral dosing q6h to maintain effect. Less frequent dosing may be effective in some cases.
- ❖ **Cisapride** (1.5 mg/kg q12h PO)<sup>43</sup> is not licensed for use in the cat but is an effective prokinetic agent in this species, with effect at all levels of the gastrointestinal tract from lower oesophageal sphincter through to colon. In dogs, it has been shown to be a more



Use of long-term medication to promote gastric emptying should not be necessary.

Owners should be advised not to dose liquid paraffin by syringe, as accidental inhalation can lead to severe lipid-induced pneumonia.



**Figure 5** Radiograph showing long-term damage to the lungs caused by inhalation of liquid paraffin. Courtesy of Gawain Hammond, University of Glasgow

effective gastric prokinetic than metoclopramide.<sup>45</sup> Cisapride has been withdrawn from the human market due to the potential for QT prolongation and ventricular arrhythmias at high plasma concentrations. In cats it appears to be well tolerated although QT prolongation and ST depression were induced when it was given at very high doses (30 mg/kg q12h for 7 days).<sup>46</sup> In the UK, availability of cisapride has been a problem but it can currently be sourced from compounding pharmacies and from Summit Veterinary Pharmacy.

- ❖ **Ranitidine** (3.5 mg/kg q12h PO)<sup>43</sup> is also not licensed for use in the cat but this H<sub>2</sub>-antagonist likewise appears to have prokinetic effect throughout the gastrointestinal tract in cats.<sup>43</sup> Its inherently bitter taste makes dosing of both liquid and tablet formulations difficult but compliance may be improved by disguising the tablet form of the drug in a gelatin capsule prior to dosing (Figure 6).



**Figure 6** Fragment of a ranitidine tablet (Zantac; Boehringer Ingelheim) masked inside a size 4 gelatin capsule to improve compliance

## KEY POINTS

- ❖ Vomiting of hair balls is common in domestic cats and is often an indication of excessive fur ingestion or of altered gastrointestinal motility.
- ❖ Owner surveys conducted in the author's practice suggest that around 10% of otherwise healthy shorthaired cats regularly bring up hair balls (two or more per year) and that the incidence in longhaired cats is around twice that in shorthaired cats.
- ❖ Diet-responsive gastrointestinal disease is a common cause of hair ball vomiting in otherwise healthy shorthaired cats.
- ❖ Preventive treatment is indicated where an underlying cause cannot be identified or eliminated.

## Funding

The author received no specific grant from any funding agency in the public, commercial or not-for-profit sectors for the preparation of this review article.

## Conflict of interest

The author does not have any potential conflicts of interest to declare.

## References

- Crystal MA. **Trichobezoars**. In: Norsworthy GD, Crystal MA, Grace SF and Tilley LP (eds). *The feline patient*. 3rd ed. Iowa: Blackwell, 2006, pp 314–315.
- Twedt DC. **Diseases of the stomach**. In: Sherding RG (ed). *The cat: diseases and clinical management*. 2nd ed. New York: Churchill Livingstone, 1994, p 1194.
- Wilkinson GT. *Diseases of the cat and their management*. Melbourne: Blackwell Scientific, 1984, p 32.
- Zoran DL. **The cat with signs of acute vomiting**. In: Rand J (ed). *Problem-based feline medicine*. 1st ed. Oxford: Elsevier Saunders, 2006, p 635.
- Barrs VR, Beatty JA, Tisdall PLC, Hunt GB, Gunew M, Nicoll RG, et al. **Intestinal obstruction by trichobezoars in five cats**. *J Feline Med Surg* 1999; 1: 199–207.
- Haynes KJ, Anderson SE and Laszlo MP. **Nasopharyngeal trichobezoar foreign body in**

**a cat**. *J Feline Med Surg* 2010; 12: 878–881.

- Durocher L, Johnson SE and Green E. **Esophageal diverticulum associated with a trichobezoar in a cat**. *J Am Anim Hosp Assoc* 2009; 45: 142–146.
- Owen MC, Morris PJ and Bateman RS. **Concurrent gastro-oesophageal intussusception, trichobezoar and hiatal hernia in a cat**. *N Z Vet J* 2005; 53: 371–374.
- Malik R. **Sequelae of trichobezoars (hair balls) passing through the intestinal tract**. *J Feline Med Surg* 2003; 5: 357–358.
- Agnello KA and Kantrowitz L. **What is your diagnosis? Esophageal obstruction**. *J Am Vet Med Assoc* 2003; 223: 1115–1116.
- Gardner CH, Hicks SL, Puette JR and Bunch SE. **What is your diagnosis? Intestinal adenocarcinoma**. *J Am Vet Med Assoc* 2003; 223: 783–784.
- Court EA, Cole C, Allan GS and Malik R. **An unusual esophageal foreign body in a cat**. *Aust Vet Pract* 1994; 24: 198–202.
- Hurov L. **What is your diagnosis? Esophageal foreign body**. *J Am Vet Med Assoc* 1985; 187: 749–750.
- Wilkes RD, Wolfe DA, Barrett RB and Edwards NJ. **What is your diagnosis? 1) Intraluminal gastric foreign body, pericardial diaphragmatic hernia, and abnormal intestinal gas patterns. 2) Bone cyst or abscess, involving the proximal right humeral metaphysis**. *J Am Vet Med Assoc* 1981; 178: 1297–1300.
- Worwood LE and Jones RM. **Recurrent fur ball in a cat**. *Vet Rec* 1979; 104: 222.
- Ryan CP and Wolfer JJ. **Recurrent trichophytobezoar in a cat**. *Vet Med Small Anim Clin* 1978; 73: 891–893.



- 17 van Nes JJ, Wolvekamp WT and Goedegebuure SA. **What is your diagnosis?** [German]. *Tijdschr Diergeneeskde* 1975; 100: 334–336.
- 18 Frye FL. **Hiatal diaphragmatic hernia and tricholithiasis in a Golden Cat (a case history).** *Vet Med Small Anim Clin* 1972; 67: 391–392.
- 19 Campbell DR and Geffen LR. **Impaction of the stomach in a cat.** *Vet Rec* 1946; 58: 456.
- 20 Panaman R. **Behavior and ecology of free-ranging farm cats (*Felis catus* L).** *Z Tierpsychol* 1981; 56: 59–73.
- 21 Houston DC and Duke GE. **Physiology; gastrointestinal.** In: Bird DM and Bilstein KL (eds). *Raptor research and management techniques*. 2nd ed. Blaine, Hancock House Publishers, 2007, pp 267–277. [http://raptors.hancockwildlife.org/filemgmt\\_data/files/RRMT-Ch16A.pdf](http://raptors.hancockwildlife.org/filemgmt_data/files/RRMT-Ch16A.pdf)
- 22 Duke GE, Evanson OA, Redig PT and Rhoades DD. **Mechanism of pellet egestion in great-horned owls (*Bubo virginianus*).** *Am J Physiol* 1976; 231: 1824–1829.
- 23 Dards JL. **Habitat utilisation by feral cats in Portsmouth Dockyard.** In: The ecology and control of feral cats. Proceedings of a symposium held at Royal Holloway College, University of London; 1980 Sept 23–24: London, UK. <http://www.feralcats.org.uk/pubs.html>
- 24 <http://www.telegraph.co.uk/earth/wildlife/5118300/Surgery-for-lion-with-deadly-hairball.html>
- 25 Seidel B and Wisser J. **Clinical diseases of captive tigers – European literature.** In: Tilson RL and Seal US (eds). *Tigers of the world – the biology, biopolitics, management and conservation of an endangered species*. Park Ridge: Noyes Publications, 1987, p 216.
- 26 <http://www.youtube.com/watch?v=3f0aTEzhnBk&feature=related>
- 27 Saunders RA and Rees Davies R. **Gastrointestinal stasis.** In: Saunders RA and Rees Davies R (eds). *Notes on rabbit internal medicine*. Oxford: Blackwell, 2005, pp 31–35.
- 28 Roche M, Bueno L, Vagne M and Blourde C. **Patterns of electrical activity in the digestive tract of the conscious cat.** *Br J Nutr* 1982; 48: 129–135.
- 29 De Vos WC. **Migrating spike complex in the small intestine of the fasting cat.** *Am J Physiol* 1993; 265: G619–G627.
- 30 Bortoff A, Sillin LF and Sterns A. **Chronic electrical activity of cat intestine.** *Am J Physiol* 1984; 246: G335–G341.
- 31 Chandler ML, Guilford G and Lawoko CR. **Radiopaque markers to evaluate gastric emptying and small intestinal transit time in healthy cats.** *J Vet Intern Med* 1997; 11: 361–364.
- 32 Arnbjerg J. **Gastric emptying time in the dog and cat.** *J Am Anim Hosp Assoc* 1992; 28: 77–81.
- 33 Steyn PF and Twedt DC. **Gastric emptying in the normal cat: a radiographic study.** *J Am Anim Hosp Assoc* 1994; 30: 78–80.
- 34 Steyn PF, Twedt DC and Toombs W. **The scintigraphic evaluation of solid phase gastric emptying in normal cats.** *Vet Radiol Ultrasound* 1995; 36: 327–331.
- 35 Goggin JM, Hoskinson JJ, Butine MD, Foster LA and Myers NC. **Scintigraphic assessment of gastric emptying of canned and dry diets in healthy cats.** *Am J Vet Res* 1998; 59: 388–392.
- 36 Armbrust LJ, Hoskinson JJ, Lora-Michiels M and Milliken GA. **Gastric emptying in cats using foods varying in fibre content and kibble shapes.** *Vet Radiol Ultrasound* 2003; 44: 339–343.
- 37 Peachey SE, Dawson JM and Harper EJ. **Gastrointestinal transit times in young and old cats.** *Comp Biochem Physiol A Mol Integr Physiol* 2000; 126: 85–90.
- 38 Dann JR, Adler MA, Duffy KL and Giffard CJ. **A potential nutritional prophylactic for the reduction of feline hairball symptoms.** *J Nutr* 2004; 134: 2124S–2125S.
- 39 Hand MS, Zicker SC and Novotny BJ. *Small animal clinical nutrition – quick consult*. Topeka: Mark Morris Institute, 2011, p 259.
- 40 Beermann B, Christensson T, Moller P and Stillstrom A. **Lipid pneumonia: an occupational hazard of fire eaters.** *BMJ* 1984; 289: 1728–1729.
- 41 Becton DL, Lowe JE and Falletta JM. **Lipoid pneumonia in an adolescent girl secondary to use of lip gloss.** *J Pediatr* 1984; 105: 421–423.
- 42 Sharif F, Crushell E, O'Driscoll K and Bourke B. **Liquid paraffin: a reappraisal of its role in the treatment of constipation.** *Arch Dis Child* 2001; 85: 121–124.
- 43 Trepanier L. **Acute vomiting in cats: rational treatment selection.** *J Feline Med Surg* 2010; 12: 225–230.
- 44 Mangel AW, Stavorski JR and Pendleton RG. **Effects of bethanechol, metoclopramide, and domperidone on antral contractions in cats and dogs.** *Digestion* 1983; 28: 205–209.
- 45 Gullikson GW, Loeffler RF and Viriña MA. **Relationship of serotonin-3 receptor antagonist activity to gastric emptying and motor-stimulating actions of prokinetic drugs in dogs.** *J Pharmacol Exp Ther* 1991; 258: 103–110.
- 46 Kii Y, Nakatsuji K, Nose I, Yabuuchi M, Mizuki Y and Ito T. **Effects of 5-HT(4) receptor agonists, cisapride and mosapride citrate on electrocardiogram in anaesthetized rats and guinea-pigs and conscious cats.** *Pharmacol Toxicol* 2001; 89: 96–103.

Available online at [jfms.com](http://jfms.com)

Reprints and permission: [sagepub.co.uk/journalsPermissions.nav](http://sagepub.co.uk/journalsPermissions.nav)