

- <sup>9</sup> Touraine JL, Revillard JP, Traeger J. Biologie de l'infection listérienne, influence de l'immunodépression. *Nouv Presse Méd* 1972;1:2827-32.
- <sup>10</sup> Tripathy SP, Mackness GB. The effect of cytotoxic agents on the primary immune response to *Listeria monocytogenes*. *J Exp Med* 1969;130:1-16.
- <sup>11</sup> Johnson ML, Colley EW. *Listeria monocytogenes* encephalitis associated with corticosteroid therapy. *J Clin Path* 1969;22:465-9.
- <sup>12</sup> Chernik NL, Armstrong D, Posner JB. Central nervous system infections in patients with cancer. *Medicine* 1973;52:563-81.
- <sup>13</sup> Niklasson PM, Hambraens A, Lundgren G, Magnussen G, Sundelin P, Groth CG. *Listeria* encephalitis in five renal transplant recipients. *Acta Med Scand* 1978;203:181-5.
- <sup>14</sup> Britt RH, Enzmann DR, Remington JS. Intracranial infection in cardiac transplant recipients. *Ann Neurol* 1981;9:107-19.
- <sup>15</sup> Berg B, Franklin G, Cuneo R, Boldrey E, Strimling B. Non surgical cure of brain abscess: early diagnosis and follow-up with computerized tomography. *Ann Neurol* 1978;3:474-8.
- <sup>16</sup> Whelan MA, Hilal SK. Computed tomography as a guide in the diagnosis and follow-up of brain abscesses. *Radiology* 1980;135:663-71.
- <sup>17</sup> Law JD, Lehmann RAW, Kirsch WM, Ehni G. Diagnosis and treatment of abscess of the central ganglia. *J Neurosurg* 1976;44:226-32.
- <sup>18</sup> Meran JC, Naidich TP, Gado MH, Marchowsky JA. Central nervous system lesions biopsied or treated by CT-guided needle placement. *Radiology* 1979;131:681-6.

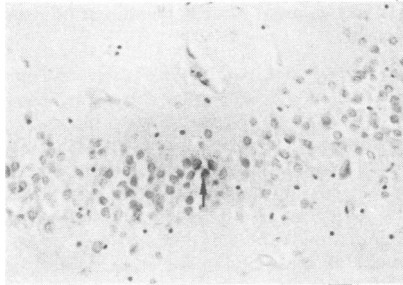


Figure Section of hippocampus from a patient with Alzheimer's disease treated with anti herpes simplex virus serum. There is a focus of three granule cells in the dentate fascia which contain antigen in the cytoplasm (arrow). Counterstained with haematoxylin  $\times 140$ .

cases of herpes simplex encephalitis using the immunoperoxidase technique my attention was drawn to a particularly heavy involvement of the granule cells of the dentate fascia of the hippocampus.<sup>2</sup> I therefore examined this layer of cells in a series of control cases among which were cases of Alzheimer's disease. Sections were taken from a block from approximately the mid point of one hippocampus from 12 patients with clinical and pathological features of Alzheimer's disease, and a small focus of positive staining for herpes simplex virus was found, involving three contiguous cells within the granule cell layer of the dentate fascia (fig). The positive staining was present in the cytoplasm and not in the nuclei of these cells. Staining of an adjacent section with antibody preabsorbed with herpes simplex virus gave negative results, but this could conceivably have been due to absence of the same cells within this section. Other cases of Alzheimer's disease and all the other control cases examined gave negative results. This observation, taken together with other preliminary observations such as that of Mann *et al*, the report of Nagington *et al*<sup>3</sup> of a case of herpes simplex encephalitis from which herpes simplex virus was only isolated after temporal lobe tissue had been co-cultivated for 18 days (suggesting the presence of latent infection), and the finding of herpes simplex virus genome in brain tissue from some patients with Alzheimer's disease,<sup>4</sup> multiple sclerosis and normal subjects,<sup>5</sup> warrants further investigation. My own observations on the distribution of herpes simplex virus within the brain in herpes simplex encephalitis suggested that the infection had arisen within one cerebral

hemisphere, possibly at a site related to the central connections of the olfactory system.

A possible hypothesis consistent with these observations is that herpes simplex virus produces a latent (or at least incomplete) infection of the olfactory bulbs, of more central connections of the olfactory tracts, or of the granule cells of the dentate fascia of the hippocampus (where the unusually close proximity of the neuron cell bodies may play a role). At this site, in the majority of those infected no pathological consequences ensue except that in later life the metabolism of neurons closely connected with these cells is altered and neurofibrillary tangles develop. On very rare occasions in persons with such an infection, perhaps triggered by some unidentified event, whole virus is again produced and overt infection results with development of acute encephalitis. Also rarely in the presenile age group, but more commonly in the senile age group, the latent infection generates metabolic alterations leading to neurofibrillary tangle formation not only in the hippocampus, but in a more widespread distribution in the neocortex, giving rise to Alzheimer's disease.

MARGARET M ESIRI  
Department of Neuropathology  
The Radcliffe Infirmary  
Oxford OX2 6HE

#### References

- Mann DMA, Yates PO, Davies JS, Hawkes J. Viruses, Parkinsonism and Alzheimer's disease. *J Neurol Neurosurg Psychiatry* 1981;44:651.
- Esiri MM. Herpes simplex encephalitis: an immunohistological study of the distribution of viral antigen within the brain. *J Neurol Sci*. In Press, 1982.
- Nagington J, Rubinstein D, Anderson J. Herpes simplex encephalitis. *Lancet* 1976;1:493.
- Sequiera LW, Carrasco LH, Curry A, Jannings LC, Lord MA, Sutton RNP. Detection of herpes simplex viral genome in brain tissue. *Lancet* 1979;2:609-12.
- Fraser NW, Lawrence WC, Wroblewska Z, Gilden DH, Koprowski H. Herpes simplex type 1 DNA in human brain tissue. *Proc Natl Acad Sci USA* 1981;78:6461-5.

#### Mann *et al* reply:

In response to Dr Esiri's letter we illustrate (figure) the area of positive immunoperoxidase reaction product, described in our earlier letter,<sup>1</sup> in the case of a 59-year-old woman with Alzheimer's

## Matters arising

### Viruses and Alzheimer's disease

Sir: I was interested in the letter from Drs Mann *et al*<sup>1</sup> describing the results of their search for herpes simplex virus antigen in samples of brain from cases of Alzheimer's disease and Parkinson's disease. Although they place more emphasis on the negative results in 40 cases, I found their positive result in the biopsy specimen from one case of Alzheimer's disease of considerable interest. Disappointingly they do not illustrate their positive staining and they do not state whether prior absorption of antibody with the virus abolished staining on an adjacent section.

In the course of a study on the distribution of herpes simplex virus antigen in