

Segmental cutaneous leukocytoclastic vasculitis associated with herpes zoster: a case report and literature review

Keiko Furuoka,^{1,2} Takeshi Fukumoto,¹ Yoshiyuki Masuda,² Ayano Tanigawa,² Hiroshi Kosaka,² Tohru Nagano²

¹Division of Dermatology, Department of Internal Related, Kobe University Graduate School of Medicine; ²Kobe City Medical Center General Hospital, Japan

Abstract

Varicella zoster virus (VZV) infection may cause large or medium vessel vasculitis, including granulomatous arteritis of the nervous system and central nervous system vasculitis. However, small vessel vasculitis, such as cutaneous leukocytoclastic vasculitis (LCV) associated with localized cutaneous VZV infection, herpes zoster, is uncommon. Herein, we present the case of a 75-year-old man with segmental leukocytoclastic vasculitis associated with herpes zoster on the leg. To the best of our knowledge, there are four cases of segmental leukocytoclastic vasculitis in herpes zoster reported in the English literature; we compared our case with these previous reports. Our review of five patients suggests that most patients were immunosuppressed. We also found that the leg is susceptible to LCV associated with herpes zoster. Anti-viral treatment was effective for LCV as well as herpes zoster. Prior reports have proposed etiologies inducing LCV; for example, immune complexes are mediated by vessel wall damage.

In support of this, histopathology in our case showed a C3-positive reaction with the small vessel walls in the dermis in direct immunofluorescence. Although the mechanism of LCV associated with herpes zoster remains unclear, we should consider LCV while diagnosing and treating patients with herpes zoster, especially immunosuppressed patients.

Introduction

Varicella zoster virus (VZV) infection may cause large or medium vessel vasculitis including granulomatous arteritis of the nervous system and central nervous system vasculitis.¹⁻³ However, small vessel vasculitis such as cutaneous leukocytoclastic vasculitis (LCV) associated with localized cutaneous VZV infection, herpes zoster, is uncommon.^{1,2} Herein, we present a rare case of segmental leukocytoclastic vasculitis associated with herpes zoster of the leg. To the best of our knowledge, there are four reports of segmental leukocytoclastic vasculitis in patients with herpes zoster in the English literature; we compared our case with these previous cases.

Correspondence: Takeshi Fukumoto, Division of Dermatology, Department of Internal Related, Kobe University Graduate School of Medicine, 7-5-1 Kusunoki-cho, Chuo-ku, Kobe 650-0017, Japan. Tel.: +81-78-382-6134. E-mail: fuku@med.kobe-u.ac.jp

Key words: herpes zoster, Varicella zoster virus, leukocytoclastic vasculitis, immunosuppression, amenamevir.

Contributions: the authors contributed equally.

Conflict of interest: the authors declare no conflict of interest.

Availability of data and materials: data and materials are available by the authors.

Received: 9 March 2023.
Accepted: 3 April 2023.
Early view: 19 May 2023.

This work is licensed under a Creative Commons Attribution-NonCommercial 4.0 International License (CC BY-NC 4.0).

©Copyright: the Author(s), 2023
Licensee PAGEPress, Italy
Dermatology Reports 2023; 15:9709
doi:10.4081/dr.2023.9709

Publisher's note: all claims expressed in this article are solely those of the authors and do not necessarily represent those of their affiliated organizations, or those of the publisher, the editors and the reviewers. Any product that may be evaluated in this article or claim that may be made by its manufacturer is not guaranteed or endorsed by the publisher.

Case Report

A 75-year-old man presented with painful purpura and blisters on his right lower leg. He had a history of focal glomerulosclerosis, hypertension, steroid-induced diabetes, and myocardial infarction. He had been taking prednisone 20 mg and cyclosporine 75 mg once daily for focal glomerulosclerosis. He had pain in his leg two weeks previously without any skin lesions. The pain in his leg worsened, and palpable purpura and some blisters appeared in a linear distribution on his lower right leg (Figure 1a). A skin biopsy of his lower right leg was performed, which revealed intraepidermal bulla with ballooning degeneration and acantholysis, and perivascular dense infiltration of neutrophils accompanied by some leukocytoclasia and hemorrhage in the dermis that was consistent with leukocytoclastic vasculitis and viral infection (Figure 1b and c). Direct immunofluorescence demonstrated a C3-positive reaction with small vessel walls in the dermis (Figure 1d). Leukocytoclastic vasculitis associated with herpes zoster was confirmed, and the patient was treated with a one-week course of amenamevir, following which the purpura resolved and all blisters scabbed over.

Discussion and Conclusions

Herpes zoster is caused by reactivation of VZV, which is latent in ganglionic neurons along the entire neuraxis. Immunosuppression is a risk factor for VZV reactivation.^{2,4} VZV infection in immunosuppressed patients can have atypical manifestations, such as painless lesions, absence of vesicles, erythematous lesions, and vasculitis.¹⁻⁴ To the best of our knowledge, four

Table 1. Clinical findings of published cases and the present patient.

	Case 1	Case 2	Case 3	Case 4	Case 5
Author	Wollina <i>et al.</i> ¹	Clark <i>et al.</i> ²	Burgard <i>et al.</i> ⁴	Erhard <i>et al.</i> ³	Present patient
Age	58	66	72	62	75
Sex	Man	Man	Man	Man	Man
Underlying diseases	Pulmonary sarcoidosis stage ■ / ■	Multisystem sarcoidosis	Immunocompetent	Mycosis fungoides	Focal glomerulosclerosis
Medication	Prednisolon (7.5 mg/day)	Prednisolone and methotrexate	NA	Methotrexate (17.5 mg/day)	Prednisolone (20 mg/day) and cyclosporin (75 mg/day)
Physical findings	Severe pain and palpable purpura	Ulcerations	Orange-red colored patchy lesions	Erythematous nodules and necrotic plaques with ulcerations	Palpable purpura and blisters
Anatomical location	Leg	Leg	Leg	Cheek and chin	Leg
Findings of biopsy	Intraepidermal acantholytic vesicle with ballooning cell combined with lymphomonocytic perivascular infiltrate and leukocytoclasia	Perivascular inflammatory infiltrate, leukocytoclasia, focal fibrin exudation and thrombosis of small blood vessels	Leukocytoclastic small vessel vasculitis (no findings corresponding to herpes zoster)	Dermal necrosis surrounded by a perivascular lymphohistiocytic infiltrate, obliterative vasculitis	Intraepidermal bulla, acantholysis and perivascular infiltration of neutrophils accompanied by leukocytoclasia and hemorrhage
DIF	IgG positive reaction with acantholytic cells	IgM/C3 positive reaction with the walls of vessels	NA	NA	C3 positive reaction with the small vessel walls in the dermis
Others	VZV antibodies on primary examination when no skin lesions were observed: IgM-negative [IgG=3879 (normal<135)]	Immunohistochemical stain for VZV: positive	A virus swab for laboratory diagnosis of VZV by PCR: positive	Electron microscopic examination: herpes virus particles within the obliterated vessels	-
Treatment	Brivudine (125 mg/day) for 5 days and analgesics	Intravenous acyclovir for 7 days and then oral valacyclovir for 7 days	NA	Acyclovir	Amenamenvir for a week
Outcome	Complete remission of all cutaneous symptoms and improvement of pain were achieved within a week	Ulcerations and leg pain improved after treatment	NA	After several weeks the lesion healed with moderate scarring, and after several months no neuralgia or other sequelae were noted	After a week purpura resolved and all blisters became scabbing

DIF, direct immunofluorescence; VZV, varicella zoster virus; PCR, polymerase chain reaction; NA, not applicable; Ig, immunoglobulin.

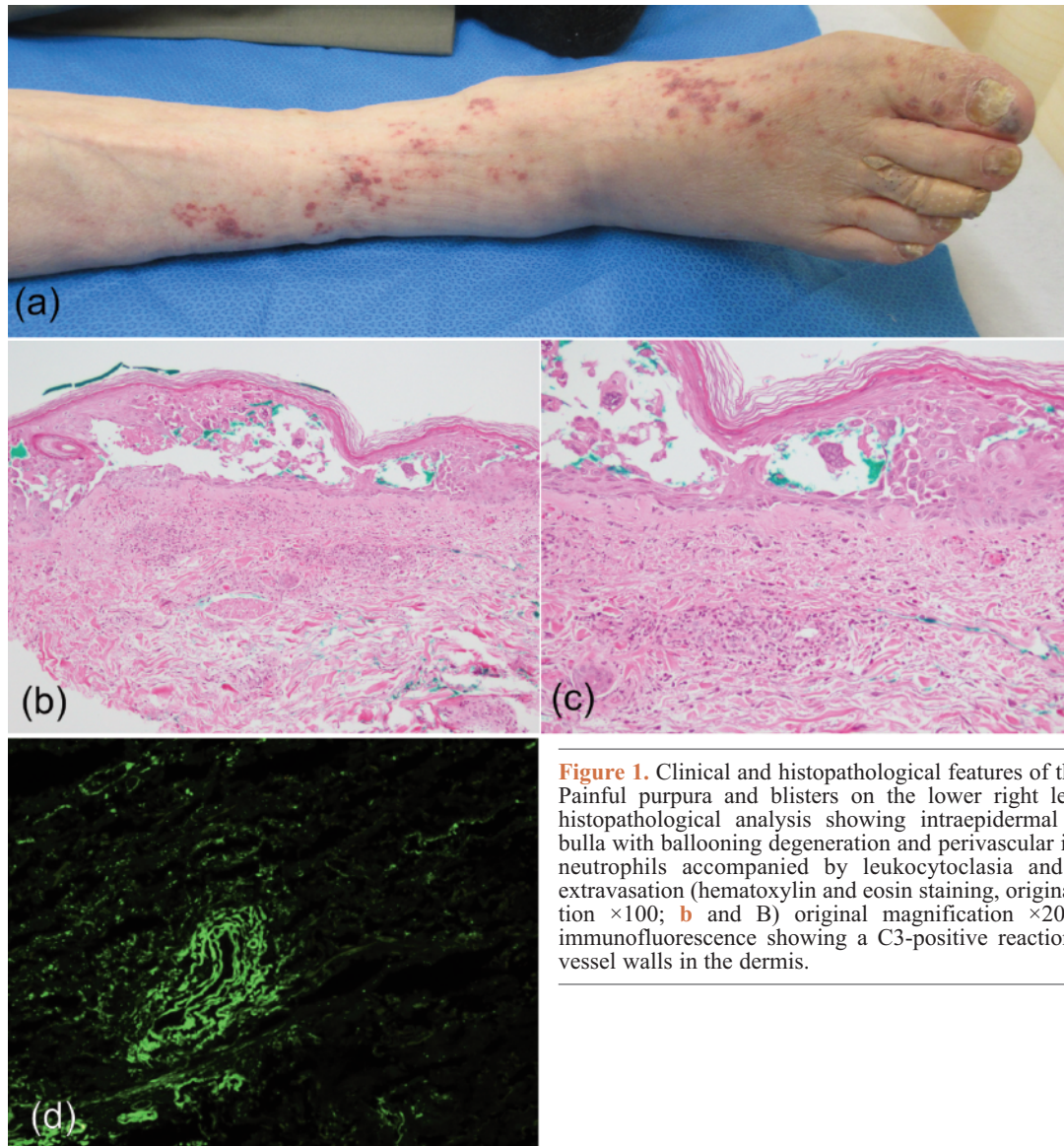


Figure 1. Clinical and histopathological features of the patient. **a)** Painful purpura and blisters on the lower right leg; **b** and **c)** histopathological analysis showing intraepidermal acantholytic bulla with ballooning degeneration and perivascular infiltration of neutrophils accompanied by leukocytoclasia and erythrocyte extravasation (hematoxylin and eosin staining, original magnification $\times 100$; **b** and **B)** original magnification $\times 200$; **d)** direct immunofluorescence showing a C3-positive reaction with small vessel walls in the dermis.

cases of segmental LCV associated with herpes zoster have been reported (Table 1). Our review of these cases revealed that most patients were immunosuppressed. All patients were male with an average age of 66.6 years. We also found that the leg is susceptible to LCV associated with herpes zoster. Anti-viral treatment was effective for LCV as well as herpes zoster. Based on these observations, we speculate that the risk factors for LCV associated with herpes zoster may include immunosuppression, male sex, and older age, with the lower limbs most likely to be affected (Table 1). The etiology of LCV may include immune complex deposition mediated by vessel wall damage or stimulated autoreactive immune cells elicited by molecular mimicry.¹ Another possibility is that direct VZV infection of the endothelium may cause thickened intima and vascular remodeling.^{2,4} In addition, it has been reported that IgA vasculitis, an acute LCV with strong abdominal symptoms, may result from VZV infection based on the observation that VZV envelope glycoprotein antigens were found in both cutaneous and gastrointestinal lesions.⁵ However, the mechanism of VZV reactivation causing cutaneous vasculitis remains unclear. Taken together, these findings suggest that clinicians should be alert to the possibility of LCV in patients with herpes zoster, especially in immunosuppressed patients.

References

1. Wollina U, Schonlebe J. Segmental leukocytoclastic vasculitis in herpes zoster. *Int J Dermatol* 2012;51:1351-2.
2. Clark AK, Dhossche J, Korcheva VB et al. Herpes zoster presenting as unilateral vasculitis. *Dermatol Online J* 2018;24.
3. Erhard H, Runger TM, Kreienkamp M et al. Atypical varicella-zoster virus infection in an immunocompromised patient: result of a virus-induced vasculitis. *J Am Acad Dermatol* 1995;32: 908-11.
4. Burgard B, Smola S, Vogt T et al. Small Vessel Vasculitis in Herpes Zoster-Discussion of Current Aspects of Varicella Zoster Virus Vasculopathy. *Am J Dermatopathol* 2018;40:602-4.
5. Ushigome Y, Yamazaki Y, Shiohara T. IgA vasculitis with severe gastrointestinal symptoms may be an unusual manifestation of varicella zoster virus reactivation. *Br J Dermatol* 2017;176:1103-5.