

Complications associated with the use of resuscitative endovascular balloon occlusion of the aorta (REBOA): an updated review

Marcelo Augusto Fontenelle Ribeiro Junior ¹, Salman M Salman ², Sally M Al-Qaraghuli,³ Farah Makki,⁴ Riham A Abu Affan,³ Shahin Reza Mohseni,⁵ Megan Brenner⁶

¹Surgery, Division of Trauma, Critical Care and Acute Care Surgery, Sheikh Shakhboub Medical City, Abu Dhabi, UAE

²Gulf Medical University, Ajman, UAE

³College of Medicine and Health Sciences, Abu Dhabi, UAE

⁴Medicine, University of Sharjah, Sharjah, UAE

⁵Sheikh Shakhboub Medical City, Abu Dhabi, UAE

⁶UCLA Medical Center, Los Angeles, California, USA

Correspondence to

Dr Marcelo Augusto Fontenelle Ribeiro Junior; drmrribeiro@gmail.com

Received 2 October 2023

Accepted 22 December 2023

ABSTRACT

Resuscitative endovascular balloon occlusion of the aorta (REBOA) has become part of the arsenal to temporize patients in shock from severe hemorrhage. REBOA is used in trauma to prevent cardiovascular collapse by preserving heart and brain perfusion and minimizing distal hemorrhage until definitive hemorrhage control can be achieved. Significant side effects, including death, ischemia and reperfusion injuries, severe renal and lung damage, limb ischemia and amputations have all been reported. The aim of this article is to provide an update on complications related to REBOA. REBOA has emerged as a critical intervention for managing severe hemorrhagic shock, aiming to temporize patients and prevent cardiovascular collapse until definitive hemorrhage control can be achieved. However, this life-saving procedure is not without its challenges, with significant reported side effects. This review provides an updated overview of complications associated with REBOA. The most prevalent procedure-related complication is distal embolization and lower limb ischemia, with an incidence of 16% (range: 4–52.6%). Vascular and access site complications are also noteworthy, documented in studies with incidence rates varying from 1.2% to 11.1%. Conversely, bleeding-related complications exhibit lower documentation, with incidence rates ranging from 1.4% to 28.6%. Pseudoaneurysms are less likely, with rates ranging from 2% to 14%. A notable incidence of complications arises from lower limb compartment syndrome and lower limb amputation associated with the REBOA procedure. Systemic complications include acute kidney failure, consistently reported across various studies, with incidence rates ranging from 5.6% to 46%, representing one of the most frequently documented systemic complications. Infection and sepsis are also described, with rates ranging from 2% to 36%. Pulmonary-related complications, including acute respiratory distress syndrome and multisystem organ failure, occur in this population at rates ranging from 7.1% to 17.5%. This comprehensive overview underscores the diverse spectrum of complications associated with REBOA.

INTRODUCTION

Non-compressible torso hemorrhage (NCTH) poses a significant threat to trauma patients, leading to substantial morbidity and mortality.¹ Resuscitative endovascular balloon occlusion of the aorta

(REBOA) has emerged as a crucial procedure in the last decade for traumatic hemorrhagic shock, with roots traced back to the Korean War.² Lieutenant Colonel Hughes proposed a potentially life-saving use of a balloon to occlude the aorta selectively, controlling hemorrhage below the occlusion level and maintaining vital blood flow in traumatic scenarios.³ REBOA uses a balloon-tipped catheter to temporarily occlude the aorta, serving as a damage control measure until definitive interventions can be performed.⁴ While effective in preventing exsanguination, REBOA, despite improvements in survival rates, presents several complications requiring timely recognition and management to minimize morbidity and mortality.⁵

REBOA is indicated for patients experiencing severe life-threatening hemorrhage below the diaphragm, in hemorrhagic shock unresponsive or transiently responding to resuscitation. It is also indicated for patients arriving in cardiac arrest due to suspected life-threatening bleeding below the diaphragm. The balloon catheter is inflated at the distal thoracic aorta (zone 1) for intra-abdominal or retroperitoneal hemorrhage and traumatic arrest. For severe pelvic, junctional, or proximal lower extremity hemorrhage, the balloon catheter may be inflated at the distal abdominal aorta (zone 3).⁶ Figure 1 outlines current algorithms for REBOA in shock and arrest.⁷ While the optimal duration of arrest and deployment of REBOA is undetermined, it should align with the time frame of resuscitative thoracotomy (RT).⁸ Current recommendations advise not exceeding 30 minutes of complete occlusion time in zone 1, potentially extending to 60 minutes in zone 3.⁸

This review aims to provide an updated overview of complications associated with REBOA, drawing insights from clinical and translational data.⁵ Additionally, it seeks to assess the effectiveness of mitigations and identify areas for future research to enhance the safety and efficacy of REBOA in managing hemorrhagic shock.

METHOD

A comprehensive literature search of PubMed, Scopus, and EMBASE databases was conducted spanning 2019–2023 to identify studies on trauma patients with non-compressible torso and pelvic hemorrhage. The search used keywords and MeSH (Medical Subject Headings) terms such as

© Author(s) (or their employer(s)) 2024. Re-use permitted under CC BY-NC. No commercial re-use. See rights and permissions. Published by BMJ.

To cite:

Fontenelle Ribeiro Junior MA, Salman SM, Al-Qaraghuli SM, et al. *Trauma Surg Acute Care Open* 2024;**9**:e001267.

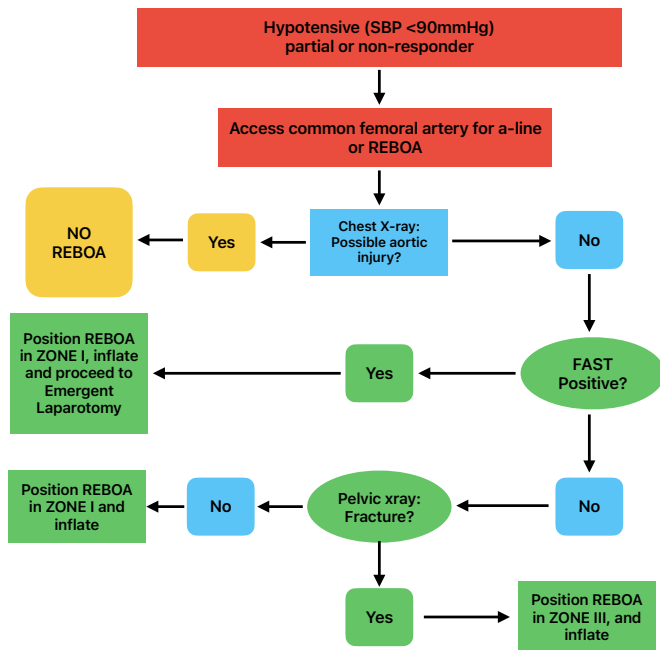


Figure 1 Deployment algorithm (adapted from Brenner *et al* [7]). REBOA, resuscitative endovascular balloon occlusion of the aorta; SBP, systolic blood pressure.

REBOA, complications, resuscitation, hemorrhage, and shock. The senior author reviewed and selected articles published in English, Spanish, and Portuguese. Inclusion criteria were limited to studies involving trauma patients with non-compressible torso and pelvic hemorrhage, while excluding those not measuring outcomes, individual case reports, and studies solely assessing prehospital REBOA.

RESULTS

The results are categorized into two groups: procedure-related complications and systemic complications. Complication rates, ranging from 11.1% to 54.4%, are influenced by factors such as aortic occlusion duration, sheath size, indications for REBOA use, time to hemorrhage control, resuscitation adjuncts, operator experience, and hospital resources.

Procedure-related complications

The most common overall procedure-related complication is related to distal embolization and lower limb ischemia, with a frequency of 16% (range: 4–52.6%). Vascular and access site complications are also highly reported, with studies reporting a range of 1.2–11.1%. Conversely, bleeding-related complications are less commonly documented, with incidence rates ranging from 1.4% to 28.6%. Pseudoaneurysms are less likely with rates ranging from 2% to 14%. There is a high incidence of complications from lower limb compartment syndrome and lower limb amputation associated with the procedure.^{8,9}

Access-related vascular injuries and mitigations

Vascular complications related to catheter insertion are commonly reported in REBOA literature. These can occur during different steps of the REBOA technique including during initial access of the femoral artery, insertion of the sheath or balloon catheter or balloon inflation, resulting in various serious vascular injuries with an incidence between 1.2% and 11.1%.^{8,9}

Ordoñez *et al*¹⁰ demonstrated that 16% of patients experienced vascular-related complications associated with groin access during REBOA, including femoral artery dissection (8%), thrombosis (4%), pseudoaneurysm (2%), and local infection (2%). Notably, none of the 14 patients who underwent REBOA with the 7-French (Fr) sheath encountered access complications.¹⁰

Furthermore, other reported complications encompass arterial pseudoaneurysm at the access site and distal embolic events, with incidence rates of 2.2% and 4.3%, respectively, alongside two instances of balloon migration after deployment.¹¹

Among various studies, access-related limb ischemic complications were noted in 8.6% of REBOA survivors. Extremity ischemia occurred in 5.2% of cases, distal embolism in 6.0%, and a combination of both in 2.6%.^{10,12–19} Laverty *et al*¹⁹ conducted a recent study investigating the prevalence of access-related limb ischemia issues in REBOA survivors, along with associated clinical, technical, and device risk factors.

Additional studies reported the following complication rates: arterial dissection (2.4%), pseudoaneurysm (0.4%), embolization (2%), clinically significant bleeding (0.6%), limb ischemia (3.9%), compartment syndrome (0.7%), and limb loss (0.7%).^{10,12,13,15,17,20,21}

Insertion techniques

In the high-paced emergency department setting, suboptimal technique during initial arterial access poses a challenge.²² Aorto/iliac perforation, intimal damage, and hematoma at the access site have all been associated with access technique variations.^{15,16,23} Percutaneous common femoral artery (CFA) access, guided by ultrasound (US), is the preferred method, surpassing the landmark technique.²² US-guided placement enhances precision, minimizing the risk of multiple punctures and related complications such as hematomas, arterial wall injuries, thrombosis, and incorrect access to the superficial femoral artery, thereby reducing the risk of vascular injury and limb ischemia.

Effective patient selection is pivotal for favorable outcomes, recognizing that recipients of REBOA often present as severely ill cases in complex clinical situations. Given the extensive ischemia in the splanchnic system, major truncal bleeding requiring zone 1 balloon inflation typically triggers a systemic response during reperfusion. To address these challenges, comprehensive training for all trauma team members is essential. Integrating a CFA line in severely injured patients undergoing massive transfusion protocol activation serves as an excellent strategy, ensuring team proficiency and facilitating catheter insertion when required.⁷

Sheath sizes

Access-related limb ischemic complications, including clinically relevant extremity ischemia or distal embolization, are prevalent in REBOA procedures.^{10,12–19,24} Catheter insertion may lead to aortic dissection, rupture, perforation, embolization, air emboli, and peripheral ischemia.^{10,13–15,17–19,25} Technical errors during arterial cannulation and 7 Fr sheath insertion, especially in hypotensive patients, can result in bleeding or damage to nearby structures.²⁵ In trauma patients undergoing REBOA, limb ischemia is a known adverse event, with the balloon's arterial occlusion, direct arterial wall injury, reduced limb outflow, venous system congestion, and reperfusion injury contributing to the mechanism and potentially leading to compartment syndrome.

Studies have highlighted the importance of considering ipsilateral extremity injuries in the context of REBOA-related complications. A national study reported a 5% incidence of major amputations, with approximately 90% linked to preadmission

ipsilateral extremity injuries, mostly traumatic amputations and vascular/orthopedic injuries.²⁶ A recent study reported a lower extremity amputation rate of 0.3%, contrasting with a 2019 study (3.6%), likely influenced by factors such as injury severity and the ability to discern limb salvage procedures and amputation timing.^{21 27} Manzano-Nunez *et al* emphasized lower rates of REBOA-associated lower limb complications when considering underlying injuries rather than operator-related technical complications.²⁸ Instances of amputation directly associated with vascular puncture during REBOA insertion were reported, and complications related to groin access were noted in about 5.6% of patients.^{28 29}

The literature advocates for the use of smaller access sheaths to mitigate complications in REBOA. Studies have shown reduced vascular access complications with smaller REBOA sheaths.^{11 30} In a study with 50 trauma patients primarily undergoing REBOA through surgical cut down, outcomes improved significantly with a smaller diameter sheath compared with a larger one.¹⁰ Despite these improvements, the incidence of lower limb amputation remains higher in REBOA patients (3.6%) compared with the no-REBOA group (0.7%), suggesting a potential association between REBOA and an increased risk of requiring lower limb amputation.^{14 21 24 26} The ongoing focus on optimizing patient outcomes and limb salvage procedures in trauma patients underscores the importance of addressing this concern.

A recent study introduced the Control of Bleeding, Resuscitation, Arterial Occlusion System (COBRA-OS), a novel 4 Fr catheter designed to minimize vessel damage or perforation during insertion, thereby reducing access site complications. The smaller catheter size aims to simplify the procedure by eliminating the need to upsue an initial sheath.³¹ Additional benefits include decreased patient discomfort and a reduced risk of bleeding complications. The COBRA-OS features an atraumatic flexible tip for safe, blind artery advancement and is designed to be 'fluoroscopy-free', eliminating the need for tracking over a wire. While the study is limited by its controlled experimental environment, small sample size, and a single expert physician, it is noteworthy that the last author is the founder of the company.³¹

Balloon placement complications and mitigations

After REBOA insertion guided by external landmarks for the desired occlusion zone, confirmation of balloon placement before inflation is crucial and typically recommended through X-ray (XR) imaging.²² However, time-sensitive emergencies and resource limitations may pose challenges for obtaining XR. Balloon morphology is assessed for overinflation or underinflation before securing the catheter. Various methods, including fluoroscopy, haptic feedback, loss of contralateral pulse, or monitoring arterial wave form on the contralateral side, are employed to measure balloon volume after inflation and evaluate the degree of occlusion.²²

In situations where XR is impractical, physiological responses and anatomic landmarks can be used for confirming balloon position. Non-radiographic techniques, such as US-guided viewing via subxiphoid, transperitoneal, or transesophageal approaches, present alternative options to overcome the limitations of standard fluoroscopic imaging. However, these techniques may pose challenges in emergency situations.³² Overinflation of the balloon can lead to substantial morbidity and mortality, causing damage to the vessel wall.³³ First-generation devices typically feature compliant balloons, contrasting with semicompliant or non-compliant balloons. The risk of aortic rupture and severe hypotension is heightened by balloon distortion, especially

when proximal and distal occlusion confirmation techniques are unreliable, making accurate measurement of overinflation challenging.³¹

Balloon occlusion complications and mitigations

Prolonged occlusion time

Occlusion time is a critical consideration in REBOA procedures, as the ischemia it induces limits the duration of complete aortic occlusion. Studies highlight increased mortality rates with occlusion times surpassing 30 minutes for zone 1 and 60 minutes for zone 3.^{6 34} Current recommendations advocate for a maximum target occlusion time of 30 minutes for zone 1 and 60 minutes for zone 3 to mitigate complications associated with REBOA procedures.⁶ Prolonged occlusion times, exceeding 40–60 minutes, have been linked to irreversible tissue damage and poor acute hemodynamic response, potentially leading to limb amputation.^{6 14 21 24 26} Extended occlusion times in trauma patients are associated with more adverse outcomes, including increased mortality and organ failure.³⁵

Complete occlusion

Complete occlusion, while effective in controlling hemorrhage below the level of occlusion, is associated with serious ischemic complications, limiting its duration and applicability in patients with complex injuries.³⁶ REBOA, despite its efficacy in managing bleeding, faces challenges related to adverse effects on cerebral, pulmonary, and cardiac pressures proximally, as well as progressive ischemic burden distally to the occlusion site.^{6 37} The complete interruption of arterial flow with REBOA catheters leads to complications beyond the occlusion point, such as ischemia-reperfusion-related issues.³⁸ The existing REBOA approach, with its all-or-nothing balloon inflation strategy, can induce significant hemodynamic instability. These limitations have prompted the development of targeted regional optimization strategies and devices aimed at enhancing proximal aortic and cerebral blood flow. These innovations mitigate distal ischemia, extend aortic occlusion durations, and facilitate resuscitation in the presence of ongoing hemorrhage while minimizing the adverse effects of complete aortic occlusion.³⁹

Automated variable aortic control

Endovascular variable aortic control (EVAC) emerges as a strategy to address challenges associated with traditional devices, aiming to titrate down to partial occlusion manually, manage hemodynamic shifts, and balance priorities of hemostasis, blood pressure (BP) augmentation, and distal organ perfusion.^{37 40} EVAC employs an algorithm-driven automated flow-regulating syringe device controller connected to existing REBOA catheters. This set-up enables precise regulation of aortic flow by making small adjustments in balloon filling volume based on real-time diastolic BP measurements above the balloon.³⁷ In preclinical models, this approach has demonstrated effective mitigation of the ischemic burden associated with sustained aortic occlusion while minimizing hemorrhage.^{41–43}

Partial REBOA

Partial REBOA (pREBOA) represents a strategy for controlled slow aortic flow past a titratable balloon, mitigating ischemic insult below the balloon and maintaining physiological central aortic and cerebral pressures.⁴⁴ Preclinical models indicate that even minimal blood flow to distal limbs with pREBOA leads to fewer adverse hemodynamic changes, reduced ischemia/reperfusion injury, and decreased inflammatory factors, while

effectively controlling hemorrhage.^{36 45 46} Additionally, preclinical data support pREBOA's capability to safely extend occlusion time to over 60 minutes in zone 1.⁴⁷

Despite limited clinical evidence for pREBOA,^{34 35 48} studies by Matsumura *et al*⁴⁸ and others show promising outcomes. Matsumura *et al* demonstrated that patients undergoing pREBOA had better hemodynamic responses and longer occlusion time compared with conventional REBOA (median 58 minutes vs. 33 minutes), with comparable mortality.⁴⁸ Another retrospective study revealed reduced end-organ dysfunction, fewer ventilator and intensive care unit days, and decreased vasopressor requirement in patients undergoing pREBOA compared with conventional REBOA.³⁵

However, achieving effective partial occlusion manually poses challenges. Manual manipulation using low-fidelity methods results in highly variable and imprecise distal aortic flow rates, making it difficult to titrate distal flow precisely, especially during ongoing hemorrhage.⁴⁹ The compliance of first-generation catheter balloons, like the Eliason-Rasmussen REBOA (ER-REBOA), limits control during deflation, leading to an all-or-nothing approach.^{16 35} Challenges also arise from difficulty in predicting optimal balloon volume for transition from complete to partial occlusion and the unpredictable interaction of fully compliant balloons with the aortic wall.^{48 50 51}

To address these challenges, purpose-built devices like the pREBOA-PRO (Prytime Medical Inc., Boerne, TX) offer titratable partial aortic occlusion with a semicompliant balloon. Preclinical studies demonstrate its feasibility, providing responsive management of deflation and gradual distal aortic flow, potentially limiting distal ischemia and reperfusion injury compared with complete aortic occlusion.^{38 52–55} The pREBOA-PRO device enables longer zone 1 deployment without frequent adjustments, improving outcomes.^{34 38} Its dual arterial line capability allows real-time monitoring of central aortic and distal femoral artery pressures, providing evidence of ongoing perfusion and guiding resuscitation.³⁴ In a clinical setting, the use of pREBOA-PRO devices allowed longer zone 1 total occlusion times without worsening distal ischemic injury compared with complete occlusion devices.³⁴ Improved feasibility and controlled partial occlusion make pREBOA-PRO a promising advancement for trauma patients, providing improved outcomes while avoiding hemodynamic collapse.

Sheath removal complications and mitigations

In the final step of the procedure, sheath removal can result in complications. Distal thrombus around the sheath and arterial dissection during cannulation and/or insertion can be worsened by prolonged occlusion and in-dwelling sheath times. Furthermore, documented cases of lower limb ischemia leading to amputation were attributed to sheath removal, which resulted from ongoing systemic ischemia.^{10 12–19 24} Assessment of perfusion prior to and after removal of the sheath should be performed routinely and surveilled by those with endovascular experience.

Systemic-related complications

Systemic complications associated with aortic occlusion procedures like REBOA pose inherent risks despite their benefits. While REBOA aims to restore central BP and control NCTH below the balloon, prolonged occlusion carries the risk of ischemia-reperfusion injuries to distal organs, including spinal cord ischemia and acute kidney injury (AKI).^{13 15 16 21 24 25 56 57} Acute kidney failure is a consistently documented systemic complication, with incidence rates ranging from 5.6% to 46%, making it one of

the most frequently reported complications. Infection and sepsis rates range from 2% to 36%, while pulmonary-related complications, such as acute respiratory distress syndrome (ARDS) and multisystem organ failure, occur at rates ranging from 7.1% to 17.5%.^{12 13 24 56} Gastrointestinal complications show relative consistency, with variability observed in other complications. Additionally, prolonged hypoperfusion can lead to hyperkalemia, acidosis, and coagulopathy.^{5 12 58}

Aortic rupture

While uncommon, aortic rupture which presents as hemorrhagic shock or limb ischemia has been reported in an animal study as a complication of overinflation.³³ Although this is a very rare complication, one study reported ipsilateral common iliac artery rupture after inadvertent inflation in the incorrect location, and another demonstrated that iatrogenic left common iliac artery damage is a risk.^{18 23}

Amputations

In a 2023 study, 3.8% of patients with ER-REBOA and 6.7% of patients with pREBOA required amputations.^{27 57}

Lower extremity complications

The overall incidence of lower extremity complications was low. A review of lower extremity complications in patients who underwent REBOA placement did not show any difference in rates of lower extremity amputation (5.3%), exploration (14%), fasciotomy (7%), or thrombectomy (3.5%) when compared with no-REBOA patients.⁵⁹

Compartment syndrome

Extremity compartment syndrome, a complication on the rise, has been reported in two separate studies, with incidence rates ranging from 6% to 15%.^{13 21} These findings are supported by Chien *et al*⁶⁰ which found their lower limb compartment syndrome incidence rate at 4.3%.

Acute kidney injury

Another noteworthy systemic complication due to ischemia-reperfusion-related complications included AKI.^{5 13 15 16 21 24 25 56} AKI has been a prevalent complication documented in many REBOA studies, with incidence rates varying from higher to no significance compared with no-REBOA use.^{13 15 16 21 24 25 56 61} AKI is caused by REBOA due to a multitude of factors. Studies that report higher rates of AKI have the majority of the REBOA performed in zone 1 and for longer occlusion times.^{13 16 21 25 56} In contrast, studies with lower or no significant difference in AKI rates compared with no-REBOA groups performed REBOA mainly in zone 3 with or without shorter occlusion times.^{15 60 62 63} In addition, Brenner *et al*²⁴ reported that as the use of REBOA becomes more widespread, higher rates of AKI are being reported, potentially related to various factors, including ischemia of distal muscle beds, systemic inflammatory response activation, and additional insults such as contrast-enhanced CT scans and angiography procedures. Remarkably, patients treated with pREBOA had a significantly lower AKI incidence at 6.7% compared with those treated with ER-REBOA at 40%.⁵⁷

Pulmonary

In an extensive examination of REBOA complications, studies revealed a diverse spectrum of adverse events, including pulmonary complications.^{12 13 24 56} A comparative study involving REBOA with angioembolization or preperitoneal pelvic packing

reported a 12.1% incidence of ARDS and acute lung injury (ALI).²⁴ Additionally, DuBose *et al*¹¹ documented ARDS or ALI at 2.6%, pneumonia at 6.1%, and multiorgan dysfunction at 6.1%.¹¹ Chien *et al*⁶⁰ reported 2.2% ARDS and 4.3% pulmonary embolism among REBOA patients.⁶⁰ The occurrence of ARDS and ALI in REBOA patients may be linked to factors such as thromboxane release, leukocyte priming, complement activation, tumor necrosis factor synthesis, and complications related to mechanical ventilation, abdominal surgery, atelectasis, fluid shifts, and crystalloid resuscitation.⁶

Sepsis

Among the common complications reported were sepsis and infections.^{10 13 24 25} Bacteremia affected 2.7% of patients, and the incidence of pneumonia reached 8.4% in a related study.²⁷

Similarly, DuBose *et al*¹¹ reported sepsis or septic shock in 6.1% of patients and an additional study found surgical site infection rates at 3.3%, severe sepsis at 3.2%, and cases of enteric fistulas.⁶⁰

Other

Paraplegia occurred in a small percentage, 1.5% of patients, while the rate of myocardial infarction was 0.8%.¹¹

Coagulopathies

Thrombotic complications are a significant concern associated with REBOA, as its deployment causes non-specific coagulation disturbances due to flow obstruction and stasis of deoxygenated blood below the balloon. This results in persistent inflammatory pathways, systemic platelet activation, and platelet-leukocyte interactions, while suppressing anti-inflammatory and thrombolytic compounds.^{5 6 10 12 13 15 16 20 21 24 60} The imbalance between prothrombotic effects and insufficient fibrinolytic activity increases the incidence of venous thromboembolism (VTE) and deep vein thrombosis (DVT). In a study, the REBOA group showed significantly higher rates of VTE (14% vs. 6.5%) and DVT (11.8% vs. 5.4%) compared with the no-REBOA group ($p=0.023$ and $p=0.035$, respectively).⁶⁰

Understanding the effects of aortic occlusion on systemic coagulation and inflammation is challenging due to co-occurring trauma and hemorrhage. Patients may present with various alterations influenced by trauma-related physiological derangements. The potential contribution of REBOA to complications is related to ischemia, where restricted oxygen and nutrient supply can lead to cellular and subcellular damages, endothelial breakdown, platelet activation, fibrin cross-linking, microthrombi formation, and persistent inflammatory pathways. This cascade may cause significant cellular damage, intravascular thrombi formation, secondary ischemia, and organ failure.⁶⁴

Multiorgan dysfunction

Multiorgan dysfunction syndrome was correlated with REBOA deployment and ranged from 3.4% to 47.6%.^{11 13 24 25} Organ dysfunction and failure result from ischemia brought on by the prolonged occlusion of the aorta.^{65 66} Another potential pathway implicated in REBOA organ dysfunction is related to the damage to the endothelial glycocalyx, which can lead to inflammation, vascular permeability, and end-organ dysfunction. Shedding of glycocalyx components into the patients' blood may thus serve as a biomarker of impending disruption.⁶ These comprehensive studies underscore the need for careful consideration of potential complications when employing REBOA in trauma patients, calling for an informed and cautious approach in its utilization.^{11 27}

On the other hand, it is important to note that multiorgan dysfunction may in turn be associated with other factors present in this group of patients, such as hemorrhagic shock and hypotension, so this complication cannot be attributed exclusively to the use of the balloon.⁵⁹

Moreover, other studies have reported cases of myocardial dysfunction during full REBOA, indicating potential complications affecting the heart.^{5 12 58} This can be explained by the severe acidosis ($pH < 7.2$) that leads to transmembrane electrolyte shifts and malfunction of intracellular proteins, significantly impacting the myocardium. Consequently, this can lead to decreased cardiac output and refractory hypotension.⁵⁸ High potassium levels on balloon deflation and late increases can also cause cardiac instability.⁵⁸ The 'trauma lethal diamond of death', where lactic acidosis hampers cardiac performance, leading to hypothermia, disrupts the coagulation cascade and is aggravated by hypocalcemia. This impaired coagulopathy, in turn, may cause ongoing hemorrhage, worsening hemorrhagic shock, and exacerbates acidosis.⁵⁸ Further studies analyzing human data are needed to assess the impact of both local and systemic hypothermias during REBOA on ischemia-reperfusion injury and coagulation specifically. These will possibly rely on development of deployable regional cooling and distal perfusion solutions.⁶⁴

Metabolic and electrolyte derangements

Metabolic and electrolyte derangements represent another complication of REBOA.^{5 12 58} In swine models of aortic occlusion, metabolic derangements including hypocalcemia and hyperkalemia, resulting from REBOA use, are common and may worsen long after reperfusion despite resuscitation. It was observed that lactic acidosis, hyperkalemia, hypoglycemia, and hypocalcemia are complications after REBOA and are severe enough to necessitate intervention regardless of the occlusion's level, degree, or duration.^{5 12 58} Notably, it was shown that lactic acid, a by-product of anaerobic metabolism causing acidosis, reaches its peak approximately an hour after reperfusion and normalizes with adequate resuscitation. Hyperkalemia is a common finding in trauma patients, where the condition can become more severe due to ischemic cellular lysis, acidosis-driven electrolyte shifts between intracellular and extracellular spaces, and reduced potassium clearance from subsequent ischemic renal dysfunction. The specific cause of hypoglycemia is not completely understood, but it could relate to a combination of factors, such as REBOA-induced adrenal ischemia, liver dysfunction, and potential pancreatic responses to hyperkalemia or transient ischemia. Also, hypocalcemia was observed in connection with lactic acidosis, potentially resulting from augmented calcium binding to free lactate ions, modified responsiveness of parathyroid hormone, intracellular calcium shifts, and phosphate chelation of calcium. These conditions, largely resulting from increased ischemia, may require aggressive pharmacological countermeasures.⁵⁸

Mortality

REBOA holds promise in improving outcomes for patients with NCTH compared with RT. However, the impact on mortality remains inconsistent, with rates ranging from 29% to 88%.^{10 12-21 25 56} This represents an improvement from the previously reported mortality rates of 91.5% and 92.6% from older studies.^{5 11 26} In multivariable analysis, prehospital cardiac arrest, penetrating trauma, decreased total Glasgow Coma Scale score, older age, and increased total Injury Severity Score were associated with higher mortality.^{26 67} Survival after REBOA has also

been shown to be dependent on hemodynamic status at the time of aortic occlusion.⁶ Recently, a study published by Jansen *et al*⁶⁸ evaluated the role of REBOA compared with standard treatment versus standard treatment alone in patients with exsanguinating hemorrhages.⁶⁸ Two groups were randomized, one with 46 REBOA and standard care (SC) patients and the other with 44 SC patients. The authors showed that the use of REBOA associated with treatment did not reduce and may have increased patient mortality. However, these results should be analyzed cautiously since due to the limited sample size.⁶⁸ The REBOA group had, in general, lower systolic BP than the SC group, making it questionable whether these patients may have survived, regardless of advanced resuscitation. The Abbreviated Injury Scales in the groups were similar, except for head injury, where the REBOA group scored higher. Traumatic brain injury itself is associated with mortality. Another relevant fact to be considered concerns the time the REBOA was applied.⁶⁸ The presented data show that the IQR in the REBOA group was from 56 to a concerning 156 minutes, causing patients to bleed for hours until bleeding control was achieved. Another important finding was the time taken to insert the balloon, which averaged 32 minutes, a significantly high figure, making it clear that team training plays a vital role in the outcome to be expected.⁶⁸ We must emphasize that the time between trauma, effective control of bleeding, and adequate team training plays a decisive role in the results and in reducing complications related to the method.

Data surrounding REBOA's success in improving mortality outcomes remain inconsistent. An analysis of the AORTA (Aortic Occlusion in Resuscitation for Trauma and Acute Care Surgery) registry during a 5-year period (2014–2018) showed a 22%/year decrease in REBOA mortality over the study's time frame. The authors attribute some of this improvement to a 10 mm Hg increase in the systolic BP threshold used to dictate proceeding with REBOA and shifting to earlier deployment of REBOA (ie, patients had less severe physiological derangement at time of REBOA placement) as well as shift from zone 1 placement to zone 3.²⁷ The most recent data out of the Japan Trauma Data Bank showed a reduced mortality rate in severely injured trauma patients and significantly lower OR for in-hospital mortality rate in patients treated with REBOA compared with open aortic cross-clamping.⁶⁹

On the other hand, another study published by Harfouche *et al*⁵⁹ reinforced the positive role of REBOA when used in high-volume trauma centers.⁵⁹ This retrospective evaluation compared pre-REBOA and REBOA (deployed in zone 3) periods based on data from the R. Adams Cowley Shock Trauma Center, a quaternary center with 6000–7000 admissions per year where 102 481 patients were included in the study. The results showed that in-hospital mortality was significantly lower in the group receiving REBOA (19.3%) versus 44.7% ($p=0.001$) in the historical control group, and the 30-day survival rate was significantly higher when comparing the groups ($p=0.035$).⁵⁹ There is no doubt that the use of endovascular occlusion of the aorta has an essential role in the management of unstable trauma patients. The best way to decrease the risk of the previously mentioned complications is proper patient selection and refined technique using US-guided arterial accesses and small-diameter devices as much as possible.

CONCLUSION

REBOA, an evolving treatment, has witnessed advancements in equipment, methodologies, and techniques, contributing to decreased severity of previous issues. Studies indicate improved

survivability, particularly with balloon inflation in zone 3. Common complications involve vascular and access sites, along with distal embolization and lower limb ischemia. Systemic complications include AKI, infection, sepsis, and pulmonary issues. The use of pREBOA and smaller profile devices emerges as a potential solution, preserving distal limb blood flow and enhancing patient outcomes. Critical factors in complication reduction include proper training, performing procedures in high-volume trauma centers, and selecting suitable cases for the method.

Contributors MAFRJ, MB: substantial contributions to the conception of the work; analysis and interpretation of data for the work. SMS, RAAA, SMA-Q, FM, SRM: substantial contributions to the conception or design of the work; acquisition of data for the work. All authors contributed to drafting of the work and revising it critically for important intellectual content. All authors approved the final version to be published and agree to be accountable for all aspects of the work in ensuring that questions related to the accuracy or integrity of any part of the work are appropriately investigated and resolved.

Funding The authors have not declared a specific grant for this research from any funding agency in the public, commercial or not-for-profit sectors.

Competing interests MB: UptoDate Inc—chapter coauthor and Prytime Medical Inc clinical advisory board (end date: May 2022).

Patient consent for publication Not applicable.

Provenance and peer review Not commissioned; externally peer reviewed.

Open access This is an open access article distributed in accordance with the Creative Commons Attribution Non Commercial (CC BY-NC 4.0) license, which permits others to distribute, remix, adapt, build upon this work non-commercially, and license their derivative works on different terms, provided the original work is properly cited, appropriate credit is given, any changes made indicated, and the use is non-commercial. See: <http://creativecommons.org/licenses/by-nc/4.0/>.

ORCID iDs

Marcelo Augusto Fontenelle Ribeiro Junior <http://orcid.org/0000-0001-9826-4722>
Salman M Salman <http://orcid.org/0000-0002-4093-1083>

REFERENCES

- Kinslow K, Shepherd A, McKenney M, Elkbuli A. Resuscitative endovascular balloon occlusion of aorta: a systematic review. *Am Surg* 2022;88:289–96.
- HUGHES CW. Use of an intra-aortic balloon catheter tamponade for controlling intra-abdominal hemorrhage in man. *Surgery* 1954;36:65–8.
- Brenner M. REBOA and catheter-based technology in trauma. *J Trauma Acute Care Surg* 2015;79:174–5.
- Granieri S, Frassini S, Cimbanassi S, Bonomi A, Paleino S, Lomaglio L, Chierici A, Bruno F, Biondi R, Di Saverio S, *et al*. Impact of resuscitative endovascular balloon occlusion of the aorta (REBOA) in traumatic abdominal and pelvic exsanguination: a systematic review and meta-analysis. *Eur J Trauma Emerg Surg* 2022;48:3561–74.
- Ribeiro Junior MAF, Feng CYD, Nguyen ATM, Rodrigues VC, Bechara GEK, de-Moura RR, Brenner M. The complications associated with Resuscitative Endovascular Balloon Occlusion of the Aorta (REBOA). *World J Emerg Surg* 2018;13:20.
- Brenner M, Moore L, Dubose J, Scalea T. Resuscitative Endovascular Balloon Occlusion of the Aorta (REBOA) for use in temporizing intra-abdominal and pelvic hemorrhage: physiologic sequelae and considerations. *Shock* 2020;54:615–22.
- Brenner M, Hoehn M, Pasley J, Dubose J, Stein D, Scalea T. Basic endovascular skills for trauma course: bridging the gap between endovascular techniques and the acute care surgeon. *J Trauma Acute Care Surg* 2014;77:286–91.
- Bekdache O, Paradis T, Shen YBH, Elbahrawy A, Grushka J, Deckelbaum D, Khwaja K, Fata P, Razek T, Beckett A. Resuscitative Endovascular balloon occlusion of the aorta (REBOA): indications, advantages and challenges of implementation in traumatic non-compressible torso hemorrhage. *Trauma Surg Acute Care Open* 2019;4:e000262.
- Okada Y, Narumiya H, Ishi W, Ryoji I. Lower limb ischemia caused by resuscitative balloon occlusion of aorta. *Surg Case Rep* 2016;2:130.
- Ordoñez CA, Khan M, Cotton B, Perreira B, Brenner M, Ferrada P, Horer T, Kauvar D, Kirkpatrick A, Priouzram A, *et al*. The Colombian experience in Resuscitative Endovascular Balloon Occlusion of the Aorta (REBOA): the progression from a large caliber to a low-profile device at a level I trauma center. *Shock* 2021;56:42–5.
- DuBose RJ, Morrison J, Brenner M, *et al*. AORTA Registry 7F vs 11-12 F access. *JEVTM* 2019;3.
- Park J, Jang SW, Yu B, Lee GJ, Chang SW, Kim DH, Chang YR, Jung PY. An early experience of Resuscitative Endovascular Balloon Occlusion of the Aorta (REBOA) in the Republic of Korea: a retrospective multicenter study. *J Trauma Inj* 2020;33:144–52.

- 13 McGreevy DT, Abu-Zidan FM, Sadeghi M, Pirouzram A, Toivola A, Skoog P, Idoguchi K, Kon Y, Ishida T, Matsumura Y, *et al.* Feasibility and clinical outcome of reboa in patients with impending traumatic cardiac arrest. *Shock* 2020;54:218–23.
- 14 Lendrum R, Perkins Z, Chana M, Marsden M, Davenport R, Grier G, Sadek S, Davies G. Pre-hospital Resuscitative Endovascular Balloon Occlusion of the Aorta (REBOA) for Exsanguinating pelvic haemorrhage. *Resuscitation* 2019;135:6–13.
- 15 Coccolini F, Ceresoli M, McGreevy DT, Sadeghi M, Pirouzram A, Toivola A, Skoog P, Idoguchi K, Kon Y, Ishida T, *et al.* Aortic balloon occlusion (REBOA) in pelvic ring injuries: preliminary results of the ABO trauma Registry. *Updates Surg* 2020;72:527–36.
- 16 McGreevy DT, Sadeghi M, Nilsson KF, Hörer TM. Low profile REBOA device for increasing systolic blood pressure in hemodynamic instability: single-center 4-year experience of use of ER-REBOA. *Eur J Trauma Emerg Surg* 2022;48:307–13.
- 17 Hadley JB, Coleman JR, Moore EE, Lawless R, Burlaw CC, Platnick B, Pieracci FM, Hoehn MR, Coleman JJ, Campion EM, *et al.* Strategies for successful implementation of resuscitative endovascular balloon occlusion of the aorta in an urban level I trauma center. *J Trauma Acute Care Surg* 2021;91:295–301.
- 18 Theodorou CM, Salcedo ES, DuBose JJ, Galante JM. Hate to burst your balloon: successful REBOA use takes more than a course. *J Endovasc Resusc Trauma Manag* 2020;4:21–9.
- 19 Laverty RB, Treffalls RN, McEntire SE, DuBose JJ, Morrison JJ, Scalea TM, Moore LJ, Podbielski JM, Inaba K, Piccinini A, *et al.* Life over limb: arterial access-related limb ischemic complications in 48-hour REBOA survivors. *J Trauma Acute Care Surg* 2022;92:723–8.
- 20 O'Neil M, Vella M, Dumas R, Seamon M, Cannon J, Qasim Z. 1771. *Critical Care Medicine* 2019;47:859.
- 21 Joseph B, Zeeshan M, Sakran JV, Hamidi M, Kulvatunoy N, Khan M, O'Keeffe T, Rhee P. Nationwide analysis of resuscitative endovascular balloon occlusion of the aorta in civilian trauma. *JAMA Surg* 2019;154:500–8.
- 22 Demetriades D, Chudnofsky CR, Benjamin ER. *Color Atlas of emergency trauma.* Cambridge University Press, 2021: 335–41.
- 23 Wasicek PJ, Teeter WA, Brenner ML, Hoehn MR, Scalea TM, Morrison JJ. Resuscitative endovascular balloon occlusion of the aorta: rupture risk and implications for blind inflation. *Trauma Surg Acute Care Open* 2018;3:e000141.
- 24 Brenner M, Moore L, Zakhary B, Schwed A, Cralley A, Romagnoli A, Fox C, Scalea T, Burlaw CC. Scalpel or sheath? Outcomes comparison between pre-peritoneal pelvic packing and angioembolization for definitive hemorrhage control after REBOA. *JEVTM* 2020;4:49–55.
- 25 Moore LJ, Fox EE, Meyer DE, Wade CE, Podbielski JM, Xu X, Morrison JJ, Scalea T, Fox CJ, Moore EE, *et al.* Prospective observational evaluation of the ER-REBOA catheter at 6 U.S. *Annals of Surgery* 2022;275:e520–6.
- 26 Levin SR, Farber A, Burke PA, Brahmabhatt TS, Richman AP, Twomey KE, Siracuse JJ. The majority of major amputations after resuscitative endovascular balloon occlusion of the aorta are associated with preadmission trauma. *Journal of Vascular Surgery* 2021;74:467–476.
- 27 Bukur M, Gorman E, DiMaggio C, Frangos S, Morrison JJ, Scalea TM, Moore LJ, Podbielski J, Inaba K, Kauvar D, *et al.* Temporal changes in REBOA utilization practices are associated with increased survival: an analysis of the AORTA Registry. *Shock* 2021;55:24–32.
- 28 Manzano-Nunez R, Escobar-Vidarte MF, Naranjo MP, Rodriguez F, Ferrada P, Casallas JD, Ordoñez CA. Expanding the field of acute care surgery: a systematic review of the use of resuscitative endovascular balloon occlusion of the aorta (REBOA) in cases of morbidly adherent placenta. *Eur J Trauma Emerg Surg* 2018;44:519–26.
- 29 Manzano-Nunez R, Escobar-Vidarte MF, Orlas CP, Herrera-Escobar JP, Galvagno SM, Melendez JJ, Padilla N, McCarty JC, Nieto AJ, Ordoñez CA. Resuscitative endovascular balloon occlusion of the aorta deployed by acute care surgeons in patients with morbidly adherent placenta: a feasible solution for two lives in peril. *World J Emerg Surg* 2018;13:44.
- 30 Shum-Tim L, Bichara-Allard S, Hopkins B, AlShahwan N, Hanley S, Manzano-Nunez R, Garcia AF, Deckelbaum D, Grushka J, Razek T, *et al.* Vascular access complications associated with resuscitative endovascular balloon occlusion of the aorta in adult trauma patients: a systematic review and meta-analysis. *J Trauma Acute Care Surg* July 21, 2023.
- 31 Power A, Parekh A, Scallan O, Smith S, Novick T, Parry N, Moore L. Size matters: first-in-human study of a novel 4 French REBOA device. *Trauma Surg Acute Care Open* 2021;6:e000617.
- 32 Teeratakulpisarn P, Angkathip P, Tanmit P, Thanapaisal C, Prasertcharoensuk S, Wongkonkitsin N. A life saving emergency Department Resuscitative Endovascular balloon occlusion of the aorta (REBOA) with open groin technique. *Open Access Emerg Med* 2021;13:183–8.
- 33 Hoareau GL, Tibbits EM, Beyer CA, Simon MA, DeSoucy ES, Faulconer ER, Neff LP, Grayson JK, Stewart IJ, Williams TK, *et al.* Resuscitative Endovascular balloon occlusion of the aorta: review of the literature and applications to veterinary emergency and critical care. *Front Vet Sci* 2019;6:197.
- 34 Gomez D, Naveed A, Rezende J, Dennis BM, Kundi R, Benjamin E, Lawless R, Nguyen J, Duchesne J, Spalding C, *et al.* Titratable partial aortic occlusion: extending zone I endovascular occlusion times. *J Trauma Acute Care Surg* 2023;95:S36–40.
- 35 Madurska MJ, Franklin C, Richmond M, Adnan SM, Stansby GP, White JM, Morrison JJ. Improving the safety of resuscitative endovascular balloon occlusion of the aorta - compliant versus semi-compliant balloon systems. *Vascular* 2020;28:612–8.
- 36 Sadeghi M, Dogan EM, Karlsson C, Jansson K, Seilitz J, Skoog P, Hörer TM, Nilsson KF. Total resuscitative endovascular balloon occlusion of the aorta causes inflammatory activation and organ damage within 30 minutes of occlusion in normovolemic pigs. *BMC Surg* 2020;20:43.
- 37 Williams TK, Neff LP, Tibbits EM, Hoareau GL, Simon MA, Davidson AJ, DeSoucy ES, Faulconer ER, Johnson MA. A novel automated endovascular variable aortic control device to expand function of Standard REBOA catheters. *JEVTM* 2019;3:3–10.
- 38 Zilberman-Rudenko J, Behrens B, McCully B, Dewey EN, Smith SG, Murphy JM, Goodman A, Underwood SJ, Rick EA, Madson BM, *et al.* Use of bilobed partial resuscitative endovascular balloon occlusion of the aorta is logistically superior in prolonged management of a highly lethal aortic injury. *J Trauma Acute Care Surg* 2020;89:464–73.
- 39 Ronaldi AE, Lauria AL, Paterson JE, Kersey AJ, Leung LY, Burmeister DM, Baer DG, White PW, Rasmussen TE, White JM. Targeted regional optimization in action: dose-dependent end-organ ischemic injury with partial aortic occlusion in the setting of ongoing liver hemorrhage. *Shock* 2022;57:732–9.
- 40 Williams TK, Tibbits EM, Hoareau GL, Simon MA, Davidson AJ, DeSoucy ES, Faulconer ER, Grayson JK, Neff LP, Johnson MA. Endovascular variable aortic control (EVAC) versus Resuscitative Endovascular balloon occlusion of the aorta (REBOA) in a swine model of hemorrhage and ischemia reperfusion injury. *J Trauma Acute Care Surg* 2018;85:519–26.
- 41 Williams TK, Neff LP, Johnson MA, Russo RM, Ferencz S-A, Davidson AJ, Clement NF, Grayson JK, Rasmussen TE. Automated variable aortic control versus complete aortic occlusion in a swine model of hemorrhage. *J Trauma Acute Care Surg* 2017;82:694–703.
- 42 Beyer CA, Hoareau GL, Tibbits EM, Davidson AJ, DeSoucy ED, Simon MA, Grayson JK, Neff LP, Williams TK, Johnson MA. Resuscitative endovascular balloon occlusion of the aorta induced myocardial injury is mitigated by endovascular variable aortic control. *J Trauma Acute Care Surg* 2019;87:590–8.
- 43 Williams AM, Bhatti UF, Dennahy IS, Graham NJ, Nikolian VC, Chtraklin K, Chang P, Zhou J, Biesterveld BE, Eliason J, *et al.* Traumatic brain injury may worsen clinical outcomes after prolonged partial resuscitative endovascular balloon occlusion of the aorta in severe hemorrhagic shock model. *J Trauma Acute Care Surg* 2019;86:415–23.
- 44 Johnson MA, Neff LP, Williams TK, DuBose JJ, EVAC Study Group. Partial Resuscitative balloon occlusion of the aorta (P-REBOA): clinical technique and rationale. *J Trauma Acute Care Surg* 2016;81:S133–7.
- 45 Johnson MA, Davidson AJ, Russo RM, Ferencz S-AE, Gotlib O, Rasmussen TE, Neff LP, Williams TK. Small changes, big effects: the hemodynamics of partial and complete aortic occlusion to inform next generation resuscitation techniques and technologies. *J Trauma Acute Care Surg* 2017;82:1106–11.
- 46 Johnson MA, Williams TK, Ferencz S-AE, Davidson AJ, Russo RM, O'Brien WT Sr, Galante JM, Grayson JK, Neff LP. The effect of resuscitative endovascular balloon occlusion of the aorta, partial aortic occlusion and aggressive blood transfusion on traumatic brain injury in a swine multiple injuries model. *J Trauma Acute Care Surg* 2017;83:61–70.
- 47 Russo RM, Williams TK, Grayson JK, Lamb CM, Cannon JW, Clement NF, Galante JM, Neff LP. Extending the golden hour: partial resuscitative endovascular balloon occlusion of the aorta in a highly lethal swine liver injury model. *J Trauma Acute Care Surg* 2016;80:372–8;
- 48 Matsumura Y, Matsumoto J, Kondo H, Idoguchi K, Ishida T, Okada Y, Kon Y, Oka K, Ishida K, Toyoda Y, *et al.* Early arterial access for resuscitative endovascular balloon occlusion of the aorta is related to survival outcome in trauma. *J Trauma Acute Care Surg* 2018;85:507–11.
- 49 Forte DM, Do WS, Weiss JB, Sheldon RR, Kuckelman JP, Eckert MJ, Martin MJ. Titrate to equilibrate and not exsanguinate! characterization and validation of a novel partial Resuscitative Endovascular balloon occlusion of the aorta catheter in normal and hemorrhagic shock conditions. *J Trauma Acute Care Surg* 2019;87:1015–25.
- 50 Davidson AJ, Russo RM, Ferencz S-AE, Cannon JW, Rasmussen TE, Neff LP, Johnson MA, Williams TK. Incremental balloon deflation following complete resuscitative endovascular balloon occlusion of the aorta results in steep inflection of flow and rapid reperfusion in a large animal model of hemorrhagic shock. *J Trauma Acute Care Surg* 2017;83:139–43.
- 51 Sadeghi M, Hörer TM, Forsman D, Dogan EM, Jansson K, Kindler C, Skoog P, Nilsson KF. Blood pressure targeting by partial REBOA is possible in severe hemorrhagic shock in pigs and produces less circulatory, metabolic and inflammatory sequelae than total REBOA. *Injury* 2018;49:2132–41.
- 52 Kemp MT, Wakam GK, Williams AM, Biesterveld BE, O'Connell RL, Verbruyse CA, Chtraklin K, Russo RM, Alam HB. A novel partial resuscitative endovascular balloon aortic occlusion device that can be deployed in zone 1 for more than 2 hours with minimal provider titration. *J Trauma Acute Care Surg* 2021;90:426–33.
- 53 Polcz JE, Ronaldi AE, Madurska M, Bedocs P, Leung LY, Burmeister DM, White PW, Rasmussen TE, White JM. Next-generation REBOA (Resuscitative Endovascular balloon occlusion of the aorta) device precisely achieves targeted regional optimization in a porcine model of hemorrhagic shock. *J Surg Res* 2022;280:1–9.

- 54 White JM, Ronaldi AE, Polcz JE, Spreadborough P, Madurska M, Mares JA, Leung LY, Rasmussen TE. A new pressure-regulated, partial resuscitative endovascular balloon occlusion of the aorta device achieves targeted distal perfusion. *J Surg Res* 2020;256:171–9.
- 55 Russo RM, White JM, Baer DG. Partial resuscitative endovascular balloon occlusion of the aorta: a systematic review of the preclinical and clinical literature. *J Surg Res* 2021;262:101–14.
- 56 Hoehn MR, Hansraj NZ, Pasley AM, Brenner M, Cox SR, Pasley JD, Diaz JJ, Scalea T. Resuscitative endovascular balloon occlusion of the aorta for non-traumatic intra-abdominal hemorrhage. *Eur J Trauma Emerg Surg* 2019;45:713–8.
- 57 Hunt I, Gold L, Hunt JP, Marr AB, Greiffenstein P, Stuke L, Smith A. Acute kidney injury in hypotensive trauma patients following resuscitative endovascular balloon occlusion of the aorta placement. *Am Surg* 2023;89:3454–9.
- 58 Abid M, Neff LP, Russo RM, Hoareau G, Williams TK, Grayson JK, DuBose JJ, Lendrum R, Johnson MA. Reperfusion repercussions: a review of the metabolic derangements following resuscitative endovascular balloon occlusion of the aorta. *J Trauma Acute Care Surg* 2020;89:S39–44.
- 59 Harfouche MN, Madurska MJ, Elansary N, Abdou H, Lang E, DuBose JJ, Kundi R, Feliciano DV, Scalea TM, Morrison JJ. Resuscitative endovascular balloon occlusion of the aorta associated with improved survival in hemorrhagic shock. *PLoS ONE* 2022;17:e0265778.
- 60 Chien C-Y, Lewis MR, Dilday J, Biswas S, Luo Y, Demetriades D. Worse outcomes with resuscitative endovascular balloon occlusion of the aorta in severe pelvic fracture: a matched cohort study. *Am J Surg* 2023;225:414–9.
- 61 Wasicek PJ, Teeter WA, Yang S, Banchs H, Galvagno SM, Hu P, Gamble WB, Hoehn MR, Scalea TM, Morrison JJ. Extended Resuscitative Endovascular balloon occlusion of the aorta (REBOA)-Induced type 2 myocardial ischemia: a time-dependent penalty. *Trauma Surg Acute Care Open* 2019;4:e000194.
- 62 Mikdad S, van Erp IAM, Moheb ME, Fawley J, Saillant N, King DR, Kaafarani HMA, Velmahos G, Mendoza AE. Pre-peritoneal pelvic packing for early hemorrhage control reduces mortality compared to Resuscitative Endovascular balloon occlusion of the aorta in severe blunt pelvic trauma patients: a nationwide analysis. *Injury* 2020;51:1834–9.
- 63 Asmar S, Bible L, Chehab M, Tang A, Khurram M, Douglas M, Castanon L, Kulvatunyou N, Joseph B. Resuscitative endovascular balloon occlusion of the aorta vs pre-peritoneal packing in patients with pelvic fracture. *J Am Coll Surg* 2021;232:17–26.
- 64 Thrailkill MA, Gladin KH, Thorpe CR, Roberts TR, Choi JH, Chung KK, Necsoiu CN, Rasmussen TE, Cancio LC, Batchinsky AI. Resuscitative Endovascular balloon occlusion of the aorta (REBOA): update and insights into current practices and future directions for research and implementation. *Scand J Trauma Resusc Emerg Med* 2021;29:8.
- 65 Heindl SE, Wiltshire DA, Vahora IS, Tsouklidis N, Khan S. Partial versus complete resuscitative endovascular balloon occlusion of the aorta in exsanguinating trauma patients with non-compressible torso hemorrhage. *Cureus* 2020;12:e8999.
- 66 Cantle PM. REBOA utility. *Surg Open Sci* 2022;8:50–6.
- 67 Koh EY, Fox EE, Wade CE, et al. Resuscitative endovascular balloon occlusion of the aorta and resuscitative thoracotomy are associated with similar outcomes in traumatic cardiac arrest. *J Trauma Acute Care Surg* 2023;95:912–7.
- 68 Jansen JO, Hudson J, Cochran C, et al. Emergency department resuscitative endovascular balloon occlusion of the aorta in trauma patients with Exsanguinating hemorrhage: the UK-REBOA randomized clinical trial. *JAMA* 2023;330:1862–71.
- 69 Haruta K, Endo A, Shiraishi A, Otomo Y. Usefulness of resuscitative endovascular balloon occlusion of the aorta compared to aortic cross-clamping in severely injured trauma patients: analysis from the Japan trauma data bank. *Acute Med Surg* 2023;10:e830.