












Segmental areas of denervation in post-polio syndrome

Desnervação segmentar na síndrome pós-pólio

Vinícius Lopes Braga¹  Heloísa Lopes Cohim Moreira¹  Pedro Henrique Almeida Fraiman¹ 
 Filipe Pereira Sarmiento¹  Igor Braga Farias¹  Paulo de Lima Serrano¹ 
 Bruno de Mattos Lombardi Badia¹  Marco Antônio Troccoli Chiaia¹ 
 Wladimir Bocca Vieira de Rezende Pinto¹  Paulo Victor Sgobbi de Souza¹  Acary Souza Bulle Oliveira¹ 

¹ Universidade Federal de São Paulo, Escola Paulista de Medicina, Departamento de Neurologia e Neurocirurgia, São Paulo SP, Brazil.

Address for correspondence Vinícius Lopes Braga (email: viniciuslopesbraga@live.com)

Arq. Neuropsiquiatr. 2024;82(2):s00441779507.

A one-year-old male disclosed motor developmental delay, appendicular hypotonia, hyporeflexia, and weakness in the left lower limb. He started walking only at three years old. After this time, his symptoms were stable. At 31 years old, the patient started slight asymmetric and slowly progressive paraparesis

and myalgia. He was referred with a suspicion of spinal muscular atrophy. Electromyography disclosed bilateral chronic lumbosacral denervation and mild acute denervation involving the right lower limb. Neuroimaging studies (brain and spinal MRI) and genetic testing (MLPA test for quantification of SMN1 and

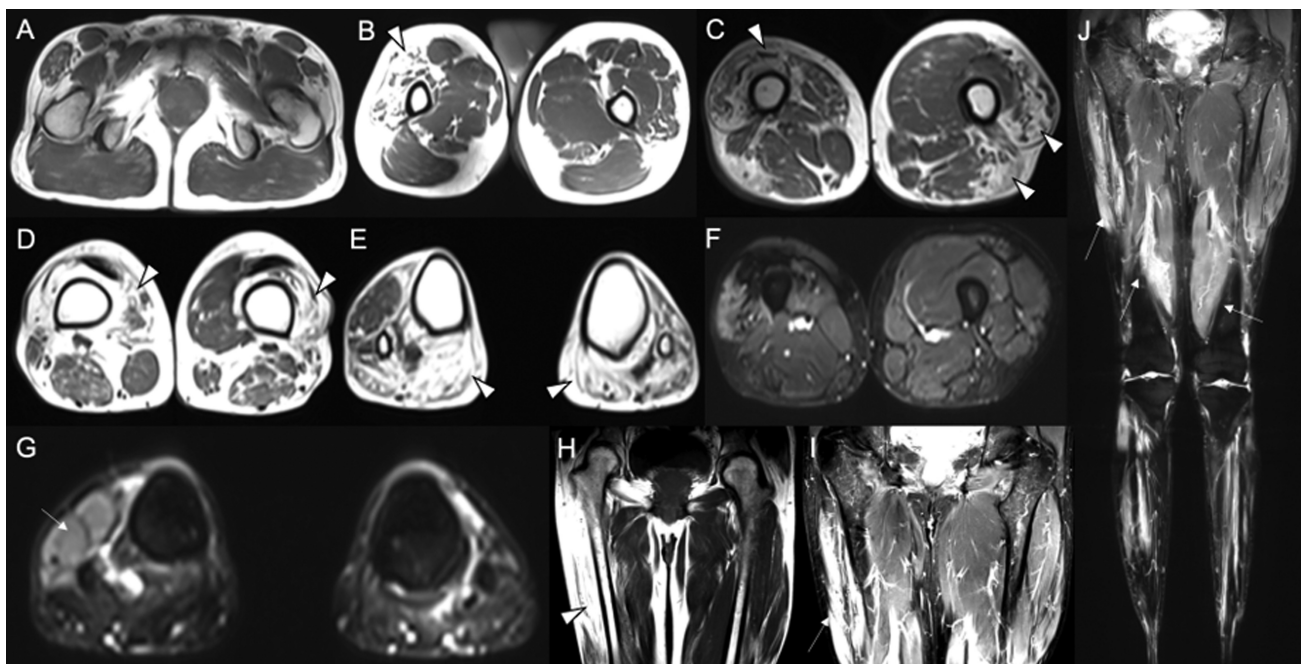


Figure 1 Muscle MRI studies. Axial (A-E) and coronal (H) T1-weighted MRI shows asymmetric amyotrophy and marked fatty replacement involving bilateral vastus lateralis, right vastus intermedius, left biceps femoris, right vastus medialis, left tibialis anterior, and bilateral heads of gastrocnemius. Axial (F,G) and coronal (I,J) STIR MRI shows hyperintensity involving right vastus lateralis and tibialis anterior.

received
October 15, 2023
received in its final form
December 01, 2023
accepted
December 3, 2023

DOI <https://doi.org/10.1055/s-0044-1779507>.
ISSN 0004-282X.

© 2024. The Author(s).

This is an open access article published by Thieme under the terms of the Creative Commons Attribution 4.0 International License, permitting copying and reproduction so long as the original work is given appropriate credit (<https://creativecommons.org/licenses/by/4.0/>).
Thieme Revinter Publicações Ltda., Rua do Matoso 170, Rio de Janeiro, RJ, CEP 20270-135, Brazil

SMN2 copy numbers and hereditary neuropathy, non-5q, and other motor neuron disease panels) were normal. Muscle MRI disclosed asymmetric neurogenic muscle “islands” alternating areas with and without fatty replacement (► **Figure 1**),¹ suggestive of Post-Poliomyelitis Syndrome (PPS).^{2,3} Muscle MRI is useful to distinguish PPS from other motor neuron diseases.¹⁻³

Authors' Contributions

VLB: conceptualization, data curation, formal analysis, writing – original draft preparation and supervision; HLCM, PHAF, FPS: conceptualization, formal analysis, writing – original draft preparation; LBF: conceptualization, data curation and writing – original draft preparation; PLS: BMLB, MATC, WBVRP: Conceptualization, data curation, formal analysis, writing – review & editing and supervision; PVSS, ASBO: Conceptualization, data curation and writing – review & editing.

Conflict of Interest

There is no conflict of interest to declare.

Acknowledgements

We are grateful to the patient and his family for contributing to this study.

References

- 1 Astrea G, Morrow JM, Manzur A, et al. Muscle “islands”: An MRI signature distinguishing neurogenic from myopathic causes of early onset distal weakness. *Neuromuscul Disord* 2022;32(02): 142–149. Doi: 10.1016/j.nmd.2021.11.003
- 2 Kriss A, Jenkins T. Muscle MRI in motor neuron diseases: a systematic review. *Amyotroph Lateral Scler Frontotemporal Degener* 2022; 23(3-4):161–175. Doi: 10.1080/21678421.2021.1936062
- 3 Sakamoto M, Watanabe H, Kubosawa H, Ishii T. Unusual MRI Findings in a Polio Survivor. *Case Rep Orthop* 2016;2016:3179621. Doi: 10.1155/2016/3179621