

mediastinitis, especially if it is caused by oesophageal rupture or, as in this case, when there may be a communication between the mediastinum and the oropharynx. Pneumomediastinum may simply follow the hyperventilation that occurs in pregnancy, but has also been associated with many other situations associated with hyperventilation from diabetic ketoacidosis to sexual intercourse. The extra pressures generated by valsalva manoeuvres involved in labour, severe asthma, belching, or the inhalation of cocaine or marijuana may also result in air leaking into the mediastinum as, too, can any cause of excessive vomiting such as hyperemesis gravidarum or abuse of "Ecstasy".

The high pressures generated by the dental drill during tooth extraction forced air into the neck and mediastinum – a complication that has also been described following oeso-

phagoscopy, both with and without actual rupture of the oesophagus (Boerhaave's syndrome). Pneumomediastinum may also occur following laparoscopic surgery, transbronchial biopsy, mechanical ventilation, and even arthroscopy of the shoulder! In all cases it is wise to consider prophylactic antibiotic therapy with good Gram negative cover and to consider a radiological search for an oesophageal leak as was undertaken in this patient. Fortunately most cases will resolve spontaneously within a week and although, as the authors comment, surgical intervention may be required, this is rarely necessary.

- 1 Wallace WA. Managing in flight emergencies. *BMJ* 1995; **311**:374–6.
- 2 Mathur R, Cullen J, Kinnear WJM, Johnston IDA. Time course of resolution of persistent air leak in spontaneous pneumothorax. *Respir Med* 1995;**89**:129–32.
- 3 Terndrup TE, Bosco SF, McLean ER. Spontaneous pneumothorax complicating pregnancy – case report and review of the literature. *J Emerg Med* 1989;**7**:245–8.

Thorax 1996;**51**:341–342

Chemodectoma of the trachea

Department of
Radiology
T M Y S Sing
K P Wong
N Young

Department of
Respiratory Medicine
P Despas

Westmead Hospital,
Westmead, NSW 2145,
Australia

Correspondence to:
Dr T M Y S Sing.

Received 18 February 1994
Returned to authors
2 June 1994
Revised version received
11 October 1994
Accepted for publication
16 January 1995

Tom M Y S Sing, Kai Ping Wong,
Noel Young, Paul Despas

Abstract

The case history is described of a patient with lower tracheal chemodectoma who presented with haemoptysis. After conservative management for eight years she represented with airways obstruction. Preoperative tumour embolisation was followed by laser ablation, stenting, and radiotherapy.

(*Thorax* 1996;**51**:341–342)

Keywords: chemodectoma, haemoptysis, bronchial stenting, embolisation.

Chemodectomas are rare tumours that arise from chemoreceptor cells of the paraganglia.¹ We believe this is the first case report of tracheal chemodectoma in the English literature.

Case report

A 77 year old woman presented in 1983 with haemoptysis. Bronchoscopic examination revealed a tumour arising from the posterior wall of the trachea at the level of the carina, extending into both main bronchi. A biopsy specimen showed a chemodectoma. Surgery was considered impossible and she was conservatively managed. She had occasional haemoptysis but little change in bronchoscopic appearances.

In June 1991 she represented with progressive dyspnoea and worsening haemoptysis. A computed tomographic (CT) scan showed a carinal mass extending into the proximal 1 cm of both main bronchi with spread into the subcarinal space, intimately related to the oesophagus and thoracic aorta with no mediastinum lymphadenopathy (fig 1). Spirometric tests showed marked impairment (forced expiratory volume in one second (FEV₁)/forced vital capacity (FVC) = 1.0/1.9 l). Bronchoscopic examination again revealed a tumour arising from the lower trachea, extending into both main bronchi. The more distal bronchi were normal.

Bronchial arteriography showed a hypertrophied upper right bronchial artery supplying a 2 cm vascular tumour (fig 2). The artery was embolised with a mixture of Gelfoam and Ivalon (polyvinyl alcohol) particles to control haemoptysis and to reduce the risk of bleeding during laser ablation.

Six days later rigid bronchoscopy and laser ablation of the endotracheal component of the tumour in the right main bronchus and lower trachea was performed. The left main bronchus was also partially obstructed but was not treated as the mucosa was soft and fleshy and the bronchial wall appeared thin with most of the obstruction due to extrinsic compression.

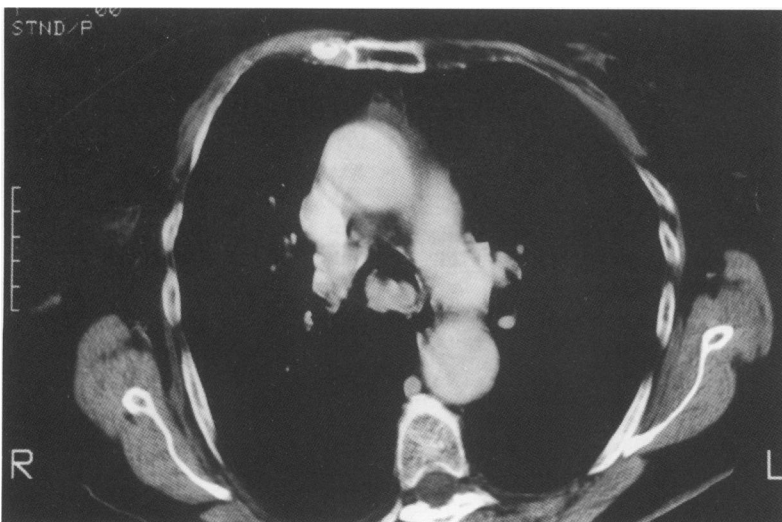


Figure 1 Thoracic computed tomographic scan (mediastinal window) showing tumour spread into the subcarinal space.

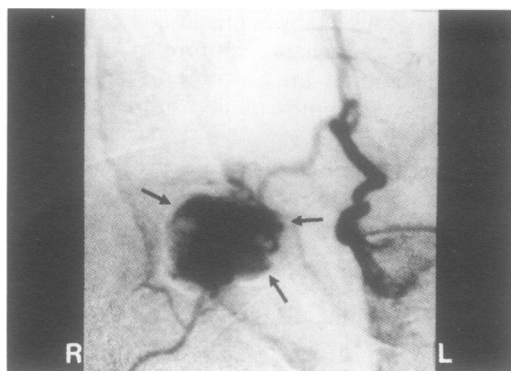


Figure 2 Bronchial arteriogram showing a vascular tumour in the lower trachea (arrow) supplied by a hypertrophied upper right bronchial artery.

Her symptoms and spirometric values worsened after laser ablation ($FEV_1 = 0.4-0.6$ l). Bronchoscopic examination several days later revealed necrotic mucosa with an unstable tracheobronchial angle and a left main bronchus that collapsed excessively during expiration. A 40 mm \times 11 mm silicone Dumon stent was deployed into the left main bronchus with its proximal 3 mm extruding into the trachea. There was complete relief of her symptoms and considerable improvement in her spirometric values ($FEV_1/FVC = 1.5/1.8$ l).

She was well several months later after treatment with 40 Gy of radiotherapy. A CT scan in June 1993 demonstrated the stent in the left main bronchus and a 2 cm mass at the carina. She remained free of respiratory symptoms.

Discussion

Chemodectomas are rare, slow growing, highly vascular tumours arising from chemoreceptor cells of the paraganglia¹⁻⁴ which are hormonally inactive and seldom metastatic.^{2,5} Paraganglia (glomus bodies) function as part of the chemoreceptor system, and participate in the autonomic control of cardiorespiratory function.² Chemoreceptor cells have been found in many body sites including the carotid body, aortic body, vagal ganglion, pulmonary artery, the superior and recurrent laryngeal nerves.⁶

Chemodectomas occur primarily in the carotid body, jugular fossa, middle ear, and occasionally the superior mediastinum.⁷ They cause symptoms by compression and infiltration of adjacent bone, nerves, and blood vessels.⁵ Malignancy occurs in approximately 10%⁷ and are hormonally active in 1%.¹

The diagnosis can be made with angiography,^{2,3} CT scanning or magnetic resonance imaging (MRI) or pathologically by biopsy or complete resection. However, biopsy samples can result in severe haemorrhage.² CT and MRI scans can be useful in assessing for multiple lesions. Duplex sonography can also be employed in suspected carotid body chemodectomas.³ Histologically it is difficult to distinguish a benign from a malignant chemodectoma.^{6,7} The natural history of malig-

nant chemodectoma is usually non-aggressive and slow growing.¹ Radioimmuno-detection can be helpful and has been recommended as a non-invasive screening technique in families at risk for chemodectomas.³

Surgery is the primary treatment for chemodectoma but resection of advanced tumours may be associated with a significant risk of complications including haemorrhage, cerebrovascular accidents, cranial nerve deficits, and death.⁷ A recent study² has shown that radiotherapy is a reasonable alternative to surgery and should be considered the treatment of choice in patients with unresectable recurrent and subtotally resected tumours. Local control has been reported in up to 98% of patients with head and neck chemodectomas after receiving at least 40 Gy. Complications from radiotherapy are rare.⁵

Preoperative tumour embolisation reduces intraoperative blood loss, facilitates subsequent tumour removal, and reduces operative time.^{6,8} A degradable embolisation material such as gelatin sponge instead of a more permanent material is suggested for use in these cases since the tumour will be removed within a few days of the procedure.⁹

Colt *et al*¹⁰ suggested laser resection of endotracheal or tracheal tumours and insertion of a silicone stent in cases where the diameter of the airways is less than 50% of normal. Silicone stents are effective in maintaining a patent tracheobronchial tree when the results of laser resection of malignancies of the lower airway are unsatisfactory. Complications are rare and stents can easily be removed or replaced in case of migration, obstruction by granuloma, or tumour extension.¹⁰

In our patient laser ablation weakened the tracheobronchial wall causing expiratory collapse of the tracheobronchial angle. The silicone Dumon stent inserted into the left main bronchus gave support to the airway, relieving the patient's respiratory symptoms.

The authors would like to thank Miss L. Tan for typing the manuscript and Medical Illustrations at Westmead Hospitals for photographing the radiographs.

- 1 Pryzant RM, Chou JL, Easley JD. Twenty year experience with radiation therapy for temporal bone chemodectomas. *Int J Radiat Oncol Biol Phys* 1989;17:1303-7.
- 2 Schild SE, Foote RL, Buskirk SJ, Robinow JS, Bock FF, Cupps RE, *et al.* Results of radiotherapy for chemodectomas. *Mayo Clin Proc* 1992;67:537-40.
- 3 Kairemo KJA, Hopsu EVM. Radioimmuno-detection of chemodectoma by In-111 labeled anti-CEA antibody. *Clin Nucl Med* 1990;15:900-3.
- 4 Pantanowitz D, Sareli P. Multiple malignant paragangliomas. *S Afr Med J* 1989;76:441-3.
- 5 Springate SC, Weichselbaum RR. Radiation or surgery for chemodectoma of the temporal bone. A review of local control and complications. *Head Neck* 1990;12:303-7.
- 6 Havas TE, Gullane PJ. Multicentric chemodectoma in the head and neck. *Aust N Z J Surg* 1989;59:641-5.
- 7 Guedea F, Mendenhall WM, Parsons JT, Million RR. Radiotherapy for chemodectoma of the carotid body and ganglion nodosum. *Head Neck* 1991;13:509-13.
- 8 Bhojraj SY, Dandawate AV, Ramakantan R. Preoperative embolisation, transpedicular decompression and posterior stabilisation for metastatic disease of the thoracic spine causing paraplegia. *Paraplegia* 1992;30:292-9.
- 9 Hennessy O, Jamieson CW, Allison DJ. Pre-operative embolisation of a chemodectoma. *Br J Radiol* 1984;57:845-6.
- 10 Colt HG, Meric B, Dumon JF. Double stents for carcinoma of the oesophagus invading the tracheo-bronchial tree. *Gastrointest Endosc* 1992;38:485-9.