

Case Report

New-onset tachycardia-bradycardia syndrome following acute non-medullary brainstem infarction

Jingmin Zhao¹, Yu Gao¹, Zhengxian Jin¹, Yujing Huang¹, Kwee-Yum Lee², Guangxun Shen¹

¹Department of Neurology, China-Japan Union Hospital of Jilin University, Changchun, Jilin, China; ²Department of Orthopaedic Surgery and Musculoskeletal Medicine, University of Otago, Dunedin, New Zealand

Received December 19, 2023; Accepted January 30, 2024; Epub February 15, 2024; Published February 28, 2024

Abstract: Tachycardia-bradycardia syndrome (TBS) is a variant of sick sinus syndrome (SSS) characterized by alternating tachycardia and bradycardia. A few cases of SSS secondary to structural lesions in the medulla have been reported, but there has never been a reported case of the rare sign akin to TBS following acute non-medullary brainstem infarction. Furthermore, new-onset cardiac arrhythmias in stroke often presented in one continuous pattern - either as bradycardia or tachycardia, but instances of an alternating fashion have been rarely reported. We present the case of a 46-year-old female who developed severe dizziness with vomiting, diplopia, and slurred speech, which gradually worsened to quadriplegia, severe hypophonia, and dysphagia. Brain magnetic resonance imaging (MRI) demonstrated acute midbrain and pontine infarction. Except for neurological symptoms, the patient experienced unexpected TBS with the symptoms of excessive sweating, palpitations, and irritability without any other predisposing factors. The frequency of the episodes gradually declined until it spontaneously disappeared the 5th day after admission. Given the unpredictable nature of the tachycardia and bradycardia, it was challenging to manage the arrhythmias with medications. A pacemaker was recommended, but financial reasons led the patient to reject this option. Two weeks after antithrombotic therapy and rehabilitation, she was discharged with residual symptoms of diplopia, moderate dysarthria, mild quadriplegia, and no cardiac symptoms. Our case highlighted the occurrence of TBS as a new-onset arrhythmia that can manifest during the acute phase of non-medullary brainstem infarcts. Further research into brainstem lesions contributing to TBS is warranted us to elucidate the underlying mechanisms.

Keywords: Tachycardia-bradycardia syndrome, non-medullary brainstem infarction, central autonomic network, intracranial pressure

Introduction

Cardiac arrhythmias are associated with central nervous system dysfunction, which are frequent in stroke [1]. Clinically, new-onset cardiac arrhythmias in stroke often present in one continuous pattern - either as bradycardia or tachycardia, but instances of an alternating fashion mimicking tachycardia-bradycardia syndrome (TBS), a variant of sick sinus syndrome (SSS), are rarely reported [2]. While the neurocardiac syndrome has mostly been focused on cortical areas, especially the insula areas, it is crucial to recognize the significant role that nuclei of the medulla play in regulating autonomic cardiovascular functions in the brainstem [3]. Although cases of SSS secondary to structural lesions in the medulla have been reported, there has never been a reported case of the

rare sign akin to TBS following acute non-medullary brainstem infarction [4-6].

Case presentation

A 46-year-old right-handed woman developed an episode of severe dizziness with vomiting, diplopia, and slurred speech, and the symptoms lasted for three hours before she was referred to our emergency department. She had a 20-year history of smoking cigarettes, and no known cardiac issues. Neurological examination revealed somnolence, dysarthria, and left lateral gaze palsy with left internuclear ophthalmoplegia, suggestive of left one and a half syndrome. She was subsequently admitted to the neuro-intensive care unit (NICU) after a brain computed tomography (CT) confirmed the absence of intracranial hemorrhage. Fingertip

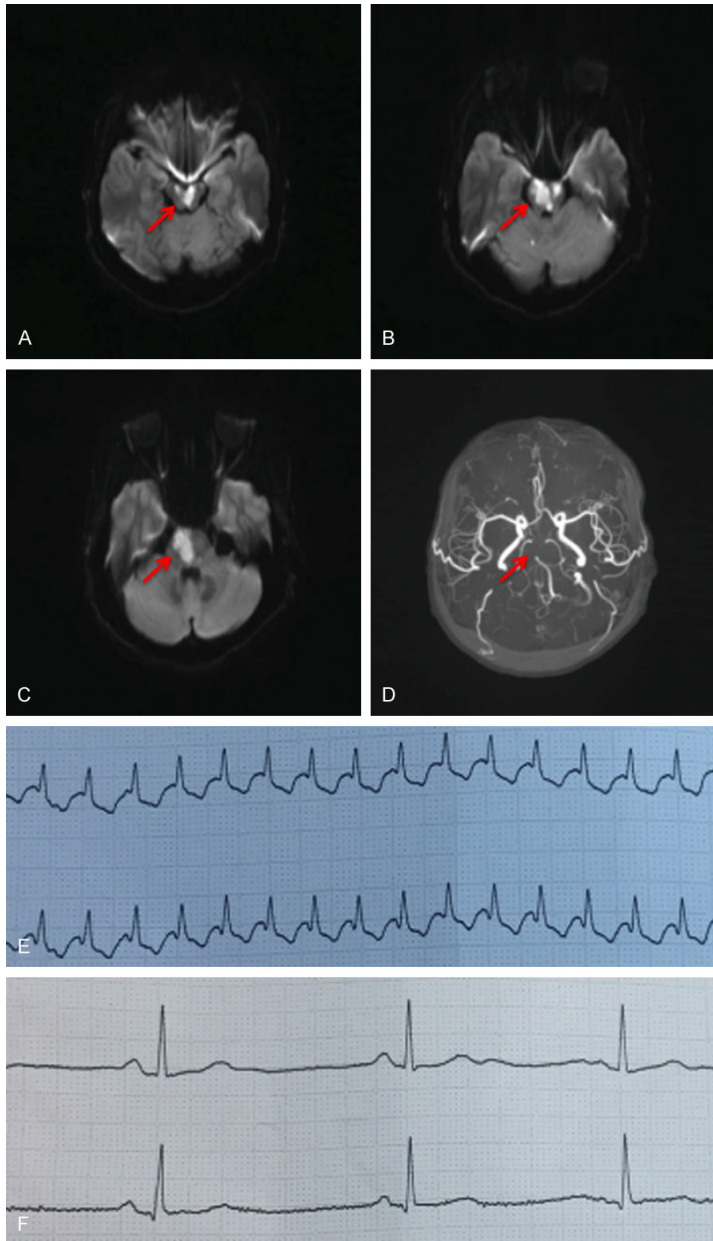


Figure 1. Brain MRI and ECG abnormalities. Diffusion-weighted sequences on brain magnetic resonance imaging showed midbrain and pontine infarction (A-C). The basilar artery and initial segments of both left and right posterior cerebral arteries could not be visualized by brain magnetic resonance angiography (D). The ECG, measured at 4-minute intervals, showed sinus bradycardia and supraventricular tachycardia with heart rates of 206 and 47 beats per minute, respectively (E, F).

blood glucose and electrocardiogram (ECG) results were normal limits. Given the diagnosis of hyperacute cerebral infarction, intravenous thrombolysis was initiated with 54 mg tissue plasminogen activator (rt-PA) 3.5 hours after symptom onset. The patient was given atorvastatin with a dosage of 20 mg once daily and

100 ml of butylphthalide injection twice daily. Despite treatment, the symptoms worsened progressively, leading to quadriplegia, impairment of the horizontal eye movement and anarthria within the initial 24 hours. A diagnosis of locked-in syndrome was established due to total immobility with the preservation of the ability to perform vertical eye movement, blink, and maintain a normal level of consciousness. Brain CT after neurological deterioration demonstrated no intracranial hemorrhage. Dual antiplatelet therapy with aspirin (100 mg/day) and clopidogrel (75 mg/day) was initiated 24 hours after thrombolysis. Diffusion-weighted sequences on brain magnetic resonance imaging (MRI) showed midbrain and pontine infarction (**Figure 1A-C**), while no structural lesions were found in the medulla oblongata and supratentorial region. Brain magnetic resonance angiography (MRA) indicated non-visualization of the basilar artery and bilateral initial part of posterior cerebral artery (PCA) (**Figure 1D**). Notably, the patient experienced new-onset cardiac arrhythmias along with the worsening of neurological symptoms. Unexpected tachycardia occurred with heart rates rapidly escalating from normal to over 170 beats/min for a few minutes. Subsequently, the heart rate dropped to less than 50 beats/min without any medication, as observed by cardiac monitoring. The heart rate ranged between 34 and 206 during an attack without major alterations of blood pressure, whereas it ranged from 59 to 66 between attacks. Episodes of

ECG abnormalities at 4-minute interval time showed supraventricular tachycardia and sinus bradycardia with the heart rate of 206 and 47 beats/min, respectively (**Figure 1E, 1F**). The patient developed symptoms of excessive sweating, palpitations, and irritability with tachycardia episodes. Doppler echocardiography

Stroke induced tachycardia-bradycardia syndrome

showed mild tricuspid regurgitation and normal left ventricular systolic and diastolic function. Laboratory tests, including cardiac enzymes (Troponin I 0.01 ng/mL, CK-MB 0.90 ng/mL, myoglobin 51.5 ng/mL), brain natriuretic peptide (89 pg/ml) and ion levels (potassium 3.6 mmol/L, sodium 138.7 mmol/L, and calcium 2.26 mmol/L), revealed no significant abnormalities. Electrolyte abnormalities, metabolic abnormalities, uncontrolled sleep apnea, and possible offending medications (e.g., beta-blockers, calcium channel blockers) were excluded as causes of secondary TBS. The alternating tachycardia and bradycardia occurred approximately 10 times per day during the initial 48 hours since admission, and the frequency of the episodes gradually declined until it disappeared by the 5th day, as documented by continuous cardiac monitoring and by nurses in the NICU. Although 24-hour dynamic ECG was inconclusive due to some interference, real-time ECG confirmed each episode of alternating tachycardia and bradycardia. Given the unpredictable nature of the tachycardia and bradycardia, it was challenging to manage the arrhythmias with medications. While the consideration of a pacemaker was on the table before tachycardia medication, financial reasons led the patient to decline the option. Two weeks after antithrombotic therapy and rehabilitation, she was discharged with residual symptoms of diplopia, moderate dysarthria, and mild quadriplegia. At the 4-month follow-up, palpitations, excessive sweating, and arrhythmias had ceased, despite ongoing diplopia and slurred speech, resulting in a modified Rankin Scale (mRS) score of 3.

Discussion

TBS represents a variant of SSS characterized by alternating slow and fast heart rates, presumably caused by a malfunction of the sinus node. The spectrum of associated arrhythmias is broad, including inappropriate sinus bradycardia, sinus pauses (> 3 seconds) with junctional escape, sinus arrest, atrial tachycardia, atrial flutter, and atrial fibrillation. Commonly, there is an alternating pattern of tachycardia-bradycardia with a normal sinus rate or bradycardia observed between attacks. The condition may be exacerbated or initiated by both intrinsic factors such as degenerative fibrosis, ion channel dysfunction, and remodeling of the

sinoatrial node, as well as extrinsic factors including pharmacologic, metabolic, or autonomic factors. Diagnosis ultimately hinges on the identification of the arrhythmia through ECG with the presence of symptoms such as palpitations, dizziness, and syncope [7]. For individuals with TBS, the installation of a permanent pacemaker allows the continuation of anti-arrhythmic drug therapy, thereby maintaining sinus rhythm.

Newly developed cardiac arrhythmias are commonly observed following ischemic or hemorrhagic stroke. Previous studies have reported a significantly higher frequency of new-onset arrhythmias in patients with stroke compared to those without a history of stroke [8]. Studies indicated that a 39% incidence of new-onset arrhythmias in patients with no previous cardiac history after experiencing a stroke [2]. The incidence of arrhythmia is particularly elevated within the initial 48 hours following admission to the stroke unit, as detected by cardiac monitoring [9, 10]. Various types of ECG abnormalities have been detected following acute stroke, including abnormal T waves, QT prolongation, atrial fibrillation, atrial tachycardia, and, in some instances, ventricular arrhythmias [1, 8]. Additionally, it is worth noting that the presentation of new-onset cardiac arrhythmias in stroke often follows a continuous pattern, manifesting as either bradycardia or tachycardia. However, an alternating pattern mimicking TBS has not been previously reported.

In our patient, the occurrence of alternating tachycardia and bradycardia could not be associated with any underlying heart disease or medication, and it was most likely that the brainstem lesions were responsible for the tachycardia-bradycardia phenomenon, supported by the following reasons: 1) The patient had no history of heart disease, and the cardiac workups did not show significant findings; 2) The possibility of drug-induced TBS such as calcium channel blockers, beta blockers, amphetamines, antipsychotics, bronchodilators, corticosteroids, and loop diuretics was excluded; 3) The possibility of other causes in TBS such as electrolyte disturbance, obstructive sleep apnea, and neuromuscular diseases was excluded; 4) The onset of tachycardia-bradycardia coincided with the acute phase of brainstem infarction; and 5) The alternating heart rate

normalized as the acute ischemic lesion of the brainstem recovered.

TBS is most likely to be caused by an imbalance of the autonomic tone to the sinoatrial node due to no confounding causes in our case. The sympathovagal imbalance can result from the local pressure effect of the brainstem infarctions. It has been well documented that the cortex, brainstem and autonomic nerves affect cardiac electrophysiology and arrhythmia and that these may function as an integrated system [3]. Research on neurocardiac syndrome has mostly been focused on cortical regions, especially the insula areas, whereas the nucleus tractus solitarius (NTS) in the medulla is assumed to play an essential role in the autonomic regulation of cardiovascular functions within the brainstem [11]. Notably, several case reports have described patients with lateral medullary infarction who developed cardiovascular autonomic dysfunction or sinus arrest [4, 5, 12]. Lee et al. reported a case of SSS following Wallenberg syndrome [6], characterized by an increased R-R interval with bradycardia and prolonged sinus pause. However, occurrence of SSS resulting from non-medullary brainstem has been rarely reported. In our case, the new-onset of TBS was caused by acute brainstem infarction involving midbrain and pontine lesions. While RVLM and NTS in the medulla play a crucial role in cardiovascular regulation, they are not the sole region involved. Other regions in the midbrain and pontine areas (e.g., periaqueductal grey matter of the mesencephalon and Kölliker-Fuse region of the lateral pons), as well as the parasympathetic and sympathetic branches of the autonomic nervous system, also contributes to cardiac regulation [13].

In addition to brainstem lesions, increased intracranial pressure (ICP) can also cause changes in the autonomic nervous system. The cerebral edema caused by brainstem multifocal lesions can displace and compress vital brain tissue and cerebral vessels, affecting cerebrospinal fluid circulation, and leading to increased ICP. ICP serves as a determinant of sympathetic activity, and it can modulate sympathetic activity even at relatively low ICP levels. ICP has also been suggested to play a role in the vagus nerve's function affecting sympathetic and parasympathetic nerve fibers. High

ICP triggered an increased vagal discharge to the heart leading to sinus cycle abnormalities. Makhaly et al. proposed that SSS featuring multiple intermittent sinus pauses was attributed to elevated ICP due to tumor-induced mass effect in the corpus callosum and pontine area [14]. In our case, the tachycardia-bradycardia phenomenon exhibited self-limiting characteristics and showed rapid improvement. This could be attributed to the prompt resolution of edema around the lesion or the rapid reestablishment of the central autonomic regulatory mechanism.

Hence, it is postulated that local compression of the rostral pontine and midbrain infarcts or an increase in ICP due to multifocal lesions could cause significant dysfunction in the cardiovascular regulatory system. This dysfunction involves both the sympathetic and parasympathetic divisions of the autonomic nervous system, ultimately resulting in the manifestation of TBS.

Conclusion

In conclusion, we have highlighted the occurrence of alternating tachycardia and bradycardia as a new onset arrhythmia that can manifest during the acute phase of non-medullary brainstem infarcts. Further research into brainstem lesions contributing to TBS is warranted to elucidate the underlying mechanisms.

Acknowledgements

We thank the patient and her husband for their permission to publish this case report.

Disclosure of conflict of interest

None.

Address correspondence to: Guangxun Shen, Department of Neurology, China-Japan Union Hospital of Jilin University, No. 126 Xiantai Avenue, Changchun 130033, Jilin, China. E-mail: shenguangxun@jlu.edu.cn

References

- [1] Norris JW, Froggatt GM and Hachinski VC. Cardiac arrhythmias in acute stroke. *Stroke* 1978; 9: 392-396.
- [2] Lavy S, Yaar I, Melamed E and Stern S. The effect of acute stroke on cardiac functions as

Stroke induced tachycardia-bradycardia syndrome

- observed in an intensive stroke care unit. *Stroke* 1974; 5: 775-780.
- [3] Taggart P, Critchley H and Lambiase PD. Heart-brain interactions in cardiac arrhythmia. *Heart* 2011; 97: 698-708.
- [4] Takazawa T, Ikeda K, Kano O, Kabuki T, Kawabe K and Iwasaki Y. A case of sinus arrest and post-hiccup cough syncope in medullary infarction. *J Stroke Cerebrovasc Dis* 2014; 23: 566-571.
- [5] von Heinemann P, Grauer O, Schuierer G, Ritzka M, Bogdahn U, Kaiser B and Schlaichetzki F. Recurrent cardiac arrest caused by lateral medulla oblongata infarction. *BMJ Case Rep* 2009; 2009: bcr02.2009.1625.
- [6] Lee SW, Lee H, Yoo J, Kim J and Lim KB. Sick sinus syndrome combined with Wallenberg syndrome: a case report. *Brain Neurorehabil* 2021; 14: e27.
- [7] Semelka M, Gera J and Usman S. Sick sinus syndrome: a review. *Am Fam Physician* 2013; 87: 691-696.
- [8] Goldstein DS. The electrocardiogram in stroke: relationship to pathophysiological type and comparison with prior tracings. *Stroke* 1979; 10: 253-259.
- [9] Fernández-Menéndez S, García-Santiago R, Vega-Primo A, González Nafría N, Lara-Lezama LB, Redondo-Robles L, Montes-Montes M, Riveira-Rodríguez MC and Tejada-García J. Cardiac arrhythmias in stroke unit patients. Evaluation of the cardiac monitoring data. *Neurologia* 2016; 31: 289-295.
- [10] Kallmünzer B, Breuer L, Kahl N, Bobinger T, Raaz-Schrauder D, Huttner HB, Schwab S and Köhrmann M. Serious cardiac arrhythmias after stroke: incidence, time course, and predictors—a systematic, prospective analysis. *Stroke* 2012; 43: 2892-2897.
- [11] Tahsili-Fahadan P and Geocadin RG. Heart-brain axis: effects of neurologic injury on cardiovascular function. *Circ Res* 2017; 120: 559-572.
- [12] Koay S and Dewan B. An unexpected Holter monitor result: multiple sinus arrests in a patient with lateral medullary syndrome. *BMJ Case Rep* 2013; 2013: bcr2012007783.
- [13] Sposato LA, Hilz MJ, Aspberg S, Murthy SB, Bahit MC, Hsieh CY, Sheppard MN and Scheitz JF; World Stroke Organisation Brain & Heart Task Force. Post-stroke cardiovascular complications and neurogenic cardiac injury: JACC state-of-the-art review. *J Am Coll Cardiol* 2020; 76: 2768-2785.
- [14] Makhaly S, Fallah P and Giannetti N. Elevated intracranial pressure as a cause of sick sinus syndrome. *Case Rep Cardiol* 2018; 2018: 5015840.