

Cytokine and chemokine profiles in ulcerative colitis relapse after coronavirus disease 2019 vaccination

Yasuhiro Masuta, Kosuke Minaga, Yasuo Otsuka, Natsuki Okai, Akane Hara, Sho Masaki, Tomoyuki Nagai, Hajime Honjo, Masatoshi Kudo, and Tomohiro Watanabe*

Department of Gastroenterology and Hepatology, Kindai University Faculty of Medicine, 377-2 Ohno-Higashi, Osaka-Sayama, Osaka 589-8511, Japan

(Received 24 April, 2023; Accepted 12 July, 2023; Released online in J-STAGE as advance publication 16 September, 2023)

Coronavirus disease 2019 (COVID-19) vaccines are highly effective; however, vaccine-related adverse events, including autoimmunity, have been reported. Case reports describing relapse or new-onset of ulcerative colitis (UC) after COVID-19 mRNA vaccination are available. However, the molecular mechanisms underlying the development of colonic inflammation associated with COVID-19 mRNA vaccination are poorly understood. Furthermore, it is unclear whether the relapse of UC after COVID-19 vaccination is driven by unique cytokine responses that differ from those of UC not associated with vaccination. mRNAs derived from COVID-19 vaccines are potent inducers of type I IFN response. We encountered three cases of UC relapse after COVID-19 vaccination. mRNA expressions of IFN- α , IFN- β , IL-1 β , and IL-12/23p40 showed higher tendency in the colonic mucosa of patients with UC associated with vaccination compared with those not associated with vaccination. In contrast, the expressions of C-X-C motif chemokine ligand 9 (CXCL9) and CXCL10 were comparable. Immunofluorescence analyses also showed higher expression of IFN- α in the colonic mucosa of patients with UC associated with COVID-19 vaccination than in those not associated with vaccination. Taken together, these data suggest that the colonic mucosa of patients with UC who relapsed after COVID-19 vaccination was characterized by enhanced type I IFN responses.

Key Words: ulcerative colitis, COVID-19 vaccination, type I IFN, IL-6, CXCL10

Coronavirus disease 2019 (COVID-19) vaccines (BNT162b2 and mRNA-1273) were produced using mRNA-based novel technologies.⁽¹⁻³⁾ The rapid development and production of these mRNA-based vaccines have successfully decreased the number of deaths and severe illnesses associated with severe acute respiratory syndrome coronavirus 2 (SARS-CoV-2) infection. Immunization with these COVID-19 mRNA vaccines is strongly recommended because of their safety and efficacy. A two-dose regimen of BNT162b2 and mRNA-1273 showed approximately 95% protection against COVID-19-related severe illness and death.^(2,3) Although patients with inflammatory bowel disease (IBD) treated with infliximab or tofacitinib display reduced production of antibodies (Abs) against SARS-CoV-2, rates of infections and hospitalizations are comparable between the general populations and patients with IBD.⁽⁴⁻⁶⁾ Therefore, patients with IBD are strongly recommended to receive immunization with these mRNA vaccines for protection against SARS-CoV-2 infection.

Much attention has been paid to the adverse events caused by these mRNA-based COVID-19 vaccines. The major adverse events include fever, headache, myalgia, and general fatigue.⁽⁷⁾

However, recent studies have reported cases of new-onset or flare-ups of autoimmune disorders after immunization with COVID-19 vaccines.⁽⁷⁾ New-onset or flare-up autoimmune hepatitis, systemic lupus erythematosus (SLE), rheumatoid arthritis, and adult-onset Still's disease after immunization with COVID-19 vaccines have been reported.⁽⁸⁻¹⁷⁾ In line with these case reports, studies have reported patients with new-onset or flare-up ulcerative colitis (UC) after COVID-19 mRNA vaccination.^(18,19) Whether such occurrence of autoimmunity is coincidental or caused by vaccination against SARS-CoV-2 is unclear; however, Irure-Ventura *et al.*⁽²⁰⁾ reported an increase in the development of antineutrophil cytoplasmic Abs-associated vasculitis in 2021 (after COVID-19 vaccination) in comparison with that in 2019. Thus, we speculate that administering COVID-19 mRNA vaccines may trigger the development of immune disorders, including UC.

Upon entry into cells, single-stranded RNA (ssRNA) and double-stranded RNA (dsRNA) derived from COVID-19 mRNA vaccines are recognized by toll-like receptor 3 (TLR3), TLR7, TLR8, retinoic acid-inducible gene-I (RIG-I), and melanoma differentiation-associated gene 5 (MDA5).^(7,21) These pattern recognition receptors (PRRs) are well-established inducers of type I IFN and pro-inflammatory cytokine responses.^(7,21) We encountered a case of UC relapse after COVID-19 vaccination, characterized by enhanced serum type I IFN and IL-6 responses.⁽¹⁸⁾ Pro-inflammatory cytokine responses triggered by PRR activation underlie the immunopathogenesis of UC.⁽²²⁾ In addition, the induction of type I IFN responses followed by a robust expression of IFN-stimulated genes (ISGs) play pathogenic roles in the development of experimental colitis and human UC.⁽²³⁻²⁵⁾ Since mRNA vaccination is a strong inducer of type I IFN responses, it is likely that type I IFNs act together with pro-inflammatory cytokines to cause colonic inflammation. COVID-19 vaccination has not been considered to increase the rate of UC exacerbation;^(26,27) however, robust type I IFN responses induced by vaccination might worsen the disease. Therefore, we investigated the cytokine and chemokine responses in the colon of three patients with UC relapse after COVID-19 vaccination by focusing on type I IFN responses compared with those with UC relapse independent of vaccination.

*To whom correspondence should be addressed.
E-mail: tomohiro@med.kindai.ac.jp

Table 1. Clinical characteristics of patients with COVID-19 vaccination-associated ulcerative colitis

| Case | Age/Sex | Disease type | Time from vaccination to flare-up | Symptoms | Endoscopic findings | Biopsy site | Pathological findings |
|------|---------|--------------------|-----------------------------------|--|--|------------------|--|
| 1 | 25 F | Pancolitis | 4 days | Abdominal pain, diarrhea, bloody stool | Invisible vascular networks, erosions | Transverse colon | Infiltration of immune cells, crypt abscess |
| 2 | 38 F | Left sided colitis | 3 days | Abdominal pain, diarrhea, bloody stool | Invisible vascular networks, erosions | Descending colon | Infiltration of immune cells, loss of goblet cells |
| 3 | 42 F | Left sided colitis | 3–4 days | Bloody stool | Invisible vascular networks, ulcerations, erosions | Rectum | Infiltration of immune cells, loss of goblet cells, erosions |

Materials and Methods

Patients with active UC associated with COVID-19 vaccination. According to previous case reports, new onset or flare-up of autoimmune disorders associated with COVID-19 vaccination usually occurs within 2 weeks after the vaccination.^(8–17) In this study, we defined UC flare-ups after COVID-19 vaccination as exacerbation of UC-associated symptoms and UC aggravation based on endoscopic findings observed within 2 weeks after the final vaccination. We report three cases of UC flare-ups after COVID-19 vaccination. The clinical characteristics of the patients are summarized in Table 1. Endoscopic disease activity was assessed based on Mayo endoscopic subscore (MES) in accordance with previous reports.^(28,29) Histological disease activity for UC was evaluated using Nancy histological index.^(30,31)

Ethics approval statement. Ethical permission for this study was granted by the Review Boards of Kindai University Faculty of Medicine (approval No.: 28-034). Written informed consent was obtained from each patient.

Case reports for UC flare-up after COVID-19 vaccination.
Case 1: A 25-year-old woman presented with watery diarrhea, bloody stools, and abdominal pain. She received the first dose of the COVID-19 vaccine (BNT162b2, BioNTech-Pfizer) 4 days before the onset of symptoms. She was diagnosed with UC at age 12, and complete remission has been maintained without medication since then. Blood examination results were unremarkable, except for elevated serum C-reactive protein (CRP) levels (1.71 mg/dl, normal range <0.14). During colonoscopy, the disappearance of vascular networks, edema, redness, and erosions was observed in the rectum, transverse colon, and cecum. Pathological examination of the endoscopic biopsy specimens revealed infiltration of immune cells and crypt abscesses. These endoscopic and pathological findings were consistent with those of active UC, and the patient was treated with 5-aminosalicylic acid (5-ASA, 4,800 mg/day). Symptom relief was achieved 2 weeks after 5-ASA treatment, and she received a second dose of the COVID-19 vaccine without UC exacerbation.

Case 2: A 38-year-old woman presented with abdominal pain, diarrhea, and bloody stools. She was diagnosed with UC at 36 years of age and was initially treated with prednisolone for induction of remission. She was treated with 5-ASA (2,400 mg/day) and azathioprine (AZA, 50 mg/day) for UC a year ago and achieved complete remission. She received the first and second COVID-19 vaccine doses (BNT162b2) 11 and 10 months before symptom onset, respectively. She received a third dose of the COVID-19 vaccine (BNT162b2) 3 days before symptom onset. She developed watery diarrhea, bloody stools, and abdominal pain. Leukocytosis (15,450/ μ l, normal range; 3,300–8,600) accompanied by a marked elevation of CRP levels (12.7 mg/dl) and hypoalbuminemia (2.9 g/dl, normal range; 4.1–5.1) were noted in her blood examination results. Colonoscopy

revealed multiple erosions and invisible vascular networks in the rectum, sigmoid colon, and transverse colon. Pathological examination revealed a loss of goblet cells and infiltration of immune cells into the lamina propria. She was diagnosed with UC flare-ups based on endoscopic and pathological findings. She was treated with increased doses of 5-ASA (4,800 mg/day). Symptom relief and a reduction in CRP levels were observed after the escalation of 5-ASA therapy.

Case 3: A 42-year-old woman treated with AZA (100 mg/day) to maintain UC remission developed bloody stool 3 or 4 days after the first dose of the COVID-19 vaccine (BNT162b2). She was initially treated with intrarectal budesonide (4 mg/day), which decreased the frequency of bloody stools. Subsequently, she received a second dose of the COVID-19 vaccine (BNT162b2), which increased the frequency of bloody stools. Blood examination revealed mild anemia (red blood cell counts, 292×10^4 /ml; normal range, 435 – 555×10^4 ; hemoglobin, 9.3 g/dl; normal range, 13.7–16.8; hematocrit, 28.6%; normal range, 40.7–50.1) and elevated CRP levels (3.94 mg/dl). Ulcerations, erosions, and loss of vascular networks were observed in the rectum, sigmoid, and descending colons. Loss of goblet cells, accumulation of granulocytes in the lamina propria, and mucosal erosion were observed in colonic biopsy specimens. These endoscopic and pathological findings were consistent with those of active UC. Neither oral administration of prednisolone (30 mg/day) nor intravenous administration of ustekinumab (260 mg) or infliximab (5 mg/kg) achieved induction of remission. She underwent colectomy. As presented in Table 1, the clinical manifestations of UC flare-ups after COVID-19 vaccination, including endoscopic and pathological findings, were indistinguishable from those not associated with vaccination.⁽³²⁾

Patients with active UC not associated with COVID-19 vaccination. Ten patients with active UC not associated with COVID-19 vaccination were also recruited. These patients were regarded as patients with COVID-19 vaccine-non-associated UC. Endoscopic biopsy samples from patients with COVID-19 vaccine-non-associated UC were obtained from April 14, 2015, to February 7, 2021, when none could receive COVID-19 vaccination. Active UC was diagnosed based on endoscopic and pathological findings as previously described.^(33,34) UC relapse was defined as aggravation of UC-associated symptoms and UC aggravation based on endoscopic findings.^(28,29) Endoscopic and histological disease activities were assessed by MES and Nancy histological index, respectively. The clinical characteristics of the patients with active UC not associated with COVID-19 vaccination are summarized in Table 2. Ethical approval for this study was obtained from the Review Board of Kindai University Faculty of Medicine, and written informed consent was obtained from each patient.

Healthy colonic mucosa samples. Biopsy samples were obtained from non-tumorous portions of colonic adenoma. Four

Table 2. Clinical characteristics of patients with COVID-19 vaccination-non-associated ulcerative colitis

| Case | Age/Sex | Disease type | Medication | Endoscopic findings | Biopsy site | Pathological findings |
|------|---------|--------------------|---|--|------------------|---|
| 1 | 60 F | Left sided colitis | 5-ASA, $\alpha 4 \beta 7$ integrin antibody | Invisible vascular networks, ulcerations, bleeding | Sigmoid colon | Infiltration of immune cells, crypt abscess |
| 2 | 29 F | Pancolitis | TNF-alpha inhibitor | Invisible vascular networks, ulcerations, bleeding | Rectum | Infiltration of immune cells, ulcerations |
| 3 | 49 M | Pancolitis | 5-ASA | Invisible vascular networks, erosions, bleeding | Rectum | Infiltration of immune cells |
| 4 | 50 F | Pancolitis | 5-ASA | Invisible vascular networks, erosions | Descending colon | Infiltration of immune cells, crypt abscess |
| 5 | 78 F | Pancolitis | 5-ASA | Invisible vascular networks, ulcerations, bleeding | Sigmoid colon | Infiltration of immune cells, erosions |
| 6 | 45 F | Pancolitis | 5-ASA | Invisible vascular networks, erosions | Ascending colon | Infiltration of immune cells |
| 7 | 79 M | Pancolitis | Prednisolone, 5-ASA | Invisible vascular networks, ulcerations, bleeding | Transverse colon | Infiltration of immune cells, crypt abscess |
| 8 | 60 M | Pancolitis | Prednisolone, 5-ASA | Invisible vascular networks, ulcerations, bleeding | Sigmoid colon | Infiltration of immune cells, crypt abscess, erosions |
| 9 | 27 M | Pancolitis | 5-ASA | Invisible vascular networks, ulcerations, bleeding | Sigmoid colon | Infiltration of immune cells, erosions |
| 10 | 42 F | Pancolitis | 5-ASA | Invisible vascular networks, erosions | Transverse colon | Infiltration of immune cells, crypt abscess, erosions |

patients with colonic adenoma were recruited in this study, including a 55-years old male, a 57-year-old male, a 70-year-old female, and a 68-year-old male. Biopsy samples were obtained from the descending colon ($n = 1$), cecum ($n = 2$), and rectum ($n = 1$).

Quantitative reverse transcription-polymerase chain reaction (qPCR). Colonic biopsy samples were obtained during endoscopy and subjected to qPCR as previously described.^(24,34,35) qPCR analyses were performed using Quantitect primer assays (Qiagen, Valencia, CA). Primers for the target genes were purchased from Qiagen, and SYBR Green-based qPCR was performed using a LightCycler 480 system (Roche, Tokyo, Japan). *Actin* mRNA expression was used as the reference gene. Non-tumor portions of the colonic mucosa from patients with colon adenoma ($n = 4$) were considered as healthy colonic mucosa.

Immunofluorescence analyses. Deparaffinized formalin-fixed samples were subjected to immunofluorescence analysis as described previously.⁽³⁶⁾ Samples were incubated with primary Abs, including mouse anti-IL-6 Ab (Abcam, Cambridge, UK), FITC-conjugated rat anti-IFN- α Ab (Miltenyi Biotec, Auburn, CA), and rabbit anti-TLR7 Ab (Abcam), and incubated with secondary Alexa 488- or Alexa 546-conjugated rabbit or mouse IgG (Invitrogen, Carlsbad, CA). Immunofluorescence images were obtained (Biozero BZ-8100, Keyence, Osaka, Japan), and the number of stained cells was calculated as previously described.^(33,37)

Statistical analyses. Statistical analysis was performed using GraphPad Prism (GraphPad Software, San Diego, CA), as previously reported.⁽³⁸⁾ Differences between the two groups were assessed using the Mann–Whitney *U* test, a nonparametric version of the unpaired *t* test. Differences between multiple comparisons were assessed using Kruskal–Wallis test, a nonparametric version of the one-way analysis of variance. For post-hoc analysis, the Bonferroni-corrected Mann–Whitney *U* test was performed for comparison between the two groups. The effects were considered statistically significant at $p < 0.05$.

Results

Distribution of MES and Nancy histological index in patients with UC flare-ups after COVID-19 vaccination. We initially examined whether UC flare-ups after COVID-19 vaccination differed from UC flare-ups non-associated with COVID-19 vaccination based on endoscopic and histological disease activity. MES and Nancy histological index were used for evaluation of endoscopic and histologic disease activity, respectively. As shown in Fig. 1, a similar distribution pattern of disease activity was observed between patients with COVID-19 vaccination-associated UC and those with UC non-associated with COVID-19 vaccination. Our findings suggest no significant difference in disease activity between the two patient populations.

Cytokine and chemokine responses in patients with UC flare-ups after COVID-19 vaccination. Pro-inflammatory cytokines, including IL-1 β , IL-6, IL-12, IL-23, and TNF- α , underlie the immunopathogenesis of UC.^(22,39) We initially measured the mRNA expression of these cytokines in the colonic mucosa of patients with UC flare-ups with or without COVID-19 vaccination, as previously described.^(24,34) The mRNA expression in the non-tumor portions of patients with colon adenoma served as samples of healthy colonic mucosa. As shown in Fig. 2 (please note that the y-axis is a log₁₀ scale), the mRNA expression of IL-1 β , IL-6, and TNF- α was higher in active UC mucosa than in healthy colonic mucosa, irrespective of the COVID-19 vaccination status. No statistically significant difference between healthy colonic mucosa and active UC mucosa associated with vaccination was observed because of the limited number of samples in the latter group. The mRNA expression of IL-12/23p40 was higher in the active colonic mucosa of patients with UC flare-ups associated with COVID-19 vaccination than in those not associated with vaccination. Thus, the colonic mucosa of patients with UC showed enhanced expression of IL-1 β , IL-6, and TNF- α , irrespective of the COVID-19 vaccination status.

RNAs derived from COVID-19 vaccines are sensed by PRRs, and they promote type I IFN responses.^(7,21) In this study, we focused on the expression of type I IFNs. The expression of IFN-

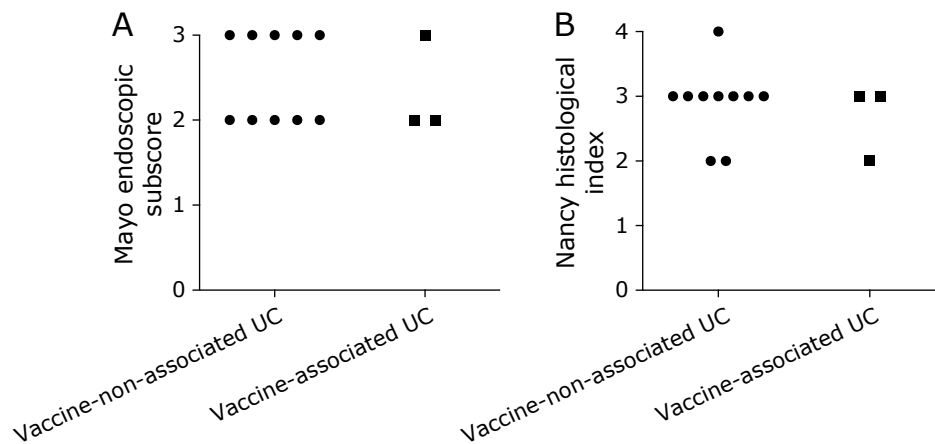


Fig. 1. Distribution of Mayo endoscopic subscore and Nancy histological index in patients with ulcerative colitis (UC) associated with COVID-19 vaccination. Mayo endoscopic subscore (A) and Nancy histological index (B) were determined in patients with UC associated with COVID-19 vaccination ($n = 3$) and those not associated with COVID-19 vaccination ($n = 10$).

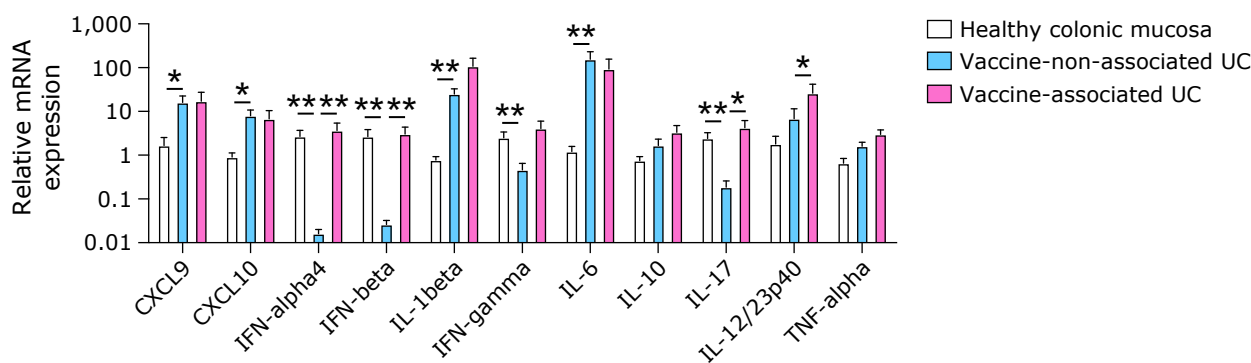


Fig. 2. mRNA expression of cytokines and chemokines in the colonic mucosa of patients with ulcerative colitis (UC) associated with COVID-19 vaccination. mRNA was isolated from the colonic mucosa of patients with UC associated with COVID-19 vaccination ($n = 3$) and those not associated with COVID-19 vaccination ($n = 10$). Non-tumorous portions of the colonic mucosa in patients with colonic adenomas served as healthy colonic mucosa ($n = 4$). CXCL9, C-X-C motif chemokine ligand 9; CXCL10, C-X-C motif chemokine ligand 10. Results are expressed as mean \pm SE. * $p < 0.05$, ** $p < 0.01$.

$\alpha 4$ and IFN- β was higher in the colonic mucosa of patients with UC associated with COVID-19 vaccination than in those without the COVID-19 vaccination. C-X-C motif chemokine ligand 9 (CXCL9) and CXCL10 are T helper type 1 chemokines whose expression is driven by type I IFN and TNF- α .^(24,40) The expression of CXCL9 and CXCL10 was higher in the colonic mucosa of patients with UC, irrespective of COVID-19 vaccination status, than in healthy colonic mucosa. The expression of type I and type II IFNs (IFN- $\alpha 4$, IFN- β , and IFN- γ) was higher in the colonic mucosa of patients with UC associated with COVID-19 vaccination and healthy controls than in patients with UC not associated with COVID-19 vaccination. Notably, the expression of IFNs was higher in the colonic mucosa of patients with UC associated with COVID-19 vaccination than in those of healthy colonic mucosa, although not statistically significant. Overall, these chemokine and cytokine analyses revealed that pro-inflammatory and type I IFN responses were enhanced in the colonic mucosa of patients with UC associated with COVID-19 vaccination.

Expression of IL-10 and forkhead box p3 in patients with UC flare-ups after COVID-19 vaccination. Regulatory T cells (Tregs) expressing forkhead box p3 (FOXP3) contribute to maintaining intestinal homeostasis.⁽⁴¹⁾ IL-10 is a prototypical anti-inflammatory cytokine produced by Tregs.^(35,41) To examine the involvement of Treg activation, the mRNA expression levels

of IL-10 and FOXP3 were determined. As shown in Fig. 2 and 3 (please note that the y-axis is a log10 scale), the expression of FOXP3 and IL-10 was higher in the colonic mucosa of patients with UC associated with COVID-19 vaccination than in those not associated with COVID-19 vaccination or in healthy controls, although the difference was not significant. Thus, the colonic mucosa of patients with UC associated with COVID-19 vaccination was characterized by pro-inflammatory cytokine, type I IFNs, and Treg responses.

Expression of PRRs in patients with UC flare-ups after COVID-19 vaccination. PRRs recognize dsRNA and ssRNA derived from COVID-19 vaccines.^(7,21) MDA5/RIG-I and TLR3/7/8/9 are cytosolic and endoplasmic PRRs for sensing RNAs.^(7,21) Consistent with the reduced type I IFN responses in patients with UC flare-ups not associated with COVID-19 vaccination, TLR7 expression was lower in this group than in the other groups (Fig. 3). Comparable expression levels of these PRRs except for TLR3 were observed in healthy colonic mucosa and active colonic mucosa of patients with UC flares-ups associated with COVID-19 vaccination (Fig. 3). TLR7 expression was higher in the active colonic mucosa of patients with UC flare-up associated with COVID-19 vaccination than in those not associated with vaccination, whereas expression of TLR3 and TLR9 was comparable in both groups.

The expression of signaling molecules associated with type I

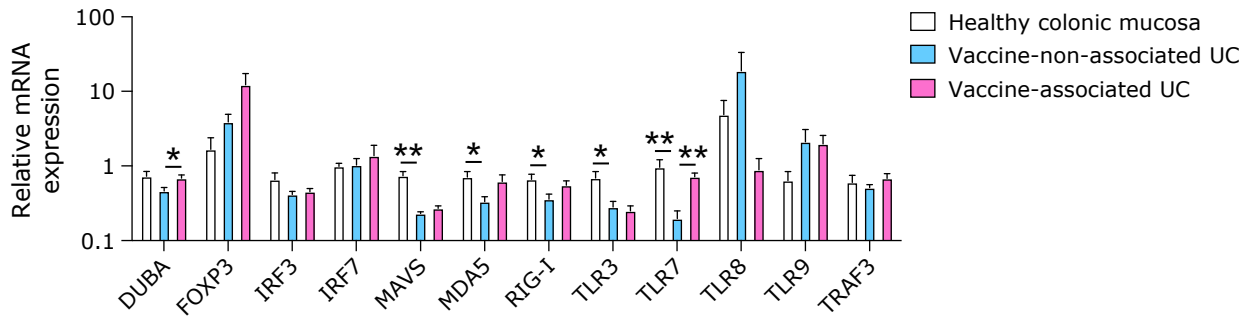


Fig. 3. mRNA expression of molecules associated with type I IFNs and regulatory T cells in the colonic mucosa of patients with ulcerative colitis (UC) associated with COVID-19 vaccination. mRNA was isolated from the colonic mucosa of patients with UC associated with COVID-19 vaccination ($n = 3$) and those not associated with COVID-19 vaccination ($n = 10$). Non-tumorous portions of the colonic mucosa in patients with colonic adenomas served as healthy colonic mucosa ($n = 4$). DUBA, deubiquitinating enzyme A; IRF3, IFN regulatory factor 3; MAVS, mitochondrial antiviral signaling; MDA5, melanoma differentiation-associated gene 5; RIG-I, retinoic acid-inducible gene-I; TLR3, toll-like receptor 3; TRAF3, TNF receptor-associated factor 3. Results were expressed as mean \pm SE. * $p < 0.05$, ** $p < 0.01$.

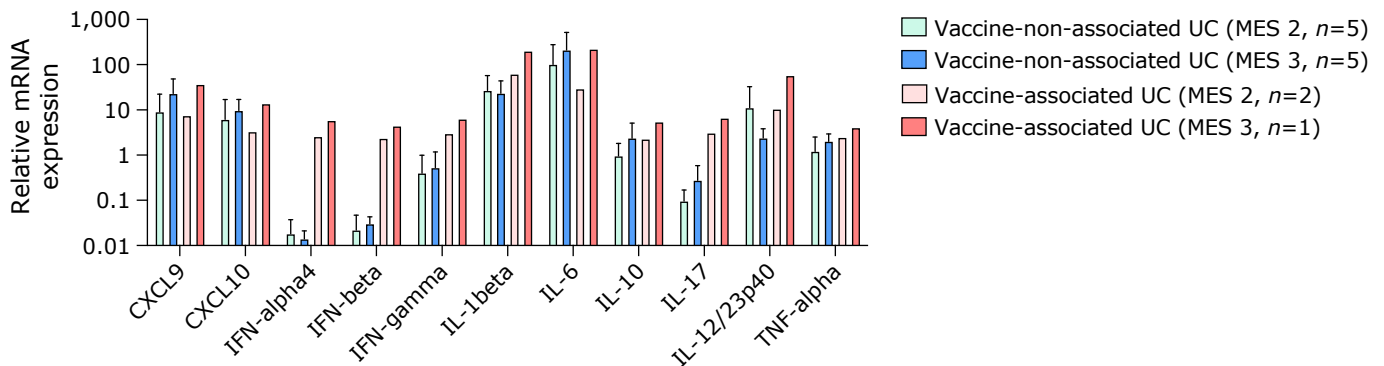


Fig. 4. mRNA expression of cytokines and chemokines in the colonic mucosa of patients with ulcerative colitis (UC) associated with or without COVID-19 vaccination based on Mayo endoscopic subscore. mRNA was isolated from the colonic mucosa of patients with UC associated with COVID-19 vaccination ($n = 3$) and those not associated with COVID-19 vaccination ($n = 10$). Patients with vaccine-non-associated UC included five cases with Mayo endoscopic subscore 2 (MES 2) and five cases with MES 3. Vaccine-associated UC patients include two cases with MES 2 and one case with MES 3. CXCL9, C-X-C motif chemokine ligand 9; CXCL10, C-X-C motif chemokine ligand 10. Results are expressed as mean \pm SE.

IFN response was examined. No significant differences in the expression of mitochondrial antiviral signaling (MAVS), TNF receptor-associated factor 3 (TRAF3), IFN regulatory factor 3 (IRF3), or IRF7 were observed in the colonic mucosa of patients with UC with or without COVID-19 vaccination. In contrast, the expression of deubiquitinating enzyme A (DUBA), a negative regulator of type I IFN responses,⁽²⁴⁾ was significantly higher in the colonic mucosa of patients with UC associated with COVID-19 vaccination than in those not associated with COVID-19 vaccination.

Relationship between cytokine responses and endoscopic disease activity in patients with UC flare-ups with or without COVID-19 vaccination. Expression of some pro-inflammatory cytokines and chemokines correlates to endoscopic disease activity.^(28,29) We analyzed mRNA expression of cytokines and chemokines based on MES. We could not perform statistical analyses since three UC flare-up patients were judged as MES 2 ($n = 2$) and MES 3 ($n = 1$). However, we observed much higher expression of IFN- α 4, IFN- β , and TLR7 in the colonic mucosa of patients with UC flare-ups associated with COVID-19 vaccination than those non-associated with vaccination, irrespective of the MES grade (Fig. 4 and 5).

No significant difference in mRNA expression of cytokines and chemokines was observed in patients with UC flare-ups non-associated with COVID-19 vaccination based on MES. The small number of UC cases with MES 2 ($n = 5$) and MES 3

($n = 5$) likely contributed to the lack of significant differences in cytokine or chemokine mRNA expression. However, mRNA expression of DUBA, TRAF3, TLR7, and TLR9 was significantly higher in patients with UC flare-ups non-associated with vaccination with MES 3 than in those with MES 2 (Fig. 5).

Protein expression of IL-6 and IFN- α in patients with UC flare-ups after COVID-19 vaccination. Having found that the colonic mucosa of patients with UC flare-ups associated with COVID-19 vaccination is characterized by pro-inflammatory cytokines and type I IFN responses, we examined the protein expression of IFN- α , IL-6, and TLR7. For this purpose, colonic biopsy samples were subjected to immunofluorescence analyses. Consistent with qPCR data, the protein expression of IFN- α was higher in patients with UC flare-ups associated with COVID-19 vaccination than in those not associated with COVID-19 vaccination (Fig. 6A). In contrast, IL-6 expression was higher in patients with UC flare-ups not associated with COVID-19 vaccination than in those with UC flare-ups associated with vaccination. Semi-quantitative assessment by counting immunoreactive cells in the high-power field also showed that the proportion of cells positive for IFN- α was higher in the active colonic mucosa of patients with vaccine-associated UC than in those with vaccine-non-associated UC, whereas the proportion of cells positive for IL-6 was lower in patients with UC associated with vaccination than in those not associated with vaccination (Fig. 6B). Furthermore, TLR7 co-localized with IFN- α in the colonic lamina

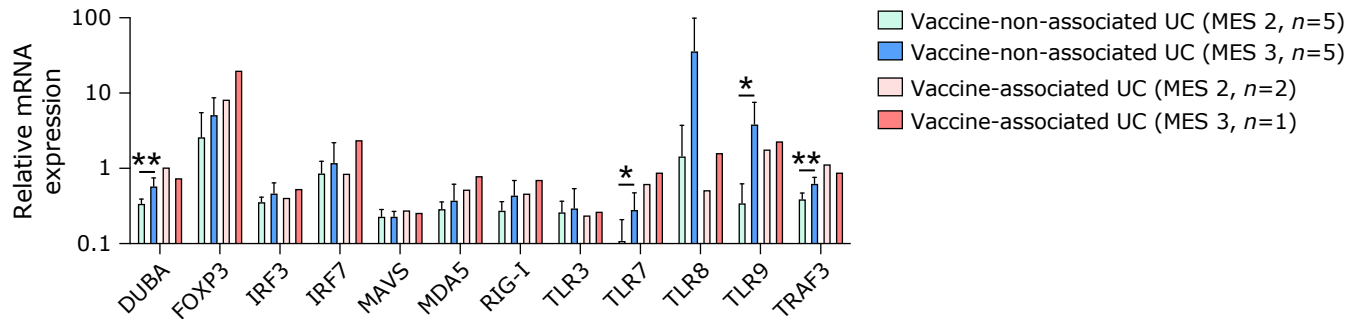


Fig. 5. mRNA expression of molecules associated with type I IFNs and regulatory T cells in the colonic mucosa of patients with ulcerative colitis (UC) associated with or without COVID-19 vaccination based on Mayo endoscopic subscore. mRNA was isolated from the colonic mucosa of patients with UC associated with COVID-19 vaccination ($n = 3$) and those not associated with COVID-19 vaccination ($n = 10$). Patients with vaccine-non-associated UC include five cases with Mayo endoscopic subscore 2 (MES 2) and five cases with MES 3. Vaccine-associated UC patients include two cases with MES 2 and one case with MES 3. DUBA, deubiquitinating enzyme A; IRF3, IFN regulatory factor 3; MAVS, mitochondrial antiviral signaling; MDA5, melanoma differentiation-associated gene 5; RIG-1, retinoic acid-inducible gene-1; TLR3, toll-like receptor 3; TRAF3, TNF receptor-associated factor 3. Results are expressed as mean \pm SE. * $p < 0.05$, ** $p < 0.01$.

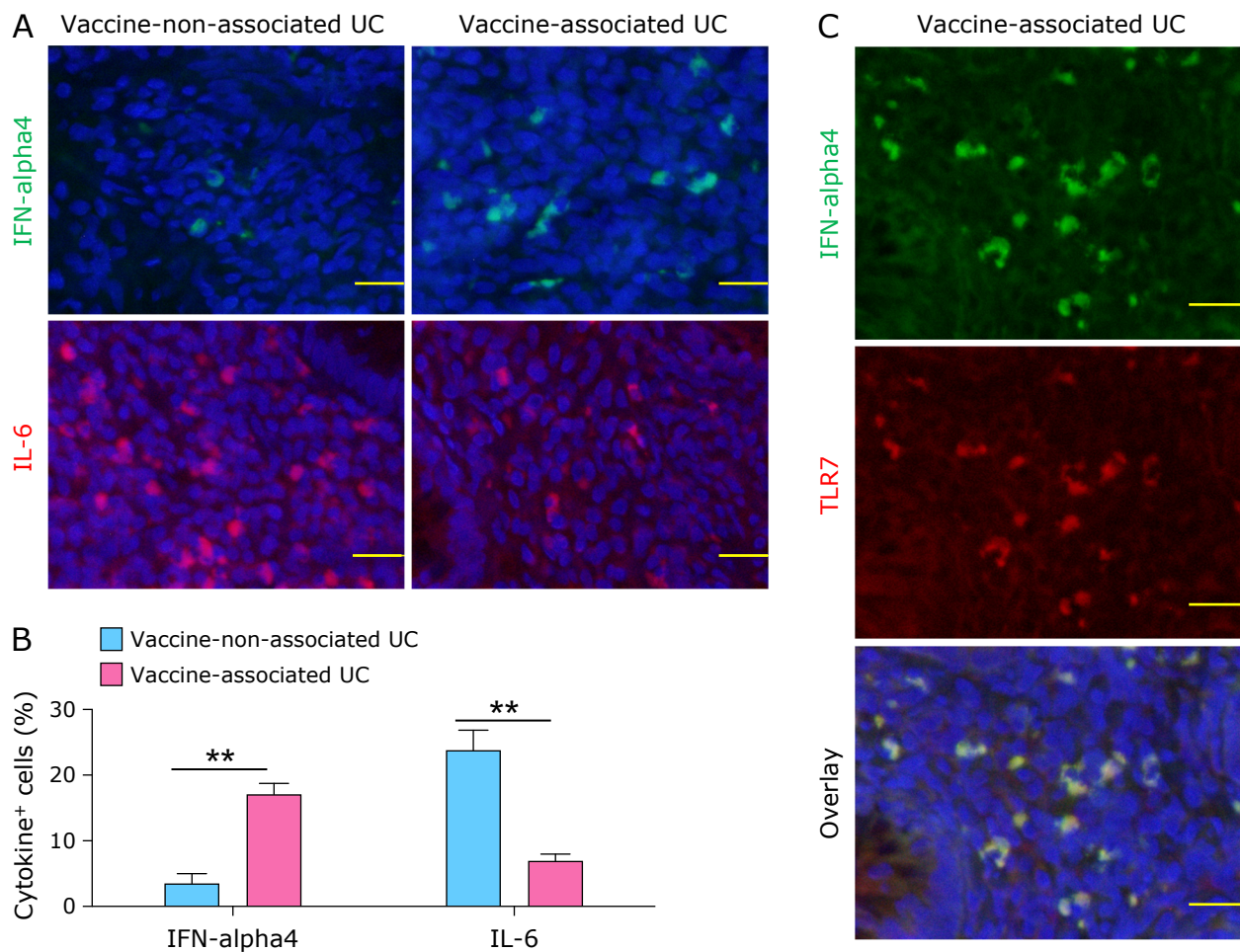


Fig. 6. Expression of IFN- α , IL-6, and TLR7 in the colonic mucosa of patients with ulcerative colitis (UC) associated with COVID-19 vaccination. Expression of IFN- α , IL-6, and TLR7 was examined by immunofluorescence analyses using colonic biopsy samples obtained from patients with UC associated with COVID-19 vaccination ($n = 3$) and those not associated with COVID-19 vaccination ($n = 3$). (A) Representative immunofluorescence photomicrograph of patient tissue stained with anti-IFN- α Ab (green color) or anti-IL-6 Ab (red color). Nuclei were counter-stained with DAPI. Scale bar: 20 μ m. (B) The number of cells positive for IFN- α or IL-6 was determined by counting in a high-power field and is shown as the percentage of total DAPI-positive mononuclear cells. (C) Representative immunofluorescence photomicrograph of patient tissue stained with anti-IFN- α Ab (green color) and anti-TLR7 Ab (red color). Nuclei were counter-stained with DAPI. Scale bar; 20 μ m. Results are expressed as mean \pm SE. ** $p < 0.01$. See color figure in the on-line version.

propria mononuclear cells of patients with vaccine-associated UC flare-ups (Fig. 6C). Collectively, these qPCR and immunofluorescence analyses strongly suggest that UC flare-ups associated with COVID-19 vaccination are distinctive from those not associated with COVID-19 vaccination with respect to type I IFN responses; enhanced type I IFN responses were observed in the former.

Discussion

Two types of COVID-19 mRNA vaccines, BNT162b2 mRNA COVID-19 vaccine and mRNA SARS-CoV-2 1273 vaccine, are widely used because of their high efficacy in preventing severe COVID-19.^(2,3) However, immunization with these mRNA vaccines is accompanied by various adverse events.^(7,21) In addition to acute adverse events, much attention is paid to the late-onset side effects of vaccination. New onset or relapse of autoimmunity after COVID-19 vaccination has been reported.^(8–17) We recently encountered a case of UC relapse after COVID-19 vaccination characterized by systemic type I IFN and IL-6 responses.⁽¹⁸⁾ Thus, UC relapse after COVID-19 vaccination may be different from UC relapse not associated with COVID-19 vaccination; the latter is driven by prototypical inflammatory cytokines, such as TNF- α , IL-6, IL-12, and IL-23, whereas the former is characterized by pro-inflammatory cytokines and type I IFNs.⁽²²⁾ To explore this possibility, we compared the mRNA and protein expression levels of cytokines and chemokines by qPCR and immunofluorescence analyses. We provided evidence that IL-6, TNF- α , and type I IFNs are involved in UC flare-ups after COVID-19 vaccination. Considering the robust induction of type I IFNs via PRR-mediated recognition of mRNAs derived from COVID-19 vaccines, immunization with the COVID-19 vaccine is likely causative rather than coincidental in the development of UC flare-ups. However, profiles of cytokines and chemokines in the colonic mucosa were determined using samples from three patients with UC flare-ups after COVID-19 vaccination. Thus, the sample size was too small to conclude that the colonic mucosa of patients with UC flare-ups after COVID-19 vaccination is characterized by type I IFN responses. Therefore, further studies addressing cytokine responses in many UC patients with or without relapse after COVID-19 vaccination are needed to verify these findings.

Type I IFNs play both protective and pathogenic roles in the development of UC.⁽⁴²⁾ ISG expression was upregulated and downregulated in the colonic mucosa during the active and remission phases of UC, respectively.^(23,24) In addition, cases of UC flare-ups after the administration of type I IFNs against chronic hepatitis C virus infections have been reported.⁽⁴³⁾ On the other hand, the beneficial roles of type I IFNs have been highlighted by clinical trials in which a significant population of patients with UC was successfully treated with type I IFNs.^(44,45) Thus, both beneficial and pathogenic roles for type I IFNs have been reported. mRNA expression of IFN- α 4 and IFN- β were elevated in the colonic mucosa of patients with UC flare-ups after COVID-19 vaccination compared with those not associated with vaccination. In addition, COVID-19 vaccination increased the colonic expression of ISGs, including DUBA and TLR7, suggesting that type I IFN responses and the induction of ISG expression might mediate the exacerbation of UC after COVID-19 vaccination. As expected, the mRNA expression of prototypical proinflammatory cytokines (IL-1 β , IL-6, IL-12/23p40, and TNF- α) and chemokines (CXCL9 and CXCL10) was higher in the colonic mucosa of patients with UC flare-ups, irrespective of the COVID-19 vaccination status, than in the healthy colonic mucosa of patients with colon adenoma. However, the mRNA expression of IL-1 β , IL-12/23p40, and TNF- α was higher in patients with UC flare-ups after COVID-19 vaccination than in those not associated with COVID-19 vaccina-

tion. One might assume that the enhanced type I IFN responses in UC flare-ups associated with vaccination were counter-regulatory mechanisms, reflecting strong IL-6 and TNF- α responses since the nuclear factor-kappa B-dependent production of IL-6 and TNF- α is reciprocally regulated by the IRF-dependent production of type I IFNs.⁽⁴⁶⁾ In this regard, we believe that the PRR-mediated production of type I IFNs upon sensing mRNAs is a primary event in UC flare-ups after COVID-19 vaccination. This notion is supported by experimental studies providing evidence that the administration of mRNA vaccine induces type I IFN-polarized innate immunity.^(47,48) Additionally, type I IFNs function as upstream cytokines that can induce the production of IL-6 and TNF- α .⁽³⁶⁾ Collectively, our cytokine and chemokine analyses of active colonic mucosa suggest that type I IFN responses triggered by COVID-19 vaccination are involved in the exacerbation of UC after vaccination. However, type I IFN responses induced by COVID-19 vaccination do not usually cause flare-ups in most UC cases. Therefore, in addition to the robust production of type I IFNs, another factor may contribute to the exacerbation of UC after COVID-19 vaccination. Identifying such risk factors requires studies addressing the colonic immune environments in patients with or without UC flare-ups who receive vaccination.

Another feature of UC flare-ups after COVID-19 vaccination is enhanced mRNA expression of FOXP3 and IL-10. Tregs expressing FOXP3 contribute to the maintenance of intestinal homeostasis through the production of IL-10.⁽⁴¹⁾ Colonic mRNA expression of IL-10 and FOXP3 tended to be higher in patients with UC associated with COVID-19 vaccination than in those not associated with vaccination. However, the molecular mechanisms underlying the enhanced expression of FOXP3 in patients with UC flare-ups after COVID-19 vaccination are not fully understood. Furthermore, type I IFNs contribute to maintaining intestinal homeostasis through the expansion and induction of Tregs expressing FOXP3.^(49–51) Therefore, the initial type I IFN responses induced by COVID-19 vaccination may lead to enhanced Treg responses. Importantly, strong expression of FOXP3 and IL-10 is unlikely to suppress colonic inflammation in patients with UC flare-ups associated with COVID-19 vaccination.

Enhanced type I IFN responses underlie the immunopathogenesis of various autoimmune disorders, especially SLE and type 1 autoimmune pancreatitis (AIP).⁽⁵²⁾ If the excessive production of type I IFNs caused by immunization with mRNA vaccines drives the development of new-onset or relapse autoimmunity, the frequency of exacerbation of SLE and type 1 AIP after vaccination would be greater than that in other autoimmune diseases. Case reports regarding new-onset or relapse of SLE and AIP are available;^(9,53–55) however, it is unclear whether immunization with the COVID-19 vaccine increases the number of type I IFN-dependent autoimmunity. The link between mRNA vaccine-induced type I IFN responses and autoimmunity requires further epidemiological and immunological analyses. In addition, cases with new-onset or flare-ups of UC triggered by SARS-CoV-2 infection have been reported.^(56–58) It would be intriguing to see the involvement of type I IFN responses in UC cases associated with SARS-CoV-2 infection.

Our clinicopathological analyses suggested that the endoscopic and pathological findings of the three cases of patients with UC flare-ups after COVID-19 vaccination were similar to those with typical UC flare-ups as assessed by MES and Nancy histological index. Although the sample size was small to draw definitive conclusions in this study, no significant differences were observed in MES or Nancy histological index between UC flare-up cases associated with COVID-19 vaccination and those not associated with vaccination. Thus, it may be difficult to distinguish between UC flare-ups associated with COVID-19 vaccination and those not associated with vaccination based on clinical

manifestations. Serum levels of IFN- β were markedly elevated in patients with UC flare-ups or new-onset rheumatoid arthritis after COVID-19 vaccination.^(14,18) Therefore, elevated serum IFN- β concentrations might be useful for the early detection of UC flare-ups after COVID-19 vaccination. Establishment of serum IFN- β concentration evaluation for diagnosing COVID-19 vaccination-associated UC requires a comparison between healthy controls and patients with UC flare-ups or non-flare-ups after vaccination.

In conclusion, the active colonic mucosa of patients with UC triggered by COVID-19 vaccination was characterized by type I IFN responses in addition to prototypical proinflammatory cytokine responses, including IL-1 β , IL-12/23p40, and TNF- α , compared with those of patients with UC not associated with COVID-19 vaccination. COVID-19 vaccination does not increase the incidence of UC exacerbation.^(26,27) However, our data show the involvement of unique cytokines profiles in the development of UC flare-ups after vaccination. Thus, we propose that UC flare-ups associated with COVID-19 vaccination are a unique type of UC with respect to pro-inflammatory cytokine and type I IFN responses. However, interpreting our findings need to be done with caution because the number of patients recruited in this study was small. We recruited three patients with COVID-19 vaccine-associated UC flare-ups and ten patients with vaccine-non-associated UC flare-ups. Further studies addressing the colonic immune environment in patients with flare-ups or new-onset UC cases with or without COVID-19 vaccination are warranted.

Author Contributions

Conceptualization: YM, KM, and TW; Methodology: YM, KM, and TW; Formal analysis and investigation: YM, KM, NO, AH, YO, SM, TN, HH, and TW; Writing - original draft preparation: YM, KM, and TW; Writing - review and editing: YM, KM, and TW; Funding acquisition: TW; Resources: SM, TN, and HH; Supervision: MK.

Acknowledgments

The authors thank Ms. Yukiko Ueno for her secretarial support.

Data Availability Statement

The data that support the findings of this study are available

References

- Sahin U, Karikó K, Türeci Ö. mRNA-based therapeutics--developing a new class of drugs. *Nat Rev Drug Discov* 2014; **13**: 759–780.
- Polack FP, Thomas SJ, Kitchin N, et al. Safety and efficacy of the BNT162b2 mRNA Covid-19 vaccine. *N Engl J Med* 2020; **383**: 2603–2615.
- Baden LR, El Sahly HM, Essink B, et al. Efficacy and safety of the mRNA-1273 SARS-CoV-2 vaccine. *N Engl J Med* 2021; **384**: 403–416.
- Alexander JL, Kennedy NA, Ibraheim H, et al. COVID-19 vaccine-induced antibody responses in immunosuppressed patients with inflammatory bowel disease (VIP): a multicentre, prospective, case-control study. *Lancet Gastroenterol Hepatol* 2022; **7**: 342–352.
- Lin S, Lau LH, Chanchlani N, Kennedy NA, Ng SC. Recent advances in clinical practice: management of inflammatory bowel disease during the COVID-19 pandemic. *Gut* 2022; **71**: 1426–1439.
- Hadi YB, Thakkar S, Shah-Khan SM, Hutson W, Sarwari A, Singh S. COVID-19 vaccination is safe and effective in patients with inflammatory bowel disease: analysis of a large multi-institutional research network in the united states. *Gastroenterology* 2021; **161**: 1336–1339.e3.
- Sprent J, King C. COVID-19 vaccine side effects: the positives about feeling bad. *Sci Immunol* 2021; **6**: eabj9256.
- Sharabi A, Shiber S, Molad Y. Adult-onset Still's disease following mRNA

upon reasonable request from the corresponding author.

Abbreviations

| | |
|------------|--|
| Ab | antibody |
| AIP | autoimmune pancreatitis |
| 5-ASA | 5-aminosalicylic acid |
| AZA | azathioprine |
| COVID-19 | coronavirus disease 2019 |
| CRP | C-reactive protein |
| CXCL | C-X-C motif chemokine ligand |
| dsRNA | double-stranded RNA |
| DUBA | deubiquitinating enzyme A |
| FOXP3 | forkhead box p3 |
| IBD | inflammatory bowel disease |
| IRF | IFN regulatory factor |
| ISG | IFN-stimulated gene |
| MAVS | mitochondrial antiviral signaling |
| MDA5 | melanoma differentiation-associated gene 5 |
| MES | Mayo endoscopic subscore |
| PRR | pattern recognition receptor |
| qPCR | quantitative reverse transcription-polymerase chain reaction |
| RIG-I | retinoic acid-inducible gene-I |
| SARS-CoV-2 | severe acute respiratory syndrome coronavirus 2 |
| SLE | systemic lupus erythematosus |
| ssRNA | single-stranded RNA |
| TLR | toll-like receptor |
| TRAF3 | TNF receptor-associated factor 3 |
| Treg | regulatory T cell |
| UC | ulcerative colitis |

Funding

This work was supported by Grants-in-Aid for Scientific Research (19K08455, 21K159857, 22K07996, and 23K15026) from the Japan Society for the Promotion of Science, Takeda Science Foundation, Smoking Research Foundation, Yakult Bio-Science Foundation, SENSHIN Medical Research Foundation, and a Kindai University Research Enhancement Grant (KD2208, KD2301).

Conflict of Interest

No potential conflicts of interest were disclosed.

- COVID-19 vaccination. *Clin Immunol* 2021; **233**: 108878.
- Sagy I, Zeller L, Raviv Y, Porges T, Bieber A, Abu-Shakra M. New-onset systemic lupus erythematosus following BNT162b2 mRNA COVID-19 vaccine: a case series and literature review. *Rheumatol Int* 2022; **42**: 2261–2266.
- Avcı E, Abasiyanik F. Autoimmune hepatitis after SARS-CoV-2 vaccine: new-onset or flare-up? *J Autoimmun* 2021; **125**: 102745.
- Palla P, Vergadis C, Sakellariou S, Androutsakos T. Letter to the editor: autoimmune hepatitis after COVID-19 vaccination: a rare adverse effect? *Hepatology* 2022; **75**: 489–490.
- Bril F, Al Diffalha S, Dean M, Fettig DM. Autoimmune hepatitis developing after coronavirus disease 2019 (COVID-19) vaccine: causality or casualty? *J Hepatol* 2021; **75**: 222–224.
- Bixio R, Bertelle D, Masia M, Pistillo F, Carletto A, Rossini M. Incidence of disease flare after BNT162b2 coronavirus disease 2019 vaccination in patients with rheumatoid arthritis in remission. *ACR Open Rheumatol* 2021; **3**: 832–833.
- Watanabe T, Minaga K, Hara A, Yoshikawa T, Kamata K, Kudo M. Case report: new-onset rheumatoid arthritis following COVID-19 vaccination. *Front Immunol* 2022; **13**: 859926.

- 15 Garrido I, Lopes S, Simões MS, *et al.* Autoimmune hepatitis after COVID-19 vaccine - more than a coincidence. *J Autoimmun* 2021; **125**: 102741.
- 16 Chen Y, Xu Z, Wang P, *et al.* New-onset autoimmune phenomena post-COVID-19 vaccination. *Immunology* 2022; **165**: 386–401.
- 17 Rodríguez Y, Rojas M, Beltrán S, *et al.* Autoimmune and autoinflammatory conditions after COVID-19 vaccination. New case reports and updated literature review. *J Autoimmun* 2022; **132**: 102898.
- 18 Masuta Y, Watanabe T, Minaga K, Kudo M. A case of ulcerative colitis relapse characterized by systemic type I interferon responses after COVID-19 vaccination. *Inflamm Bowel Dis* 2022; **28**: e110–e111.
- 19 Ak Ç, Sayar S, Adali G, Özdil K. Acute severe ulcerative colitis after mRNA coronavirus disease 2019 vaccination: Can mRNA vaccines unmask inflammatory bowel diseases? *ACG Case Rep J* 2022; **9**: e00806.
- 20 Irure-Ventura J, Belmar-Vega L, Fernández-Fresnedo G, *et al.* Increased induction of *de novo* serum ANCA and ANCA-associated vasculitis after mass vaccination against SARS-CoV-2. *iScience* 2022; **25**: 104847.
- 21 Teijaro JR, Farber DL. COVID-19 vaccines: modes of immune activation and future challenges. *Nat Rev Immunol* 2021; **21**: 195–197.
- 22 Strober W, Fuss IJ. Proinflammatory cytokines in the pathogenesis of inflammatory bowel diseases. *Gastroenterology* 2011; **140**: 1756–1767.
- 23 Samic M, Lim J, Verschuere E, *et al.* Selective autophagy of the adaptor TRIF regulates innate inflammatory signaling. *Nat Immunol* 2018; **19**: 246–254.
- 24 Masuta Y, Minaga K, Kurimoto M, *et al.* Activation of nucleotide-binding oligomerization domain 2 by muramyl dipeptide negatively regulates Toll-like receptor 9-mediated colonic inflammation through the induction of deubiquitinating enzyme A expression. *Int Immunol* 2023; **35**: 79–94.
- 25 Arimura K, Takagi H, Uto T, *et al.* Crucial role of plasmacytoid dendritic cells in the development of acute colitis through the regulation of intestinal inflammation. *Mucosal Immunol* 2017; **10**: 957–970.
- 26 James D, Jena A, Bharath PN, *et al.* Safety of SARS-CoV-2 vaccination in patients with inflammatory bowel disease: a systematic review and meta-analysis. *Dig Liver Dis* 2022; **54**: 713–721.
- 27 Lev-Tzion R, Focht G, Lujan R, *et al.* COVID-19 vaccine is effective in inflammatory bowel disease patients and is not associated with disease exacerbation. *Clin Gastroenterol Hepatol* 2022; **20**: e1263–e1282.
- 28 Uchiyama K, Takagi T, Mizushima K, *et al.* Mucosal interleukin-8 expression as a predictor of subsequent relapse in ulcerative colitis patients with Mayo endoscopic subscore 0. *J Gastroenterol Hepatol* 2022; **37**: 1034–1042.
- 29 Uchiyama K, Takagi T, Mizushima K, *et al.* Increased mucosal IL-12 expression is associated with relapse of ulcerative colitis. *BMC Gastroenterol* 2021; **21**: 122.
- 30 Kirchgessner J, Svrcek M, Le Gall G, *et al.* Nancy Index Scores of chronic inflammatory bowel disease activity associate with development of colorectal neoplasia. *Clin Gastroenterol Hepatol* 2020; **18**: 150–157.e1.
- 31 Marchal-Bressenot A, Salleron J, Boulagnon-Rombi C, *et al.* Development and validation of the Nancy histological index for UC. *Gut* 2017; **66**: 43–49.
- 32 Ungaro R, Mehandru S, Allen PB, Peyrin-Biroulet L, Colombel JF. Ulcerative colitis. *Lancet* 2017; **389**: 1756–1770.
- 33 Honjo H, Watanabe T, Arai Y, *et al.* ATG16L1 negatively regulates RICK/RIP2-mediated innate immune responses. *Int Immunol* 2021; **33**: 91–105.
- 34 Watanabe T, Minaga K, Kamata K, *et al.* RICK/RIP2 is a NOD2-independent nodal point of gut inflammation. *Int Immunol* 2019; **31**: 669–683.
- 35 Takai A, Marusawa H, Minaki Y, *et al.* Targeting activation-induced cytidine deaminase prevents colon cancer development despite persistent colonic inflammation. *Oncogene* 2012; **31**: 1733–1742.
- 36 Watanabe T, Sadakane Y, Yagama N, *et al.* Nucleotide-binding oligomerization domain 1 acts in concert with the cholecystokinin receptor agonist, cerulein, to induce IL-33-dependent chronic pancreatitis. *Mucosal Immunol* 2016; **9**: 1234–1249.
- 37 Masaki S, Watanabe T, Arai Y, *et al.* Expression levels of cellular inhibitor of apoptosis proteins and colitogenic cytokines are inversely correlated with the activation of interferon regulatory factor 4. *Clin Exp Immunol* 2022; **207**: 340–350.
- 38 Minaga K, Watanabe T, Hara A, *et al.* Identification of serum IFN- α and IL-33 as novel biomarkers for type I autoimmune pancreatitis and IgG4-related disease. *Sci Rep* 2020; **10**: 14879.
- 39 Neurath MF. New targets for mucosal healing and therapy in inflammatory bowel diseases. *Mucosal Immunol* 2014; **7**: 6–19.
- 40 Liu M, Guo S, Hibbert JM, *et al.* CXCL10/IP-10 in infectious diseases pathogenesis and potential therapeutic implications. *Cytokine Growth Factor Rev* 2011; **22**: 121–130.
- 41 Yamaguchi T, Wing JB, Sakaguchi S. Two modes of immune suppression by Foxp3(+) regulatory T cells under inflammatory or non-inflammatory conditions. *Semin Immunol* 2011; **23**: 424–430.
- 42 Wirtz S, Neurath MF. Illuminating the role of type I IFNs in colitis. *J Clin Invest* 2005; **115**: 586–588.
- 43 Watanabe T, Hirono H, Hasegawa K, Soga K, Shibasaki K. Literature review in cases with exacerbation of ulcerative colitis induced by treatment with interferon and/or ribavirin. *J Gastroenterol Hepatol* 2011; **26**: 1709–1716.
- 44 Mannon PJ, Hornung RL, Yang Z, *et al.* Suppression of inflammation in ulcerative colitis by interferon- β -1a is accompanied by inhibition of IL-13 production. *Gut* 2011; **60**: 449–455.
- 45 Nikolaus S, Rutgeerts P, Fedorak R, *et al.* Interferon beta-1a in ulcerative colitis: a placebo controlled, randomised, dose escalating study. *Gut* 2003; **52**: 1286–1290.
- 46 Häcker H, Tseng PH, Karin M. Expanding TRAF function: TRAF3 as a tri-faced immune regulator. *Nat Rev Immunol* 2011; **11**: 457–468.
- 47 Li C, Chen Y, Zhao Y, *et al.* Intravenous injection of coronavirus disease 2019 (COVID-19) mRNA vaccine can induce acute myopericarditis in mouse model. *Clin Infect Dis* 2022; **74**: 1933–1950.
- 48 Liang F, Lindgren G, Lin A, *et al.* Efficient targeting and activation of antigen-presenting cells *in vivo* after modified mRNA vaccine administration in rhesus macaques. *Mol Ther* 2017; **25**: 2635–2647.
- 49 Metidji A, Rieder SA, Glass DD, Cremer I, Punksosy GA, Shevach EM. IFN- α/β receptor signaling promotes regulatory T cell development and function under stress conditions. *J Immunol* 2015; **194**: 4265–4276.
- 50 Wang D, Ghosh D, Islam SM, *et al.* IFN- β facilitates neuroantigen-dependent induction of CD25+ FOXP3+ regulatory T cells that suppress experimental autoimmune encephalomyelitis. *J Immunol* 2016; **197**: 2992–3007.
- 51 Lee SE, Li X, Kim JC, *et al.* Type I interferons maintain Foxp3 expression and T-regulatory cell functions under inflammatory conditions in mice. *Gastroenterology* 2012; **143**: 145–154.
- 52 Watanabe T, Minaga K, Kamata K, Kudo M, Strober W. Mechanistic insights into autoimmune pancreatitis and IgG4-related disease. *Trends Immunol* 2018; **39**: 874–889.
- 53 Patel AH, Amin R, Lalos AT. Acute liver injury and IgG4-related autoimmune pancreatitis following mRNA-based COVID-19 vaccination. *Hepatol Forum* 2022; **3**: 97–99.
- 54 Kim HJ, Jung M, Lim BJ, Han SH. New-onset class III lupus nephritis with multi-organ involvement after COVID-19 vaccination. *Kidney Int* 2022; **101**: 826–828.
- 55 Molina-Rios S, Rojas-Martinez R, Estévez Ramirez GM, Medina YF. Systemic lupus erythematosus and antiphospholipid syndrome after COVID-19 vaccination. A case report. *Mod Rheumatol Case Rep* 2023; **7**: 43–46.
- 56 Elbadry M, Medhat MA, Zaky S, El Kassas M. Ulcerative colitis as a possible sequela of COVID-19 Infection: the endless story. *Arab J Gastroenterol* 2022; **23**: 134–137.
- 57 Nawghare P, Jain S, Chandnani S, Rathi P. A case of acute severe ulcerative colitis triggered by COVID-19 infection. *Cureus* 2023; **15**: e34369.
- 58 Obara N, Koganei K, Tatsumi K, *et al.* Subtotal colectomy for refractory ulcerative colitis with COVID-19 infection; a first case report in Japan. *Clin J Gastroenterol* 2021; **14**: 1437–1442.



This is an open access article distributed under the terms of the Creative Commons Attribution-NonCommercial-NoDerivatives License (<http://creativecommons.org/licenses/by-nc-nd/4.0/>).