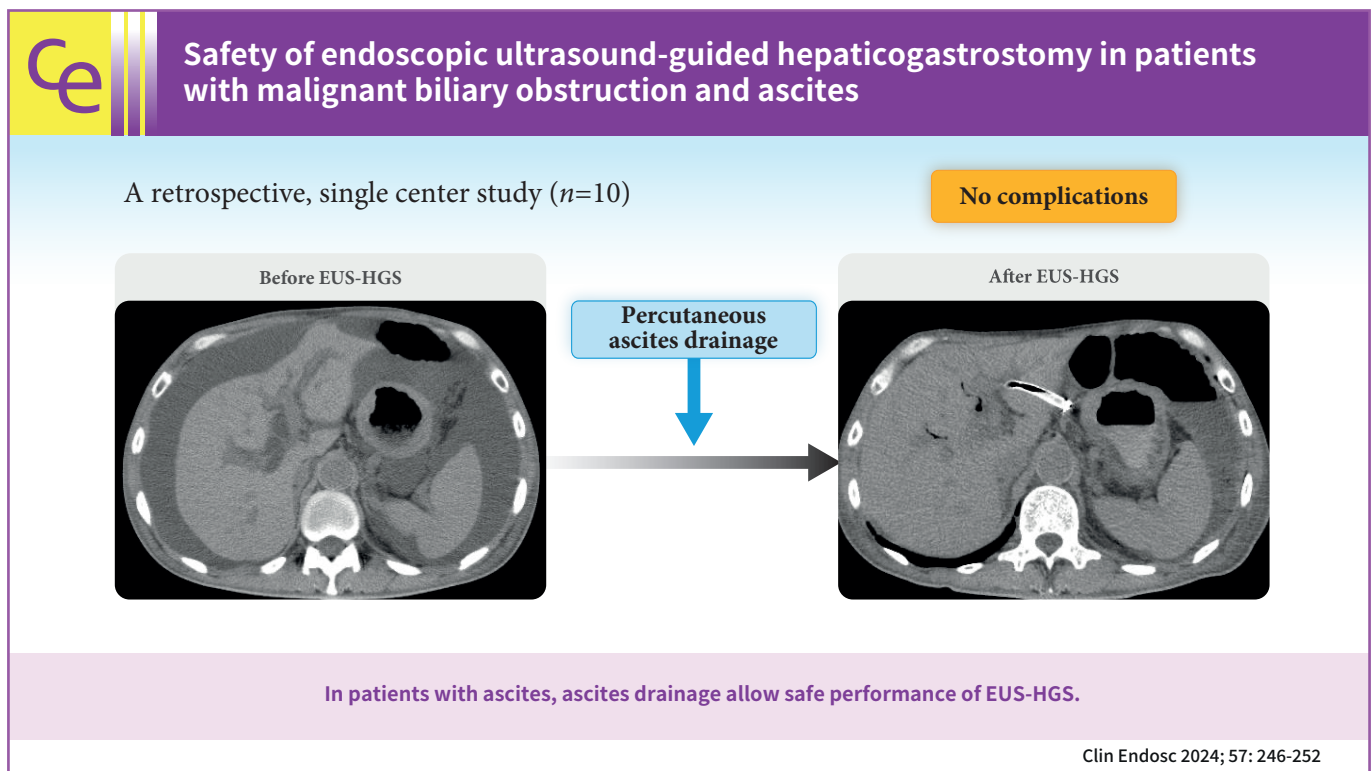


# Safety of endoscopic ultrasound-guided hepaticogastrostomy in patients with malignant biliary obstruction and ascites

Tsukasa Yasuda, Kazuo Hara, Nobumasa Mizuno, Shin Haba, Takamichi Kuwahara, Nozomi Okuno, Yasuhiro Kuraishi, Takafumi Yanaidani, Sho Ishikawa, Masanori Yamada, Toshitaka Fukui

Department of Gastroenterology, Aichi Cancer Center Hospital, Nagoya, Japan



Received: March 5, 2023 Revised: April 30, 2023 Accepted: May 11, 2023

Correspondence: Kazuo Hara  
Department of Gastroenterology, Aichi Cancer Center Hospital, 1-1  
Kanokoden, Chikusa-ku, Nagoya, Aichi 464-8681, Japan  
E-mail: khara@aichi-cc.jp

© This is an Open Access article distributed under the terms of the Creative Commons Attribution Non-Commercial License (<http://creativecommons.org/licenses/by-nc/4.0/>) which permits unrestricted non-commercial use, distribution, and reproduction in any medium, provided the original work is properly cited.

**Background/Aims:** Endoscopic ultrasound (EUS)-guided hepaticogastrostomy (EUS-HGS) is useful for patients with biliary cannulation failure or inaccessible papillae. However, it can lead to serious complications such as bile peritonitis in patients with ascites; therefore, development of a safe method to perform EUS-HGS is important. Herein, we evaluated the safety of EUS-HGS with continuous ascitic fluid drainage in patients with ascites.

**Methods:** Patients with moderate or severe ascites who underwent continuous ascites drainage, which was initiated before EUS-HGS and terminated after the procedure at our institution between April 2015 and December 2022, were included in the study. We evaluated the technical and clinical success rates, EUS-HGS-related complications, and feasibility of re-intervention.

**Results:** Ten patients underwent continuous ascites drainage, which was initiated before EUS-HGS and terminated after completion of the procedure. Median duration of ascites drainage before and after EUS-HGS was 2 and 4 days, respectively. Technical success with EUS-HGS was achieved in all 10 patients (100%). Clinical success with EUS-HGS was achieved in 9 of the 10 patients (90%). No endoscopic complications such as bile peritonitis were observed.

**Conclusions:** In patients with ascites, continuous ascites drainage, which is initiated before EUS-HGS and terminated after completion of the procedure, may prevent complications and allow safe performance of EUS-HGS.

**Keywords:** Ascites; Cholangiography; Endoscopy; Peritonitis; Ultrasonography

## INTRODUCTION

Endoscopic ultrasound-guided biliary drainage (EUS-BD) is a relatively new therapeutic modality that is used when conventional endoscopic retrograde cholangiopancreatography (ERCP) is not feasible.<sup>1-4</sup> EUS-BD, which was first reported in 2001,<sup>5</sup> has shown high success rates.<sup>6</sup> EUS-BD is an alternative to percutaneous transhepatic biliary drainage (PTBD) and has been used to treat patients with biliary cannulation failure or inaccessible papillae. Its applicability in primary drainage has also been reported.<sup>7-9</sup>

EUS-BD comprises antegrade stenting, rendezvous with ERCP, and bilioenterostomy, and is categorized as EUS-guided hepaticogastrostomy (EUS-HGS) and EUS-guided choledochoduodenostomy (EUS-CDS).<sup>10</sup> Among these two techniques, EUS-HGS has the widest indications, including high-grade hilar stenosis, duodenal stenosis, surgically altered anatomy, and bile duct catheterization failure.<sup>11-14</sup> Therefore, EUS-HGS is the most frequently performed EUS-BD procedure.<sup>15,16</sup>

Unlike ERCP, EUS-HGS avoids traumatic papillary irritation, which could lead to acute pancreatitis. Furthermore, unlike PTBD, it is more comfortable and physiologically safer for patients.

EUS-HGS-related complications, including bile leakage, peritonitis, stent prolapse, perforation, and bleeding, have been reported.<sup>17,18</sup> In particular, the risk of severe complications is higher in patients with ascites than in those without ascites. Thus, to avoid complications, ERCP is preferentially performed instead of EUS-HGS in patients with ascites. However, ERCP may not

be feasible in patients with stomach or duodenal invasion or in those with surgically altered anatomy. Thus, it is important to develop a safe method to perform EUS-HGS in patients with ascites. We hypothesized that EUS-HGS could be performed safely in patients with ascites by initiating continuous ascites drainage prior to the procedure and terminating it after completion of the procedure. Thus, herein, we evaluated whether EUS-HGS can be safely performed in patients who undergo continuous ascites drainage that was initiated before EUS-HGS and terminated after the completion of the procedure.

## METHODS

Ten consecutive patients with moderate or severe ascites who had undergone EUS-HGS with continuous ascites drainage, which was initiated before EUS-HGS and terminated after its completion, between April 2015 and December 2022 at our institute were retrospectively investigated.

Patients with moderate or severe ascites who were likely to experience difficulty with PTBD, those with ascites in the EUS-HGS puncture route as observed on computed tomography (CT), and those who could safely undergo percutaneous ascites drainage underwent continuous ascites drainage. EUS-HGS was not originally indicated for patients with severe ascites; it was performed only when it was considered beneficial and the patient strongly desired advanced treatment.

CT of the abdomen and pelvis was performed 24 hours after the procedure to confirm the absence of complications such as stent migration and bile leakage. Follow-up began on the date

of the first endoscopic drainage procedure and ended in December 2022 or on the date of the patient's death.

### Ascites drainage

The daily upper limit of ascites drainage was 3,000 mL, and drainage was performed for up to 3 days before EUS-HGS. Drainage was stopped post-EUS-HGS when the volume had reached  $\leq 1,000$  mL/day and no infection was observed. The amount of ascites was evaluated using CT as per previously reported methods<sup>19,20</sup> and was defined as follows: mild ascites, detected only in the upper or lower abdominal cavity; moderate ascites, detected in both the upper and lower abdominal cavities; and severe ascites, ascites extending continuously from the pelvic cavity to the upper abdominal cavity (Fig. 1).

### Endoscopic procedures

All the procedures were performed under ultrasonographic and fluoroscopic guidance. EUS-HGS was performed using a convex echoendoscope (GF-UCT260; Olympus or EG-760UT, Fujifilm). Before EUS-HGS, a forward-viewing scope was used to clip the gastroesophageal junction for easy identification of the esophagus and to prevent its puncture. An echoendoscope was inserted into the stomach. After the puncture point was determined, the left intrahepatic bile duct (B2 or B3) was punc-

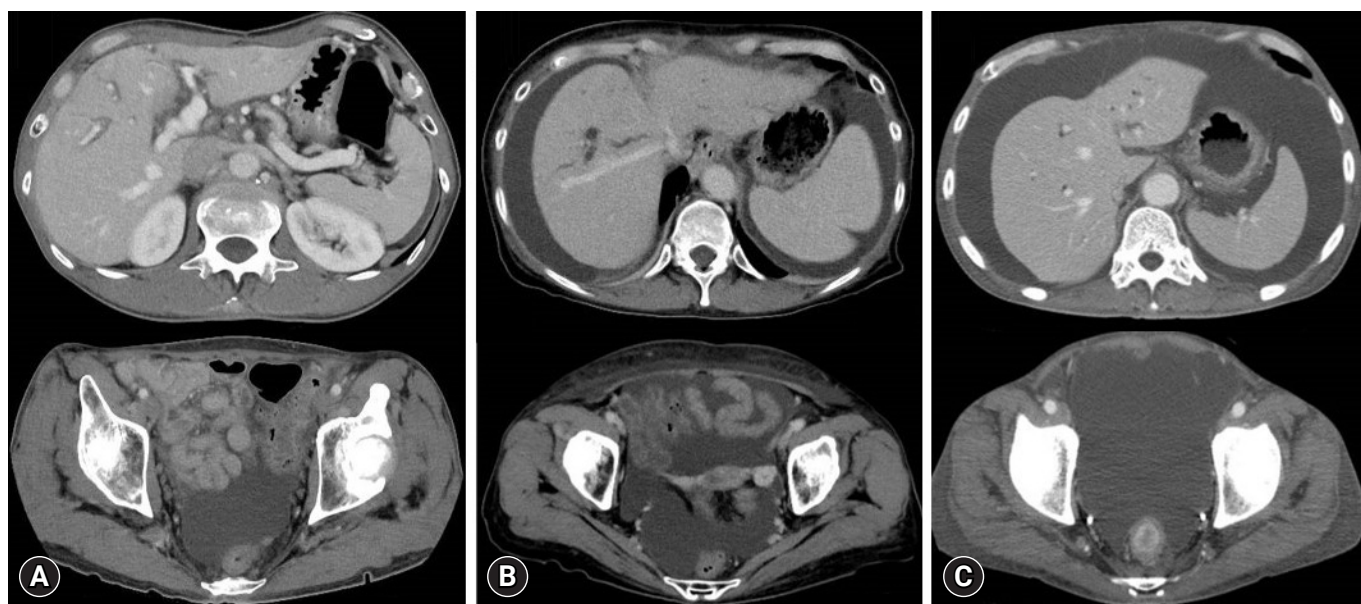
tured using a 19 G needle (EZ shot 3 plus; Olympus) attached to a connector (Radifocus Hemostasis Valve II; Terumo). Subsequently, a 0.025-inch guidewire (M-through; Asahi Intecc) was introduced into the left intrahepatic bile duct. A small amount of contrast medium was injected to confirm appropriate placement of the guidewire. Thereafter, the guidewire was placed in the common bile duct and a fistula was created using a 7-Fr tapered cannula (ES dilator soft type, 0.025-inch; Zeon Medical). Cholangiography was performed using an uneven double-lumen cannula (Piolax Medical). Finally, a fully covered, self-expandable metal stent (6 mm $\times$ 12 cm, Hanarostent; Boston Scientific) was placed and the implantation site was confirmed with fluoroscopy. In some cases, the devices were changed at the discretion of the surgeon.

### Evaluated outcomes

The evaluated outcomes included the technical and clinical success rates of EUS-HGS, EUS-HGS-related complications, and feasibility of re-intervention.

### Definitions

Technical success was defined as successful placement of the stent via the stomach into the left intrahepatic bile duct, which was confirmed by endoscopy and CT. Clinical success was de-



**Fig. 1.** Computed tomography images showing ascites. (A) Mild ascites: ascites present in the lower abdomen but not in the upper abdomen. (B) Moderate ascites: ascites present in both the upper and lower abdomens. (C) Severe ascites: ascites present continuously from the upper to the lower abdomen.

defined as improvement in cholangitis or reduction in the total serum bilirubin level to <75% of the pretreatment value within 2 weeks. Procedure time was defined as the interval between the insertion of the scope and the completion of all procedures.

**Complications**

Complications of endoscopic treatment were divided into early (occurring within 14 days of the endoscopic procedure) and late (occurring >14 days after the procedure). These complications were evaluated according to the American Society for Gastrointestinal Endoscopy lexicon.<sup>21</sup> Bleeding was defined as a reduction in the serum hemoglobin level to <2.0 g/dL from the pretreatment value.

**Ethical statements**

This study was approved by the Institutional Review Board of the Aichi Cancer Center Hospital (No. IR041150). The requirement for informed consent from patients was waived owing to the retrospective nature of this study.

**RESULTS**

The characteristics of the 10 patients are presented in Table 1.

**Table 1.** Clinical characteristics of patients who underwent continuous ascites drainage beginning before and ending after endoscopic ultrasound-guided hepaticogastrostomy

Characteristic	Value (n=10)
Age (yr)	66.5 (58–77)
Male	6 (60)
Anticoagulant therapy	1 (10)
Biliary obstruction cause	
Pancreatic cancer	3 (30)
Gastric cancer	5 (50)
Metastatic colorectal cancer	1 (10)
Metastatic cervical cancer	1 (10)
Degree of ascites	
Moderate	4 (40)
Severe	6 (60)
Liver metastases	2 (20)
Suppurative cholangitis	2 (20)
Reason for endoscopic ultrasound-guided hepaticogastrostomy	
Gastric or duodenal obstruction	5 (50)
Surgically altered anatomy	3 (30)
Failed biliary cannulation	2 (20)

Values are presented as median (range) or number (%).

Of the 10 patients (six males, four females; median age, 66.5 [58–77] years) with malignant biliary obstruction, EUS-HGS had to be performed due to gastric or duodenal obstruction during the course of cancer in five (50%) patients, surgically altered anatomy in three (30%) patients, and lack of ERCP efficacy (bile duct catheterization failure despite some attempts) in two (20%) patients. The ascites was moderate in four (40%) patients and severe in six (60%) patients.

Details of the EUS-HGS procedure are shown in Table 2, and the clinical outcomes are shown in Table 3.

The median duration of pre- and post-EUS-HGS ascites drainage was 2 days (range, 1–3 days) and 4 days (range, 2–6 days), respectively. Antimicrobial agents were administered to

**Table 2.** Technical data concerning the endoscopic ultrasound-guided hepaticogastrostomy procedures

Technical data	Value (n=10)
Procedure time (min)	20 (15–44)
Diameter of the punctured intrahepatic duct (mm)	4.8 (3.0–8.0)
Puncture site	
B2	6 (60)
B3	4 (40)
Puncture needle gauge	
19-gauge	8 (80)
22-gauge	2 (20)
Type of stent	
Covered self-expandable metal stent	10 (100)
Diameter of stent	
6 mm	7 (70)
8 mm	3 (30)
Antegrade stenting	4 (40)

Values are presented as median (range) or number (%).

**Table 3.** Clinical outcomes for patients who underwent endoscopic ultrasound-guided hepaticogastrostomy

Clinical outcomes	Value (n=10)
Technical success	10 (100)
Clinical success	9 (90)
Complications of endoscopic treatment	
Early complications	0 (0)
Late complications	0 (0)
Antimicrobials use after endoscopic ultrasound-guided hepaticogastrostomy	10 (100)
Duration of antimicrobial use after procedure (days)	7 (2–12)
Duration until eating was resumed (days)	1 (1–4)
Re-intervention, n (%)	3 (30)
Duration of follow-up, days; median [range]	31 (13–383)

Values are presented as number (%) or median (range).

all the patients after EUS-HGS. The median duration of post-EUS-HGS antimicrobial agent use was 7 days (range, 2–12 days), and the median duration until the resumption of eating was 1 day (range, 1–4 days).

Technical success was achieved in all 10 patients (100%). The median procedure time was 20 minutes (range, 15–44 mins). The median diameter of the punctured intrahepatic bile duct was 4.8 mm (range, 3.0–8.0 mm) and B2 and B3 punctures were performed in six and four patients, respectively. The gauge of the puncture needles used was 19-G in eight patients and 22-G in two patients. All stents were self-expandable metal stents.

Clinical success was achieved in nine of the 10 (90%) patients. EUS-HGS was clinically unsuccessful in one patient whose general condition worsened owing to the rapidly progressing advanced cancer. Chemotherapy was performed in patients in whom clinically successful endoscopic treatment was achieved because the total serum bilirubin level dropped below the threshold. This facilitated chemotherapy in two patients, whereas the other patients were administered the best supportive care because of their decreased performance status. The median follow-up duration after EUS-HGS was 43 days (range, 13–383 days), and the median stent patency was 43 days (range, 13–215 days).

No patients experienced endoscopic treatment-related early complications, such as bile peritonitis, infectious peritonitis, or stent migration (Supplementary Video 1, 2). During hospitalization, none of the patients had electrolyte abnormalities or renal dysfunction, and no late complications were noted (Table 4).

During long-term follow-up, three (30%) patients underwent re-intervention for cholangitis ( $n=2$ ) or stent dislocation ( $n=1$ ). The patients with cholangitis had complete fistulae; therefore, stent replacement was possible. Stent dislocation was observed on CT in one patient 203 days after the endoscopic procedure.

Re-stent placement was challenging because of fistula closure; however, jaundice did not exacerbate after the procedure because chemotherapy relieved the bile duct stricture.

## DISCUSSION

In patients with ascites who require biliary drainage, ERCP is preferred to EUS-HGS or PTBD because it does not typically cause bile leakage. However, this procedure may not be feasible if there is duodenal invasion or when the anatomy is surgically altered. In such cases, EUS-HGS can be used as an alternative. We hypothesized that EUS-HGS could be performed safely in patients with ascites if continuous ascites drainage is performed prior to, during, and after the procedure to minimize ascitic fluid volume.

To the best of our knowledge, no comprehensive studies on EUS-HGS have been performed in patients with ascites, and this is the first report to examine the safety of EUS-HGS in patients with ascites.

One limitation of the extrahepatic approach is the potentially high risk of bile leakage.<sup>22</sup> In particular, patients with excess ascites have higher risks of developing peritonitis and stent migration because of the inability to form a mature fistula after the procedure.<sup>23</sup> The overall EUS-HGS-related complication rate is approximately 18.2%, with bleeding (3.7%), bile leakage (2.8%), stent migration (2.8%), biloma (2.6%), liver hematoma (1.2%), and sepsis (1.2%) being more common.<sup>10</sup> Bile leakage into the abdominal cavity and stent migration are the most serious complications of this procedure.<sup>15,24-26</sup> Ascites carries the potential risk of complications, such as infectious peritonitis, which are occasionally serious. We previously reported a case of severe infectious peritonitis after EUS-HGS in a patient with ascites.<sup>27</sup> Thus, it is important to prevent serious complications when performing EUS-HGS in patients with ascites.

Herein, initiating continuous ascites drainage before EUS-HGS and terminating it after the completion of the procedure resulted in technical and clinical success in 10 (100%) and 9 (90%) patients, respectively. No serious complications, such as bile peritonitis, were observed. Continued ascites drainage post-procedure until the volume was <1,000 mL/day may have also prevented the development of ascites between the stomach and liver and promoted fistula formation. Furthermore, preventing complications such as ascites infection and internal migration may have contributed as well. Thus, when EUS-HGS is scheduled for patients with ascites, percutaneous insertion of a

**Table 4.** Complications of endoscopic ultrasound-guided hepaticogastrostomy

Complications	Value ( $n=10$ )
Early complications	
Bile peritonitis	0 (0)
Sepsis	0 (0)
Stent migration	0 (0)
Bleeding	0 (0)
Late complications	
Abscess	0 (0)
Pseudoaneurysm	0 (0)

drainage tube and continuous ascites drainage prior to, during, and after the procedure may prevent complications such as peritonitis and stent migration.

Bile leakage has been observed more frequently in patients receiving plastic stents (10%) than in those receiving covered, self-expandable, metal stents (4%)<sup>6</sup>; therefore, covered metal stents are recommended for patients with ascites. Luminal stent length is reportedly an important factor in reducing EUS-HGS-related adverse events.<sup>28</sup> Therefore, considering stent shortening, a stent of  $\geq 10$  cm in length should be used to prevent stent migration.<sup>28,29</sup> Herein, covered, self-expandable, metal stents ( $\geq 10$  cm) were used in all patients. The use of migration-resistant stents may shorten the post-EUS-HGS ascites drainage period, and further increase the safety of the procedure.

Our study had some limitations. This single-center study included only a select group of nonrandomized patients. Additional studies are required to further evaluate the efficacy and safety of EUS-HGS with continuous ascites drainage prior to, during, and after the procedure in patients with malignant biliary obstruction and ascites.

In conclusion, EUS-HGS can be performed more safely in patients with malignant biliary obstruction and moderate or severe ascites by reducing the ascitic fluid volume via continuous drainage before and during EUS-HGS, which is terminated after the completion of the procedure.

## Supplementary Material

**Supplementary Video 1.** Computed tomography imaging before endoscopic ultrasound-guided hepaticogastrostomy (<http://doi.org/10.5946/ce.2023.075.v001>).

**Supplementary Video 2.** Computed tomography imaging after endoscopic ultrasound-guided hepaticogastrostomy (<http://doi.org/10.5946/ce.2023.075.v002>).

Supplementary materials related to this article can be found online at <https://doi.org/10.5946/ce.2023.075>.

## Conflicts of Interest

Dr. Mizuno reports receiving grants and personal fees from Yakult Honsha, Novartis, MSD, and ASLAN Pharmaceuticals, grants from Incyte, Ono Pharmaceutical, Seagen, Taiho Pharmaceutical, and Dainippon Sumitomo Pharma, and personal fees from AstraZeneca and Fujifilm Toyama Chemical for work other than the submitted paper. The authors declare no conflicts of interest.

## Funding

None.

## Author Contributions

Conceptualization: TY, KH; Data curation: TY; Investigation: TY; Methodology: KH; Project administration: KH; Resources: TY; Supervision: KH; Validation: all authors; Visualization: TY; Writing-original draft: TY; Writing-review & editing: all authors.

## ORCID

Tsukasa Yasuda	<a href="https://orcid.org/0000-0003-3878-6814">https://orcid.org/0000-0003-3878-6814</a>
Kazuo Hara	<a href="https://orcid.org/0000-0002-4699-6136">https://orcid.org/0000-0002-4699-6136</a>
Nobumasa Mizuno	<a href="https://orcid.org/0000-0001-9704-1885">https://orcid.org/0000-0001-9704-1885</a>
Shin Haba	<a href="https://orcid.org/0000-0002-7578-5610">https://orcid.org/0000-0002-7578-5610</a>
Takamichi Kuwahara	<a href="https://orcid.org/0000-0001-8348-8926">https://orcid.org/0000-0001-8348-8926</a>
Nozomi Okuno	<a href="https://orcid.org/0000-0001-6376-687X">https://orcid.org/0000-0001-6376-687X</a>
Yasuhiro Kuraishi	<a href="https://orcid.org/0000-0003-4238-5714">https://orcid.org/0000-0003-4238-5714</a>
Takafumi Yanaidani	<a href="https://orcid.org/0000-0003-0621-3982">https://orcid.org/0000-0003-0621-3982</a>
Sho Ishikawa	<a href="https://orcid.org/0000-0002-0677-7641">https://orcid.org/0000-0002-0677-7641</a>
Masanori Yamada	<a href="https://orcid.org/0000-0001-7101-8249">https://orcid.org/0000-0001-7101-8249</a>
Toshitaka Fukui	<a href="https://orcid.org/0000-0001-8557-6428">https://orcid.org/0000-0001-8557-6428</a>

## REFERENCES

1. Sharaiha RZ, Kumta NA, Desai AP, et al. Endoscopic ultrasound-guided biliary drainage versus percutaneous transhepatic biliary drainage: predictors of successful outcome in patients who fail endoscopic retrograde cholangiopancreatography. *Surg Endosc* 2016;30:5500–5505.
2. Lee TH, Choi JH, Park DH, et al. Similar efficacies of endoscopic ultrasound-guided transmural and percutaneous drainage for malignant distal biliary obstruction. *Clin Gastroenterol Hepatol* 2016;14:1011–1019.
3. Sharaiha RZ, Khan MA, Kamal F, et al. Efficacy and safety of EUS-guided biliary drainage in comparison with percutaneous biliary drainage when ERCP fails: a systematic review and meta-analysis. *Gastrointest Endosc* 2017;85:904–914.
4. Nakai Y, Kogure H, Isayama H, et al. Endoscopic ultrasound-guided biliary drainage for benign biliary diseases. *Clin Endosc* 2019; 52:212–219.
5. Giovannini M, Moutardier V, Pesenti C, et al. Endoscopic ultrasound-guided bilioduodenal anastomosis: a new technique for biliary drainage. *Endoscopy* 2001;33:898–900.
6. Kawakubo K, Isayama H, Kato H, et al. Multicenter retrospective study of endoscopic ultrasound-guided biliary drainage for ma-

- lignant biliary obstruction in Japan. *J Hepatobiliary Pancreat Sci* 2014;21:328–334.
7. Bang JY, Navaneethan U, Hasan M, et al. Stent placement by EUS or ERCP for primary biliary decompression in pancreatic cancer: a randomized trial (with videos). *Gastrointest Endosc* 2018;88:9–17.
  8. Paik WH, Lee TH, Park DH, et al. EUS-guided biliary drainage versus ERCP for the primary palliation of malignant biliary obstruction: a multicenter randomized clinical trial. *Am J Gastroenterol* 2018;113:987–997.
  9. Park JK, Woo YS, Noh DH, et al. Efficacy of EUS-guided and ERCP-guided biliary drainage for malignant biliary obstruction: prospective randomized controlled study. *Gastrointest Endosc* 2018;88:277–282.
  10. Isayama H, Nakai Y, Itoi T, et al. Clinical practice guidelines for safe performance of endoscopic ultrasound/ultrasonography-guided biliary drainage: 2018. *J Hepatobiliary Pancreat Sci* 2019;26:249–269.
  11. Hamada T, Isayama H, Nakai Y, et al. Transmural biliary drainage can be an alternative to transpapillary drainage in patients with an indwelling duodenal stent. *Dig Dis Sci* 2014;59:1931–1938.
  12. Khashab MA, El Zein MH, Sharzehi K, et al. EUS-guided biliary drainage or enteroscopy-assisted ERCP in patients with surgical anatomy and biliary obstruction: an international comparative study. *Endosc Int Open* 2016;4:E1322–E1327.
  13. Nakai Y, Kogure H, Isayama H, et al. Endoscopic ultrasound-guided biliary drainage for unresectable hilar malignant biliary obstruction. *Clin Endosc* 2019;52:220–225.
  14. Kongkam P, Tasneem AA, Rerknimitr R. Combination of endoscopic retrograde cholangiopancreatography and endoscopic ultrasonography-guided biliary drainage in malignant hilar biliary obstruction. *Dig Endosc* 2019;31 Suppl 1:50–54.
  15. Poincloux L, Rouquette O, Buc E, et al. Endoscopic ultrasound-guided biliary drainage after failed ERCP: cumulative experience of 101 procedures at a single center. *Endoscopy* 2015;47:794–801.
  16. Paik WH, Park DH. Outcomes and limitations: EUS-guided hepaticogastrostomy. *Endosc Ultrasound* 2019;8(Suppl 1):S44–S49.
  17. Martins FP, Rossini LG, Ferrari AP. Migration of a covered metallic stent following endoscopic ultrasound-guided hepaticogastrostomy: fatal complication. *Endoscopy* 2010;42 Suppl 2:E126–E127.
  18. Prachayakul V, Thamtorawat S, Siripipattanamongkol C, et al. Bleeding left hepatic artery pseudoaneurysm: a complication of endoscopic ultrasound-guided hepaticogastrostomy. *Endoscopy* 2013;45 Suppl 2 UCTN:E223–E224.
  19. Nakajima TE, Yamaguchi K, Boku N, et al. Randomized phase II/III study of 5-fluorouracil/l-leucovorin versus 5-fluorouracil/l-leucovorin plus paclitaxel administered to patients with severe peritoneal metastases of gastric cancer (JCOG1108/WJOG7312G). *Gastric Cancer* 2020;23:677–688.
  20. Hara H, Kadowaki S, Asayama M, et al. First-line bolus 5-fluorouracil plus leucovorin for peritoneally disseminated gastric cancer with massive ascites or inadequate oral intake. *Int J Clin Oncol* 2018;23:275–280.
  21. Cotton PB, Eisen GM, Aabakken L, et al. A lexicon for endoscopic adverse events: report of an ASGE workshop. *Gastrointest Endosc* 2010;71:446–454.
  22. Maranki J, Hernandez AJ, Arslan B, et al. Interventional endoscopic ultrasound-guided cholangiography: long-term experience of an emerging alternative to percutaneous transhepatic cholangiography. *Endoscopy* 2009;41:532–538.
  23. Chantarojanasiri T, Ratanachu-Ek T, Pausawasdi N. What you need to know before performing endoscopic ultrasound-guided hepaticogastrostomy. *Clin Endosc* 2021;54:301–308.
  24. Ogura T, Higuchi K. Technical tips for endoscopic ultrasound-guided hepaticogastrostomy. *World J Gastroenterol* 2016;22:3945–3951.
  25. Sportes A, Camus M, Greget M, et al. Endoscopic ultrasound-guided hepaticogastrostomy versus percutaneous transhepatic drainage for malignant biliary obstruction after failed endoscopic retrograde cholangiopancreatography: a retrospective expertise-based study from two centers. *Therap Adv Gastroenterol* 2017;10:483–493.
  26. Marx M, Caillol F, Sfumato P, et al. EUS-guided hepaticogastrostomy in the management of malignant biliary obstruction: Experience and learning curve in a tertiary referral center. *Dig Liver Dis* 2022;54:1236–1242.
  27. Okuno N, Hara K, Mizuno N, et al. Infectious peritonitis after endoscopic ultrasound-guided biliary drainage in a patient with ascites. *Gastrointest Interv* 2018;7:40–43.
  28. Ogura T, Yamamoto K, Sano T, et al. Stent length is impact factor associated with stent patency in endoscopic ultrasound-guided hepaticogastrostomy. *J Gastroenterol Hepatol* 2015;30:1748–1752.
  29. Okuno N, Hara K, Mizuno N, et al. Stent migration into the peritoneal cavity following endoscopic ultrasound-guided hepaticogastrostomy. *Endoscopy* 2015;47 Suppl 1 UCTN:E311.