



Ocular surface lesions in clinical grades of Bell's phenomenon

Omer Faruk Yilmaz¹ and Halit Oguz^{1,2}

¹ Goztepe Prof. Dr. Suleyman Yalcin City Hospital, Department of Ophthalmology, Istanbul, Turkey

² Istanbul Medeniyet University Faculty of Medicine, Department of Ophthalmology, Istanbul, Turkey

ABSTRACT

Background: Bell's phenomenon, also known as the palpebral oculogyric reflex, is a critical reflex that protects the cornea. We developed an innovative, simple, and practical grading scale for Bell's phenomenon that includes the inverse Bell's phenomenon. Using this scale, we investigated the characteristics of Bell's phenomenon among asymptomatic individuals in different age groups and examined the frequency of ocular surface lesions in asymptomatic and symptomatic participants with different grades.

Methods: In this cross-sectional study, we randomly included 330 eyes of 165 asymptomatic, healthy, White Turkish individuals who attended the outpatient eye clinic, with a male-to-female ratio of 1:1.4, in the control group. These were categorized into four age groups: 4 – 20 years, 21 – 40 years, 41 – 60 years, and > 60 years. Eighty eyes from 40 patients with ocular surface lesions and absence of grade +2 Bell's phenomenon were included in the symptomatic group. Bell's phenomenon was classified into five grades: grade +2 (strong positive), grade +1 (weak positive), grade 0 (no Bell's phenomenon, no eye movement), grade –1 (weak inverse), and grade –2 (strong inverse).

Results: We detected higher frequencies of grade +2, +1, and 0 in individuals aged 4 – 40, 41 – 60, and > 60 years, respectively. There was a significant difference between age groups in the frequencies of different grades ($P < 0.001$). Pairwise analysis revealed a significantly lower frequency of grade +2 in the age group > 60 years compared with the 4 – 20 and 21 – 40 year groups (both $P < 0.05$). Grade +2 was the most frequent in both sexes. We detected grade 0 in 27.1% of men and 22.1% of women in the control group, with no significant difference in the frequencies of different grades between sexes ($P > 0.05$). We observed significant differences between grades with respect to the frequency of ocular surface lesions ($P < 0.001$). Pairwise analysis revealed a significantly higher frequency of ocular surface lesions in asymptomatic individuals with grade 0 and all four other grades (all $P < 0.001$). However, the frequency of ocular surface lesions was comparable between sexes ($P > 0.05$). Of the 40 symptomatic individuals, 28 (70%), 5 (12.5%), 4 (10%), and 3 (7.5%) had grade 0, +1, –1, and –2, respectively. The number of symptomatic patients was higher in grade 0 ($n = 28$) than in other grades (grade +1, –1, and –2: $n = 12$ patients), and these individuals had a higher frequency of ocular surface lesions ($n = 38$ lesions) than others (grade +1, –1, and –2: 7 lesions).

Conclusions: Using a simple, practical grading scale for Bell's phenomenon that includes inverse Bell's phenomenon, we observed that inverse Bell's phenomenon is a reflex that may be present in healthy individuals and could have a protective effect on the eye, although not to such a degree as a strong Bell's phenomenon. Our observations imply that bilateral conjunctival calcifications/Vogt's limbal girdle may be associated with grades 0 and +1 Bell's phenomenon. Further large-scale studies are needed to determine the frequency of Bell's phenomenon in the general population using this innovative, simple, practical grading scale, and to identify the protective or injurious effect of each grade on the ocular surface.

KEYWORDS

reflex, Bell's phenomenon, Bell's reflex, age group, ocular surface lesions, corneal pannus, band keratopathy, pingueculas, conjunctivas


Correspondence: Omer Faruk Yilmaz, Goztepe Prof. Dr. Suleyman Yalcin City Hospital, Department of Ophthalmology, Istanbul, Turkey.

Email: dryilmazof@yahoo.com. ORCID iD: <https://orcid.org/0000-0001-5571-3735>

How to cite this article: Yilmaz OF, Oguz H. Ocular surface lesions in clinical grades of Bell's phenomenon. Med Hypothesis Discov Innov Ophthalmol. 2023 Winter; 12(4): 177-186. <https://doi.org/10.51329/mehdiophthal1484>

Received: 11 December 2023; Accepted: 26 January 2024



Copyright © Author(s). This is an open-access article distributed under the terms of the Creative Commons Attribution-NonCommercial 4.0 International License (<https://creativecommons.org/licenses/by-nc/4.0/>) which permits copy and redistribute the material just in noncommercial usages, provided the original work is properly cited. 

INTRODUCTION

Bell's phenomenon, also known as the palpebral–oculogyric reflex, is a critical reflex that protects the cornea. Sir Charles Bell first described it in 1969 [1, 2]. Bell's phenomenon is the upward and slightly outward movement of the eyeball during eyelid closure to protect the cornea [3]. Under normal conditions, the tear film [4], eyelids, blink reflex, complete eyelid closure during sleep, and strong Bell's phenomenon protect the cornea [5, 6].

The activity of Bell's phenomenon varies with age and reflects the maturation process of the brainstem and extraocular muscles [7]. In a study conducted on 300 newborn babies, Bell's phenomenon was not detected in premature newborns but was present in 16.7% of full-term newborns. The incidence of Bell's phenomenon in infants increases by the month [7]. In addition to age, Bell's phenomenon is affected by many conditions, such as eye surgery, lagophthalmos, and intensive care unit stays [8].

There are many types of ocular surface lesions. Pingueculum, conjunctival calcification, Vogt's limbal girdle, furrow degeneration, and Salzmann's nodular degeneration are conditions that usually occur in older individuals [9–12]. Corneal and conjunctival calcifications can be idiopathic or associated with chronic renal failure and hyperparathyroidism [13]. The conjunctival flora is also influenced by the presence of corneal lesions [14, 15].

In our corneal department, we have noted that many patients with absence of Bell's phenomenon or with an inverse Bell's phenomenon had corneal or conjunctival degeneration. Therefore, we developed a simple and practical grading scale for Bell's phenomenon that includes the inverse Bell's phenomenon. Using this scale, we investigated the frequency of Bell's phenomenon according to age and sex groups and its relationship with the presence of ocular surface lesions in asymptomatic and symptomatic individuals.

METHODS

In this cross-sectional study, we examined all individuals who presented to the cornea unit at Istanbul Medeniyet University Göztepe Training and Research Hospital, Istanbul, Turkey, from 2022 to 2023. Ethical approval for this study was obtained from the Ethics Committee of Istanbul Medeniyet University Göztepe Training and Research Hospital clinical research on April 13, 2022 (decision number: 2023/0094). The study participants provided informed consent for participation and publication of their data.

Individuals with corneal lesions and a weak Bell's phenomenon were systematically enrolled into the patient group during the study period. We excluded those with a history of ocular surgeries, those treated in an intensive care unit, individuals with a history of trauma or coexisting eyelid problems such as entropion or ectropion, patients with neurological or psychiatric diseases, and those with chronic use of eye drops. The control group consisted of healthy individuals without ocular or eyelid problems or systemic diseases who underwent a similar evaluation for the grading of Bell's phenomenon.

In the control group, 330 eyes of 165 asymptomatic White Turkish individuals who attended the outpatient eye clinic were randomly selected. They were classified into four age groups: 4–20 years, 21–40 years, 41–60 years, and >60 years. In the patient group, 80 eyes of 40 individuals with ocular surface lesions and absence of a strong Bell's phenomenon (grade +2) were included. The shape and location of punctate epitheliopathy in patients with corneal lesions were evaluated using fluorescein staining under slit-lamp biomicroscopy (Photo Slit Lamp at 16× magnification; Topcon SL-D701, Tokyo, Japan) examination.

Study participants underwent comprehensive ophthalmological examinations, including measurement of best-corrected distance visual acuity using a Snellen chart (Auto Chart Projector ACP 1800, Chongqing Vision Star Optical Co., Ltd., China), intraocular pressure measurement using the Goldmann applanation tonometer (AT900, Haag-Streit, Koeniz, Switzerland), and both undilated and dilated slit-lamp biomicroscopy (Photo Slit Lamp at 16× magnification; Topcon SL-D701, Tokyo, Japan).

Bell's phenomenon was evaluated by forcefully holding the upper eyelid in place while the participant attempted to close the eye tightly [16]. To standardize the classification, Bell's phenomenon was evaluated using a similar technique by a single examiner who opened the upper eyelid approximately 6 mm (about half the corneal diameter). This amount of upper eyelid opening is essential to a standardized classification of Bell's phenomenon, as upper eyelid flexibility has interindividual variability [17, 18]. In grading, the examiner noted the maximum level to which the eyeball moved during active eye closure. The lower eyelid was not touched during the grading. While assessing Bell's phenomenon, the examiner must perceive that the patient is applying force to close the eyelids; otherwise, the patient's upward and downward gaze would be misclassified. After bilateral evaluation of Bell's phenomenon, controlling unilateral Bell's phenomenon will reduce the possibility of misclassification.

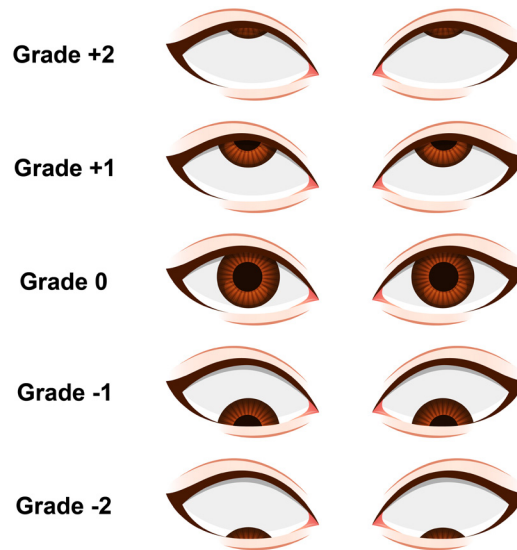


Figure 1. Classification of Bell's phenomenon.

Table 1. A practical grading scale for Bell's phenomenon

Grade	Definition	Characteristics
+ 2	Strong positive Bell's phenomenon	Eye movement is upward, the cornea is entirely under the upper eyelid, and only the sclera is visible 6 mm above the lower eyelid margin.
+ 1	Weak positive Bell's phenomenon	Eye movement is upward, but the cornea or lower limbus is visible 6 mm above the lower eyelid margin.
0	No Bell's phenomenon	There is no eye movement, and the pupil or cornea is visible in the lower eyelid margin.
-1	Weak inverse Bell's phenomenon	Eye movement is downward, but the cornea or upper limbus is visible in the lower eyelid margin.
-2	Strong inverse Bell's phenomenon	Eye movement is downward, the cornea is entirely under the lower eyelid, and only the sclera is visible in the lower eyelid margin.

In this study, Bell's phenomenon was classified according to the lower lid margin level and the direction and extent of eye movement. Bell's phenomenon was graded as positive if there was upward eye movement, negative if there was downward eye movement, and zero if there was no eye movement. Grade +2 indicated the presence of Bell's phenomenon with upward and strong eye movement. Grade +1 indicated the presence of Bell's phenomenon with upward but weak eye movement. Grade 0 indicated no eye movement and absence of Bell's phenomenon. The inverse Bell's phenomenon is characterized by downward eye movement. Grade -1 represented weak inverse, and grade -2 indicated a strong inverse Bell's phenomenon (Figure 1) (Table 1).

Data were analyzed using Statistical Software version 19.7.2 (MedCalc Software Ltd., Ostend, Belgium) [19]. Categorical variables are presented as frequencies and percentages. The Kruskal – Wallis test followed by pairwise post hoc analysis using the Dunn – Bonferroni method was used for comparisons between age groups. The Mann – Whitney U test was used for comparisons between sexes. A P -value < 0.05 was considered to indicate statistical significance.

RESULTS

In the examination of 165 asymptomatic healthy individuals (95 female [57.6%], 70 male [42.4%]), no ocular surface lesions were observed in 121 (73.3%), bilateral conjunctival calcifications/Vogt's limbal girdle were observed in 20 (12.1%), bilateral pinguecula in 20 (12.1%), and bilateral central horizontal oval punctate epitheliopathy in 4 (2.4%).

The frequency of each grade of Bell's phenomenon among asymptomatic individuals was documented according to age group (Table 2). Grade +2 Bell's phenomenon was more frequent in individuals aged 4 – 40 years, grade +1 was more frequent in individuals aged 41 – 60 years, and grade 0 was more frequent in individuals aged > 60 years (Table 2). There was a statistically significant difference between age groups with respect to

Table 2. Frequency of grades of Bell's phenomenon among age and sex groups in 165 asymptomatic participants

Age or sex group	Grade of Bell's phenomenon, n (%)					Total
	Grade +2	Grade +1	Grade 0	Grade -1	Grade -2	
4 – 20 y	22 (13.3)	10 (6.1)	2 (1.2)	1 (0.6)	4 (2.4)	39 (23.6)
21 – 40 y	14 (8.5)	6 (3.6)	2 (1.2)	0 (0.0)	2 (1.2)	24 (14.5)
41 – 60 y	15 (9.1)	20 (12.1)	16 (9.7)	1 (0.6)	3 (1.8)	55 (33.3)
> 60 y	7 (4.2)	13 (7.9)	20 (12.1)	1 (0.6)	6 (3.6)	47 (28.5)
Total	58 (35.2)	49 (29.7)	40 (24.2)	3 (1.8)	15 (9.1)	165 (100.0)
Men	23 (13.9)	21 (12.7)	19 (11.5)	1 (0.6)	6 (3.6)	70 (42.4)
Women	35 (21.2)	28 (17.0)	21 (12.7)	2 (1.2)	9 (5.5)	95 (57.6)

Abbreviations: y, years; n, number of individuals; %, percentage. Note: Percentages were calculated based on the frequency per 165 healthy participants in the control group.

Table 3. Frequency of ocular surface lesions in each grade of Bell's phenomenon among age and sex groups in 165 asymptomatic participants

Age or sex group	Grade of Bell's phenomenon, number of patients with ocular surface lesions (%) / total					Total
	Grade +2	Grade +1	Grade 0	Grade -1	Grade -2	
4 – 20 y	0 / 22	0 / 10	0 / 2	0 / 1	0 / 4	0 / 39
21 – 40 y	1 / 14	1 / 6	0 / 2	0 / 0	0 / 2	2 / 24
41 – 60 y	2 / 15	4 / 20	13 / 16	0 / 1	1 / 3	20 / 55
> 60 y	0 / 7	4 / 13	15 / 20	0 / 1	3 / 6	22 / 47
Total	3 (5.2) / 58	9 (18.4) / 49	28 (70.0) / 40	0 (0.0) / 3	4 (26.7) / 15	44 (26.7) / 165
Men	1 (4.3) / 23	4 (19.0) / 21	13 (68.4) / 19	0 (0.0) / 1	2 (33.3) / 6	20 (28.6) / 70
Women	2 (5.7) / 35	5 (17.9) / 28	15 (71.4) / 21	0 (0.0) / 2	2 (22.2) / 9	24 (25.3) / 95

Abbreviations: y, years; n, number of individuals; %, percentage.

Table 4. Bell's phenomenon classification and location of 45 ocular surface lesions in 40 symptomatic patients

Type of lesion	Grade +1	Grade 0	Grade -1	Grade -2
Bilateral inferior corneal punctate epitheliopathy	0	12	0	0
Bilateral central corneal punctate epitheliopathy	3	0	1	0
Bilateral superior corneal punctate epitheliopathy	0	0	0	3
Bilateral inferior pannus and corneal scarring	0	9	0	0
Inferior band keratopathy	0	2	0	0
Bilateral pinguecula	0	10	0	0
Conjunctival calcification or Vogt's limbal girdle	0	5	0	0
Total number of patients	3 lesions in 5 patients	38 lesions in 28 patients	1 lesion in 4 patients	3 lesions in 3 patients

Note: Grade, grading of Bell's phenomenon as detailed in Table 1. Note: Using the Kruskal – Wallis test, we observed a statistically significant difference between grades of Bell's phenomenon with respect to frequency of ocular surface lesions ($P < 0.001$). The post hoc Dunn – Bonferroni test revealed a significant difference in frequencies of ocular surface lesions between grade 0 and all other grades ($P < 0.001$).

grade frequency ($P < 0.001$). Pairwise analysis revealed a significantly higher frequency of grade +2 in the 4 – 20 year age group ($P = 0.012$) and the 21 – 40 year group ($P = 0.014$) than in individuals aged > 60 years. Half of the individuals with grade 0 Bell's phenomenon were aged > 60 years (Table 2).

Grade 0 Bell's phenomenon was detected in 21 of 95 female (22.1%) and 19 of 70 male patients (27.1%). Grade +2 was the most frequent grading in both sexes, being more common in women ($n = 35$) than in men ($n = 23$) (Table 2). However, the frequencies of grades were comparable between the two sexes ($P = 0.652$).

Concerning the frequencies of observed ocular surface lesions among age groups, of 39 asymptomatic individuals in the 4 – 20 year group, only 2 (5.1%) had grade 0 Bell's phenomenon (Table 2), with no lesions observed in individuals with any grade of Bell's phenomenon in this age group (Table 3). Of 24 asymptomatic

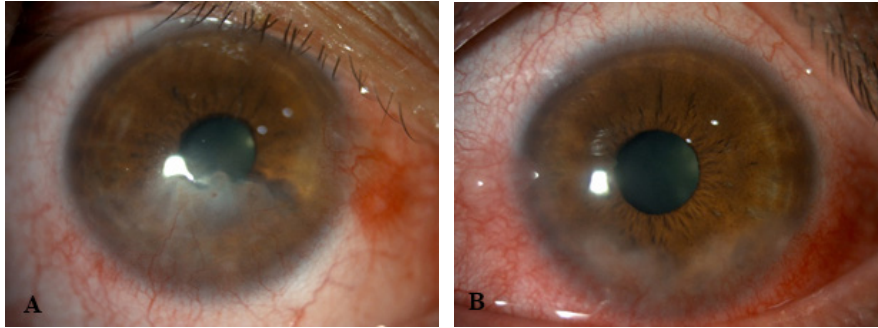


Figure 2. (A, B) Slit-lamp photographs of a symptomatic patient with grade 0 Bell's phenomenon show bilateral inferior limbal pannus and exposure keratopathy.

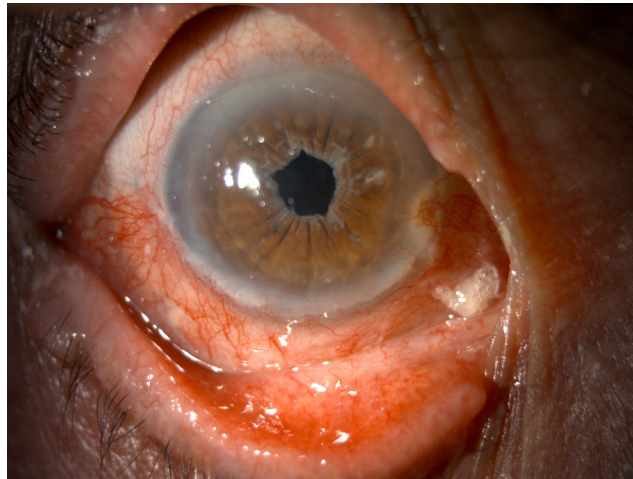


Figure 3. Slit-lamp photograph of a symptomatic patient with grade 0 Bell's phenomenon shows that the lower half of the conjunctiva is affected more than the upper half.

individuals in the 21 – 40 year group, only 2 (8.3%) had grade 0 Bell's phenomenon (Table 2), and bilateral conjunctival calcifications/Vogt's limbal girdle were observed in 2 individuals with grades +2 and +1 Bell's phenomenon (Table 3). Of 55 asymptomatic individuals in the 41 – 60 year group, 16 (29.1%) had grade 0 and 20 (36.4%) had grade +1 Bell's phenomenon (Table 2). In this age group, conjunctival calcifications/Vogt's limbal girdle were detected in 11 individuals and bilateral pinguecula were detected in 9 (Table 3). Among 47 asymptomatic individuals in the > 60 year group, grade 0 was detected in 20 (42.6%) (Table 2). In this age group, bilateral conjunctival calcifications/Vogt's limbal girdle were observed in 5 individuals, bilateral pinguecula were observed in 11 individuals, and bilateral central horizontal oval punctate epitheliopathy was found in 6 individuals (Table 3).

We observed a statistically significant difference between grades of Bell's phenomenon with respect to frequency of observed ocular surface lesions ($P < 0.001$). Pairwise analysis revealed a significantly higher frequency of ocular surface lesions in grade 0 versus each of the other four grades (all $P < 0.001$). However, there was no statistically significant difference in the frequency of ocular surface lesions between the two sexes ($P = 0.636$).

Of 69 asymptomatic participants aged > 40 years who had grades 0 and +1 Bell's phenomenon (Table 2), 18 had bilateral conjunctival calcifications/Vogt's limbal girdle and 18 had bilateral pinguecula (Table 3). Bilateral central horizontal epitheliopathy was observed in 6 of 15 individuals with ocular surface lesions in the > 60 year group who had grade 0 Bell's phenomenon (Table 3), while this was not observed in the other age groups. No corneal epithelial lesions were observed in individuals with grades -1 and -2 in the > 60 year group (Table 3). This may indicate that inverse Bell's phenomenon is more protective than grade 0.

Among the 40 symptomatic individuals in the patient group, grades 0, +1, -1, and -2 Bell's phenomenon were detected in 28 (70%), 5 (12.5%), 4 (10%), and 3 (7.5%) patients (Table 4). As listed in Table 4, among 28 symptomatic patients with grade 0 Bell's phenomenon, 38 ocular surface lesions were detected. Because

some patients had two distinct, simultaneous, bilateral lesions, the number of observed lesions was more than 28. While corneal punctate epitheliopathy was observed in the superior corneal and limbal regions in 3 patients with grade -2 Bell's phenomenon, the same was observed in the central or inferior corneal and limbal regions in individuals with grades +1, 0, and -1 Bell's phenomenon (Table 4). In the patient group, no individuals had a strong grade +2 Bell's phenomenon. In this group, the observed lesions were bilateral, horizontal, oval, and within the interpalpebral fissure area. In symptomatic patients, grade 0 Bell's phenomenon (n=28) was more frequent than the other grades (grade +1, -1, and -2: 12 patients), with a higher frequency of ocular surface lesions (n=38 lesions) than in the other grades (grade +1, -1, and -2: 7 lesions) (Table 4). Three patients with grade -2 Bell's phenomenon had bilateral superior corneal punctate epitheliopathy (Table 4), and the superior limbal palisades of Vogt were more prominent.

Figures 2 and 3 display slit-lamp photographs of 2 patients with ocular surface lesions in the absence of Bell's phenomenon (grade 0). In Figure 2, slit-lamp photographs of a 38-year-old symptomatic patient with grade 0 Bell's phenomenon show bilateral inferior limbal exposure keratopathy and pannus sparing the upper half of the cornea. In Figure 3, a slit-lamp photograph of an 85-year-old patient with grade 0 Bell's phenomenon shows that the lower half of the conjunctiva is affected more than the upper half.

DISCUSSION

Using a simple, practical grading scale for Bell's phenomenon, we observed no sex predominance in either the frequency of each grade or the frequency of ocular surface lesions observed in each grade in healthy individuals. However, we observed a significant difference between age groups with respect to the frequency of different grades. Because grade 0 was the most frequent among symptomatic patients, and ocular surface lesions were most frequent in patients with this grade, grade 0 may be the least protective compared with grades +1, -1, and -2.

Bell's phenomenon is a critical reflex that protects the cornea [20]. It is characterized by upward and outward movement of the eyeball [21]. Inverse Bell's phenomenon has been reported as a finding coincident with corneal degeneration [22], a transient phenomenon after surgery [23-28] or trauma [29], or a finding associated with underlying neurodegenerative disorders [30]. Our participants with inverse Bell's phenomenon in both the asymptomatic and symptomatic groups had no history of trauma or surgery or any underlying systemic comorbidities.

Superficial corneal lesions are often associated with chronic ocular inflammatory conditions [31] and are usually present within the interpalpebral fissure area [31, 32]. In the etiopathogenesis of superficial corneal

Table 5. Summary of inverse Bell's phenomenon cases [22-30] retrieved in a PubMed literature review

Author (Year)	Patients	The cause of inverse Bell's phenomenon	Transient / Permanent
Nissirios et al. (2013) [22]	Five out of 10 patients with Salzmann nodular degeneration.	Superior Salzmann nodular degeneration was detected.	Permanent.
Goel et al. (2017) [23]	Two out of 32 patients.	Levator resection for congenital ptosis.	Transient Bell's phenomenon lasted for 1 – 2 weeks.
Na and Yang (2009) [24]	Two patients: a 22-year-old woman and a 19-year-old man.	Levator resection for congenital ptosis.	Transient Bell's phenomenon lasted for 1 – 2 weeks.
Betharia (2006) [25]	Three patients: a 12-year-old man, a 16-year-old girl, and a 22-year-old man.	Levator resection for blepharoptosis.	Transient Bell's phenomenon.
Pandey et al. (2019) [26]	A 9-year-old girl.	Frontalis sling-suspension ptosis surgery.	Transient Bell's phenomenon lasted for 3 weeks.
Shitole et al. (2015) [27]	A 24-year-old man.	Following ptosis surgery.	Transient Bell's phenomenon lasted for 4 weeks.
Morawala. (2019) [28]	A 27-year-old woman.	Levator resection for congenital ptosis.	Transient Bell's phenomenon lasted for 1 week.
Liakopoulos et al. (2021) [29]	A 6-year-old girl.	Upper eyelid trauma.	Late onset Bell's phenomenon.
Esteban et al. (1978) [30]	Two out of 24 patients with amyotrophic lateral sclerosis.	Amyotrophic lateral sclerosis.	Not mentioned.

lesions in advanced age, many conditions, such as incomplete lid closure, lack of blinking, lid anomalies, ectropion/entropion, delayed tear clearance, and sunken upper eyelids may play a role [33, 34]. The ocular surface is preserved in individuals with intact Bell's phenomenon [35]. We observed that the frequency of superficial corneal lesions increased in individual without a strong Bell's phenomenon. We hypothesized that weak Bell's phenomenon is one of many causes of superficial corneal lesions. We classified Bell's phenomenon by taking facial photographs of all patients with exposure keratopathy [36] who presented to our department within a 1-year period. Most patients with bilateral horizontal corneal lesions did not have a strong Bell's phenomenon. Therefore, we developed a practical grading scale that includes the inverse Bell's phenomenon and used it for grading of Bell's phenomenon in study participants.

The frequency of different grades of Bell's phenomenon varied significantly with age. We observed that grade 0 was more common in the group aged > 60 years. The inverse Bell's phenomenon was observed in 18 (11%) of our healthy asymptomatic participants. The inverse Bell's phenomenon in normal individuals may have a protective effect on the ocular surface compared to grade 0, as we observed a significantly higher frequency of ocular surface lesions in grade 0 compared with grades -1 and -2. Therefore, we hypothesized that the impairment of upward eye movement due to trauma or surgery elicits a downward eye movement to protect the cornea. There are several reports in the literature on inverse Bell's phenomenon, in which the eye moves downward [22-30]. Most studies reported inverse Bell's phenomenon as a complication after surgery or trauma [23-29]. A few authors, such as Gupta et al. [37], have characterized inverse Bell's phenomenon as a protective reflex.

Searching PubMed without time or language restrictions, we retrieved 18 reported cases of inverse Bell's phenomenon [22-30], 11 of which were transient cases that developed after ptosis surgery or trauma [23-29] (Table 5). Nissirios et al. [22] observed inverse Bell's phenomenon in 5 of 10 patients with Salzmann nodular degeneration; however, they did not classify these as Bell's phenomenon. Interestingly, the lesion location was superior in those with inverse Bell's phenomenon [22], as we observed in our patients with grade -2. Goel et al. [23] detected transient inverse Bell's phenomenon after levator resection in 2 of 32 patients with congenital ptosis. Na and Yang [24] reported 2 patients with transient inverse Bell's phenomenon within 2 weeks after levator resection. Betharia et al. [25] reported 3 patients with transient inverse Bell's phenomenon after levator resection. Pandey et al. [26] detected transient inverse Bell's phenomenon in a 9-year-old girl after ptosis surgery using frontalis sling suspension. Shitole et al. [27] detected an inverse Bell's phenomenon in a 24-year-old man after ptosis surgery. Morawala et al. [28] detected a transient inverse Bell's phenomenon in a patient with congenital ptosis after levator resection. Liakopoulos et al. [29] reported late-onset inverse Bell's phenomenon after trauma in a 6-year-old girl. Esteban et al. [30] evaluated Bell's phenomenon in 24 patients with amyotrophic lateral sclerosis in three groups: attenuated, abolished, and reversed Bell's phenomenon. They observed inverse Bell's phenomenon in 2 patients. Chung et al. [38] reported absence of Bell's phenomenon in 14 of 104 patients with thyroid eye disease. Eshraghi et al. [8] observed weakening of Bell's phenomenon in 30 patients after inferior and medial orbital wall decompression for thyroid-associated ophthalmopathy. Hartford et al. [39] reported absence of Bell's phenomenon in 20 of 65 patients admitted to an intensive care unit. Honda et al. [40] observed that 53 patients with muscular dystrophy had weak Bell's phenomenon.

The incidence of superficial corneal lesions increases with age [41, 42]. We observed a higher frequency of superficial corneal and conjunctival lesions in those with grade 0 Bell's phenomenon. Superficial corneal lesions were less frequent in those with inverse Bell's phenomenon. Although some corneal lesions were detected in patients with inverse Bell's phenomenon, the frequency of corneal lesions and the severity of symptoms were higher in those with grade 0. Therefore, downward eye movement may protect the eyes with inverse Bell's phenomenon. Lesions in grades 0, +1, and -1 were mainly in the central and inferior horizontal regions. Lesions in grade -2 were mainly in the superior corneal and limbal regions. Grades +2, +1, and 0 Bell's phenomenon were more common in those under 40 years of age, in those 41 - 60 years of age, and in those > 60 years of age, respectively. This suggests weakening of Bell's phenomenon with age. The Bell's phenomenon examination revealed that young participants had more vigorous eye movement.

We developed a simple, practical grading scale that includes grades -1 and -2 for weak and strong inverse Bell's phenomenon, respectively, and we graded Bell's phenomenon in asymptomatic and symptomatic participants with and without ocular surface lesions. In previous research, Bell's phenomenon was assessed using different methods. Takahashi et al. [3] measured the upward range of motion of the inferior corneal limbus after inferior rectus surgery in 12 patients with thyroid-associated inferior rectus myopathy. They demonstrated that Bell's phenomenon weakened on the operated side. Eshraghi et al. [8] measured the distance between the lower eyelid margin and the corneal limbus to evaluate Bell's phenomenon in 30 patients with orbital wall

decompression after thyroid-associated ophthalmopathy [8]. This distance measurement method is not very practical, and it cannot evaluate inverse Bell's phenomenon. Mustafa classified Bell's phenomenon in newborns but did not include inverse Bell's phenomenon in the classification [7].

Bell's phenomenon should be assessed in the presence of horizontal ocular surface lesions or if lesions are recurrent. When planning eyelid surgery, the Bell's phenomenon grade should be considered. It is wise to determine whether the eyelids completely close while the patient sleeps, because in those with Bell's phenomenon weaker than grade +2, incomplete eyelid closure may cause chronic recurrent corneal lesions. Regardless of the grade of Bell's phenomenon, corneal symptoms are mild in patients whose eyelids fully close while sleeping. Patients with open eyelids should be conservatively managed by closing the eyelids using tape [43, 44], rather than using medical therapy, because of the risk of bacterial contamination of eye drops with prolonged use [45, 46].

We developed a simple, practical grading scale for Bell's phenomenon and observed a frequent presentation of ocular surface lesions in individuals with grade 0. The corresponding grades of inverse Bell's phenomenon may have protective roles similar to those of grades +2 and +1. Limitations of this study included its cross-sectional design and unequal numbers of participants in the symptomatic and asymptomatic groups. Further large-scale prospective cohort studies are necessary to establish a causal association between our grades of Bell's phenomenon and the presence or absence of ocular surface lesions.

CONCLUSIONS

Using a simple, practical grading scale for Bell's phenomenon that includes inverse Bell's phenomenon, we observed that inverse Bell's phenomenon is a reflex that may be present in healthy individuals and could have a protective effect on the eye, although not to such a degree as a strong Bell's phenomenon. Our observations imply that bilateral conjunctival calcifications/Vogt's limbal girdle may be associated with grades 0 and +1 Bell's phenomenon. Further large-scale studies are needed to determine the frequency of Bell's phenomenon in the general population using this innovative, simple, practical grading scale, and to identify the protective or injurious effect of each grade on the ocular surface.

ETHICAL DECLARATIONS

Ethical approval: Ethical approval for this study was obtained from the Ethics Committee of Istanbul Medeniyet University Goztepe Training and Research Hospital clinical research on April 13, 2022 (decision number: 2023/0094). The study participants provided informed consent for participation and publication of their data.

Conflict of interest: None.

FUNDING

None.

ACKNOWLEDGMENTS

None.

REFERENCES

- Liu GT, Volpe NJ, Galetta SL (2019). 'The neuro-ophthalmic examination'. In Liu, Volpe, and Galetta's Neuro-Ophthalmology third edition (pp. 7-36). Elsevier. doi: 10.1016/B978-0-323-34044-1.00002-X
- Wilkins RH, Brody IA. Bell's palsy and Bell's phenomenon. Arch Neurol. 1969;21(6):661-2. doi: 10.1001/archneur.1969.00480180117012 pmid: 4901420
- Takahashi Y, Sabundayo MS, Mito H, Miyazaki H, Kakizaki H. Bell's phenomenon in thyroid-associated inferior rectus myopathy. Graefes Arch Clin Exp Ophthalmol. 2017;255(12):2467-2471. doi: 10.1007/s00417-017-3792-9 pmid: 28861686
- Al-Zubi KM, Al-Kubaisy WA, Al-Azzeh YE, Batayneh BK, Alqaraleh HA, Abid LA, et al. Symptomatic dry eye disease among university students. Med Hypothesis Discov Innov Ophthalmol. 2023;12(2):70-77. doi: 10.51329/mehdiophthal1472 pmid: 38357613
- Kaye AD, Renschler JS, Cramer KD, Anyama BO, Anyama EC, Gayle JA, et al. Postoperative Management of Corneal Abrasions and Clinical Implications: a Comprehensive Review. Curr Pain Headache Rep. 2019;23(7):48. doi: 10.1007/s11916-019-0784-y pmid: 31147838
- Cruz AA, Garcia DM, Pinto CT, Cechetti SP. Spontaneous eyeblink activity. Ocul Surf. 2011;9(1):29-41. doi: 10.1016/s1542-0124(11)70007-6 pmid: 21338567
- Mustafa TA. The Bell's phenomenon in newborns. Neurosciences (Riyadh). 2005;10(1):41-3. pmid: 22473182
- Eshraghi B, Moayeri M, Pourazizi M, Rajabi MT, Rafizadeh M. Decreased Bell's phenomenon after inferior and medial orbital wall

- decompression in thyroid-associated ophthalmopathy: a double-edged sword in management of the patients. *Graefes Arch Clin Exp Ophthalmol.* 2022;260(5):1701-1705. doi: [10.1007/s00417-021-05509-1](https://doi.org/10.1007/s00417-021-05509-1) pmid: [34851466](https://pubmed.ncbi.nlm.nih.gov/34851466/)
9. Vignesh AP, Srinivasan R, Karanth S, Vijitha S. A Case Report of Vogt's Limbal Girdle and Retinitis Pigmentosa in a Thirteen-Year-Old Boy: A Rare and Unusual Association. *Case Rep Ophthalmol.* 2015;6(3):311-6. doi: [10.1159/000439265](https://doi.org/10.1159/000439265) pmid: [26483674](https://pubmed.ncbi.nlm.nih.gov/26483674/)
 10. Moshirfar M, Villarreal A, Ronquillo Y. Furrow Degeneration. 2023. In: *StatPearls* [Internet]. Treasure Island (FL): StatPearls Publishing; 2024-. pmid: [32491464](https://pubmed.ncbi.nlm.nih.gov/32491464/)
 11. Serra HM, Moro PA. Climatic Droplet Keratopathy Is a Misnomer for This Corneal Degeneration. *Semin Ophthalmol.* 2023;38(6):515-520. doi: [10.1080/08820538.2023.2176240](https://doi.org/10.1080/08820538.2023.2176240) pmid: [36794906](https://pubmed.ncbi.nlm.nih.gov/36794906/)
 12. Brown AC, Nataneli N. Salzmanns Nodular Corneal Degeneration. 2023. In: *StatPearls* [Internet]. Treasure Island (FL): StatPearls Publishing; 2024-. pmid: [32809519](https://pubmed.ncbi.nlm.nih.gov/32809519/)
 13. Canellos HM, Cooper J, Paek A, Chien J. Multiple calcified deposits along the eyelid margins secondary to chronic renal failure and hyperparathyroidism. *Optometry.* 2005;76(3):181-4. doi: [10.1016/s1529-1839\(05\)70283-9](https://doi.org/10.1016/s1529-1839(05)70283-9) pmid: [15786637](https://pubmed.ncbi.nlm.nih.gov/15786637/)
 14. Yilmaz OF, Sarmis A, Mutlu MA, Oguz H. Does corneal tattooing affect the conjunctival microbiota? *Cutan Ocul Toxicol.* 2023;1-6. doi: [10.1080/15569527.2023.2275025](https://doi.org/10.1080/15569527.2023.2275025) pmid: [37879108](https://pubmed.ncbi.nlm.nih.gov/37879108/)
 15. Yilmaz OF, Oguz H. Aesthetic corneal tattooing/keratopigmentation using tattoo pen machine: choosing suitable method and color. *Graefes Arch Clin Exp Ophthalmol.* 2023;261(12):3531-3540. doi: [10.1007/s00417-023-06135-9](https://doi.org/10.1007/s00417-023-06135-9) pmid: [37318581](https://pubmed.ncbi.nlm.nih.gov/37318581/)
 16. Shah KP, Mukherjee B. Efficacy of frontalis suspension with silicone rods in ptosis patients with poor Bell's phenomenon. *Taiwan J Ophthalmol.* 2017;7(3):143-148. doi: [10.4103/tjo.tjo_36_17](https://doi.org/10.4103/tjo.tjo_36_17) pmid: [29034153](https://pubmed.ncbi.nlm.nih.gov/29034153/)
 17. Branham G, Holds JB. Brow/Upper lid anatomy, aging and aesthetic analysis. *Facial Plast Surg Clin North Am.* 2015;23(2):117-27. doi: [10.1016/j.fsc.2015.01.001](https://doi.org/10.1016/j.fsc.2015.01.001) pmid: [25921563](https://pubmed.ncbi.nlm.nih.gov/25921563/)
 18. Esteban A, Traba A, Prieto J. Eyelid movements in health and disease. The supranuclear impairment of the palpebral motility. *Neurophysiol Clin.* 2004;34(1):3-15. doi: [10.1016/j.neucli.2004.01.002](https://doi.org/10.1016/j.neucli.2004.01.002) pmid: [15030796](https://pubmed.ncbi.nlm.nih.gov/15030796/)
 19. MedCalc (2024). 'MedCalc Software Ltd'. Available at: <https://www.medcalc.org> (Accessed: December 01, 2023)
 20. Mosieri CN, Arthur ME. (2019). 'Eye Injury'. In: Fox, III C, Cornett E, Ghali G. (eds). *Catastrophic Perioperative Complications and Management.* (pp 197–211). Springer, Cham. doi: [10.1007/978-3-319-96125-5_14](https://doi.org/10.1007/978-3-319-96125-5_14)
 21. Iwasaki M, Kellinghaus C, Alexopoulos AV, Burgess RC, Kumar AN, Han YH, et al. Effects of eyelid closure, blinks, and eye movements on the electroencephalogram. *Clin Neurophysiol.* 2005;116(4):878-85. doi: [10.1016/j.clinph.2004.11.001](https://doi.org/10.1016/j.clinph.2004.11.001) pmid: [15792897](https://pubmed.ncbi.nlm.nih.gov/15792897/)
 22. Nissirios NJ, Barsam A, Nadji E, Donnenfeld ED, Perry HD. Relationship of Bell phenomenon with Salzmann nodular degeneration. *Cornea.* 2013;32(7):939-42. doi: [10.1097/ICO.0b013e318281722b](https://doi.org/10.1097/ICO.0b013e318281722b) pmid: [23442252](https://pubmed.ncbi.nlm.nih.gov/23442252/)
 23. Goel R, Kishore D, Nagpal S, Jain S, Agarwal T. The Relationship of Amount of Resection and Time for Recovery of Bell's Phenomenon after Levator Resection in Congenital Ptosis. *Open Ophthalmol J.* 2017;11:24-30. doi: [10.2174/1874364101711010024](https://doi.org/10.2174/1874364101711010024) pmid: [28584563](https://pubmed.ncbi.nlm.nih.gov/28584563/)
 24. Na KS, Yang SW. Two cases of inverse Bell's phenomenon following levator resection: a contemplation of the mechanism. *Eur J Ophthalmol.* 2009;19(2):285-7. doi: [10.1177/112067210901900218](https://doi.org/10.1177/112067210901900218). Erratum in: *Eur J Ophthalmol.* 2009;19(4):696. pmid: [19253248](https://pubmed.ncbi.nlm.nih.gov/19253248/)
 25. Betharia SM, Sharma V. Inverse Bell's phenomenon observed following levator resection for blepharoptosis. *Graefes Arch Clin Exp Ophthalmol.* 2006;244(7):868-70. doi: [10.1007/s00417-005-0122-4](https://doi.org/10.1007/s00417-005-0122-4) pmid: [16175375](https://pubmed.ncbi.nlm.nih.gov/16175375/)
 26. Pandey TR, Limbu B, Rajkarnikar Sthapit P, Gurung HB, Saiju R. Transient Inverse Bell's Phenomenon Following Frontalis Sling-Suspension Ptosis Surgery: A Rare Ophthalmic Phenomenon. *Int Med Case Rep J.* 2019;12:325-327. doi: [10.2147/IMCRJ.S216805](https://doi.org/10.2147/IMCRJ.S216805) pmid: [31802953](https://pubmed.ncbi.nlm.nih.gov/31802953/)
 27. Shitole S, Jakkal T, Khaire B. Inverse Bell's Phenomenon: Rare Ophthalmic Finding Following Ptosis Surgery. *J Clin Diagn Res.* 2015;9(3):ND01-2. doi: [10.7860/JCDR/2015/11340.5686](https://doi.org/10.7860/JCDR/2015/11340.5686) pmid: [25954644](https://pubmed.ncbi.nlm.nih.gov/25954644/)
 28. Morawala A, Sharma A, Naik MN. Inverse Bell's phenomenon: a rare complication of levator resection surgery in a case of congenital ptosis. *BMJ Case Rep.* 2019;12(11):e232451. doi: [10.1136/bcr-2019-232451](https://doi.org/10.1136/bcr-2019-232451) pmid: [31791995](https://pubmed.ncbi.nlm.nih.gov/31791995/)
 29. Liakopoulos DA, Bontzos G, Detorakis ET. Late-onset inverse Bell's phenomenon after upper eyelid trauma. *Natl J Maxillofac Surg.* 2021;12(2):262-265. doi: [10.4103/njms.NJMS_283_20](https://doi.org/10.4103/njms.NJMS_283_20) pmid: [34483587](https://pubmed.ncbi.nlm.nih.gov/34483587/)
 30. Esteban A, De Andrés C, Giménez-Roldán S. Abnormalities of Bell's phenomenon in amyotrophic lateral sclerosis: a clinical and electrophysiological evaluation. *J Neurol Neurosurg Psychiatry.* 1978;41(8):690-8. doi: [10.1136/jnnp.41.8.690](https://doi.org/10.1136/jnnp.41.8.690) pmid: [681956](https://pubmed.ncbi.nlm.nih.gov/681956/)
 31. Kuan HC, Ivan Cheng EY, Yong MH, Wan Abdul Halim WH, Othman O. Corneal Nodules and Possible Pathologies: A Case Series. *Cureus.* 2021;13(12):e20822. doi: [10.7759/cureus.20822](https://doi.org/10.7759/cureus.20822) pmid: [35141078](https://pubmed.ncbi.nlm.nih.gov/35141078/)
 32. Magovern M, Wright JD Jr, Mohammed A. Spheroidal degeneration of the cornea: a clinicopathologic case report. *Cornea.* 2004;23(1):84-8. doi: [10.1097/00003226-200401000-00015](https://doi.org/10.1097/00003226-200401000-00015) pmid: [14701964](https://pubmed.ncbi.nlm.nih.gov/14701964/)
 33. Labib A, Patel BC, Milroy C. Lower Eyelid Laxity Examination. 2023 May. In: *StatPearls* [Internet]. Treasure Island (FL): StatPearls Publishing; 2024-. pmid: [35015428](https://pubmed.ncbi.nlm.nih.gov/35015428/)
 34. Milner MS, Beckman KA, Luchs JI, Allen QB, Awdeh RM, Berdahl J, et al. Dysfunctional tear syndrome: dry eye disease and associated tear film disorders - new strategies for diagnosis and treatment. *Curr Opin Ophthalmol.* 2017;27 Suppl 1(Suppl 1):3-47. doi: [10.1097/01.icu.0000512373.81749.b7](https://doi.org/10.1097/01.icu.0000512373.81749.b7) pmid: [28099212](https://pubmed.ncbi.nlm.nih.gov/28099212/)
 35. Yoon JS, Lew H, Lee SY. Bell's phenomenon protects the tear film and ocular surface after frontalis suspension surgery for congenital ptosis. *J Pediatr Ophthalmol Strabismus.* 2008;45(6):350-5. doi: [10.3928/01913913-20081101-17](https://doi.org/10.3928/01913913-20081101-17) pmid: [19043946](https://pubmed.ncbi.nlm.nih.gov/19043946/)
 36. Ruiz-Lozano RE, Gomez-Elizondo DE, Colorado-Zavala MF, Loya-Garcia D, Rodriguez-Garcia A. Update on indications, complications, and outcomes of scleral contact lenses. *Med Hypothesis Discov Innov Ophthalmol.* 2022;10(4):165-178. doi: [10.51329/mehdiophthal1435](https://doi.org/10.51329/mehdiophthal1435) pmid: [37641653](https://pubmed.ncbi.nlm.nih.gov/37641653/)
 37. Gupta JS, Chatterjee A, Kumar K. Inverse Bell's Phenomenon as a Protective Mechanism. *Am J Ophthalmol.* 1965;59:931-3. pmid: [14288945](https://pubmed.ncbi.nlm.nih.gov/14288945/)
 38. Chung HW, Lee H, Baek S. Absent Bell's phenomenon in patients with thyroid eye disease. *BMC Ophthalmol.* 2021;21(1):361. doi: [10.1186/s12886-021-02107-x](https://doi.org/10.1186/s12886-021-02107-x) pmid: [34635084](https://pubmed.ncbi.nlm.nih.gov/34635084/)

39. Hartford JB, Bian Y, Mathews PM, De Rojas J, Garg A, Rasool N, et al. Prevalence and Risk Factors of Exposure Keratopathy Across Different Intensive Care Units. *Cornea*. 2019;38(9):1124-1130. doi: [10.1097/ICO.0000000000001961](https://doi.org/10.1097/ICO.0000000000001961) pmid: [31394552](https://pubmed.ncbi.nlm.nih.gov/31394552/)
40. Honda Y, Yoshioka M. Ophthalmological findings of muscular dystrophies: a survey of 53 cases. *J Pediatr Ophthalmol Strabismus*. 1978;15(4):236-8. doi: [10.3928/0191-3913-19780701-12](https://doi.org/10.3928/0191-3913-19780701-12) pmid: [739358](https://pubmed.ncbi.nlm.nih.gov/739358/)
41. Cerulli L, Missiroli F. (2008). 'Aging of the Cornea'. In: Cavallotti CAP, Cerulli L (eds) *Age-Related Changes of the Human Eye*. Aging Medicine. (pp 45–60). Humana Press. doi: [10.1007/978-1-59745-507-7_4](https://doi.org/10.1007/978-1-59745-507-7_4)
42. Farjo AA, Halperin GI, Syed N, Sutphin JE, Wagoner MD. Salzmann's nodular corneal degeneration clinical characteristics and surgical outcomes. *Cornea*. 2006;25(1):11-5. doi: [10.1097/01.ico.0000167879.88815.6b](https://doi.org/10.1097/01.ico.0000167879.88815.6b) pmid: [16331034](https://pubmed.ncbi.nlm.nih.gov/16331034/)
43. Ahmadinejad M, Karbasi E, Jahani Y, Ahmadipour M, Soltaninejad M, Karzari Z. Efficacy of Simple Eye Ointment, Polyethylene Cover, and Eyelid Taping in Prevention of Ocular Surface Disorders in Critically Ill Patients: A Randomized Clinical Trial. *Crit Care Res Pract*. 2020;2020:6267432. doi: [10.1155/2020/6267432](https://doi.org/10.1155/2020/6267432) pmid: [32351735](https://pubmed.ncbi.nlm.nih.gov/32351735/)
44. Pham TT, Perry JD. Floppy eyelid syndrome. *Curr Opin Ophthalmol*. 2007;18(5):430-3. doi: [10.1097/ICU.0b013e3282ced08e](https://doi.org/10.1097/ICU.0b013e3282ced08e) pmid: [17700238](https://pubmed.ncbi.nlm.nih.gov/17700238/)
45. Yilmaz OF, Sarmis A, Mutlu MA, Ersoy EE, Askarova U, Oguz H. Bacterial contamination of multi-use antibiotic steroid eye ointments and drops. *Graefes Arch Clin Exp Ophthalmol*. 2023;261(6):1691-1700. doi: [10.1007/s00417-023-05977-7](https://doi.org/10.1007/s00417-023-05977-7) pmid: [36642767](https://pubmed.ncbi.nlm.nih.gov/36642767/)
46. Faruk Yilmaz O, Sarmis A, Ali Mutlu M, Büsra Sahin Z, Pelin Kaya S, Oguz H. Bacterial contamination of multi-use tear drops, gels, and ointments. *Cont Lens Anterior Eye*. 2023;46(6):102064. doi: [10.1016/j.clae.2023.102064](https://doi.org/10.1016/j.clae.2023.102064) pmid: [37806847](https://pubmed.ncbi.nlm.nih.gov/37806847/)