

Case Report

Phenotypic Variability of Andersen–Tawil Syndrome Due to Allelic Mutation c.652C>T in the *KCNJ2* Gene—A New Family Case Report

Maria Elena Onore ¹, Esther Picillo ¹, Paola D’Ambrosio ², Salvatore Morra ¹, Vincenzo Nigro ^{1,3} and Luisa Politano ^{2,*}

¹ Department of Precision Medicine, University of Campania “Luigi Vanvitelli”, 80138 Naples, Italy; mariaelena.onore@unicampania.it (M.E.O.); esther.picillo@unicampania.it (E.P.); salvatore.morra@unicampania.it (S.M.); vincenzo.nigro@unicampania.it (V.N.)

² Cardiology and Medical Genetics Unit, University of Campania “Luigi Vanvitelli”, 80138 Napoli, Italy; paoladambrosio@gmail.com

³ Telethon Institute of Genetics and Medicine (TIGEM), 80078 Pozzuoli, Italy

* Correspondence: luisa.politano@unicampania.it

Abstract: Andersen–Tawil syndrome (ATS) is a multisystem channelopathy characterized by periodic paralysis, ventricular arrhythmias, prolonged QT interval, and facial dysmorphism occurring in the first/second decade of life. High phenotypic variability and incomplete penetrance of the genes causing the disease make its diagnosis still a challenge. We describe a three-generation family with six living individuals affected by ATS. The proband is a 37-year-old woman presenting since age 16, with episodes of muscle weakness and cramps in the pre-menstrual period. The father, two brothers, one paternal uncle and one cousin also complained of cramps, muscle stiffness, and weakness. Despite normal serum potassium concentration, treatment with potassium, magnesium, and acetazolamide alleviated paralysis attacks suggesting a dyskaemic syndrome. Dysmorphic features were noted in the proband, only later. On the ECG, all but one had normal QT intervals. The affected males developed metabolic syndrome or obesity. The father had two myocardial infarctions and was implanted with an intracardiac cardioverter defibrillator (ICD). A genetic investigation by WES analysis detected the heterozygous pathogenic variant (NM_000891.2: c.652C>T, p. Arg218Trp) in the *KCNJ2* gene related to ATS, confirmed by segregation studies in all affected members. Furthermore, we performed a review of cases with the same mutation in the literature, looking for similarities and divergences with our family case.

Keywords: *KCNJ2* gene; Andersen–Tawil syndrome; channelopathies; Kir2.1 mutations; Arg218Trp; R218W



Citation: Onore, M.E.; Picillo, E.; D’Ambrosio, P.; Morra, S.; Nigro, V.; Politano, L. Phenotypic Variability of Andersen–Tawil Syndrome Due to Allelic Mutation c.652C>T in the *KCNJ2* Gene—A New Family Case Report. *Biomolecules* **2024**, *14*, 507. <https://doi.org/10.3390/biom14040507>

Academic Editor: Domenico Lio

Received: 28 March 2024

Revised: 17 April 2024

Accepted: 19 April 2024

Published: 22 April 2024



Copyright: © 2024 by the authors. Licensee MDPI, Basel, Switzerland. This article is an open access article distributed under the terms and conditions of the Creative Commons Attribution (CC BY) license (<https://creativecommons.org/licenses/by/4.0/>).

1. Introduction

Channelopathies are a group of rare genetic neuromuscular disorders (NMDs) caused by dysfunction of chloride, sodium, calcium, and potassium ion channels, which are critical for muscle membrane excitability [1]. Non-dystrophic myotonias (NDM) and periodic paralyses (PP) are included in this group of genetic NMDs.

Non-dystrophic myotonias include myotonia congenita, paramyotonia congenita, and sodium channel myotonia [2]. Myotonia congenita is caused by pathogenic mutations in genes encoding chloride (*CLCN1*) and voltage-dependent muscle sodium (*SCN4A*) channels. Two forms of myotonia congenita have been described, the autosomal dominant form, better known as Thomsen disease (MIM #160800) [3] due to heterozygous pathogenic variants in *CLCN1*, and the autosomal recessive form, known as Becker disease (MIM #255700) due to bi-allelic pathogenic variants in *CLCN1* gene. Paramyotonia congenita (MIM #168300) and sodium channel myotonia (MIM #608390), both inherited as autosomal dominant traits, are caused by pathogenic mutations in the *SCN4A* gene. However,

mutations in the *SCN4A* gene have also been found in periodic paralysis conditions, due to potassium electrolyte imbalance. Hypokalemic periodic paralysis (hypoPP), hyperkalemic periodic paralysis (hyperPP), and Andersen–Tawil syndrome are included in this second group of channelopathies (PP) [1], in which muscle stiffness/weakness may be the predominant clinical symptom.

Hypokalemic periodic paralyzes (hypoPPs) are autosomal dominant conditions characterized by recurrent episodes of muscle weakness and low serum potassium concentrations (hypokalemia).

Based on specific gene mutations, hypoPPs are subdivided into two different groups: hypokalemic periodic paralysis Type 1 (MIM #170400), due to heterozygous mutations in the *CACNA1S* gene (occurring in 80% of cases) and hypokalemic periodic paralysis Type 2 (MIM #613345) due to mutations in *SCN4A* gene (occurring in 10% of cases) [1].

Hyperkalemic periodic paralysis (hyperPP) is characterized by high serum potassium concentrations (hyperkalemia) [4] in individuals affected and is also caused by pathogenic mutations in the *SCN4A* gene [5,6].

Andersen–Tawil syndrome (ATS), also defined as Andersen cardiodyrhythmic periodic paralysis, is an autosomal dominant multisystem channelopathy characterized by periodic paralysis, prolonged QT interval, ventricular arrhythmias, and facial dysmorphisms. ATS was first reported in 1971 [7] and then characterized in 1994 [8].

Mutations in the *KCNJ2* gene were first associated with Andersen–Tawil syndrome in 2001 [9] and until now more than 90 pathogenic mutations have been reported in the literature [10]. Clinically, the hypokalemic periodic paralysis picture and cardiac abnormalities, including ventricular arrhythmias, prolonged QT interval, and prominent U wave, occur in the first or second decade of life [11]. Dysmorphic features including broad forehead, hypoplastic mandible, hypotelorism, low-set ears, widely spaced eyes, fifth digit clinodactyly, syndactyly, short stature, and scoliosis are reported in 67–75% of affected patients [12]. Mild learning difficulties are also described [13].

The *KCNJ2* gene, localized on chromosome 17 (17q24.3), encodes for the inwardly rectifying potassium channel subunits Kir2.1, a channel that can assume a homo— or heteromeric conformation [14]. Each monomer consists of two transmembrane helix segments, M1 and M2, a single ion-selective pore, and a cytoplasmic amino (NH₂), and carboxyl (COOH) domains [15]. The Kir2 subfamily consists of six members (Kir2.1–Kir2.6) encoded by *KCNJ2*, *KCNJ12*, *KCNJ4*, *KCNJ14*, *KCNJ17*, and *KCNJ18* genes, respectively [16]. While Kir2.6 is primarily expressed in skeletal muscles and Kir2.4 in neurons, Kir2.1, Kir2.2, and Kir2.3 are localized in the heart, brain, and skeletal and vascular muscles [17,18].

The pathogenic mutations causing ATS are located over the entire Kir2.1 channel structure and most of them are missense variations [10]. Based on their functional implication, the pathogenic mutations have been grouped into four different categories: trafficking deficient mutations; mutations related to phosphatidylinositol 4,5-bisphosphate (PIP₂)-binding defects, the main channel modulator; mutations with reported changes in channel conformation; and mutations with defects in two or more such mechanisms [10].

Advances in NGS technologies in recent years have allowed the diagnosis of a larger number of patients with ATS, highlighting the high phenotypic variability and incomplete penetrance of this channelopathy.

We reported a three-generation family with six living individuals affected by ATS and a broad spectrum of phenotypic presentations, in which genetic investigation using whole exome sequencing (WES) identified the previously reported heterozygous loss-of-function (LoF) variant in *KCNJ2* (NM_000891.2: c.652C>T, p. Arg218Trp).

We also carried out a review of all cases with the same mutation published in the literature, looking for similarities and divergences in the phenotype compared to members of our family case.

2. Detailed Family Case Description

2.1. Clinical Evaluation of Patients

A three-generation family with six living individuals affected by ATS and a broad spectrum of phenotypic presentations is described (Figure 1).

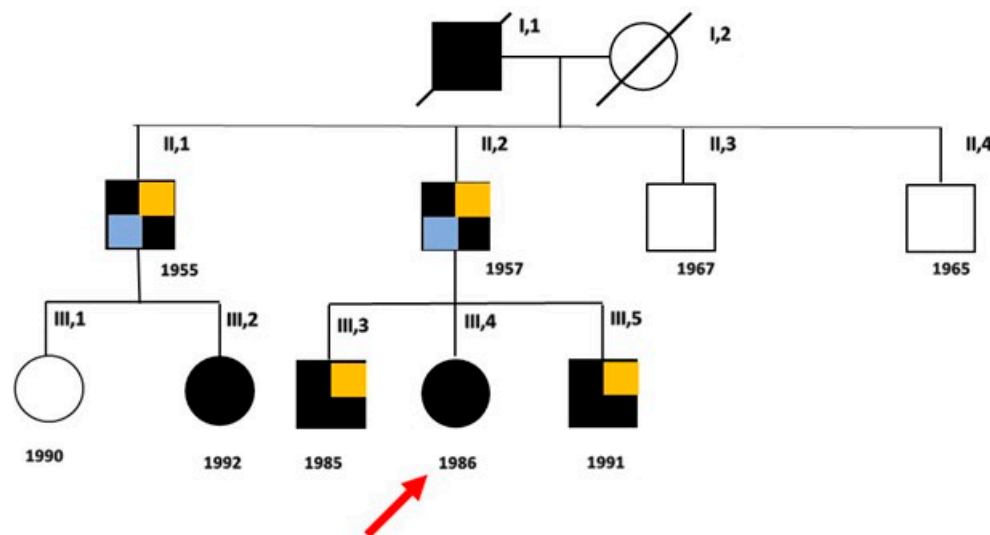


Figure 1. Family pedigree. Black boxes indicate the affected members and white boxes indicate unaffected individuals, after genetic test. The proband (III, 4) is indicated by the arrow. Light blue boxes indicate patients with metabolic syndrome and ischemic heart disease; orange boxes indicate patients with obesity.

The proband (III, 4) is a 37-year-old woman who presented episodes of muscle weakness and cramps, more common in the pre-menstrual period, since the age of 16. Creatine kinase (CK) levels were within the normal limits (160 U/L versus 190 U/L), while potassium levels were at lower reference limits (4.2 mEq/L). Treatment with potassium, magnesium, and carbonic anhydrase inhibitors alleviated the episodes of cramps and muscle weakness, suggesting a diagnosis of familial hypokalemic periodic paralysis.

Some years later, facial and hand dysmorphisms such as elusive chin (a mild degree of micrognathia), and then overt micro- and retro-gnathia, dental crowding, hypotelorism, high forehead, low set of ears, small hands and feet, previously overlooked, became more evident. These signs were looked for in the other members of the family and were found differently expressed in each of them, the greatest number being present in the third generation. Mild learning difficulties were observed in the proband, her father, and her younger brother. During the long follow-up (FU) (21 years), the patient independently decided to interrupt the therapy and to take only large doses of magnesium, reporting a worsening of symptoms, especially in the upper limbs with greater stiffness and weakness persisting for several days. Symptoms were exacerbated during the two pregnancies and after childbirth, partially alleviated with the re-intake of generous doses of magnesium pidolate, up to 500 mEq of Mg⁺⁺. Serum potassium concentration was within the reference limits at each follow-up, but it was never possible to obtain its value during the episodes of paralysis, though she was recommended to measure it. She complained of states of anxiety and episodes of heart palpitations. Dynamic 24 h ECG, performed on several occasions during the last five years, showed the presence of ventricular and supra-ventricular ectopic beats, and couplets (Figure 2) without episodes of ventricular tachycardia.

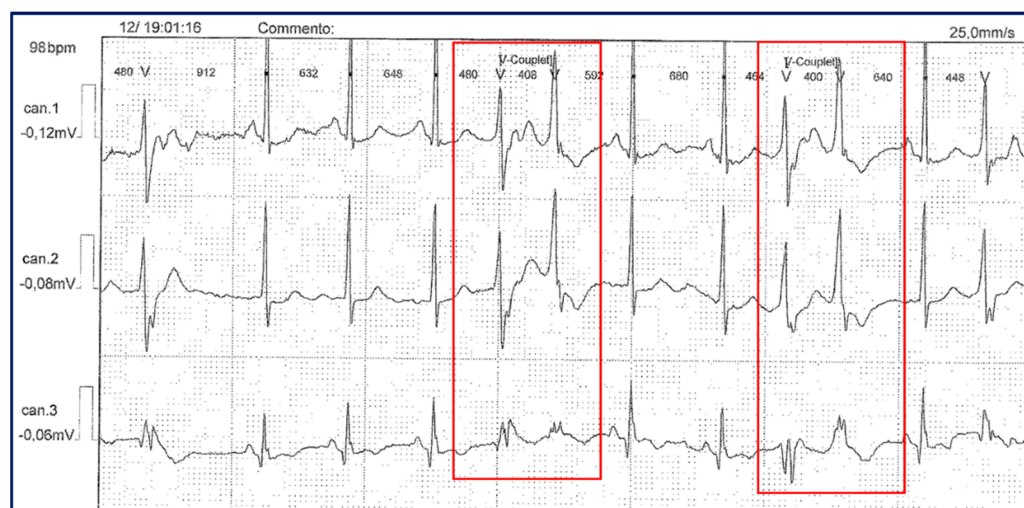


Figure 2. Dynamic 24 h ECG (Holter monitoring) in the proband, showing the presence of couplets of ectopic ventricular beats (red boxes).

Her father (II, 2), despite the presence of hypertrophic muscle masses resembling Thomsen disease, complained of cramps, contractures with myotonia, and myalgia post-exercise at femoral quadriceps (Figure 3) and calve muscles, since the age of 6. At the first consultation, he reported that his father had the same physical structure and suffered, in turn, from cramps and episodes of paralysis, and that he himself in his youth had been diagnosed with limb-girdle muscular dystrophy in a neurology department.

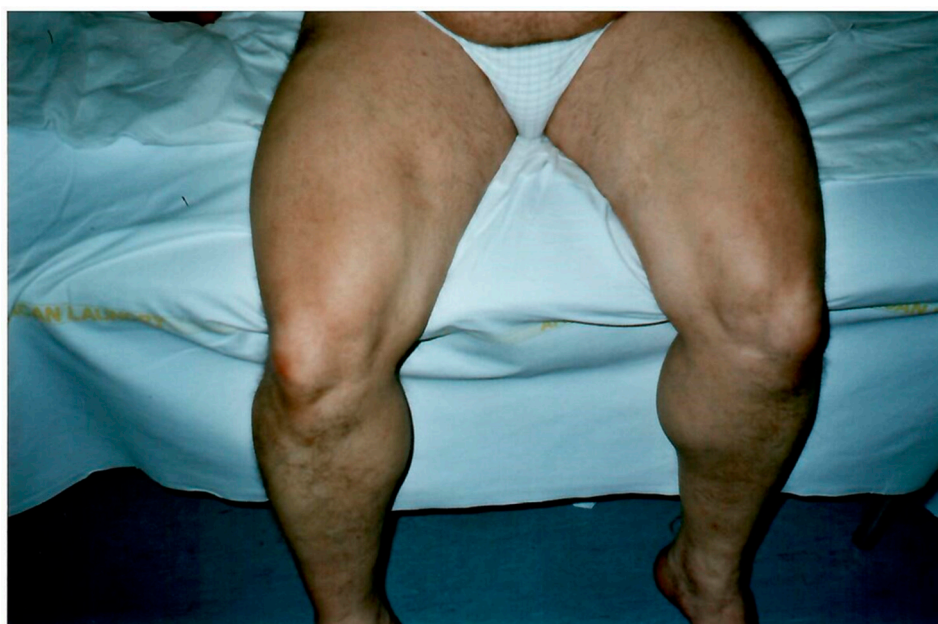

Figure 3. Hypertrophic appearance of lower limb muscles in patient II, 2.

At clinical examination, he reported stable dysphonia, difficulties in walking and climbing stairs, and episodes of stiffness and adynamia more frequent than in the past, when they were limited to twice a year. CK levels were slightly increased (223 U/L versus 190 U/L), while serum potassium levels were at the upper reference limits. Over the years, he developed a metabolic syndrome characterized by obesity, hypertension, dyslipidemia, and type 2 diabetes. During the follow-up, he had two episodes of acute myocardial infarction (AMI), and due to the presence of ectopic ventricular arrhythmia with thousands of couplets and many dozens of runs, was implanted with an intracardiac

cardioverter defibrillator (ICD) at the age of 52. To date, he presents post-ischemic dilated cardiomyopathy (ejection fraction, EF 30%) and chronic heart failure, complicated by nocturnal episodes of obstructive sleep apnea (OSA).

The proband's brothers (III, 3; III, 5) also have hypertrophic muscle masses and reported episodes of stiffness (twice a month), cramps, myalgias, and inconstant paresthesia in the fingertips of both hands. Patient (III, 5) sometimes complained of difficulty in muscle relaxation after prolonged contraction (myotonia). Both had increased CK levels (1157 U/L and CK 235 U/L, respectively), while serum potassium concentration ranged from normal to upper reference limits. Dysmorphic features including mandibular hypoplasia, dental crowding, clinodactyly of fifth toe, and syndactyly of II/III fingers of hands were present in both brothers, while scoliosis, hypertelorism, small ears, and short neck were present only in the youngest. Treatment with acetazolamide relieved symptoms.

The older paternal uncle (II, 1) also presented periodic paralysis, myalgias at the posterior compartment of the thighs and calves, memory and attention disturbances, and metabolic syndrome including hypertension, diabetes, and obesity. At the age of 60, he underwent two coronary artery bypass grafts due to ischemic heart disease.

His younger daughter (III, 2) came to our observation at the age of 27, complaining for about three years of symptoms characterized by nocturnal muscle cramps and muscle weakness upon awakening, and the presence of myotonia in the hands which appeared at the age of 6–7 years, and attenuated over times. CK values were within the normal limits, while the potassium concentration was below the normal lower limit (3.9 mEq/L).

However, none of the patients except the proband's father showed prolonged QT interval or severe arrhythmias during the long follow-up. None presented a prominent U wave.

2.2. Genetic Analysis

A first genetic investigation, carried out by a targeted panel including the two main genes associated with congenital myotonias, *CLCN1* and *SCN4A* genes, was negative. However, by extending the molecular investigation to further genes associated with the described phenotype, the heterozygous missense variant NM_000891.2: c.652C>T, p. Arg218Trp in exon 2 of the *KCNJ2* gene (Figure 4) was identified.

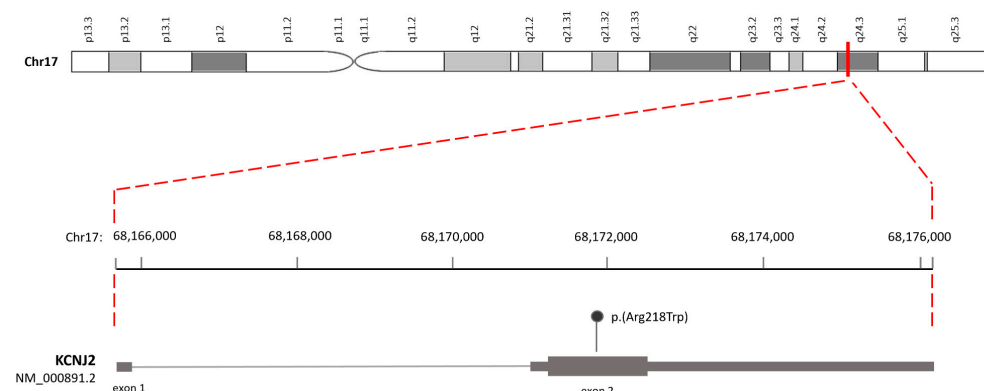


Figure 4. Schematic representation of the human *KCNJ2* genomic structure and position of the variant (NM_000891.2: c.652C>T, p. Arg218Trp) on exon 2.

This variant, previously identified in the proband in an external laboratory, was validated using Sanger sequencing in our laboratory as indicated below.

In brief, after PCR amplification of the exon 2 (*KCNJ2_ex2_Arg218Trp_Forward*: 5'-TGCTTTCATCATTGGCGCAG-3'; *KCNJ2_ex2_Arg218Trp_Reverse*: 5'-TCCACCAATGCCTTCCAGTATG-3'). Sanger sequencing was performed using the BigDye™ Terminator v1.1 Cycle Sequencing kit (Applied Biosystems™, Foster City, CA, USA) and analyzed on a 3500 xl Genetic Analyzer (Applied Biosystems for Sanger). Automatic identification of variations was achieved by analyzing sequencing data (ABI file) using Mutation Surveyor version 3.24 software (SoftGenetics, State College, PA, USA).

The variant, already reported in the public database ClinVar (VCV000008919.23), is predicted to be pathogenic (PP5 very strong, PM5 strong, PP3 strong, PM1 moderate, PM2 supporting), both using the default settings of Varsome (January 2024), and according to the ACMG/AMP guidelines. The analysis of segregation carried out in our laboratory, confirmed the heterozygosity in the proband, her brothers, and her father (Figure 5), and in the paternal uncle (II, 1) and the younger of his daughters (III, 2), while excluded it in the other two uncles (II, 3 and II, 4) and in the cousin (III, 1).

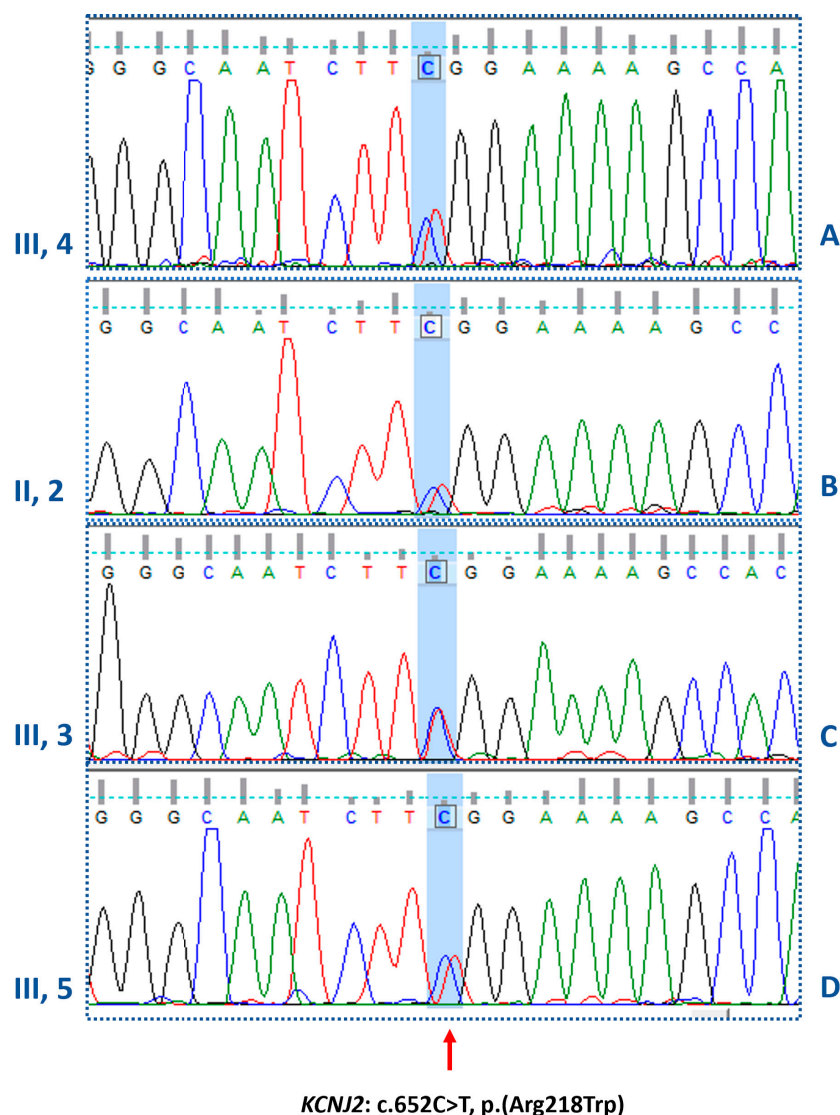


Figure 5. Electropherograms of the *KCNJ2* gene. In panels A, B, C, and D, the electropherograms confirm the heterozygous missense mutation (c.652C>T) identified in the proband, her father and the two brothers, respectively.

3. Discussion

To date, nine families (not counting the one reported here) with 31 affected individuals, and 20 isolated cases carrying the heterozygous variant c.652C>T, p.Arg218Trp in *KCNJ2* gene have been described in the literature (Table 1a,b) [13,19–36].

Table 1. Patients with the heterozygous variant c.652C>T, p. Arg218Trp in *KCNJ2* gene so far reported in the literature.

(a)												
ATS Familial Cases												
Authors [Reference]	Relationship	Age at Onset/Sex	Clinical Presentation		Laboratory Investigations		Cardiological Features		Dysmorphisms/Other Features			
			First Symptoms	Muscle Involvement	K ⁺ Levels in mEq/L (n.v. 4.2–5.6)	CK Levels in U/L (n.v. < 90)	ECG and Echo Features at 1st Visit and During FU	QTc in msec	Facial and Other Dysmorphisms	Additional Features	Age at Last FU	
Davies et al. [13]	Proband	9/F	VA	PP	n.r.	120	VA	n.r.	Abnormal dentition, dental enamel discoloration		Mild Ataxia	n.r.
	Brother	16/M	PP	PP	Low	n.r.	--	n.r.	--	--	--	n.r.
	Brother	14/F	PP	PP	Low	154	VA	n.r.	--	--	--	n.r.
	Mother	8/F	VA	PP	n.r.	n.r.	VA	n.r.	--	--	--	n.r.
Davies et al. [13]	Proband	24/M	Painful PP	PP	n.r.	n.r.	--	n.r.	--	--	--	n.r.
	Son	14/M	PP	PP	n.r.	n.r.	--	n.r.	--	--	--	n.r.
	Son	13/M	PP	PP	low	184	--	n.r.	--	--	--	n.r.
Donaldson et al. [19]	Proband	10/F	Weakness of the lower limbs; paralysis	PP; muscle weakness of lower limbs	2.0	n.r.	bVT; PVC; prominent U wave; LQTS; EVB	445	Micrognathia, scoliosis, clinodactyly, small ears, hypertelorism, short and wide neck, fingers syndactyly		---	29
Pouget et al. [20]	Father	38/M	Muscle pain; EVB		n.r.	n.r.	EVB	n.r.	---	---	---	53
Schoonderwoerd et al. [21]	Proband	18/F	Cardiac arrest	Exercise intolerance	2.6	n.r.	Prominent U wave; VF; DCM frequent PVCs; VT	n.r.	Mild facial asymmetry, clinodactyly, syndactyly of second and third toes		--	n.r.
	Mother	34/F	Unexpected syncopal event	--	n.r.	n.r.	Frequent PVCs; VT; DCM	n.r.	Asymmetric face, prognathia, camptodactyly of toes, syndactyly of the second and third toes		--	n.r.
	Brother	16/M	Muscle weakness	Muscle weakness of limbs	n.r.	n.r.	Prominent U wave; PVC; pVT	n.r.	Low set ears, prominent forehead, bifid uvula, webbed neck, small mandible, clinodactyly, syndactyly of the second and third toes		--	n.r.

Table 1. Cont.

Tengan et al. [22]	Proband	13/M	Muscle weakness	PP, weakness of proximal limb muscles	Normal	n.r.	Prolonged QT; isolated EVB	490	Short stature, micrognathia, retrognathia, clinodactyly of fourth and fifth fingers, arched palate, thoracic scoliosis	Obesity; OSA, daytime sleepiness	n.r.
	Daughter	6/F	Muscle weakness	Episodes of weakness	Normal	n.r.	--	n.r.	Short stature, micrognathia, clinodactyly of fourth and fifth fingers	OSA	n.r.
Bokenkamp et al. [23]	Proband	3/F	Arrhythmia	--	--	n.r.	Polymorphic EVB, prolonged QT, prominent U wave, mild aortic root dilation	480	Mild dysmorphic features, including broad forehead, hypertelorism, small mandible and clinodactyly	--	6
	Father	/M	Polymorphic EVB	--	--	n.r.	Polymorphic EVB	--	Mild dysmorphic features	--	
	Brother	6/M	Polymorphic EVB; syncope	1 episode of muscle weakness	--	n.r.	Polymorphic EVB	--	Mild dysmorphic features	--	7
Haruna et al. [24]	Proband	6/F	Syncopal events	PP	n.r.	n.r.	PVC, bVT, monomorphic VT	483	--	--	n.r.
	Father	38/M	Muscle weakness	PP	n.r.	n.r.	PVC	384	--	--	n.r.
	Grandfather	/M	Muscle weakness	PP	n.r.	n.r.	--	410	--	--	n.r.
Haruna et al. [24]	Proband	11/F	Muscle weakness	--	n.r.	n.r.	bVT, mVT	365	Dysmorphic features	--	n.r.
	Father	47/M	Muscle weakness	--	n.r.	n.r.	--	394	--	--	n.r.
	Brother	5/M	Myalgia	--	n.r.	n.r.	--	342	--	--	n.r.
Janson et al. [25]	Proband	10/M	VEB, bVT	PP, episodes of muscle weakness	n.r.	n.r.	EVB, bVT	--	Micrognathia, wide-spaced eyes, clinodactyly of the fifth digit	--	15
	Mother	F	PP, VT	PP	n.r.	n.r.	VT, CM	--	Micrognathia, wide-spaced eyes, clinodactyly of the fifth digit	--	n.r.

Table 1. Cont.

Ardissone et al. [26]	Proband	14/M	Acute muscle pain	Muscle pain, cramps, generalized weakness	3.5	346	Sinus Tachycardia	Normal	Broad forehead, hypoplastic mandible, low-set ears, short stature, low weight	--	4
	Mother	20/F	Muscle pain post-exercise, muscle weakness	Severe generalized muscle weakness	--	n.r.	--	--	Broad forehead, hypoplastic mandible, low-set ears, short stature, low weight	--	n.r.
	Brother	M	VT, long QT	--	--	n.r.	VT, long QT, arrhythmias	--	Broad forehead, hypoplastic jaw, low-set ears	--	n.r.
	Brother	M	VT, long QT	Muscle stiffness	--	n.r.	VT, long QT, arrhythmias	--	Broad forehead, hypoplastic jaw, low-set ears	--	n.r.
Barron-Diaz et al. [27]	Proband	25/F	VT	Limb weakness	n.r.	n.r.	PVC, VT	441	Short stature, broad forehead, jaw hypoplasia, dental alterations, camptodactyly, clinodactyly, feet syndactyly, dental alterations	--	n.r.
	Sister	7/F	VT, weakness, syncopal episodes	Limb weakness	n.r.	n.r.	PVC, VT, arrhythmias, mitral regurgitation	544	Triangular face, scoliosis, broad forehead, ptosis palpebral, mandibular hypoplasia, dental alterations, camptodactyly in hands, clinodactyly, feet syndactyly	--	n.r.
Our Family Case	Uncle	34/M	Cramps, myalgias, muscle weakness	General muscle hypertrophy	4.2	297	Coronary artery by-pass graftings; IHD; sVT; sEVB; EVB	360	---	Metabolic syndrome	66
	Father	6/M	Cramps, myalgias post-exercise	Lower limbs	5.4	827	AMI; eccentric hypertrophy of LV; ICD implant sVT; nsVT	450	Dental crowding	Metabolic syndrome; OSA	68
	Cousin	24/F	Cramps; muscle weakness; myotonia	Lower limbs	3.9	171	Normal	370	Small ears		5

Table 1. Cont.

Our Family Case	Older brother	12/M	Cramps; muscle stiffness at lower limbs	Lower limbs	4.7	150	Sinus arrhythmia; decreased amplitude of T waves in LPL	380	Jaw hypoplasia; dental crowding; clinodactyly fifth toe; syndactyly of II/III fingers of hands	Obesity	39
	Proband	16/F	Premenstrual episodes of PP, muscle stiffness	Upper and lower limbs	4.4	97	Sinus Bradycardia; EVB during FU	370	Micrognathia, elusive chin, low set of ears, dental crowding, hypotelorism, mall hands/ feet	—	37
	Young brother	11/M	Muscle stiffness	Upper limbs	4.9	426	Sinus Bradycardia; transient WPM	370	Scoliosis, micrognathia, small ears, hypertelorism, short neck, fingers clinodactyly and syndactyly	Obesity	32
(b)											
ATS Sporadic Cases											
Haruna et al. [24]	Proband	6/M	Muscle weakness	PP	n.r.	n.r.	PVC	339	Dysmorphic features	--	n.r.
Takahashi et al. [28]	Proband	5/F	Syncopal events, muscle weakness	Muscle weakness	Normal	n.r.	Long QT, prominent U wave, PVC, intractable VA	490	--	--	18
Subbiah et al. [29]	Proband	17/F	Muscle weakness, bVT	PP, episodes of weakness	n.r.	n.r.	Symptomatic EVB, bVT, prominent U wave	460	--	--	n.r.
Rajakulendran et al. [30]	Proband	9/F	Attacks of muscle weakness	Muscle weakness	Normal	n.r.	--	365	Short stature, micromelia, low set ears, clinodactyly of hands, syndactyly of toes	--	n.r.
Kimura et al. [31]	Proband	6/F	Syncopal events	PP	n.r.	n.r.	PVC	508	--	--	n.r.
	Proband	11/F	--	--	n.r.	n.r.	pVT	n.r.	Dysmorphic features	--	n.r.
	Proband	6/M	--	PP	n.r.	n.r.	bVT	468	Dysmorphic features	--	n.r.
	Proband	19/F	Syncopal events	--	n.r.	n.r.	bVT	400	Dysmorphic features	--	n.r.
	Proband	12/M	--	--	n.r.	n.r.	bVT, pVT, PVC	427	Dysmorphic features	--	n.r.
	Proband	6/F	--	--	n.r.	n.r.	pVT, PVC	392	--	--	n.r.
	Proband	5/M	--	--	n.r.	n.r.	pVT, PVC	Normal	--	--	n.r.

Table 1. Cont.

Lefter et al. [32]	Proband	10/M	Lower limb weakness	PP, myalgia, weakness, fixed proximal myopathy	Normal	850	Prominent U wave	n.r.	Short stature, micromelia, micrognathia, low set ears, fifth digit clinodactyly, syndactyly of the left foot digits 2–3	--	19
Jung et al. [33]	Proband	6/M	pVT	Paralysis of lower limbs	2.5	n.r.	pVT	n.r.	Micrognathia, clinodactyly	--	25
Luo et al. [34]	Proband	11/M	PP	PP	Normal	n.r.	--	n.r.	--	--	n.r.
Horigome et al. [35]	Proband	6/M	PP	PP	n.r.	n.r.	bVT	n.r.	Short stature, dysmorphic features	--	n.r.
	Proband	19/M	PP	PP	n.r.	n.r.	PVC	n.r.	Dysmorphic features	--	n.r.
	Proband	24/F	PP	PP	n.r.	n.r.	PVC	n.r.	Short stature, dysmorphic features	--	n.r.
	Proband	28/F	PP	PP	n.r.	n.r.	bVT	n.r.	Short stature, dysmorphic features	--	n.r.
	Proband	54/F	PP	PP	n.r.	n.r.	PVC	n.r.	Dysmorphic features	--	n.r.
Yang et al. [36]	Proband	7/M	Syncopal events	Lower limb myotonia	3.9	n.r.	PVC, bVT, prominent U wave	420	Short stature, mandibular hypoplasia, single palmar crease, long bone, over hyper-extension	--	n.r.

Legenda. "--": absence of signs indicated in the column. AMI: acute myocardial infarction; bVT: bidirectional ventricular tachycardia; CK: creatine kinase; CM: cardiomyopathy; DCM: dilated cardiomyopathy; EVB: ectopic ventricular beats; ICD: implantable cardioverter defibrillator; IHD: ischemic heart disease; LPL: left precordial leads; LQTS: long QT syndrome; LV: left ventricle; nsVT: not sustained ventricular tachycardia; OSA: obstructive sleep apnea; PP: periodic paralysis; pVT: polymorphic ventricular tachycardia; QTc: corrected QT interval in milliseconds; sVT: supra ventricular tachycardia; VA: ventricular arrhythmia; VF: ventricular fibrillation; VT: ventricular tachycardia; WPM: wandering pacemaker; n.r.: not reported. Metabolic syndrome includes hypertension, obesity, type 2 diabetes, and dyslipidemia; FU: follow-up. In bold, our family case; in red are abnormal values.

All subjects have at least one feature of the triad commonly associated with ATS. Muscle phenotype, including muscle weakness, muscle pain, cramps, and episodes of periodic paralysis, is reported in 30/46 (65.2%) individuals. Potassium concentration is available for only five patients (9.8%), three boys and two girls, who present values ranging from 2 to 3.9 mEq/L. CK values are available for five patients (9.8%), three boys and two girls, and range from normal values to about five times the upper reference limit.

Cardiac manifestations including ventricular tachycardia (VT), premature ventricular contractions (PVC), prolonged QT interval, bidirectional or polymorphic ventricular tachycardia (bVT or pVT), syncopal episodes or cardiac arrest are reported in 25/46 (54.3%) subjects. QTc values are available for 11/31 (35.4%) male and 10/25 (40%) female patients. Prolonged QTc above the normal upper limit (440 msec in males and 460 msec in females) is present in 27.2% of male and 30% of female patients. Dilated cardiomyopathy or a high risk of cardiac sudden death are described by Schoonderwoerd [21] and Barron-Diaz [27], respectively.

Dysmorphic features are present in 32/51 (62.7%) cases. In particular, short stature or scoliosis are the most represented skeletal anomalies (21.5% and 7.8%, respectively), followed by clinodactyly (23.5%) and syndactyly (15.7%). Abnormal dentition and dental enamel discoloration are reported in three patients (5.9%) [13,27].

Some aspects found in members of our family case such as the prevalence of the disease in males (4/6, 66.7%), the great intra-familial variability concerning the age of onset and clinical presentation, the muscle phenotype as the prevalent presenting symptom, and the variable presence of dysmorphic features agree with the data present in the literature.

Age of onset varies from 6 to 34 years and muscle symptoms including cramps, post-exercise myalgia, and episodes of muscle weakness up to paralysis are the predominant features. Dysmorphic features such as elusive chin, overt micrognathia, dental crowding, hypertelorism, low set of ears, small hands and feet, clinodactyly and syndactyly of the fingers are variably present only in the third generation.

By contrast, other aspects such as normal or above normal height, serum potassium concentration within the reference limits, concomitance of paralysis attacks with the premenstrual period in women, high occurrence of metabolic syndrome and ischemic heart disease in male patients, presence of myotonia in some members of the family (father and younger brother, cousin) are atypical features of ATS.

Serum potassium concentration, recorded during the follow-up period, outside the episodes of paralysis, varies from 3.9 to 5.4 mEq/L (Table 1a,b). However, a possible correlation with potassium imbalance was supposedly based on the beneficial effect of acetazolamide on episodes of paralysis.

Adynamia associated with the pre-menstrual period was already reported by Sarova-Pinhas et al. in 1981. They described a 17-year-old girl who suffered from episodes of flaccid paralysis during each menstrual cycle [37]. Symptoms were responsive to treatment with acetazolamide, which is a drug that acts at the nephron's proximal convoluted tubule level by inhibiting carbonic anhydrase, an enzyme involved in maintaining the body's acid-base balance. Through the inhibition of carbonic anhydrase activity, acetazolamide reduces the reabsorption of bicarbonate and sodium, increasing their urinary excretion, and influencing the movement of potassium from extracellular to intracellular compartments [38]. A positive response to treatment with acetazolamide or antiarrhythmic drugs blocking sodium channels, such as flecainide and mexiletine, is also reported by other authors [23,35,39–42].

Cardiac evaluation, periodically performed during the long years of follow-up—21 for the proband and her family and 15 for the uncle—showed the presence of sinus bradycardia in younger patients and the onset of ectopic ventricular beats often in pairs in the proband. Cardiovascular disease evolving to post-ischemic dilated cardiomyopathy and chronic heart failure, associated with the onset of ventricular arrhythmias requiring ICD implantation prevailed in older patients over the muscle condition. The co-existing metabolic syndrome with hypertension, obesity, type 2 diabetes, and dyslipidemia likely contributed to the rapid evolution of heart disease.

Episodic flaccid muscle weakness (periodic paralysis), cardiac abnormalities (ventricular arrhythmias, prolonged QT interval, prominent U wave), and dysmorphic features (broad forehead, hypoplastic mandible, hypertelorism, low-set ears, widely spaced eyes, fifth digit clinodactyly, syndactyly, short stature, and scoliosis) are regarded as the triad of features typically associated with Andersen–Tawil syndrome. High phenotypic variability and incomplete penetrance of the gene causing the disease define this condition. Muscle weakness is the most immediate manifestation of the disease related to an elevated (>5.6 mEq/L), normal, or most commonly reduced (<3.5 mmol/U) serum potassium concentration. Pathogenic mutations in the *KCNJ2* gene, encoding for the inwardly rectifying potassium channel subunits Kir2.1, have been associated with ATS [43].

Here we reported a three-generation family with six living members affected by ATS, in which the genetic investigation identified the previously reported heterozygous loss-of-function (LoF) variant c.652C>T, p. Arg218Trp in the *KCNJ2* gene. The variant falls in the carboxyl (COOH) domain of the channel [9]. The residue Arg218, highly conserved, is involved in the binding of phosphatidylinositol 4,5-bisphosphate (PIP2), the main modulator of Kir2.1 channels [19]. Kir2.1 has three C-terminal PIP2 binding regions (aa 175–206, aa 207–246, aa 324–365) [43] and the substitution of residue 218 has been associated with decreased PIP2 binding and inhibition of channel function [44]. Affected patients present the clinical features characteristic of ATS including ventricular arrhythmias, dysmorphic features, and episodes of muscle weakness [22,32]. Systolic dysfunction has also been reported in these patients in the setting of dilated cardiomyopathy [21]. However, these features are not always present at the same time and can occur during the course of the disease.

The high inter- and intra-familial phenotypic variability observed in individuals with ATS [24,26,31] and this report suggests that many cases may still be undiagnosed due to the scarcity or absence of typical symptoms. The case of a man with a 60-year history of episodic weakness in the proximal limb muscles, diagnosed as ATS only at age 66, is illustrative [45]. Affected individuals can sometimes present a picture of fixed myopathy that can lead to a wrong diagnosis of muscular dystrophy [32].

Complicating the diagnosis is the fact that episodes of muscle weakness and periodic paralysis are not peculiar to channelopathies, but they can also be found in different conditions such as mitochondrial cytopathies, which should be taken into account in the differential diagnosis.

Mitochondrial cytopathies represent a heterogeneous group of multisystem disorders, which preferentially affect muscle and nervous systems. They can be caused either by mutations in the maternally inherited mitochondrial genome or by nuclear DNA mutations [46,47]. Mitochondrial cytopathies are generally not considered in the diagnostic workup of patients with electrolyte disorders, which are commonly reported in mitochondrial cytopathies, often as presenting symptoms. Viering et al. [48], by studying 362 patients affected by mitochondrial diseases, found that about 80% of them had an electrolyte disorder, which was the presenting or main symptom in 13% of patients. They emphasized that mitochondrial diseases should be considered in the evaluation of unexplained electrolyte disorders.

Owing to the non-uniform distribution of mitochondria in tissues and the co-existence of mutated and wild-type mtDNA (heteroplasmy) in these organelles, these disorders may present with a huge variety of symptoms, including muscle weakness and cardiomyopathy [46,47]. The progressive increase in mtDNA heteroplasmy causes progressive mitochondrial dysfunction leading to a loss in their bioenergetic capacity, disruption in the balance of mitochondrial fusion and fission events, and decreased mitophagy. This failure in mitochondrial physiology leads to the accumulation of depolarized and ROS-generating mitochondria. Thus, besides attenuated ATP production, dysfunctional mitochondria interfere with proper cellular metabolism and signaling pathways in cardiac cells, contributing to the development of ischemic heart disease, cardiomyopathy, and atherosclerotic vascular disease [49]. Mitochondria are known to regulate apoptotic and autophagic pathways that

have been shown to play an important role in the development of cardiomyopathy and atherosclerosis [50].

In our family case, the classic mitochondrial pattern of inheritance is not conceivable, since the proband's paternal grandfather is the first to present symptoms, with a male-to-male transmission. However, the co-occurrence of a second mutation in nuclear mtDNA genes cannot be ruled out.

4. Conclusions

The clinical features typically associated with Andersen–Tawil syndrome, such as episodes of muscle weakness, cardiac arrhythmias, and dysmorphic features would require a multidisciplinary approach.

In our opinion, closer collaboration between neuro-myologists, cardiologists, orthopedists, and geneticists in the case of patients with signs and symptoms of muscular, cardiac, or skeletal involvement described above, which, if not present at the same time, must be carefully looked for, would facilitate the clinical and genetic diagnosis of ATS.

Author Contributions: Conceptualization, L.P.; Methodology, L.P.; Validation, V.N.; Investigation, P.D., L.P., S.M., M.E.O. and E.P.; Writing—Original Draft Preparation, M.E.O. and L.P.; Writing—Review and Editing: L.P.; Supervision, L.P. All authors have read and agreed to the published version of the manuscript.

Funding: This research received no external funding.

Institutional Review Board Statement: The study was conducted according to the guidelines of the Declaration of Helsinki and approved by the Ethics Committee of the University of Campania “Luigi Vanvitelli” (# 0017030/i-13/07/2020).

Informed Consent Statement: Written informed consent for genetic investigation and data collection for research purposes was obtained from the proband and other family members, at the time of blood collection, as a consolidated hospital practice.

Data Availability Statement: Due to privacy, data is available upon request, subject to evaluation by the corresponding author.

Acknowledgments: The authors are grateful to the family members for their participation and cooperation.

Conflicts of Interest: The authors declare no conflicts of interest.

References

1. Matthews, E.; Holmes, S.; Fialho, D. Skeletal muscle channelopathies: A guide to diagnosis and management. *Pract. Neurol.* **2021**, *21*, 196–204. [[CrossRef](#)] [[PubMed](#)]
2. Morales, F.; Pusch, M. An Up-to-Date Overview of the Complexity of Genotype-Phenotype Relationships in Myotonic Channelopathies. *Front. Neurol.* **2020**, *10*, 1404. [[CrossRef](#)] [[PubMed](#)]
3. Dunø, M.; Vissing, J. Myotonia Congenita. In *GeneReviews*®[Internet]; Adam, M.P., Feldman, J., Mirzaa, G.M., Pagon, R.A., Wallace, S.E., Bean, L.J.H., Gripp, K.W., Amemiya, A., Eds.; 3 August 2005 [updated 25 February 2021]; University of Washington: Seattle, WA, USA, 1993–2024.
4. Cannon, S.C. Sodium Channelopathies of Skeletal Muscle. *Handb. Exp. Pharmacol.* **2018**, *246*, 309–330. [[CrossRef](#)] [[PubMed](#)]
5. Weber, F.; Lehmann-Horn, F. Hypokalemic Periodic Paralysis. In *GeneReviews*®[Internet]; Adam, M.P., Feldman, J., Mirzaa, G.M., Pagon, R.A., Wallace, S.E., Bean, L.J.H., Gripp, K.W., Amemiya, A., Eds.; 30 April 2002 [updated 26 July 2018]; University of Washington: Seattle, WA, USA, 1993–2024.
6. Weber, F. Hyperkalemic Periodic Paralysis. In *GeneReviews*®[Internet]; Adam, M.P., Feldman, J., Mirzaa, G.M., Pagon, R.A., Wallace, S.E., Bean, L.J.H., Gripp, K.W., Amemiya, A., Eds.; 18 July 2003 [updated 1 July 2021]; University of Washington: Seattle, WA, USA, 1993–2024.
7. Andersen, E.D.; Krasilnikoff, P.A.; Overvad, H. Intermittent muscular weakness, extra-systoles, and multiple developmental anomalies. A new syndrome? *Acta Paediatr. Scand.* **1971**, *60*, 559–564. [[CrossRef](#)] [[PubMed](#)]
8. Tawil, R.; Ptacek, L.J.; Pavlakis, S.G.; DeVivo, D.C.; Penn, A.S.; Ozdemir, C.; Griggs, R.C. Andersen's syndrome: Potassium-sensitive pe-riodic paralysis, ventricular ectopy, and dysmorphic features. *Ann. Neurol.* **1994**, *35*, 326–330. [[CrossRef](#)] [[PubMed](#)]
9. Plaster, N.M.; Tawil, R.; Tristani-Firouzi, M.; Canún, S.; Bendahhou, S.; Tsunoda, A.; Donaldson, M.R.; Iannaccone, S.T.; Brunt, E.; Barohn, R.; et al. Mutations in Kir2.1 cause the developmental and episodic electrical phenotypes of Andersen's syndrome. *Cell* **2001**, *105*, 511–519. [[CrossRef](#)] [[PubMed](#)]

10. Moreno-Manuel, A.I.; Gutiérrez, L.K.; Vera-Pedrosa, M.L.; Cruz, F.M.; Bermúdez-Jiménez, F.J.; Martínez-Carrascoso, I.; Sánchez-Pérez, P.; Macías, Á.; Jalife, J. Molecular stratification of arrhythmogenic mechanisms in the Andersen Tawil syndrome. *Cardiovasc. Res.* **2023**, *119*, 919–932. [[CrossRef](#)] [[PubMed](#)]
11. Tristani-Firouzi, M.; Jensen, J.L.; Donaldson, M.R.; Sansone, V.; Meola, G.; Hahn, A.; Bendahhou, S.; Kwicinski, H.; Fidzianska, A.; Plas-ter, N.; et al. Functional and clinical characterization of KCNJ2 mutations associated with LQT7 (Andersen syndrome). *J. Clin. Investig.* **2002**, *110*, 381–388. [[CrossRef](#)] [[PubMed](#)]
12. Nguyen, H.L.; Pieper, G.H.; Wilders, R. Andersen-Tawil syndrome: Clinical and molecular aspects. *Int. J. Cardiol.* **2013**, *170*, 1–16. [[CrossRef](#)] [[PubMed](#)]
13. Davies, N.P.; Imbrici, P.; Fialho, D.; Herd, C.; Bilsland, L.G.; Weber, A.; Mueller, R.; Hilton-Jones, D.; Ealing, J.; Boothman, B.R.; et al. Andersen-Tawil syndrome: New potassium channel mutations and possible phenotypic variation. *Neurology* **2005**, *65*, 1083–1089. [[CrossRef](#)] [[PubMed](#)]
14. Preisig-Müller, R.; Schlichthörl, G.; Goerge, T.; Heinen, S.; Brüggemann, A.; Rajan, S.; Derst, C.; Veh, R.W.; Daut, J. Heteromerization of Kir2.x potassium channels contributes to the phenotype of Andersen’s syndrome. *Proc. Natl. Acad. Sci. USA* **2002**, *99*, 7774–7779. [[CrossRef](#)] [[PubMed](#)]
15. Reilly, L.; Eckhardt, L.L. Cardiac potassium inward rectifier Kir2: Review of structure, regulation, pharmacology, and arrhythmogenesis. *Heart Rhythm.* **2021**, *18*, 1423–1434. [[CrossRef](#)] [[PubMed](#)]
16. Hager, N.A.; McAtee, C.K.; Lesko, M.A.; O’Donnell, A.F. Inwardly Rectifying Potassium Channel Kir2.1 and its “Kirious” Regulation by Protein Trafficking and Roles in Development and Disease. *Front. Cell Dev. Biol.* **2022**, *9*, 796136. [[CrossRef](#)] [[PubMed](#)]
17. Ryan, D.P.; da Silva, M.R.; Soong, T.W.; Fontaine, B.; Donaldson, M.R.; Kung, A.W.; Jongjaroenprasert, W.; Liang, M.C.; Khoo, D.H.; Cheah, J.S.; et al. Mutations in potassium channel Kir2.6 cause susceptibility to thyro-toxic hypokalemic periodic paralysis. *Cell* **2010**, *140*, 88–98. [[CrossRef](#)] [[PubMed](#)]
18. Dassau, L.; Conti, L.R.; Radeke, C.M.; Ptáček, L.J.; Vandenberg, C.A. Kir2.6 regulates the surface expression of Kir2.x inward rectifier potassium channels. *J. Biol. Chem.* **2011**, *286*, 9526–9541. [[CrossRef](#)] [[PubMed](#)]
19. Donaldson, M.R.; Jensen, J.L.; Tristani-Firouzi, M.; Tawil, R.; Bendahhou, S.; Suarez, W.A.; Cobo, A.M.; Poza, J.J.; Behr, E.; Wagstaff, J.; et al. PIP2 binding residues of Kir2.1 are common targets of mutations causing Andersen syndrome. *Neurology* **2003**, *60*, 1811–1816. [[CrossRef](#)]
20. Pouget, J.; Philip, N.; Faugere, G.; Pellissier, J.F. Le syndrome d’Andersen: Une forme particulière de paralysie périodique avec dysrythmie cardiaque [Andersen syndrome: A particular form of paralysis with cardiac dysrhythmia]. *Rev. Neurol.* **2004**, *160 Pt 2*, S38–S42. [[CrossRef](#)] [[PubMed](#)]
21. Schoonderwoerd, B.A.; Wiesfeld, A.C.; Wilde, A.A.; van den Heuvel, F.; Van Tintelen, J.P.; van den Berg, M.P.; Van Veldhuisen, D.J.; Van Gelder, I.C. A family with Andersen-Tawil syndrome and dilated cardiomyopathy. *Heart Rhythm.* **2006**, *3*, 1346–1350. [[CrossRef](#)] [[PubMed](#)]
22. Tengan, C.H.; Antunes, A.C.; Bauab, J.R.; Prado, G.F.; Manzano, G.M.; Gabbai, A.A. Andersen syndrome: An association of periodic paralysis, cardiac arrhythmia and dysmorphic abnormalities. *Arq. Neuropsiquiatr.* **2006**, *64*, 582–584. [[CrossRef](#)] [[PubMed](#)]
23. Bökenkamp, R.; Wilde, A.A.; Schalij, M.J.; Blom, N.A. Flecainide for recurrent malignant ventricular arrhythmias in two siblings with Andersen-Tawil syndrome. *Heart Rhythm.* **2007**, *4*, 508–511. [[CrossRef](#)] [[PubMed](#)]
24. Haruna, Y.; Kobori, A.; Makiyama, T.; Yoshida, H.; Akao, M.; Doi, T.; Tsuji, K.; Ono, S.; Nishio, Y.; Shimizu, W.; et al. Genotype-phenotype correlations of KCNJ2 mutations in Japanese patients with Andersen-Tawil syndrome. *Hum. Mutat.* **2007**, *28*, 208. [[CrossRef](#)] [[PubMed](#)]
25. Janson, C.M.; Poelzing, S.; Shah, M.J. Combined inhibition of Na⁺ and Ca²⁺ channels: A novel paradigm for the treatment of incessant ventricular arrhythmias in Andersen-Tawil syndrome. *Heart Rhythm.* **2014**, *11*, 318–320. [[CrossRef](#)] [[PubMed](#)]
26. Ardisson, A.; Sansone, V.; Colleoni, L.; Bernasconi, P.; Moroni, I. Intrafamilial phenotypic variability in Andersen-Tawil syndrome: A diagnostic challenge in a potentially treatable condition. *Neuromuscul. Disord.* **2017**, *27*, 294–297. [[CrossRef](#)] [[PubMed](#)]
27. Barrón-Díaz, D.R.; Totomoch-Serra, A.; Escobar-Cedillo, R.E.; García-Gutierrez, A.; Reyes-Quintero, Á.E.; Villegas Davirán, S.E.; Ibar-ra-Miramón, C.B.; Márquez, M.F. Andersen-Tawil Syndrome with High Risk of Sudden Cardiac Death in Four Mexican Patients. Cardiac and Extra-Cardiac Phenotypes. *Rev. Investig. Clin.* **2020**, *73*, 145–153. [[CrossRef](#)]
28. Takahashi, T.; Tandai, S.; Toki, T.; Sato, T.; Eto, S.; Sato, A.; Ueda, T.; Sato, S.; Ichinose, K.; Ito, E.; et al. KCNJ2 mutation in intrac-table ventricular arrhythmia with Andersen’s syndrome. *Pediatr. Int.* **2005**, *47*, 220–223. [[CrossRef](#)] [[PubMed](#)]
29. Subbiah, R.N.; Gula, L.J.; Skanes, A.C.; Krahn, A.D. Andersen-Tawil syndrome: Management challenges during pregnancy, labor, and delivery. *J. Cardiovasc. Electrophysiol.* **2008**, *19*, 987–989. [[CrossRef](#)] [[PubMed](#)]
30. Rajakulendran, S.; Tan, S.V.; Hanna, M.G. Muscle weakness, palpitations and a small chin: The Andersen-Tawil syndrome. *Pract. Neurol.* **2010**, *10*, 227–231. [[CrossRef](#)] [[PubMed](#)]
31. Kimura, H.; Zhou, J.; Kawamura, M.; Itoh, H.; Mizusawa, Y.; Ding, W.G.; Wu, J.; Ohno, S.; Makiyama, T.; Miyamoto, A.; et al. Phenotype variability in patients carrying KCNJ2 mutations. *Circ. Cardiovasc. Genet.* **2012**, *5*, 344–353. [[CrossRef](#)] [[PubMed](#)]
32. Lefter, S.; Hardiman, O.; Costigan, D.; Lynch, B.; McConville, J.; Hand, C.K.; Ryan, A.M. Andersen-Tawil syndrome with early fixed myopathy. *J. Clin. Neuromuscul. Dis.* **2014**, *16*, 79–82. [[CrossRef](#)]

33. Jung, J.H.; Chae, J.H.; Song, J.H.; Ahn, S.H. The Case | An unusual case of recurrent hypokalemic periodic paralysis. *Kidney Int.* **2017**, *91*, 1523–1524. [[CrossRef](#)] [[PubMed](#)]
34. Luo, S.; Xu, M.; Sun, J.; Qiao, K.; Song, J.; Cai, S.; Zhu, W.; Zhou, L.; Xi, J.; Lu, J.; et al. Identification of gene mutations in patients with primary periodic paralysis using targeted next-generation sequencing. *BMC Neurol.* **2019**, *19*, 92. [[CrossRef](#)] [[PubMed](#)]
35. Horigome, H.; Ishikawa, Y.; Kokubun, N.; Yoshinaga, M.; Sumitomo, N.; Lin, L.; Kato, Y.; Tanabe-Kameda, Y.; Ohno, S.; Nagashima, M.; et al. Multivariate analysis of TU wave complex on electrocardiogram in Andersen-Tawil syndrome with KCNJ2 mutations. *Ann. Noninvasive Electrocardiol.* **2020**, *25*, e12721. [[CrossRef](#)] [[PubMed](#)]
36. Yang, J.; Li, K.; Lv, T.; Xie, Y.; Liu, F.; Zhang, P. Case report: Mexiletine suppresses ventricular arrhythmias in Andersen-Tawil syndrome. *Front. Cardiovasc. Med.* **2022**, *9*, 992185. [[CrossRef](#)] [[PubMed](#)]
37. Sarova-Pinhas, I.; Braham, J.; Shalev, A. Premenstrual periodic paralysis. *J. Neurol. Neurosurg. Psychiatry* **1981**, *44*, 1162–1164. [[CrossRef](#)] [[PubMed](#)]
38. Grob, D.; Johns Rj Liljestrand, A. Potassium movement in patients with familial periodic paralysis: Relationship to the defect in muscle function. *Am. J. Med.* **1957**, *23*, 356–375. [[CrossRef](#)] [[PubMed](#)]
39. Resnick, J.S.; Engel, W.K.; Griggs, R.C.; Stam, A.C. Acetazolamide prophylaxis in hypokalemic periodic paralysis. *N. Engl. J. Med.* **1968**, *278*, 582–586. [[CrossRef](#)] [[PubMed](#)]
40. Griggs, R.C.; Engel, W.K.; Resnick, J.S. Acetazolamide treatment of hypokalemic periodic paralysis. Prevention of attacks and improvement of persistent weakness. *Ann. Intern. Med.* **1970**, *73*, 39–48. [[CrossRef](#)] [[PubMed](#)]
41. Lewis, E.D.; Griggs, R.C.; Moxley, R.T., 3rd. Regulation of plasma potassium in hyperkalemic periodic paralysis. *Neurology* **1979**, *29*, 1131–1137. [[CrossRef](#)] [[PubMed](#)]
42. Poskanzer, D.C.; Kerr, D.N. A third type of periodic paralysis, with normokalemia and favourable response to sodium chloride. *Am. J. Med.* **1961**, *31*, 328–342. [[CrossRef](#)] [[PubMed](#)]
43. Soom, M.; Schönherr, R.; Kubo, Y.; Kirsch, C.; Klinger, R.; Heinemann, S.H. Multiple PIP2 binding sites in Kir2.1 inwardly rectifying potassium channels. *FEBS Lett.* **2001**, *490*, 49–53. [[CrossRef](#)] [[PubMed](#)]
44. Lopes, C.M.; Zhang, H.; Rohacs, T.; Jin, T.; Yang, J.; Logothetis, D.E. Alterations in conserved Kir channel-PIP2 interactions underlie channelopathies. *Neuron* **2002**, *34*, 933–944. [[CrossRef](#)] [[PubMed](#)]
45. Zhao, X.; Zu, H.; Yao, K. A case report of Andersen-Tawil syndrome misdiagnosed with myodystrophy. *Front. Neurol.* **2023**, *14*, 1170693. [[CrossRef](#)] [[PubMed](#)]
46. Schmiedel, J.; Jackson, S.; Schäfer, J.; Reichmann, H. Mitochondrial cytopathies. *J. Neurol.* **2003**, *250*, 267–277. [[CrossRef](#)] [[PubMed](#)]
47. El-Hattab, A.W.; Scaglia, F. Mitochondrial cytopathies. *Cell Calcium.* **2016**, *60*, 199–206. [[CrossRef](#)] [[PubMed](#)]
48. Viering, D.H.H.M.; Vermeltoort, L.; Bindels, R.J.M.; Deinum, J.; de Baaij, J.H.F. Electrolyte Disorders in Mitochondrial Cytopathies: A Systematic Review. *J. Am. Soc. Nephrol.* **2023**, *34*, 1875–1888. [[CrossRef](#)] [[PubMed](#)]
49. Dominic, E.A.; Ramezani, A.; Anker, S.D.; Verma, M.; Mehta, N.; Rao, M. Mitochondrial cytopathies and cardiovascular disease. *Heart* **2014**, *100*, 611–618. [[CrossRef](#)] [[PubMed](#)]
50. Elorza, A.A.; Soffia, J.P. mtDNA Heteroplasmy at the Core of Aging-Associated Heart Failure. An Integrative View of OXPHOS and Mitochondrial Life Cycle in Cardiac Mitochondrial Physiology. *Front. Cell Dev. Biol.* **2021**, *9*, 625020. [[CrossRef](#)] [[PubMed](#)]

Disclaimer/Publisher’s Note: The statements, opinions and data contained in all publications are solely those of the individual author(s) and contributor(s) and not of MDPI and/or the editor(s). MDPI and/or the editor(s) disclaim responsibility for any injury to people or property resulting from any ideas, methods, instructions or products referred to in the content.