

Technique for Harvest of Superficial Quadriceps Tendon Autograft



Nguyen Quang Ton Quyen, M.D., Duong Minh Hieu, M.D., Vu Trung Hieu, M.D.,
Pham Dinh Vinh, M.D., Truong Nguyen Khanh Hung, M.D., Ph.D., and
Tang Ha Nam Anh, M.D., Ph.D.

Abstract: The idea of using quadriceps tendon autograft (QT) anterior cruciate ligament reconstruction first came into being in the 1990s; it was, however, not widely recognized and has resurfaced only in recent times. Because sufficient technological supports have not been developed to enable an optimal artificial graft, autologous grafts are still the most dependable option. The major reason for choosing QT instead of hamstring or patellar tendon to get autologous grafts is that it seems to cause the fewest donor site problems. Two commonly applied ways of using the quadriceps are partial and full thickness; another option is superficial. Our technique for harvesting the superficial part of the QT, which starts proximal to the fused point of the 3 layers, is aimed at circumventing premature cutting of the graft.

Despite being one of the most common orthopaedic surgeries, anterior cruciate ligament (ACL) reconstruction still arouses considerable controversy regarding the treatment of ACL injury, in general, and debates on graft choice, in particular. Each type of graft exposes its own limitations, with patellar tendon (PT) grafts possibly leading to a higher incidence of anterior knee pain and patellar fracture and hamstring grafts (HT) being associated with a greater failure rate and knee flexion weakness.^{1,2} The currently available literature discloses highly favorable outcomes of quadriceps tendon autograft (QT) compared with HT or PT.³ QT also provides a viable option in the situation of multiple-ligament knee injury.

There are 2 apparent reasons why this type of graft has not become popular: the complexity of the harvesting technique and the unavailability of fixation

implants. A short full-thickness QT graft can be obtained with an open procedure,⁴ which is overly invasive and unfavorable to most surgeons; or by a minimally invasive technique with certain instruments occasionally unavailable to them.⁵ The fixation of a short full-thickness QT (6-8 cm) into the tunnel requires special implants.^{5,6} Therefore the idea of using a long superficial QT graft may offer the surgeon an option that is both more feasible and more capable of gaining full benefits of QT autograft.

We describe our technique for harvesting superficial QT, which starts dissection proximal to the fused point of the tendon, making it trouble-free to identify the superficial layer. As a result, there is no need to exert considerable force to strip the graft off the main tendon, avoiding the risk of premature graft amputation

Surgical Technique

Before incision, mark out the anatomical landmarks of the knee including the patella, patellar tendon, and tibial tuberosity. A 3 to 4 cm transverse incision is made 2 fingerbreadths proximal to the patella, gently dissect through the subcutaneous fat until reaching the fascia. Use 2 small Farabeuf retractors and a surgical sponge to peel the adjacent fat tissue away from the tendon. At this time, the vastus lateralis, the vastus medialis, the superior pole of the patella and the entire QT can be seen easily (Fig 1; Video 1).

From about 4 to 5 cm proximal to the patella, mark the planned graft, which is usually 10 mm wide and in the middle part of the QT, and then make two parallel hole

From the Department of Orthopedic Surgery, Tam Anh Hospital, Ha Noi, Vietnam (N.Q.T.Q., D.M.H., V.T.H.); Private practice, Ho Chi Minh City, Vietnam (P.D.V.); the Orthopedic and Trauma Department, Cho Ray Hospital, Ho Chi Minh City, Vietnam (T.N.K.H.); the Center of Orthopedics and Traumatology, Tam Anh Hospital, Ho Chi Minh City, Vietnam (T.H.N.A.).

Received August 22, 2023; accepted December 1, 2023.

Address correspondence to Nguyen Quang Ton Quyen, M.D., Department of Orthopedic Surgery, Tam Anh Hospital, 08 Hoang Nhu Tiep Street, Ward Bo De, District Long Bien, Ha Noi, Vietnam. E-mail: quyenortho@gmail.com

© 2024 THE AUTHORS. Published by Elsevier Inc. on behalf of the Arthroscopy Association of North America. This is an open access article under the CC BY-NC-ND license (<http://creativecommons.org/licenses/by-nc-nd/4.0/>).

2212-6287/231190

<https://doi.org/10.1016/j.eats.2024.102920>

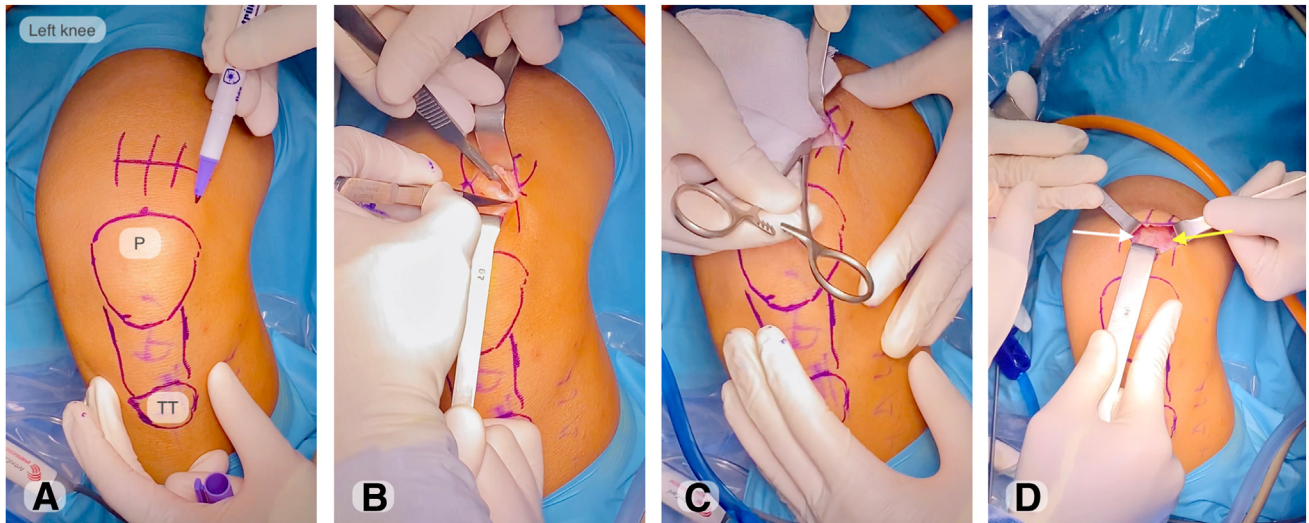


Fig 1. Anatomic landmarks. (A) Skin incision. (B) Subcutaneous fat dissection. (C) Adjacent fat tissue to peel off. (D) Quadriceps tendon autograft exposure. P, patella; TT, tibial tuberosity.

incisions in the 2 edges of the graft. Use a right-angle forceps to connect these 2 separate punctures, and split between the superficial and intermediate layer of the quadriceps, which is usually 3 mm in depth. Wrap a no. 1 Vicryl suture (Ethicon, Somerville, NJ) around the graft and lift it up to see if the correct plane has been entered. Normally, a clear space is found between the rectus femoris (RT) superficially and the remaining QT profoundly. If fibrous bands are still connected to the underlying tendon, that is because we have probably gone too deep. Otherwise, the tendon will be easily separated from the layer underneath (Fig 2).

Pull the Vicryl suture to tension the graft so that the direction of the tendon fibers can be seen; then gradually release the 2 edges of the graft upward and avoid

going in the wrong orientation. Notice that the superficial layer is only about 3 mm, so there is no need to go too deep into the QT itself. When there is enough space, slide the finger underneath the graft to make a blunt dissection proximally toward the origin of the rectus, then we can feel 2 layers of tendon above and below the finger. While maintaining its distal insertion on the patella, harvest the graft proximally with an open tendon stripper (Fig 3).

Whenever there is any resistance, check again if we are on the right plane and if we have enough release; always follow the RT direction toward the anterior-inferior iliac spine. Pull the proximal stump of the tendon out of the wound, and use a clamp with a sponge to hold and tension it. Then, use scissors to process

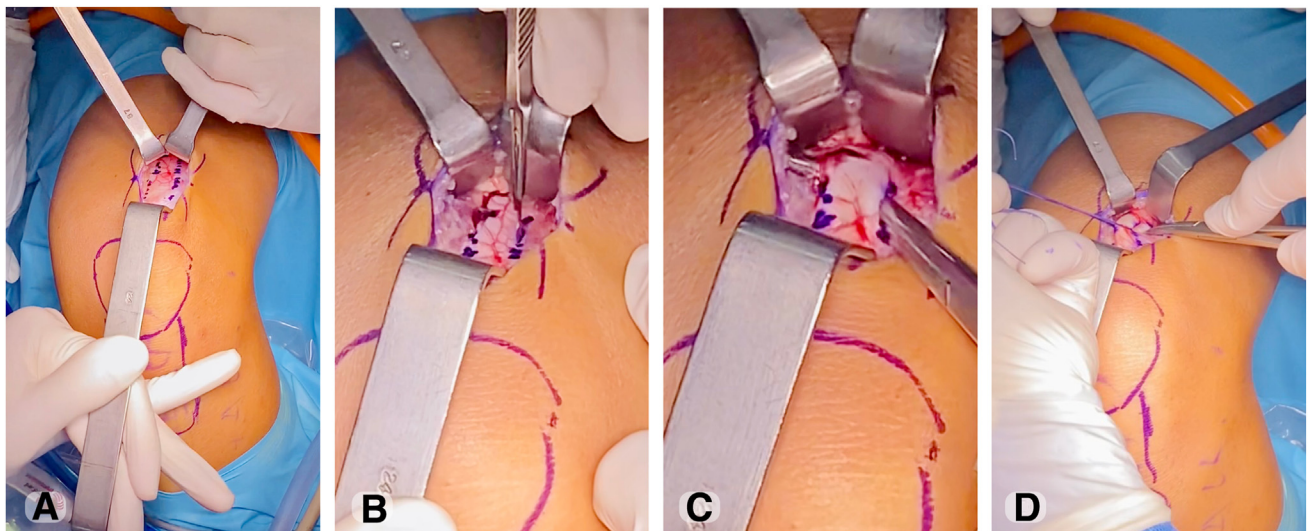


Fig 2. (A) The planned graft marking. (B) Two separate 3 mm-deep punctures. (C) Separating the superficial part with a right-angle forceps. (D) Graft wrapping by a 1.0 Vicryl suture (Ethicon, Bridgewater, NJ). Left knee, supine Position with knee in 90 degree of flexion.

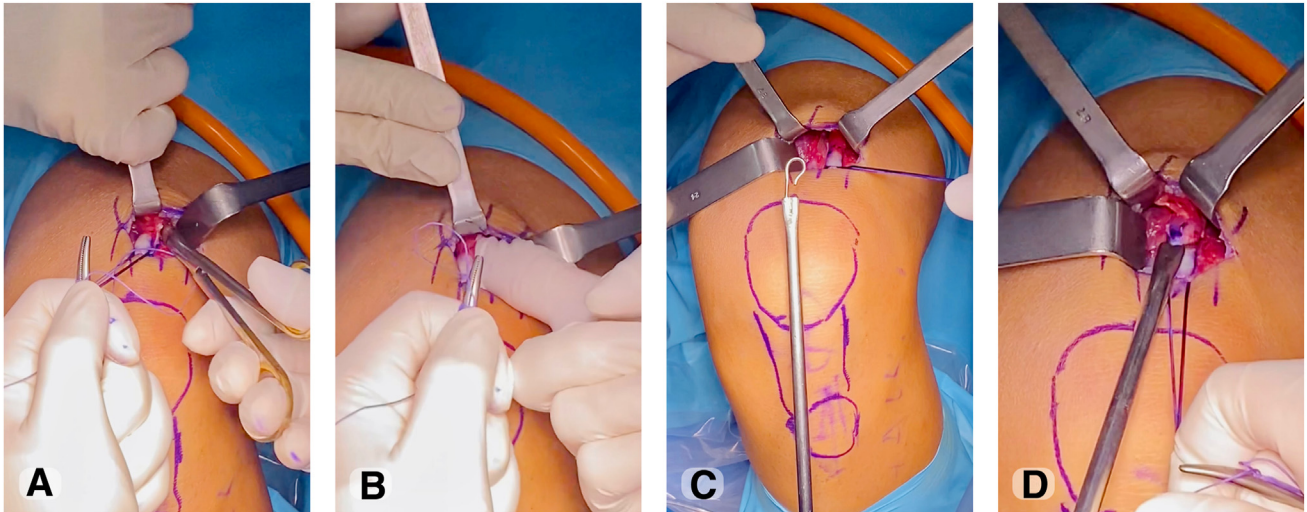


Fig 3. (A) Two edges of the graft are released. (B) The space between the 2 layers is determined. (C) A blunt edge harvester manufactured by a local company, similar to Arthrex's design, is shown. (D) The tendon is secured in the loop (left knee, supine position with knee in 90 degree of flexion).

dissecting out the graft distally toward its patellar insertion, and finally amputate the graft off the bone surface (Fig 4). We opt not to close the tendon defect itself. Instead, we insert some fibrin clot to, we hope, stimulate the healing, secure it with a running locking stitch, and finish skin closure in the standard fashion (Fig 5).

Discussion

Recent literature has continued to support the use of quadriceps tendon autograft for ACL reconstruction by providing equivalent clinical results compared with other autografts with less donor site morbidity.⁷ The 2 most common ways to harvest a QT autograft usually result in partial- or full-thickness graft and approximately 80 mm in length. The fixation of these short

grafts requires special implants that are unavailable in many institutions. In contrast, with a long, superficial quadriceps graft, the procedure is simply the same as what we usually do with the hamstring tendon, which is familiar to most surgeons.

The superficial layer of the QT is always independently composed of the rectus femoris tendon, which is fused to the underneath layer at about 4.5 cm above the patella.^{8,9} The average thickness of the superficial layer is 3 mm.⁹ On the basis of this anatomical understanding, we propose to start dissection proximally to the fused point, harvest a 10 mm-wide and 3 mm-deep middle part of the RT, which almost always results in a quadruple graft with a diameter of 8.5 to 9 mm.

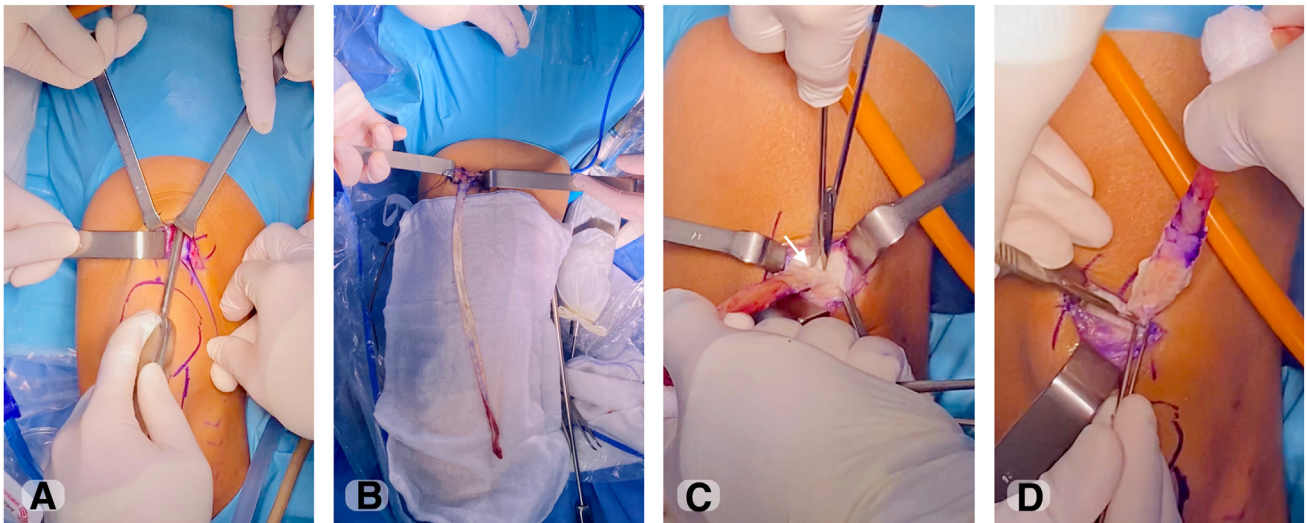


Fig 4. (A) Directing the harvester toward the ASIS. (B) Harvesting the proximal part of the graft. (C) Dissecting the distal part of the graft off the main tendon. (D) Amputating the the graft (left knee, supine position with knee in 30 degree of flexion).

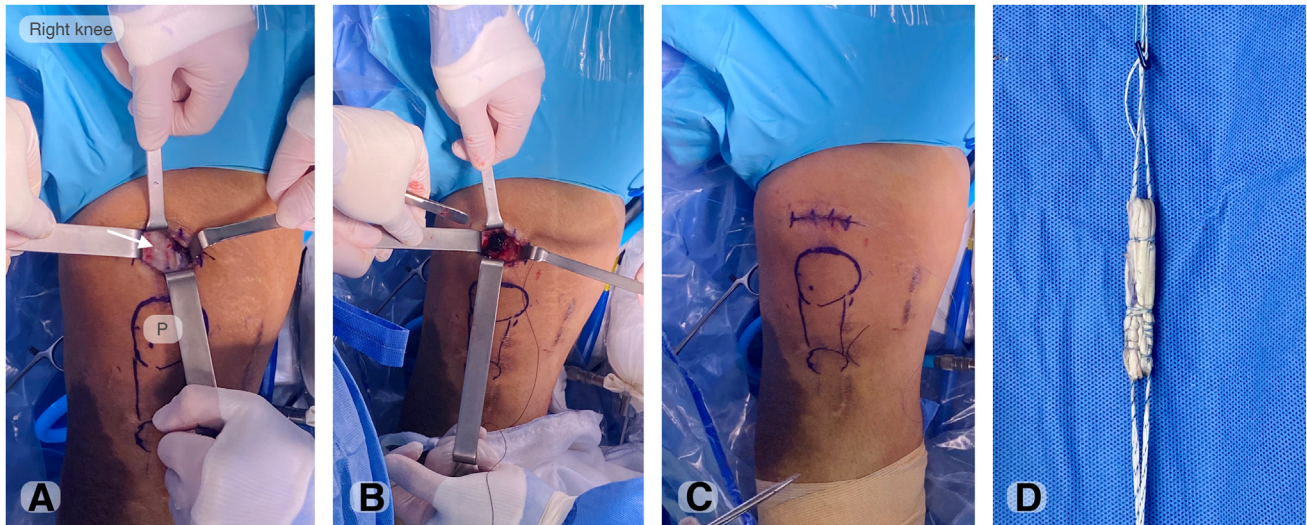

Fig 5. (A) Check the integrity of the remaining tendon. (B) Fibrin clot. (C, D) Closure and graft preparation (right knee, supine position with knee in full extension). P, patella.

Table 1. Surgical Pearls and Pitfalls

Surgical Pearls and Pitfalls	
Pearls	
Skin incision: a 3 cm transverse incision	
Dissection: starting proximal to the fused point	
Slide the finger between the first and second layers	
Mark a 10mm wide graft in the middle part of the QT	
Keep the distal insertion while stripping the graft	
Pitfalls	
Considerable force when stripping (wrong plane)	
Wrong direction while harvesting	

Table 2. Advantage and Disadvantages of the Technique

Advantage and Disadvantages of the Technique	
Advantages	
Less visible scars	
Lower risk of premature amputation	
Avoid penetrating the joint	
The graft is compatible with any fixation system.	
Disadvantages	
Necessary but not mandatory to have an open stripper	

There are 2 situations when we may encounter troubles and unwittingly cut off the tendon. One is getting into the wrong plane, not between the first 2 layers but too deep into the second layer. To cope with this, once we cannot gently strip off the proximal part, we need to stop and start all over again to get into the correct space. The other is not stripping the RT in the right direction. This can be avoided by determining the iliac spine before stripping.

In the unavailability of an open harvester, after identifying the superficial layer, dissect it distally toward its patellar insertion and cut the graft off the bone, then harvest it with a closed harvester proximally. Some may worry that removing the entire superficial layer of the QT may cause pain and extension weakness

after surgery, but we have so far not found that to be the case.

Advantages, disadvantages, surgical pearls and pitfalls of the technique are summarized in [Tables 1 and 2](#).

Disclosures

The authors report no conflicts of interest in the authorship and publication of this article. Full ICMJE author disclosure forms are available for this article online, as [supplementary material](#).

References

1. Kartus J, Movin T, Karlsson J. Donor-site morbidity and anterior knee problems after anterior cruciate ligament reconstruction using autografts. *Arthroscopy* 2001;17:971-980.
2. Persson A, Fjeldsgaard K, Gjertsen J-E, et al. Increased risk of revision with hamstring tendon grafts compared with patellar tendon grafts after anterior cruciate ligament reconstruction: A study of 12,643 patients from the Norwegian Cruciate Ligament Registry, 2004-2012. *Am J Sports Med* 2014;42:285-291.
3. Mo Z, Li D, Yang B, Tang S. Comparative efficacy of graft options in anterior cruciate ligament reconstruction: A systematic review and network meta-analysis. *Arthrosc Sports Med Rehabil* 2020;2(5):e645-e654.
4. Lippe J, Armstrong A, Fulkerson JP. Anatomic guidelines for harvesting a quadriceps free tendon autograft for anterior cruciate ligament reconstruction. *Arthroscopy* 2012;28:980-984.
5. Fink C, Herbolt M, Abermann E, Hoser C. Minimally invasive harvest of a quadriceps tendon graft with or without a bone block. *Arthrosc Tech* 2014;3(4):e509-e513.
6. Lavender C, Fravel W, Patel T, Singh V. Minimally invasive quad harvest featuring endoscopic closure and preparation with adjustable suspensory fixation device incorporated with braided suture. *Arthrosc Tech* 2021;10(1):e217-e220.

7. Clinger B, Xerogeanes J, Feller J, et al. Quadriceps tendon autograft for anterior cruciate ligament reconstruction: State of the art. *J ISAKOS* 2022;7:162-172.
8. Strauss M, Kennedy ML, Brady A, et al. Qualitative and quantitative anatomy of the human quadriceps tendon in young cadaveric specimens. *Orthop J Sports Med* 2021;9(9):23259671211037305.
9. Olewnik Ł, Zielinska N, Ruzik K, et al. A new look at quadriceps tendon—Is it really composed of three layers? *Knee* 2023;40:292-304.