



Accurate etiological diagnosis of *Mycoplasma hominis* mediastinitis in immunocompetent patients using metagenomic next-generation sequencing: a case series and literature review

Sishi Cai¹, Jue Pan¹, Suzhen Wang², Rong Bao², Chunmei Zhou², Xiaodong Gao³, Haruhiko Shiya⁴, Bijie Hu^{1,3}

¹Department of Infectious Diseases, Zhongshan Hospital, Fudan University, Shanghai, China; ²Department of Microbiology, Zhongshan Hospital, Fudan University, Shanghai, China; ³Department of Hospital Infection Management, Zhongshan Hospital, Fudan University, Shanghai, China; ⁴Department of Thoracic Surgery, Hokkaido University Hospital, Sapporo, Japan

Contributions: (I) Conception and design: S Cai; (II) Administrative support: J Pan, X Gao, B Hu; (III) Provision of study materials or patients: S Wang, R Bao, C Zhou; (IV) Collection and assembly of data: S Cai; (V) Data analysis and interpretation: S Cai; (VI) Manuscript writing: All authors; (VII) Final approval of manuscript: All authors.

Correspondence to: Bijie Hu, MD. Department of Infectious Diseases, Zhongshan Hospital, Fudan University, 180 Fenglin Road, Shanghai 200032, China; Department of Hospital Infection Management, Zhongshan Hospital, Fudan University, 180 Fenglin Road, Shanghai 200032, China. Email: Doctorhbj@126.com.

Background: As a culture-independent method, metagenomic next-generation sequencing (mNGS) is widely used in microbiological diagnosis with advantages in identifying potential pathogens, guiding antibiotic therapy, and improving clinical prognosis, especially in culture-negative cases. *Mycoplasma hominis* (*M. hominis*) mediastinitis is a rare and severe disease for which etiological diagnosis is important but challenging. The application of mNGS in the etiological diagnosis of mediastinitis has seldom been studied.

Methods: By searching the electronic medical history retrieval system with “*Mycoplasma hominis*” and “mediastinitis”, seven patients diagnosed with *M. hominis* mediastinitis were reviewed in Zhongshan Hospital, Fudan University, Shanghai from 9 December 2020 to 14 February 2023. Microbiological cultures and mNGS were conducted for blood, abscess, and/or mediastinal fluid. Adjustment of the antibiotic therapy due to mNGS was assessed. A literature review was conducted in the PubMed database beginning in 1970 for *M. hominis* infection and mediastinitis.

Results: For the seven patients, cultures of blood, abscess, and mediastinal fluid were negative whereas mNGS identified *M. hominis* in serum, abscess, and/or mediastinal fluid and was used to guide specific antibiotic therapy. The stringent mapped reads number of genera (SMRNG), stringent mapped reads number of species (SMRN), and coverage rate of *M. hominis* detection by mNGS were significantly higher in body fluid (abscess or mediastinal fluid) than in serum. All seven patients had underlying heart diseases and underwent previous cardiac surgery. The most common symptoms were fever and sternal pain. After detection of *M. hominis*, antibiotics were adjusted to quinolones or doxycycline except for one patient, whose diagnosis was clarified after death. Two patients died. Literature review since 1970 identified 30 cases of extra-genital infection caused by *M. hominis*. Including our seven new cases, 2 (5.4%) were neonates and 35 (94.6%) were adults. Thirty (81.1%) cases were postoperative infection and 15 (40.5%) had implanted devices. Five patients (13.5%) died.

Conclusions: mNGS might be a promising technology in the detection of fastidious pathogens such as *M. hominis*. Accurate etiological diagnosis by mNGS could guide antibiotic therapy and facilitate clinical management.

Keywords: Metagenomic next-generation sequencing (mNGS); *Mycoplasma hominis* (*M. hominis*); mediastinitis; diagnosis; case series

Submitted Feb 22, 2024. Accepted for publication Apr 07, 2024. Published online Apr 12, 2024.

doi: 10.21037/jtd-24-286

View this article at: <https://dx.doi.org/10.21037/jtd-24-286>

Introduction

Mycoplasma hominis (*M. hominis*) is a small fastidious bacterium, 0.3–0.4 µm in diameter, that lacks a typical bacterial peptidoglycan cell wall, belonging to the Mycoplasmataceae family within the Mollicutes class (1). It is part of the urogenital and respiratory tract commensal flora of healthy individuals, colonizing in the urogenital tract among 21–54% of women and 4–13% of men. Its colonization rate in the upper respiratory tract ranges from 1% to 3% among healthy adults (2). *M. hominis* predominantly causes genitourinary tract infections such as pyelonephritis, pelvic inflammatory diseases, chorioamnionitis, and cesarean section wound infections. These infections particularly occur during the peripartum period and might be associated with potential adverse neonatal outcomes such as bronchopulmonary dysplasia (3,4). Extra-genitourinary infections are relatively rare but have also been documented, including mediastinitis (2,5-8), wound infections (1,9), arthritis (10-14), meningitis (4,15-18), endocarditis (19-21), and abscess (22,23), a large portion of which are postoperative infection. Among them, *M. hominis* mediastinitis especially tends to be severe with high mortality. In previous literatures, these infections usually occur in immunocompromised patients. However, extra-genitourinary infections of *M. hominis* are rare and the number of reported cases is limited. Patients with extra-

genitourinary infections of *M. hominis* have significant heterogeneity and this disease lacks sufficient study.

The lack of a rigid cell wall renders *M. hominis* unable to be visualized on bacterial gram stains and osmotically fragile, requiring an *M. hominis*-specific culture, which is not widely available. Growth on standard aerobic or anaerobic bacterial culture plates is slow and insensitive (8). Difficulty in culturing and identifying *M. hominis* leads to a dilemma in early diagnosis and intervention. Delayed diagnosis is common and might be associated with inappropriate antibiotic application and poor outcomes. Culture-independent techniques such as polymerase chain reaction (PCR) and *M. hominis* antigen tests might be more sensitive, but a prior suspicion of *M. hominis* infection is required for their implementation, which is often overlooked clinically.

Metagenomic next-generation sequencing (mNGS) is an advanced technique with high sensitivity for the etiological diagnosis of infectious diseases. The comprehensive and unbiased nature of mNGS has especially facilitated identification of relatively rare pathogens (24). However, its application in diagnosing *M. hominis* mediastinitis has been less studied, mainly due to the status that this disease is very rare. As a culture-independent diagnostic method, mNGS has advantages in the identification of fastidious pathogens such as *M. hominis*. Here, we report seven cases of *M. hominis* mediastinitis identified by mNGS and review them along with previously reported cases of extra-genitourinary *M. hominis* infections. In our study, the seven reported cases of *M. hominis* mediastinitis were not immunocompromised, expanding our understanding of this disease. We present this article in accordance with the STROBE and AME Case Series reporting checklists (available at <https://jtd.amegroups.com/article/view/10.21037/jtd-24-286/rc>).

Methods

Patients

The research design of this study was a retrospective case series. Searching our electronic medical history retrieval system, we retrospectively reviewed seven patients diagnosed with *M. hominis* mediastinitis who were admitted to Zhongshan Hospital, Fudan University, Shanghai from 9 December 2020 to 14 February 2023. Routine

Highlight box

Key findings

- Metagenomic next-generation sequencing (mNGS) may be a promising tool for detecting pathogens in patients with *Mycoplasma hominis* (*M. hominis*) mediastinitis.

What is known and what is new?

- *M. hominis* mediastinitis is rare but life-threatening. Culture of *M. hominis* is challenging and delay of diagnosis is common.
- mNGS is more sensitive and time saving than culture in detecting *M. hominis*.

What is the implication, and what should change now?

- The application of mNGS for the etiological diagnosis of *M. hominis* mediastinitis could guide antibiotic treatment strategies and improve clinical outcomes.

microbiological cultures for blood, abscess, mediastinal fluid, and sputum were conducted after admission. mNGS was applied when conventional culture turned negative and atypical pathogens were suspected. The study was conducted in accordance with the Declaration of Helsinki (as revised in 2013). The study was approved by the Ethical Review Committee of Zhongshan Hospital, Fudan University, Shanghai, China (No. B2017-193R) and informed consent was taken from all the patients or the relatives.

Literature review

We searched in PubMed articles published in English beginning in 1970 with the terms “*M. hominis* infection” or “mediastinitis”. Demographic, clinical, and microbiological data were collected in a specifically developed case report form.

Culture

All seven patients underwent blood culture by peripheral venous puncture at least once during fever after admission. 8–10 mL of blood samples were injected into aerobic, anaerobic, and fungal blood culture bottles [BD BACTEC™, Becton, Dickinson, and Co. (BD), Franklin Lakes, NJ, USA] and then loaded into an automated continuous monitoring system (BD BACTEC™, BD) for 1 week. Abscess, mediastinal fluid, and sputum were cultured onto blood agar, chocolate agar, and fungal chromogenic plates for 1 week. If the culture had bacterial or fungal growth, strain identification was performed by VITEK MALDI-TOF mass spectrometry (bioMérieux, Craponne, France). Antimicrobial susceptibility tests were conducted using Vitek 2 (bioMérieux).

mNGS

Sample processing, mNGS, and analysis were performed as described previously. Blood samples were stored at room temperature whereas all other specimens were stored at –80 °C before testing. A total of 5 mL of blood was drawn from patients. After centrifugation, the plasma sample was transferred to a new sterile tube. Samples of 3 mL of abscess or mediastinal fluid were collected from patients according to standard procedures. DNA was extracted using a TIANamp Micro DNA Kit (DP316; TIANGEN Biotech,

Beijing, China), followed by DNA library generation, PCR amplification, and analysis by an Ion Torrent Proton Sequencer (Life Technologies, Carlsbad, CA, USA). Before sequencing, an Agilent 2100 Bioanalyzer (Agilent Technologies, Santa Clara, CA, USA) and quantitative PCR (qPCR) were used to evaluate the quality of the DNA libraries. Qualified DNA libraries were sequenced on the Ion Torrent Proton (Life Technologies, South San Francisco, CA, USA) sequencing platform. High-quality sequencing data were produced by removal of low-quality and short (length <35 bp) reads. Human host sequences mapped to the human reference genome (hg19) were removed via Burrows-Wheeler Alignment. The remaining nonhuman data were aligned to four microbial genome databases consisting of viruses, bacteria, fungi, and parasites which can be downloaded from the National Center for Biotechnology Information (NCBI; <ftp://ftp.ncbi.nlm.nih.gov/genomes/>). The RefSeq contains 4,189 virus, 2,328 bacteria, 199 fungi, and 135 parasites related to human infectious diseases.

Criteria for a positive mNGS result

The measurement parameters of mNGS results in this study consisted of coverage rate, relative abundance of species, stringent mapped reads number of species (SMRN), relative abundance of genera, and stringent mapped reads number of genera (SMRNG).

For bacteria, viruses, and parasites, a positive mNGS result must meet the following conditions: on the species level, mNGS identified a bacterium, virus, or parasite whose coverage rate scored 10-fold greater than that of any other bacteria, viruses, or parasites according to a previous study (24).

For fungi, the criteria for a positive mNGS result were as follows: on the species level, mNGS identified a fungus whose coverage rate scored 5-fold greater than that of any other fungi (24).

Statistical analysis

Continuous variables were expressed as median (interquartile range) if they followed a non-normal distribution. Comparative analysis between the two groups was conducted by the Mann-Whitney *U* test. Data analysis was performed with the statistical software SPSS version 21.0 (IBM Corp., Armonk, NY, USA). All tests were two-

tailed, and statistical significance was considered at $P < 0.05$.

Results

Patient evaluation

The clinical features of the seven patients are summarized in *Table 1*. All seven patients had underlying heart diseases and underwent previous cardiac surgery, five at our hospital and two at the local hospital before onset of infection. None of them were receiving glucocorticoids or immunosuppressive therapy.

Infection occurred 2 days, 6 days, 7 days, 12 days, 2.5 years, and 40 days after the initial cardiac surgery in patient A, B, C, D, E, and G, respectively. For patient F, infection occurred 5 years after the first cardiac surgery and 2 years after the second surgery, presumably caused by the same pathogen. All seven patients had fever and sternal pain, which were the first signs of infection. Patients with acute or subacute courses (A, B, C, D, and G) had purulent mediastinal or sternal wound fluids.

Imaging examination such as X-ray or computed tomography (CT) scan revealed mediastinal, pericardial, pleural effusion, and lung exudation. ^{18}F -fluorodeoxyglucose (^{18}F -FDG) positron emission tomography (PET)/CT showed glucose metabolism increase in paraaortic, pericardial, and mediastinal areas in patients E and F, as shown in *Figure 1*. Transthoracic echocardiography (TTE) indicated concurrent infective endocarditis in patients C, E, and F. Detection of *M. hominis* by mNGS in serum indicated concurrent bloodstream infection in patient A, B, C, E, and F.

Pathogen detection

For each patient, blood cultures were conducted at least once during fever after admission, all of which returned negative results. Abscess of surgical debridement tissues or sternal wound and mediastinal fluid were cultured repeatedly and also returned sterile results. Sputum samples of patient A and D were culture positive for *Acinetobacter baumannii* (*A. baumannii*).

Among the seven patients, mNGS identified *M. hominis* in nine clinical specimens including five serums, two abscesses, and two mediastinal fluids, as shown in *Table 2*. mNGS also detected concurrent infections of *Ureaplasma parvum* in the serum and abscess of patient B, *Ureaplasma urealyticum* in the abscess of patient C and mediastinal fluid

of patient G, and *A. baumannii* in the mediastinal fluid of patient D. The turn-around time (TAT) of mNGS took 24 hours. Delay in the diagnosis of *M. hominis* infections mainly resulted from delayed conduction of mNGS.

Differences of M. hominis detection results by mNGS between serum and body fluid

The SMRNG, SMRN, and coverage rate of *M. hominis* detection by mNGS were significantly higher in body fluid (abscess or mediastinal fluid) than in serum ($P < 0.05$), as shown in *Table 3*. There was no significant difference in relative abundance of genera or species of *M. hominis* detection between serum and body fluid.

Antibiotic adjustment, surgical treatment, and outcomes

After detection of *M. hominis*, antibiotic regimens were adjusted to quinolones or doxycycline except for in patient C, whose diagnosis was clarified after death. Patients A and D received merely antibiotic treatment and mediastinum drainage while the other five patients underwent re sternotomy and debridement surgery in addition to conservative treatment. Patients C and D died as a result of infection deterioration whereas the other five patients completely recovered.

Literature review

Our literature review since 1970 identified 30 cases of mediastinitis, wound infections, arthritis, meningitis, endocarditis, and abscess caused by *M. hominis*, as shown in *Table 4*. Including our seven new cases, 2 (5.4%) were neonates and 35 (94.6%) were adults. A total of 31 patients (83.8%) were male. Surgery had been previously conducted in 30 patients (81.1%) and 15 (40.5%) had implanted devices. There were 12 patients (32.4%) who were immunocompromised including 7 (18.9%) with organ transplantation and 5 (13.5%) under glucocorticoids or immunosuppressive therapy due to autoimmune diseases. Concurrent infections occurred in 12 patients (32.4%) including three coinfecting with *Ureaplasma urealyticum*, three with *Staphylococcus epidermidis*, two with *A. baumannii*, one with *Ureaplasma parvum*, one with *Actinomyces*, one with *Klebsiella pneumoniae* and *Serratia marcescens*, and one with *Pseudomonas aeruginosa*. There were 24 cases (64.9%) whose culture returned positive. 16S ribosomal RNA (rRNA) sequencing and PCR assisted the etiological diagnosis in 29

Table 1 Summary of the seven newly reported cases of *M. hominis* mediastinitis

Patient: age (years), gender	Associated conditions	Initial operation(s)	Onset of symptoms	Image findings	Specimen(s) positive for <i>M. hominis</i> identified by mNGS	Concurrent infection(s)	Antimicrobial therapy	Revision operation(s) or procedure(s)	Outcomes
A: 54, M	CKD, congenital bicuspid aortic valve malformation, severe aortic and mitral regurgitation, LVEF 55%	Bentall procedure, mechanical mitral valve replacement, tricuspid valve plasty	POD 2, fever, purulent mediastinal fluid, CRP 304.3 mg/L	POD 3, X-ray, bilateral lung exudation, left pleural effusion, POD 26, CT scan, slight inflammation in both lungs	POD 7, serum	POD 14, <i>A. baumannii</i> in sputum identified by culture	POD 2, Vm, Mem, POD 7, Dox, Lev for 3 weeks, POD 14, Scf added for 1 week	Mediastinum drainage	Defervescence and improvement of mediastinal fluid after application of specific medication against <i>M. hominis</i> , POD 27, discharge, recovery
B: 56, M	Rheumatic heart disease, severe mitral stenosis and regurgitation, LVEF 49%, AF	Mechanical mitral valve replacement, tricuspid valve plasty, radiofrequency ablation of AF	POD 6, fever, purulent sternal wound fluid, CRP 217.9 mg/L, PCT 2.33 ng/mL	POD 7, CT scan, mediastinal, pericardial and pleural effusion, improved on CT scan POD 12	POD 12, serum and surgical debridement abscess	POD 12, <i>Ureaplasma parvum</i> in serum and surgical debridement abscess, identified by mNGS	POD 6, Vm, Mem, POD 12, Lev added	POD 10, resternotomy, debridement, drainage	Defervescence and improvement of general conditions after application of specific medication against <i>M. hominis</i> , POD 20, discharge, recovery
C: 55, M	Severe aortic regurgitation, aortic valve prolapse, LVEF 64%	Mechanical aortic valve replacement, ascending aortoplasty, CABG	POD 7, purulent sternal wound fluid	POD 7, CT scan, mediastinal, pericardial and pleural effusion, POD 48, TTE, aortic valve perivalvular abscess and vegetations	POD 58, serum and surgical debridement abscess	POD 58, <i>Ureaplasma urealyticum</i> in surgical debridement abscess identified by mNGS	POD 7, Vm, Cxm, POD 44, Lzd, Ctrx, POD 49, Dap, Tzp	Mediastinum drainage, POD 56, resternotomy, debridement, Bentall procedure	Infection worsening, MODS, POD 57, death
D: 73, M	AF, bilateral atrial enlargement, moderate mitral regurgitation, severe tricuspid regurgitation, LVEF 63%	Mitral and tricuspid valve plasty, radiofrequency ablation of AF	POD 12, fever, purulent mediastinal fluid, PCT 6.76 ng/mL	POD 13, X-ray, bilateral lung exudation	POD 17, mediastinal fluid	POD 15, multidrug-resistant <i>A. baumannii</i> in sputum identified by culture, POD 17, <i>A. baumannii</i> in mediastinal fluid identified by mNGS	POD 2, Tzp, POD 10, Vm, Mem, POD 16, Lzd, Mem, Pb, POD 17, Lev added	Mediastinum drainage	POD 3, CRRT, POD 10, tracheal intubation, assisted ventilation, infection worsening, MODS, POD 22, death
E: 54, M	Stanford type A aortic dissection 3 years before admission	Ascending aortic arch replacement, descending aortic stent implantation and Bentall procedure at the local hospital 3 years before admission	Recurrent fever for 6 months, CRP 34.2 mg/L, PCT 0.1 ng/mL on admission	¹⁸ F-FDG PET/CT on admission, inflammation of the artificial aorta and mediastinum, TTE, artificial aortic perivalvular abscess and rupture, LVEF 64%	Serum on admission	None	Dox, Mxf for 3 months since detection of <i>M. hominis</i>	Resternotomy and debridement after 1-month treatment of Dox, Mxf	Defervescence 5 days after usage of Dox and Mxf, improvement of general conditions, recovery
F: 70, M	Congenital bicuspid aortic valve malformation	Aortic valve replacement at the local hospital 8 years before admission, PVE, resternotomy and aortic valve replacement 2 years before admission, blood and valve culture negative	Fever for 2 weeks, CRP 57.9 mg/L, PCT 0.13 ng/mL on admission	¹⁸ F-FDG PET/CT on admission, aortic perivalvular, pericardial and mediastinal inflammation, TTE, artificial aortic perivalvular abscess, vegetations and leak, LVEF 50%	Serum on admission	None	Lev for 3.5 months since detection of <i>M. hominis</i>	Resternotomy, debridement, Bentall procedure after 6-week treatment of Lev	Defervescence 7 days after usage of Lev, improvement of general conditions, recovery
G: 56, M	Hypertension, Stanford type A aortic dissection	Aortic valve, ascending aorta and half aortic arch replacement	POD 40, febrile, sternal wound split and pus discharge, CRP 112.4 mg/L, PCT 0.88 ng/mL	POD 40, CT scan, mediastinal, pericardial and pleural effusion	POD 65, mediastinal fluid	POD 65, <i>Ureaplasma urealyticum</i> in mediastinal fluid identified by mNGS	POD 40, Dap, Ctrx, POD 65, Dox for 3 months	POD 50, resternotomy and debridement, mediastinum drainage	Defervescence 6 days after usage of Dox, improvement of general conditions, recovery

M. hominis, *Mycoplasma hominis*; mNGS, metagenomic next-generation sequencing; M, male; CKD, chronic kidney disease; LVEF, left ventricular ejection fraction; POD, postoperative day; CRP, C-reactive protein; CT, computed tomography; *A. baumannii*, *Acinetobacter baumannii*; Vm, vancomycin; Mem, meropenem; Dox, doxycycline; Lev, levofloxacin; Scf, cefoperazone sulbactam; AF, atrial fibrillation; PCT, procalcitonin; CABG, coronary artery bypass grafting; TTE, transthoracic echocardiography; Cxm, cefuroxime; Lzd, linezolid; Ctrx, ceftriaxone; Dap, daptomycin; Tzp, piperacillin tazobactam; MODS, multiple organ dysfunction syndrome; Pb, polymyxin B; CRRT, continuous renal replacement therapy; ¹⁸F-FDG, ¹⁸F-fluorodeoxyglucose; PET, positron emission tomography; Mxf, moxifloxacin; PVE, prosthetic valve endocarditis.

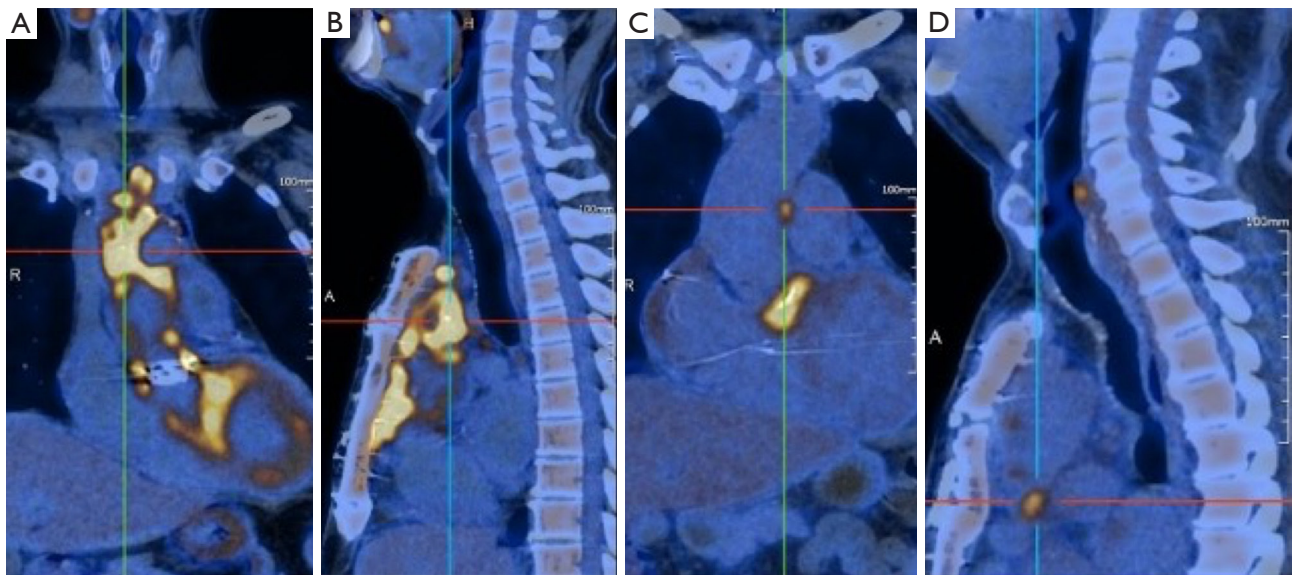


Figure 1 ^{18}F -FDG PET/CT showed glucose metabolism increase in paraaortic, pericardial, and mediastinal areas in patient E [(A,B) maximal SUV 28.9] and F [(C,D) maximal SUV 8.4]. R, right; A, anterior; ^{18}F -FDG, ^{18}F -fluorodeoxyglucose; PET, positron emission tomography; CT, computed tomography; SUV, standardized uptake value.

Table 2 Identification of *M. hominis* by mNGS in the seven newly reported mediastinitis cases

Patient No.	Specimen	SMRNG	Relative abundance of genera (%)	SMRN	Relative abundance of species (%)	Coverage rate (%)
A	Serum	72	40.62	71	40.62	0.57
B	Serum	182	31.27	176	30.29	1.14
	Abscess	7,036	62.71	6,682	61.6	33.18
C	Serum	127	7.91	123	7.78	0.83
	Abscess	13,822	96.01	13,099	94.03	52.12
D	Mediastinal fluid	70,687	45.65	66,898	44.65	80
E	Serum	2,165	88.13	2,095	87.32	12.48
F	Serum	8,390	91.7	8,156	91.04	38.52
G	Mediastinal fluid	109,706	98.65	105,970	98.11	70.12

M. hominis, *Mycoplasma hominis*; mNGS, metagenomic next-generation sequencing; SMRNG, stringent mapped reads number of genera; SMRN, stringent mapped reads number of species.

cases (78.4%). Except for our seven patients, only one case was subjected to mNGS in pathogen detection. There were 31 patients (83.8%) who underwent surgical debridement or drainage whereas 35 (94.6%) received specific antibiotic treatment against *M. hominis* including doxycycline, minocycline, quinolones, and azithromycin. A total of 5 patients (13.5%) died eventually.

Discussion

Extra-genital infections due to *M. hominis* including wound infections, abscesses, arthritis, osteitis, meningitis, and endocarditis have been documented. These infections especially occur among patients under immunosuppressive therapy due to organ transplantation or autoimmune

Table 3 Differences of *M. hominis* detection by mNGS between serum and body fluid

Parameters of mNGS results	Serum	Body fluid	P value
SMRNG	182 (99.5, 5,278)	8,733 (42,255, 99,951)	0.03
Relative abundance of genera (%)	40.62 (19.59, 89.92)	79.36 (49.92, 97.99)	0.19
SMRN	176 (97, 5126)	39,999 (8,286, 96,202)	0.03
Relative abundance of species (%)	40.62 (19.04, 89.18)	77.82 (48.89, 97.09)	0.19
Coverage rate (%)	1.14 (0.7, 25.5)	61.12 (37.92, 77.53)	0.03

Data are presented as median (IQR). *M. hominis*, *Mycoplasma hominis*; mNGS, metagenomic next-generation sequencing; SMRNG, stringent mapped reads number of genera; SMRN, stringent mapped reads number of species; IQR, interquartile range.

diseases (25). *M. hominis* infection is rare among immunocompetent hosts yet might occur postoperatively. The route of infection has been suspected to be colonization of *M. hominis* on the skin, the urinary tract, or the respiratory tract via surgical procedures, urethral catheterization, or tracheal intubation. *M. hominis* infections involving the mediastinum tended to be more severe than infections of other sites. Some cases presented as fulminant infection or sepsis whereas others may be indolent with a chronic course lasting years (2). In our newly reported seven cases, five had concurrent bloodstream infection, and were thus more difficult to manage clinically.

Up to now, *M. hominis* culture has always been challenging. Cultures of *M. hominis* usually manifest as pinpoint-sized, transparent, and nonhemolytic colonies on blood-agar plates, requiring experienced technical staff to recognize (15). Sensitivity of conventional culture is low whereas negative gram staining and the slow growth bring more challenges, leading to the underestimation of this pathogen. When regular culture is negative, atypical organisms including *M. hominis* should be taken into consideration.

M. hominis growth might be facilitated by specific culture media which is not widely available in our hospital, partially explaining the completely negative culture results of all seven patients. Even on specific culture plates, *M. hominis* growth usually takes 7 days or longer, requiring prolonged incubation, which is easily overlooked clinically. In a previous study, microbiological identification of *M. hominis* took an average of 9.1 days (range, 5–21 days) after clinical samples were obtained (2). Prompt etiological diagnosis and specific antibiotic therapy is essential in the treatment of *M. hominis* infections whereas delayed diagnosis and inappropriate antibiotic usage might lead to poor outcomes,

as demonstrated in our patients C and D.

In recent years, mNGS for pathogen detection has become widely available for a variety of sample types and patient indications. The excellent sensitivity similar to specific PCR assays, the ability to identify more potential pathogens than conventional methods, and the unbiased nature have made mNGS favored in different clinical situations (26). Previous studies most frequently elaborated on clinical application of mNGS in pulmonary infections (27), central nervous system infections (28), osteoarticular infections (29), and bloodstream infections (30) both in immunocompromised and immunocompetent patients. However, the clinical value of mNGS in the etiological diagnosis of mediastinitis has seldom been interpreted. To our knowledge, this is the first case series applying mNGS in the etiological diagnosis of *M. hominis* mediastinitis. mNGS identified the causative pathogen in seven culture-negative patients and guided specific antibiotic therapy. Clinical outcomes of patient A, B, E, F, and G had been improved and benefited by mNGS. Conduction of mNGS was significantly delayed in patients C and D and partly associated with their poor outcomes.

On the other hand, the high cost of mNGS has limited its clinical application in China to some extent. Not all patients are financially capable of payment of mNGS testing fees. For patient C and D, at the beginning of the worsening of their conditions, clinicians had already recommended mNGS to their family. Their family hesitated for financial reasons. By the time they decided to undergo mNGS testing, infection had worsened, and the patients subsequently died. For patient D, mNGS was recommended POD12. Although the patient died of multiple organ failure, partly due to surgical trauma, infection is still the most important reason for his condition

Table 4 Summary of previously reported cases of mediastinitis, wound infections, arthritis, meningitis, endocarditis, and abscess caused by *M. hominis*

Patient No.: age (years), gender	Associated conditions	Specimen(s) positive for <i>M. hominis</i>	Identification technology	Concurrent infection(s)	Treatment against <i>M. hominis</i>	Outcome	Ref.
1: -, M	Congenital heart disease, lung transplantation	Sternal wound swab	Culture	None	Dox, Azm, debridement	Resolved	(6)
2: -, M	CF, lung transplantation	Pleural fluid	Culture	None	None	Died	(6)
3: -, M	COPD, lung transplantation	Pleural fluid and BAL	Culture	None	Dox, Mxf, debridement	Resolved	(6)
4: -, M	COPD, lung transplantation	Pleural fluid and BAL	Culture	<i>Ureaplasma urealyticum</i> in pleural fluid and BAL	Dox, Cm, debridement	Resolved	(6)
5: -, M	ILD, lung transplantation	Sternal wound swab and BAL	Culture	None	Dox, Mxf, debridement	Resolved	(6)
6: 78, M	AMI, cardiac failure, CABG	Pleural fluid	Culture and PCR	None	Cm, Cpx, re sternotomy, drainage	Resolved	(2)
7: 68, M	OMI, cardiac failure, CABG	Sternal wound swab	Culture and PCR	None	Cm, re sternotomy, drainage	Died	(2)
8: 44, M	AF, CHD, CABG	Sternal wound swab	Culture and PCR	None	Oxf, re sternotomy, drainage	Resolved	(2)
9: 51, M	OMI, CABG	Sternal wound swab	Culture and PCR	<i>Staphylococcus epidermidis</i> in trachea	Cm, Dox, debridement, drainage	Resolved	(2)
10: 58, M	OMI, CABG	Mediastinal fluid	Culture and PCR	<i>Staphylococcus epidermidis</i> in sternal wound	Cm, Cpx, re sternotomy and debridement x3, drainage	Resolved	(2)
11: 48, F	Submandibular abscess, mediastinitis	Pleural fluid	Culture and PCR	<i>Actinomyces</i> in neck abscess	Cm, thoracotomy x2, drainage	Resolved	(2)
12: 63, M	Lung transplantation, mediastinitis	BAL and sputum	PCR	None	Dox, Lev, re sternotomy, debridement	Resolved	(7)
13: 54, M	Aortic valve stenosis, PFO, aortic valve replacement and PFO closure	Mediastinal abscess and urine	Culture and PCR	None	Lev, Mh, re sternotomy, debridement	Resolved	(5)
14: 21, M	Restrictive cardiomyopathy, pulmonary hypertension, heart-lung transplantation	Periaortic abscess	Culture and PCR	<i>Klebsiella pneumoniae</i> and <i>Serratia marcescens</i> in sputum	Lev, Mh, re sternotomy and debridement, mediastinal lavage	Resolved	(25)
15: 48, M	MS, immunocompromised, right hip arthroplasty	Synovial fluid of the hip and blood	Culture	None	Mh, irrigation and debridement	Resolved	(10)
16: 58, F	RA, immunocompromised, bilateral hip arthroplasty	Synovial fluid of the knee and hip	Culture and PCR	None	Dox, Mxf, debridement	Resolved	(13)
17: 59, M	Left hip replacement	Synovial fluid of the left hip	Culture and 16S	None	Cm, Mxf, debridement	Resolved	(14)
18: 27, F	SLE, immunocompromised	Synovial fluid of the left elbow	16S	None	Dox	Resolved	(11)
19: 30, M	TTP, immunocompromised	Abscess of the left hip and iliopsoas	Culture and PCR	None	Dox, Mxf, arthrotomy x2, irrigation	Resolved	(12)
20: 52, M	Traumatic brain injury, decompressive craniotomy	Head incision fluid and CSF	Culture and 16S	None	Mh, continued CSF drainage	Resolved	(15)
21: 61, M	Intracerebral hemorrhage, decompression craniotomy	CSF	mNGS and PCR	None	Mxf	Resolved	(16)
22: 39, M	Subarachnoid hemorrhage, external ventricular drainage	CSF	Culture, 16S, PCR	None	Mxf, external ventricular drainage	Died	(18)
23: 0, F	Born at term, uncomplicated vaginal delivery	CSF	16S	None	Mxf	Resolved	(4)
24: 0, M	Extremely preterm neonate (25+6 weeks), vaginal delivery, intraventricular hemorrhage	CSF	16S	None	Dox, Mxf	Resolved	(17)
25: 67, M	Ventricular tachycardia and ICD implantation	Pericardial fluid, pocket wound exudate, ICD lead	Culture and PCR	None	Dox, Mxf, ICD explantation, debridement of the generator pocket	Resolved	(19)
26: 28, M	Aortic valve and root replacement, PVE, reoperation x5, aortic homograft	Surgically removed valves and aortic tissues	16S	None	Mxf, debridement, heart transplantation	Resolved	(20)
27: 74, M	Mitral and aortic prosthetic valve replacement, PVE	Surgically removed valves	Culture and 16S	<i>Staphylococcus epidermidis</i> by blood culture	Cm, Dox, mitral and aortic valve replacement	Resolved	(21)
28: 43, M	Multiple open traumas caused by a traffic accident	Serum and wound swab	Culture and 16S	<i>Pseudomonas aeruginosa</i> in wound swab	Mh	Resolved	(9)
29: 55, F	RA, immunocompromised, perirectal abscess	Perirectal abscess	Culture	None	Dox, debridement, resection of the rectum	Resolved	(22)
30: 38, F	Total disc arthroplasty, postoperative retroperitoneal abscess	Retroperitoneal abscess	Culture	None	Dox, debridement, drainage	Resolved	(23)

M. hominis, *Mycoplasma hominis*; ref., reference; -, not available; M, male; Dox, doxycycline; Azm, azithromycin; CF, cystic fibrosis; COPD, chronic obstructive pulmonary disease; BAL, bronchoalveolar lavage; Mxf, moxifloxacin; Cm, clindamycin; ILD, interstitial lung disease; AMI, acute myocardial infarction; CABG, coronary artery bypass grafting; PCR, polymerase chain reaction; Cpx, ciprofloxacin; OMI, old myocardial infarction; AF, atrial fibrillation; CHD, coronary heart disease; Oxf, ofloxacin; F, female; Lev, levofloxacin; PFO, patent foramen ovale; Mh, minocycline; MS, multiple sclerosis; RA, rheumatoid arthritis; 16S, 16S ribosomal RNA sequencing; SLE, systemic lupus erythematosus; TTP, thrombotic thrombocytopenic purpura; CSF, cerebrospinal fluid; mNGS, metagenomic next-generation sequencing; ICD, implantable cardioverter defibrillator; PVE, prosthetic valve endocarditis.

worsening. *A. baumannii* seems to be less virulent than *M. hominis* and might not be the main cause of death.

In our hospital, the TAT of mNGS is 24 hours, much shorter than that of conventional culture. mNGS is more sensitive and time saving than culture in the detection of fastidious pathogens.

mNGS detected *M. hominis* with higher SMRNG, SMRN, and coverage rate in body fluid specimens (abscess or mediastinal fluid) than in serum, probably indicating more biomass and priority of body fluid if there was a choice of specimen type.

In previously reported cases, treatment for *M. hominis* infections included drainage, debridement, lavage, and specific antibiotics such as doxycycline, minocycline, quinolones, and azithromycin. Surgical debridement is crucial as demonstrated in many cases, especially our patient G. His general conditions had already significantly improved since resternotomy and debridement postoperative day (POD) 50 before identification of *M. hominis* infection and specific antibiotic treatment, which were delayed until POD 65. As for our patient F, after 6-week treatment of levofloxacin before debridement surgery, his serum mNGS was still positive for *M. hominis* although biomass amount had reduced (SMRNG: 8,390→2,538; SMRN: 8,156→2,462). After debridement surgery, he was prescribed levofloxacin for another 2 months after which serum mNGS turned negative. For patient C, resternotomy and debridement were delayed until POD 56 and *M. hominis* was identified after death. For patient D, debridement surgery was infeasible because of their severely ill condition and identification of *M. hominis* was delayed until POD 17. Lack of prompt debridement and specific antibiotics partly led to the deaths of patients C and D.

Conclusions

Extra-genital infection caused by *M. hominis* is extremely rare among immunocompetent hosts and could be life-threatening. Identification of *M. hominis* is challenging through conventional microbiological culture and delay of diagnosis is common. mNGS is more sensitive and time saving than culture in the detection of *M. hominis*. If conventional microbiological findings are negative or the patient responds poorly to standard therapy, the clinicians should consider the possibility of *M. hominis* involvement and apply culture-independent methods such as mNGS. Early diagnosis, specific antibiotics, drainage,

and debridement are crucial to the treatment of *M. hominis* infection.

Acknowledgments

The authors extend their thanks to all the clinicians and microbiologists who assisted in this study.

Funding: This work was funded by the Zhongshan Hospital of Fudan University (No. 2021ZSFZ06).

Footnote

Reporting Checklist: The authors have completed the STROBE and AME Case Series reporting checklists. Available at <https://jtd.amegroups.com/article/view/10.21037/jtd-24-286/rc>

Data Sharing Statement: Available at <https://jtd.amegroups.com/article/view/10.21037/jtd-24-286/dss>

Peer Review File: Available at <https://jtd.amegroups.com/article/view/10.21037/jtd-24-286/prf>

Conflicts of Interest: All authors have completed the ICMJE uniform disclosure form (available at <https://jtd.amegroups.com/article/view/10.21037/jtd-24-286/coif>). The authors have no conflicts of interest to declare.

Ethical Statement: The authors are accountable for all aspects of the work in ensuring that questions related to the accuracy or integrity of any part of the work are appropriately investigated and resolved. The study was conducted in accordance with the Declaration of Helsinki (as revised in 2013). The study was approved by the Ethical Review Committee of Zhongshan Hospital, Fudan University, Shanghai, China (No. B2017-193R) and informed consent was taken from all the patients or the relatives.

Open Access Statement: This is an Open Access article distributed in accordance with the Creative Commons Attribution-NonCommercial-NoDerivs 4.0 International License (CC BY-NC-ND 4.0), which permits the non-commercial replication and distribution of the article with the strict proviso that no changes or edits are made and the original work is properly cited (including links to both the formal publication through the relevant DOI and the license). See: <https://creativecommons.org/licenses/by-nc-nd/4.0/>.

References

- Hopkins PM, Winlaw DS, Chhajed PN, et al. Mycoplasma hominis infection in heart and lung transplantation. *J Heart Lung Transplant* 2002;21:1225-9.
- Mattila PS, Carlson P, Sivonen A, et al. Life-threatening Mycoplasma hominis mediastinitis. *Clin Infect Dis* 1999;29:1529-37.
- Capoccia R, Greub G, Baud D. Ureaplasma urealyticum, Mycoplasma hominis and adverse pregnancy outcomes. *Curr Opin Infect Dis* 2013;26:231-40.
- Wildenbeest JG, Said I, Jaeger B, et al. Neonate with Mycoplasma hominis meningoencephalitis given moxifloxacin. *Lancet Infect Dis* 2016;16:e261-6.
- Kitagawa H, Shimizu H, Katayama K, et al. Postoperative mediastinitis after cardiac surgery caused by Mycoplasma hominis: a case report. *Surg Case Rep* 2021;7:248.
- Divithotewala C, Sweeney EL, Burke A, et al. Mycoplasma hominis and Ureaplasma urealyticum infections in the immediate post-lung transplant period: A case series and literature review. *Transpl Infect Dis* 2023;25:e14058.
- Vijayvargiya P, Esquer Garrigos Z, Kennedy CC, et al. Routine Donor and Recipient Screening for Mycoplasma hominis and Ureaplasma Species in Lung Transplant Recipients. *Open Forum Infect Dis* 2022;9:ofac607.
- Sampath R, Patel R, Cunningham SA, et al. Cardiothoracic Transplant Recipient Mycoplasma hominis: An Uncommon Infection with Probable Donor Transmission. *EBioMedicine* 2017;19:84-90.
- Huang SM, Tang YR, Wang JL, et al. Case Report: Double trouble: a rare case of successfully treated Mycoplasma hominis and Pseudomonas aeruginosa co-infection. *Front Cell Infect Microbiol* 2023;13:1159891.
- Muramatsu E, Sakurai A, Kawabe Y, et al. Periprosthetic joint infection due to Mycoplasma hominis in a multiple sclerosis patient treated with fingolimod. *J Infect Chemother* 2022;28:1672-6.
- Hum RM, Ifikhar H, Tang E, et al. Septic arthritis caused by Mycoplasma hominis in a patient with systemic lupus erythematosus. *BMJ Case Rep* 2022;15:e247675.
- Ali GA, Goravey W, Hamad A, et al. An enemy in shadows-Mycoplasma hominis septic arthritis and iliopsoas abscess: Case report and review of the literature. *IDCases* 2021;26:e01260.
- Bozo N, Ravn C, Stenz Justesen U, et al. Mycoplasma hominis septic arthritis in a patient with hypogammaglobinaemia and rheumatoid arthritis. *BMJ Case Rep* 2021;14:e237798.
- Xiang L, Lu B. Infection due to Mycoplasma hominis after left hip replacement: case report and literature review. *BMC Infect Dis* 2019;19:50.
- Chen L, Lu Y, Liu J, et al. Bilateral decompressive craniotomy complicated by postoperative mycoplasma hominis epidural empyema and meningitis: A case report. *Medicine (Baltimore)* 2023;102:e33745.
- Dong Y, He Y, Zhou X, et al. Diagnosis of Mycoplasma hominis Meningitis with Metagenomic Next-Generation Sequencing: A Case Report. *Infect Drug Resist* 2022;15:4479-86.
- Ansari NS, Asztalos E, Rolnitsky A. Mycoplasma hominis meningitis in an extremely preterm newborn: a case report. *BMC Pediatr* 2021;21:69.
- Reissier S, Masson R, Guérin F, et al. Fatal nosocomial meningitis caused by Mycoplasma hominis in an adult patient: case report and review of the literature. *Int J Infect Dis* 2016;48:81-3.
- Bustos-Merlo A, Rosales-Castillo A, Cobo F, et al. Blood Culture-Negative Infective Endocarditis by Mycoplasma hominis: Case Report and Literature Review. *J Clin Med* 2022;11:3841.
- Givone F, Peghin M, Vendramin I, et al. Salvage heart transplantation for Mycoplasma hominis prosthetic valve endocarditis: A case report and review of the literature. *Transpl Infect Dis* 2020;22:e13249.
- Gagneux-Brunon A, Grattard F, Morel J, et al. Mycoplasma hominis, a Rare but True Cause of Infective Endocarditis. *J Clin Microbiol* 2015;53:3068-71.
- Stabler S, Faure E, Duployez C, et al. Closing the Brief Case: Mycoplasma hominis Extragenital Abscess. *J Clin Microbiol* 2021;59:e02344-20.
- Flouzat-Lachaniette CH, Guidon J, Allain J, et al. An uncommon case of Mycoplasma hominis infection after total disc replacement. *Eur Spine J* 2013;22 Suppl 3:S394-8.
- Miao Q, Ma Y, Wang Q, et al. Microbiological Diagnostic Performance of Metagenomic Next-generation Sequencing When Applied to Clinical Practice. *Clin Infect Dis* 2018;67:S231-40.
- Hagiya H, Yoshida H, Yamamoto N, et al. Mycoplasma hominis periaortic abscess following heart-lung transplantation. *Transpl Infect Dis* 2017. doi: 10.1111/tid.12697.
- Miller S, Chiu C. The Role of Metagenomics and Next-Generation Sequencing in Infectious Disease Diagnosis. *Clin Chem* 2021;68:115-24.
- Chen S, Kang Y, Li D, et al. Diagnostic performance of

- metagenomic next-generation sequencing for the detection of pathogens in bronchoalveolar lavage fluid in patients with pulmonary infections: Systematic review and meta-analysis. *Int J Infect Dis* 2022;122:867-73.
28. Zhang Y, Cui P, Zhang HC, et al. Clinical application and evaluation of metagenomic next-generation sequencing in suspected adult central nervous system infection. *J Transl Med* 2020;18:199.
29. Thoendel MJ, Jeraldo PR, Greenwood-Quaintance KE, et al. Identification of Prosthetic Joint Infection Pathogens Using a Shotgun Metagenomics Approach. *Clin Infect Dis* 2018;67:1333-8.
30. Jing C, Chen H, Liang Y, et al. Clinical Evaluation of an Improved Metagenomic Next-Generation Sequencing Test for the Diagnosis of Bloodstream Infections. *Clin Chem* 2021;67:1133-43.

Cite this article as: Cai S, Pan J, Wang S, Bao R, Zhou C, Gao X, Shiiya H, Hu B. Accurate etiological diagnosis of *Mycoplasma hominis* mediastinitis in immunocompetent patients using metagenomic next-generation sequencing: a case series and literature review. *J Thorac Dis* 2024;16(4):2499-2509. doi: 10.21037/jtd-24-286