

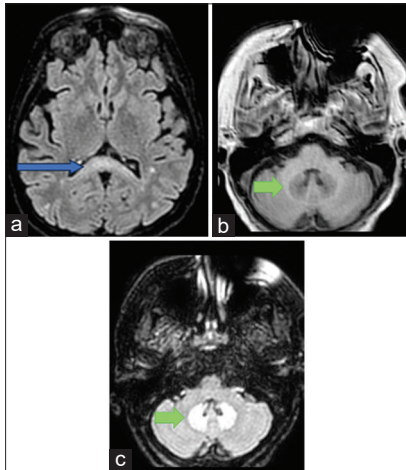
# Bilateral Dentate Nuclei Hyperintensity: An Important Diagnostic Clue in a Woman with Encephalopathy

Gabriela Lopes de Moraes, Gustavo Maximiano Alves, Fernando Henrique Magri Alves<sup>1</sup>, Natalia Oliveira da Silva, Roberto Satler Cetlin, Fabíola Dach

Department of Neurology and Neurosciences – Ribeirão Preto, Hospital das Clínicas of Ribeirão Preto (HCFMRP-USP) – University of São Paulo, School of Medicine, São Paulo, <sup>1</sup>Hospital das Clínicas of São Paulo (HC-FMUSP) – University of São Paulo, School of Medicine, São Paulo, Brazil

## CASE PRESENTATION

A woman with invasive ductal carcinoma was hospitalized due to a locally infected thoracic ulcer. Topical metronidazole was prescribed. One month later, she developed mental confusion. There were no metabolic causes to justify her altered mental state. Brain magnetic resonance imaging revealed T2/fluid attenuated inversion recovery (FLAIR) hyperintensities in the dentate nuclei [Figures 1 and 2]. Cerebrospinal fluid and electroencephalogram showed no significant changes.

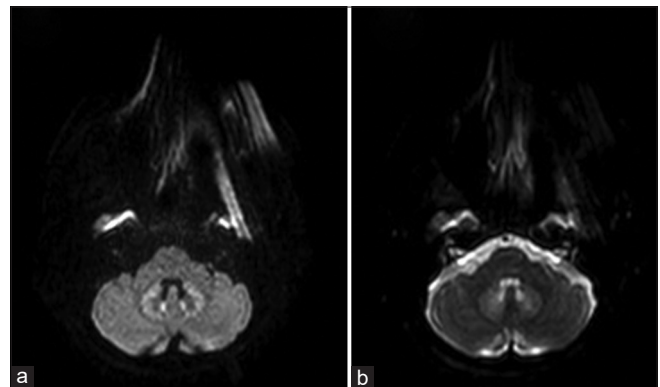


**Figure 1:** (a) Axial FLAIR scan illustrating hyperintensity within the corpus callosum (blue arrow). (b) Axial T1 imaging with bilateral dentate nuclei hypointensity (green arrow), opposite to FLAIR hyperintensity shown on (c) (green arrows). FLAIR = fluid attenuated inversion recovery

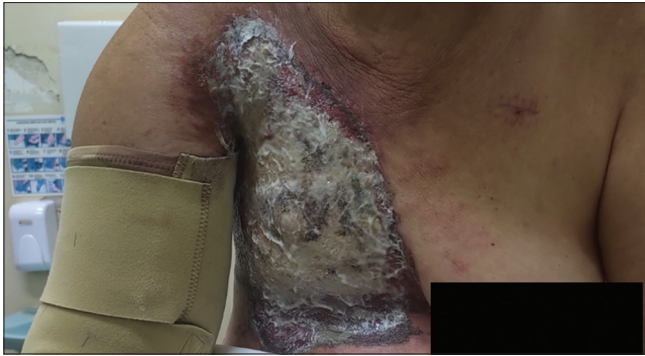Most cases of metronidazole-induced brain toxicity present with T2/FLAIR hyperintensities in the dentate nuclei.<sup>[1,2]</sup> This is the second case report in international literature of encephalopathy related to topical metronidazole.<sup>[3]</sup> Due to the extent of the ulcer being treated [Figure 3], there was probably cutaneous absorption and metronidazole intoxication.<sup>[1-3]</sup> She improved completely after the antibiotic was stopped.

## Declaration of patient consent

The authors certify that they have obtained all appropriate patient consent forms. In the form, the patient(s) has/have given his/her/their consent for his/her/their images and other



**Figure 2:** Hyperintensity on bilateral dentate nuclei on diffusion-weighted imaging (DWI) (a), with no corresponding restriction on ADC maps (b)



**Figure 3:** Large thoracic ulcer being treated with topic metronidazole for approximately 1 month before symptoms occurred

clinical information to be reported in the journal. The patients understand that their names and initials will not be published and due efforts will be made to conceal their identity, but anonymity cannot be guaranteed.

#### **Financial support and sponsorship**

Nil.

#### **Conflicts of interest**

There are no conflicts of interest.

## **REFERENCES**

1. Bond KM, Brinjikji W, Eckel LJ, Kallmes DF, McDonald RJ, Carr CM. Dentate update: Imaging features of entities that affect the dentate nucleus. *AJNR Am J Neuroradiol* 2017;38:1467-74.
2. Oliveira AM, Paulino MV, Vieira APF, McKinney AM, da Rocha AJ, Dos Santos GT, *et al.* Imaging patterns of toxic and metabolic brain disorders. *Radiographics* 2019;39:1672-95.
3. Mathew RP, Kunhimohammed SP. A case of topical metronidazole-induced encephalopathy. *JAMA Neurol* 2020;77:1318-9.

**Address for correspondence:** Dr. Gabriela Lopes de Morais, Department of Neurology and Neurosciences – Ribeirão Preto, Hospital das Clínicas de Ribeirão Preto (HCFMRP-USP) – University of São Paulo, School of Medicine, São Paulo, Brazil.  
E-mail: glmorais@hcrp.usp.br

**Submitted:** 11-Nov-2023 **Revised:** 28-Feb-2024 **Accepted:** 20-Mar-2024

**Published:** 26-Apr-2024

This is an open access journal, and articles are distributed under the terms of the Creative Commons Attribution-NonCommercial-ShareAlike 4.0 License, which allows others to remix, tweak, and build upon the work non-commercially, as long as appropriate credit is given and the new creations are licensed under the identical terms.

**For reprints contact:** WKHLRPMedknow\_reprints@wolterskluwer.com

**DOI:** 10.4103/aian.aian\_998\_23