

CASE REPORT

Open Access



New and old lessons from a devastating case of neonatal *E coli* meningitis

Tawny Saleh¹, Edwin Kamau^{2,3} and Jennifer A. Rathe^{1*}

Abstract

Background Neonatal *Escherichia coli* (*E coli*) meningitis results in significant morbidity and mortality. We present a case of a premature infant with extensive central nervous system (CNS) injury from recurrent *E coli* infection and the non-traditional methods necessary to identify and clear the infection.

Case Presentation The infant was transferred to our institution's pediatric intensive care unit (PICU) after recurrence of *E coli* CNS infection requiring neurosurgical intervention. He had been treated for early onset sepsis (EOS) with ampicillin and gentamicin for 10 days followed by rapid development of ampicillin-resistant *E coli* septic shock and meningitis after discontinuation of antibiotics. Sterility of the CNS was not confirmed at the end of 21 days of cefepime therapy and was subsequently followed by recurrent ampicillin-resistant *E coli* septic shock and CNS infection. Despite 6 weeks of appropriate therapy with sterility of CSF by traditional methods, he suffered from intractable seizures with worsening hydrocephalus. Transferred to our institution, he underwent endoscopic 3rd ventriculostomy with cyst fenestration revealing purulent fluid and significant pleocytosis. An additional 3 weeks of systemic and intraventricular antibiotics with cefepime and tobramycin were given but a significant CNS neutrophil-predominant pleocytosis persisted (average of $\sim 21,000$ cells/mm³). Repeated gram stains, cultures, polymerase chain reaction (PCR) testing, and metagenomic next generation sequencing (NGS) testing of CSF were negative for pathogens but acridine orange stain (AO) revealed numerous intact rod-shaped bacteria. After the addition of ciprofloxacin, sterility and resolution of CSF pleocytosis was finally achieved.

Conclusion Neonatal *E coli* meningitis is a well-known entity but unlike other bacterial infections, it has not proven amenable to shorter, more narrow-spectrum antibiotic courses or limiting invasive procedures such as lumbar punctures. Further, microbiologic techniques to determine CSF sterility suffer from poorly understood limitations leading to premature discontinuation of antibiotics risking further neurologic damage in vulnerable hosts.

Keywords Neonatal *E coli* meningitis, Acridine orange stain, Neonatal sepsis, CSF sterility

*Correspondence:

Jennifer A. Rathe
jrathe@mednet.ucla.edu

¹Department of Pediatrics, Division of Infectious Diseases, David Geffen School of Medicine at UCLA, Los Angeles, CA, USA

²Department of Pathology and Laboratory Medicine, David Geffen School of Medicine at UCLA, Los Angeles, CA, USA

³Present address: Department of Pathology and Area Laboratory Services, Tripler Army Medical Center, Honolulu, HI, USA



© The Author(s) 2024. **Open Access** This article is licensed under a Creative Commons Attribution 4.0 International License, which permits use, sharing, adaptation, distribution and reproduction in any medium or format, as long as you give appropriate credit to the original author(s) and the source, provide a link to the Creative Commons licence, and indicate if changes were made. The images or other third party material in this article are included in the article's Creative Commons licence, unless indicated otherwise in a credit line to the material. If material is not included in the article's Creative Commons licence and your intended use is not permitted by statutory regulation or exceeds the permitted use, you will need to obtain permission directly from the copyright holder. To view a copy of this licence, visit <http://creativecommons.org/licenses/by/4.0/>. The Creative Commons Public Domain Dedication waiver (<http://creativecommons.org/publicdomain/zero/1.0/>) applies to the data made available in this article, unless otherwise stated in a credit line to the data.

Introduction

Neonatal *E coli* sepsis results in high morbidity and mortality due to complex host and environmental factors, but early identification and appropriate treatment limits its progression to meningitis and/or significant parenchymal damage (encephalitis). Recurrence or relapse of CNS infection is a well-recognized entity of neonatal *E coli* meningitis with increased risk associated with the K1 virulence factor and signs of complicated infection (abnormalities on brain imaging: ventriculitis, abscess or clinical signs of CNS infection: seizures or altered mental status). Therefore, repeat LP to document sterility prior to the end of antibiotics has been a longstanding recommendation [1, 2].

Neonatal EOS presents within the first 72 h of life [3]. Late onset sepsis (LOS) presents in the first 4 to 28 days of life. EOS pathogens colonize the infant as they pass through the vaginal canal. Risk of EOS increases with prolonged rupture of membranes and maternal fever or infection. Conversely, LOS pathogens are obtained from the neonates' environment with significantly increased risk of severe infection for very low birthweight premature infants. Group B Streptococcal (GBS) and *E coli* are the most common pathogens responsible for EOS, with *E coli* rates rising, while a variety of gram positive and negative species are responsible for LOS without a particular pathogen predominance [3, 4]. Empiric therapy for EOS is generally ampicillin and gentamicin [3]. If meningitis is a concern, cefotaxime or cefepime are recommended with ampicillin; gentamicin has limited CNS penetration due to its large, hydrophilic nature. Consequently, aminoglycosides can be used as an adjunct but are not reliable as the primary treatment for meningitis [3, 5]. Recommendations for empiric antibiotic therapy for LOS now include a broad-spectrum 3rd or 4th generation cephalosporin +/- vancomycin due to the wide range of causative bacterial organisms and concerns for highly pathogenic gram-negative organisms [3, 6]. However, recommendations for empiric therapy for EOS continue to be ampicillin and gentamicin.

Case presentation

A 3-month-old male born prematurely at 27 weeks gestation was transferred to our institution with recurrent *E coli* CNS infection. He was born via vaginal delivery after premature and prolonged rupture of membranes, with unremarkable prenatal labs. Within 48 h, the neonate became unstable with concern for EOS but blood cultures were negative; he was treated for culture negative sepsis with 10 days of ampicillin and gentamicin.

Within a week after completion of antibiotics, he went into septic shock with ampicillin-resistant *E coli* bacteremia (Fig. 1A) complicated by intractable seizures, grade 3–4 intraventricular hemorrhage (IVH), and respiratory

failure requiring intubation. Lumbar puncture (LP) was not performed secondary to patient instability. Cefepime was administered for 21 days for presumed *E coli* meningitis with some clinical improvement but seizures continued. Brain magnetic resonance imaging (MRI) and serial head ultrasounds were significant for global encephalomalacia and worsening hemorrhage with ventriculomegaly. No LP was performed at the end of therapy.

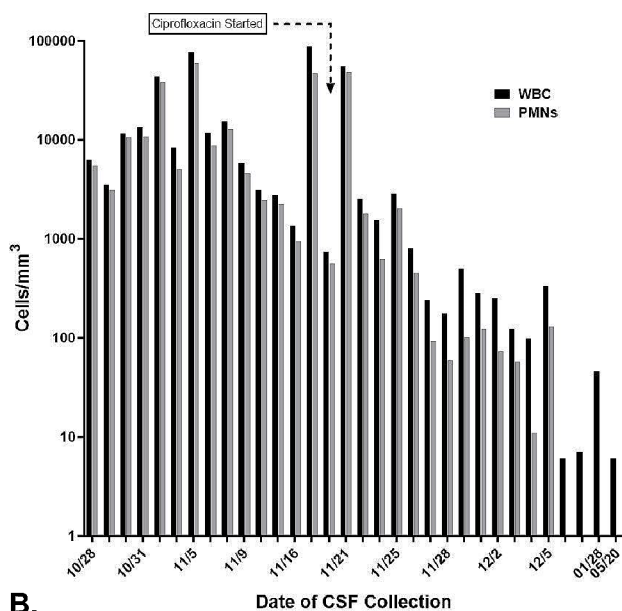
Two weeks after completion of antibiotics, the patient again went into septic shock with ampicillin-resistant *E coli* bacteremia, meningitis, and ventriculitis. He was treated with cefepime and gentamicin. He was diagnosed via a positive blood culture and positive CSF cultures (same sensitivities, Fig. 1A). Two subsequent CSF samples were negative by culture and stain, but were positive via a meningitis nucleic acid PCR panel for *E coli* after 5 and 6 weeks of therapy. Inflammatory markers and clinical signs of sepsis normalized by the 6th week of therapy with the exception of seizures. An MRI revealed multiple heterogeneous cystic structures concerning for hydrocephalus as well as loculated areas consistent with infection and/or hemorrhage. After 8 weeks of antibiotics, he was experiencing increasing hydrocephalus and seizures; he was transferred to our institution for neurosurgical intervention.

Neurosurgery performed an endoscopic 3rd ventriculostomy with cyst fenestration and reservoir placement. The surgeons encountered diffuse, thick, purulent material in the accessible intra-parenchymal and -ventricular cysts. CSF studies demonstrated significant pleocytosis with a high percentage of neutrophils, but gram stain and cultures were negative. Cefepime was continued with the addition of systemic and intraventricular (IT) tobramycin. Despite an aggressive antibiotic regimen for 3 weeks (+8 weeks prior to transfer), serial CSF sampling continued to demonstrate significant neutrophil-predominant pleocytosis (Fig. 1B). However, gram stains and cultures of the CSF remained negative. Further, metagenomic NGS tests performed at University of California San Francisco and 16 S bacterial long-range PCR performed at University of Washington did not detect any pathogenic genomic material. Systemic inflammatory markers were normal and clinical symptoms of infection were absent (Fig. 1C).

It was unclear if the pleocytosis was due to inflammation from significant brain damage or continued *E coli* infection. Brain MRI demonstrated the presence of multiple, non-communicating cysts (Fig. 2A). We hypothesized that cultures were negative not because the CNS was sterile but rather that there were sequestered areas of infection in the non-communicating brain cysts and the instillation of tobramycin may be affecting culture results. The clinical microbiology lab recommended an alternative stain with AO to help visualize any organisms

<i>E coli</i> Blood Culture Primary Infection	Susceptibility	<i>E coli</i> CSF Culture Recurrence	Susceptibility
Ampicillin	Resistant	Ampicillin	Resistant
Ampicillin + Sulbactam	Intermediate	Amikacin	Susceptible
Cefepime	Susceptible	Cefepime	Susceptible
Ceftazidime	Susceptible	Ceftotaxime	Susceptible
Ceftriaxone	Susceptible	Ceftriaxone	Susceptible
Ertapenem	Susceptible	Gentamicin	Susceptible
Gentamicin	Susceptible	Ciprofloxacin	Susceptible
Levofloxacin	Susceptible	Levofloxacin	Susceptible
Piperacillin + Tazobactam	Susceptible	Imipenem	Susceptible
Trimethoprim + Sulfamethoxazole	Resistant	Meropenem	Susceptible
Fungal Blood Culture	Negative	Trimethoprim + Sulfamethoxazole	Resistant
CSF TESTING UCLA	Result (# of tests)	CSF TESTING OUTSIDE HOSPITAL	Result (# of tests)
CSF Stains	Negative x22	CSF Cultures	Positive x2
CSF Cultures	Negative x22	CSF Cultures	Negative x2
UW 16S Bacterial PCR CSF	Negative x2	Meningitis Nucleic Acid PCR Panel	Positive x2 <i>E coli</i> K1
UCSF NGS Sequencing CSF	Negative x2		
CSF AFB Stains and Cultures	Negative x10		
CSF Fungal Cultures and Stains	Negative x10		

A.



B.

INFLAMMATORY MARKERS	10/24	10/28	11/01	11/08	11/15	11/18
Date (Month/Day)	10/24	10/28	11/01	11/08	11/15	11/18
White Blood Cell [cells x10 ⁹ /L]	10.33	9.95	7.6	9.08	5.34	8.46
Platelets [cells x10 ⁹ /L]	400	373	435	570	365	400
C-Reactive Protein [mg/dL]	N/A	N/A	N/A	N/A	<0.3	<0.3
Erythrocyte Sedimentation Rate [mm/hour]	N/A	N/A	N/A	0	0	0
Average Daily Temperature [Celsius]	37.2	36.9	36.7	37.5	37.5	37.5

C.

Fig. 1 Cerebral Spinal Fluid (CSF), Serum, and Clinical Markers of Inflammation. **A:** Culture and susceptibility testing results from blood and CSF samples from the outside hospitals from the first and recurrent episode of *E coli* infection. Culture and testing results from UCLA after transfer. **B:** This graph demonstrates the pleocytosis measured in the CSF over the course of antibiotic treatment during the patient’s admission. Black bars demonstrate the levels of WBCs detected on sampling and the grey bars represent the proportion of those WBCs consisting of neutrophils. The start of ciprofloxacin is shown with a text box and arrow at the top of the graph. Neutrophil predominant CSF pleocytosis resolved after the introduction of ciprofloxacin. **C:** Serum and core temperature measurements of the patient at the time frame concerning for continued infection despite negative CSF gram stain, cultures, bacterial 16 S PCR testing, and unbiased pathogen NGS testing. All testing was negative for signs of systemic inflammation

that might be present. Assessment of several CSF samples with AO found multiple, rod-shaped, intact bacterial organisms (Fig. 2B). None of the associated gram stains, cultures, PCR, nor NGS testing of these samples detected microorganisms. With concern for possible development of antibiotic resistance, a new secondary infection, and improved CNS penetration, we discontinued tobramycin and started ciprofloxacin with continuation of cefepime. Previous cultures demonstrated *E coli* sensitivity to ciprofloxacin (Fig. 1A). Four weeks after the addition of ciprofloxacin, the CSF pleocytosis resolved and AO stains were negative. A ventricular peritoneal shunt was placed, and he has remained infection free for >2 years.

Given his recurrent infection and significant CNS damage, he was evaluated for a primary immune deficiency by Allergy and Immunology; the work up did not identify abnormalities on lymphocyte panel, quantitative immunoglobulins, CH50 testing, TLR function, etc. He is now >2 years old. He has severe global developmental delays: he is blind, he speaks no words, he has mild hearing loss, he cannot support his head, roll over, crawl, nor use his limbs in purposeful movements, and lastly, he startles to sounds but does not respond to his name nor commands.

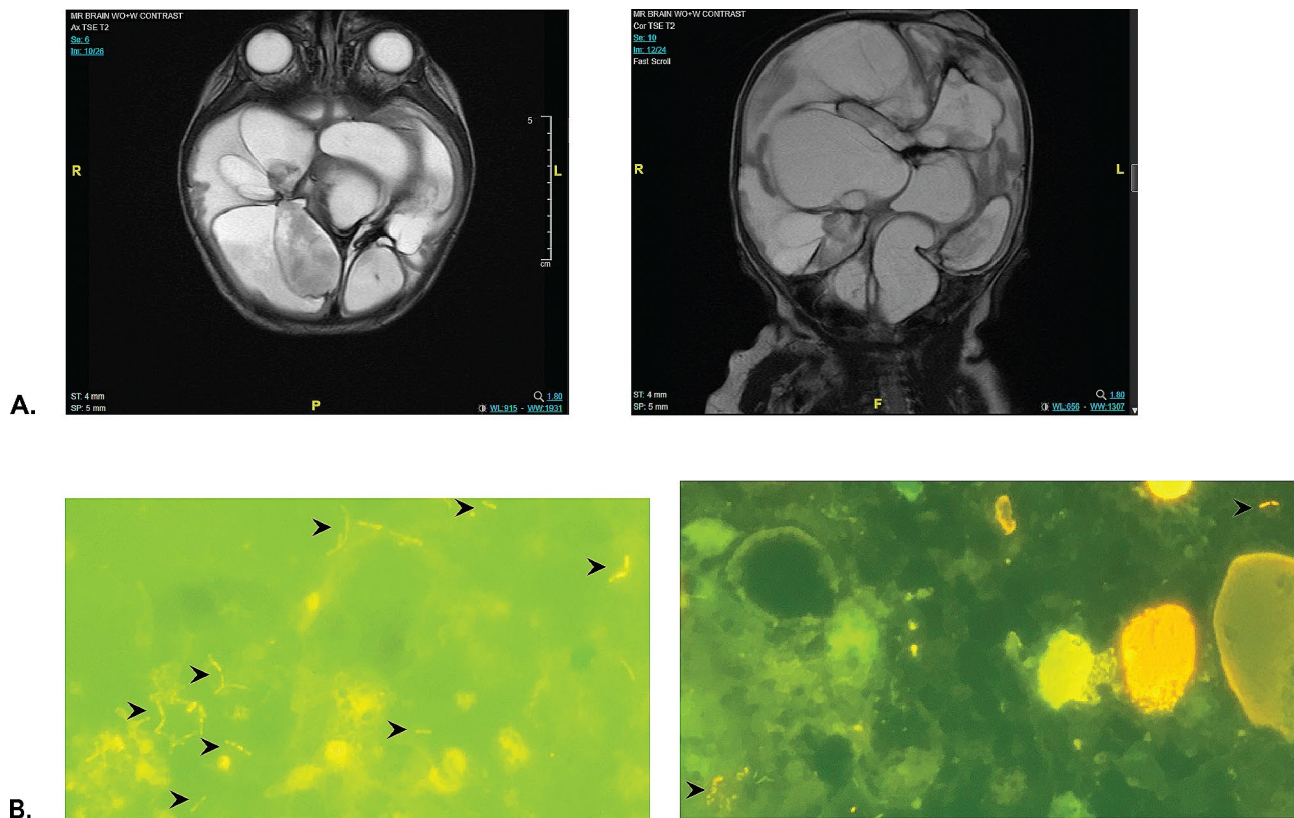


Fig. 2 MRI Brain Imaging and Acridine Orange (AO) Stains of CSF Samples Prior to Ciprofloxacin. **A:** MRI brain imaging of the patient axial and coronal views. Multiple discontinuous fluid filled cysts are noted throughout the brain with minimal remaining brain parenchyma. **B:** Sections of representative microscopic slides of patient's CSF AO stains of two separate CSF collections obtained 1–2 days apart. Black arrows locate the rod-shaped intact organisms. The connected rods are consistent with images of actively dividing organisms such as *E. coli*

Discussion and conclusions

Bacterial meningitis in neonates and infants is a rare occurrence; incidence is estimated at ~ 1 –2% for full term infants and 4–6% for preterm/very low birth-weight neonates [3, 4]. However, EOS and LOS are far more common clinical presentations, especially in pre-term infants, with the risk of progression to meningitis. As appreciated in this case, meningitis in these populations have a high likelihood of resulting in some amount of neurodevelopmental injuries with a range of severity [7, 8]. Our patient experienced EOS and LOS in rapid succession suggesting that both instances resulted from infection with the same ampicillin-resistant *E. coli*. In other words, his EOS was treated with gentamicin alone and may have predisposed to his LOS either because of partially treated *E. coli* CNS infection or as the result of a new infection from translocation of colonizing *E. coli* in his leaky, premature gastrointestinal tract. The high rates of *E. coli* resistance increasing globally raises concerns about the safety of continued empiric use of ampicillin and gentamicin in EOS [9]. However, given the large number needed to treat secondary to the rare incidence of EOS progressing to bacterial meningitis, it is not clear

that the subsequent trade off of increased antibiotic resistance is worth the small number of patients that would benefit from decreased morbidity and mortality. At this time, many argue the change is not warranted and that individual risk assessment and local antibiotic resistance rates are key in the decision to broaden antibiotics in EOS [3, 9].

Neonatal *E. coli* meningitis comes with a risk of recurrence, therefore, a repeat LP to confirm sterilization is recommended. Therapy should be extended if sterilization is not yet achieved at 21 days [10, 11]. In the case presented here, sterilization was not assessed at the initial diagnosis of *E. coli* meningitis nor at the end of therapy when the patient had stabilized. There are times when the decision is made to forgo proof of sterilization but this should only be considered in patients with uncomplicated infection and rapid clinical response to therapy; however, even that scenario is not a guarantee of bacterial clearance when it comes to neonatal *E. coli* meningitis [10]. Unfortunately, our patient had intractable seizures and severe IVH concerning for ongoing infection. A repeat LP may have demonstrated evidence of continued infection resulting in prolongation of antibiotic therapy.

As noted by *Vissing et al.*, neonatal *E coli* meningitis may be one of the clinical scenarios where pushing for shorter antibiotic courses and limiting invasive procedures is not providing benefit but increasing the chance for significant morbidity and mortality [10].

The recurrence of this patient's *E coli* CNS infection resulted in global parenchymal infection with the formation of non-communicating cystic structures. Serially CSF sampling demonstrated notable pleocytosis and purulent fluid but bacterial gram stain and culture failed to detect organisms. PCR and NGS also failed to identify bacterial pathogens despite visual evidence on acridine orange stain of numerous, intact, rod-shaped bacteria. Due to extensive systemic and IV antibiotics, it is not surprising that the cultures were no growth. However, it was unexpected that serial CSF Gram stains, NGS, and PCR did not detect bacteria. No test is 100% sensitive and specific and all are subject to specific limitations. AO actually has a higher sensitivity compared to Gram stain but is not able to differentiate between gram-positive and -negative organisms, and is not used in the regular clinical microbiology workflow for CSF samples [12, 13]. However, unknown to many physicians, the newer NGS and PCR diagnostic techniques are not reliable in detecting pathogens when using samples with high numbers of inhibitory materials and cells present, i.e. pleocytosis [14, 15].

The addition of ciprofloxacin resulted in resolution of the CNS pleocytosis and bacterial rods on AO stain. Adjunct ciprofloxacin for neonatal *E coli* meningitis has been proposed for many years by some experts in France. However, there is not clear data demonstrating ciprofloxacin superiority to aminoglycosides or cephalosporins [16]. But, in this particular patient it may have provided improved bactericidal killing secondary to higher sensitivity or better CNS penetration compared to our initial regimen [17]. As the bacteria detected on AO did not grow in culture, we could not assess for the development of resistance after prolonged treatment with cefepime and aminoglycosides.

The infant presented here suffered severe consequences from recurrent, neonatal *E coli* CNS infection resulting in destruction of most of his brain parenchyma. Uncontrollable risk factors contributing to his poor outcome include his prematurity and infection with an *E coli* K1 strain. Premature infants even without CNS infection have a greater risk of long-term consequences [18]. K1 is a virulence factor that increases the ability of the bacteria to cross the blood brain barrier. However, initial treatment with cefepime rather than ampicillin and a repeat LP prior to stopping antibiotics may have altered the ultimate outcome of his infection. This case also illustrates the importance of understanding the limitations of classic sterilization testing as well as newer technologies.

Identification of bacteria on AO stain stopped us from discontinuation of antibiotics prior to attaining true sterilization. The addition of ciprofloxacin allowed us to achieve sterilization in this patient though it is not entirely clear as to why it was successful. Key lessons from this patient include: (1) the use of AO stain when there are signs of continued infection despite negative GS and culture (2), always plan to repeat LPs to document sterilization in neonatal *E coli* meningitis unless the patient is clinically unstable, and (3) if patients are not clearing their CSF or have continued signs of clinical infection despite cefepime +/- an aminoglycoside, adjunct therapy with ciprofloxacin should be considered.

Abbreviations

E coli	Escherichia coli
CNS	Central nervous system
PCR	Polymerase chain reaction
PICU	Pediatric intensive care unit
EOS	Early onset sepsis
LOS	Late onset sepsis
CSF	Cerebral spinal fluid
IVH	Intraventricular hemorrhage
LP	Lumbar puncture
IT	Intraventricular
MRI	Magnetic resonance imaging
NGS	Next-Generation sequencing
AO	Acridine orange
GBS	Group B Streptococcus

Acknowledgements

Not applicable.

Author contributions

TS, EK, and JR conceptualized the manuscript. TS reviewed literature and wrote the original draft. EK, TS, and JR edited the manuscript. TS and JR provided pediatrics infectious disease care and clinical decision making. EK created and provided images of the acridine orange stains in the microbiology lab. JR supervised the entire process of from development to submission of the manuscript.

Funding

No grants were used to fund the preparation of this manuscript.

Data availability

The data presented in this report are available upon request from the corresponding author.

Declarations

Ethics approval and consent to participate

Not applicable.

Consent for publication

Verbal and written informed consent were obtained from the parents of the patient for publication of the text and images of this case report. A copy of the written consent is available upon request.

Competing interests

The authors declare no competing interests.

Received: 30 June 2023 / Accepted: 23 April 2024

Published online: 16 May 2024

References

1. Vissing NH, Mønster MB, Nordly S, Dayani GK, Heedegaard SS, Knudsen JD et al. Relapse of neonatal *Escherichia coli* Meningitis: did we Miss something at First? *Child (Basel)*. 2021;8(2).
2. Cherry JD, Harrison GJ, Kaplan SL, Steinbach WJ, Hotez PJ. Feigin and Cherry's textbook of pediatric infectious diseases. Philadelphia, PA: Elsevier; 2019.
3. Stoll BJ, Puopolo KM, Hansen NI, Sánchez PJ, Bell EF, Carlo WA, et al. Early-Onset neonatal Sepsis 2015 to 2017, the rise of *Escherichia coli*, and the need for Novel Prevention Strategies. *JAMA Pediatr*. 2020;174(7):e200593.
4. Gowda H, Norton R, White A, Kandasamy Y. Late-onset neonatal Sepsis-A 10-year review from North Queensland, Australia. *Pediatr Infect Dis J*. 2017;36(9):883–8.
5. Sullins AK, Abdel-Rahman SM. Pharmacokinetics of antibacterial agents in the CSF of children and adolescents. *Paediatr Drugs*. 2013;15(2):93–117.
6. Ellis JM, Rivera L, Reyes G, Castillo F, Marte P, Tejada M, et al. Cefepime cerebrospinal fluid concentrations in neonatal bacterial meningitis. *Ann Pharmacother*. 2007;41(5):900–1.
7. Flannery DD, Edwards EM, Coggins SA, Horbar JD, Puopolo KM. Late-Onset Sepsis among very Preterm infants. *Pediatrics*. 2022;150(6).
8. Thomas R, Bijlsma MW, Gonçalves BP, Nakwa FL, Velaphi S, Heath PT. Long-term impact of serious neonatal bacterial infections on neurodevelopment. *Clin Microbiol Infect*. 2023.
9. Liu Y, Zhu M, Fu X, Cai J, Chen S, Lin Y, et al. Causing neonatal Meningitis during 2001–2020: a study in Eastern China. *Int J Gen Med*. 2021;14:3007–16.
10. Vissing NH, Mønster MB, Nordly S, Dayani GK, Heedegaard SS, Knudsen JD et al. Relapse Neonatal *Child (Basel)*. 2021;8(2).
11. Mulder CJ, van Alphen L, Zanen HC. Neonatal meningitis caused by *Escherichia coli* in the Netherlands. *J Infect Dis*. 1984;150(6):935–40.
12. Sharma S, Acharya J, Banjara MR, Ghimire P, Singh A. Comparison of acridine orange fluorescent microscopy and gram stain light microscopy for the rapid detection of bacteria in cerebrospinal fluid. *BMC Res Notes*. 2020;13(1):29.
13. Lauer BA, Reller LB, Mirrett S. Comparison of acridine orange and Gram stains for detection of microorganisms in cerebrospinal fluid and other clinical specimens. *J Clin Microbiol*. 1981;14(2):201–5.
14. Oechslin CP, Lenz N, Liechti N, Ryter S, Agyeman P, Bruggmann R, et al. Limited Correlation of Shotgun Metagenomics Following Host Depletion and Routine Diagnostics for Viruses and Bacteria in low concentrated surrogate and clinical samples. *Front Cell Infect Microbiol*. 2018;8:375.
15. Hasan MR, Rawat A, Tang P, Jithesh PV, Thomas E, Tan R, et al. Depletion of human DNA in spiked clinical specimens for improvement of sensitivity of Pathogen Detection by Next-Generation sequencing. *J Clin Microbiol*. 2016;54(4):919–27.
16. Sáez-Llorens X, Castaño E, García R, Báez C, Pérez M, Tejeira F, et al. Prospective randomized comparison of cefepime and cefotaxime for treatment of bacterial meningitis in infants and children. *Antimicrob Agents Chemother*. 1995;39(4):937–40.
17. Lipman J, Allworth A, Wallis SC. Cerebrospinal fluid penetration of high doses of intravenous ciprofloxacin in meningitis. *Clin Infect Dis*. 2000;31(5):1131–3.
18. Morniroli D, Tiraferri V, Maiocco G, De Rose DU, Cresi F, Coscia A, et al. Beyond survival: the lasting effects of premature birth. *Front Pediatr*. 2023;11:1213243.

Publisher's Note

Springer Nature remains neutral with regard to jurisdictional claims in published maps and institutional affiliations.