

Successful surgical management of cardiac tamponade following direct intrahepatic portosystemic shunt in a child with Budd–Chiari syndrome: A potentially life-threatening situation

Anand Kumar Mishra¹, Meenakshi Mandal¹, Irshad R. Mohamed¹, Sadhna Lal², Harish Bhujade³

¹Department of Cardiothoracic and Vascular Surgery, Postgraduate Institute of Medical Education and Research, Chandigarh, India, ²Department of Gastroenterology, Postgraduate Institute of Medical Education and Research, Chandigarh, India, ³Department of Radiodiagnosis, Postgraduate Institute of Medical Education and Research, Chandigarh, India

ABSTRACT

Direct intrahepatic portosystemic shunt is a technique of portocaval shunting performed through the percutaneous route in patients with Budd–Chiari syndrome. Stent migration into right-sided heart chambers or perforations causing hemopericardium and cardiac tamponade is rare and underreported. In a child with a coexisting decompensated liver disease, surgical intervention and cardiopulmonary bypass can be challenging. However, surgical management in these life-threatening situations is better than redo interventions.

Keywords: Cardiac tamponade, cardiopulmonary bypass, direct intrahepatic portosystemic shunts, intervention complications

INTRODUCTION

Direct intrahepatic portosystemic shunt (DIPS) is a percutaneous technique of creating a portocaval shunt, from the portal vein to the inferior vena cava (IVC) through the intraparenchymal route. It has been established to be a safe procedure in patients with Budd–Chiari syndrome (BCS) with portal hypertension. It is coming up as an alternative to transjugular intrahepatic portosystemic shunt (TIPS) in pediatric patients and BCS. Stent migration is a known complication after deployment of portocaval shunts, with covered stents more likely to migrate than bare stents.^[1] Migration into right-sided heart chambers or perforations causing hemopericardium and cardiac tamponade are rare and underreported.^[1]

to the hospital with fever and abdominal distension. On examination, the child had a distended abdomen with dilated veins and firm hepatomegaly. Doppler ultrasonography revealed hepatic vein outflow tract obstruction and acute portal vein thrombosis with portal hypertension, suggestive of BCS. Contrast-enhanced computed tomography (CECT) abdomen showed nonvisualization of hepatic veins and intrahepatic IVC, with heterogenous liver attenuation suggestive of hepatic vein outflow obstruction. She was started on intravenous antibiotics, subcutaneous low-molecular-weight heparin, and diuretics. However, her symptoms failed to respond to medical treatment. She was planned for portocaval shunt procedure and percutaneous intervention was chosen over surgical shunt. The patient was taken

CASE REPORT

We are presenting a 2-year-old girl who had presented

This is an open access journal, and articles are distributed under the terms of the Creative Commons Attribution-NonCommercial-ShareAlike 4.0 License, which allows others to remix, tweak, and build upon the work non-commercially, as long as appropriate credit is given and the new creations are licensed under the identical terms.

For reprints contact: WKHLRPMedknow_reprints@wolterskluwer.com

How to cite this article: Mishra AK, Mandal M, Mohamed IR, Lal S, Bhujade H. Successful surgical management of cardiac tamponade following direct intrahepatic portosystemic shunt in a child with Budd–Chiari syndrome: A potentially life-threatening situation. *Ann Pediatr Card* 2023;16:370-3.

Access this article online

Quick Response Code:



Website:

<https://journals.lww.com/aopc>

DOI:

10.4103/apc.apc_107_23

Address for correspondence: Dr. Meenakshi Mandal, Department of Cardiothoracic and Vascular Surgery, Level-4, Advanced Cardiac Centre, Postgraduate Institute of Medical Education and Research, Chandigarh - 160 012, India.

E-mail: dr.meenakshimandal@gmail.com

Submitted: 05-Jul-2023

Revised: 12-Sep-2023

Accepted: 06-Jan-2024

Published: 01-Apr-2024

up for DIPS. The IVC was approached through the transjugular route, and through the intraparenchymal route in the liver, the portal vein was punctured. A bare metal stent was deployed in the portal vein. During the stent deployment, the patient had hemodynamic collapse requiring cardiopulmonary resuscitation. On table-venous angiography revealed a rent in the IVC and extravasation into the pericardial cavity. A covered stent occluding the rent site was immediately deployed and hemorrhage was controlled. This covered stent was placed within the previous stent and extended more cephalad from the uncovered stent, through the liver parenchyma into the IVC. The hemopericardium was drained using a pigtail catheter, which was removed after 2 days. The patient was discharged in a hemodynamically stable state. On the 2nd week of follow-up, a routine Doppler scan revealed stent occlusion. She underwent percutaneous catheter-guided thrombolysis and angioplasty. Four weeks later, the patient presented to the emergency with complaints of shortness of breath and cough. On examination, heart sounds were muffled, and normal breath sounds were heard. Chest X-ray revealed cardiomegaly with two stents *in situ*, reaching up to the right atrium [Figure 1a]. Transthoracic two-dimensional echocardiography revealed massive pericardial effusion causing cardiac tamponade, collection of 38 mm on the left ventricular side, and 20 mm on the right ventricular (RV) side with RV diastolic and right atrial (RA) systolic collapse. Emergency cardiac CECT was obtained to look for any rent in IVC, any active contrast extravasation, and the location of the portocaval shunt stents [Figure 1b]. The CECT scan revealed a massive hemopericardium without any active contrast extravasation. The cephalad-placed stent had migrated into the right atrium.

Cardiac surgical consultation was sought, and the patient was decided to be taken up for emergency surgery through midline sternotomy for relief of cardiac tamponade and retrieval of the stent from RA

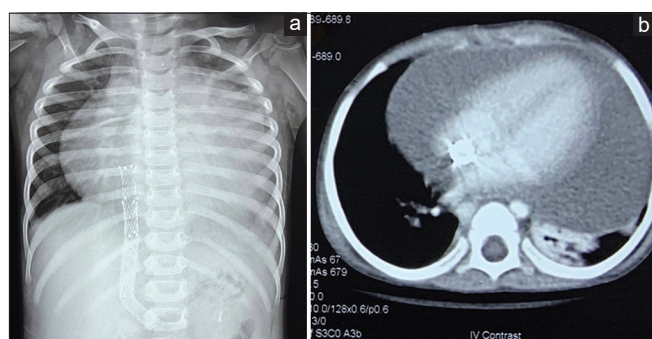


Figure 1: (a) Chest X-ray showing cardiomegaly. Direct intrahepatic portosystemic shunt protruding via inferior vena cava (IVC) into right atrial is noted. (b) Contrast-enhanced computed tomography scan showing massive pericardial effusion (max thickness 3.8 mm). Note the proximal end of IVC stent extending into right atrium

under cardiopulmonary bypass (CPB). On opening the pericardium, altered blood and clots were evacuated. After aortobicaval cannulation and the institution of CPB, IVC was noted to be markedly adhered to the surrounding pericardium. The tip of the stent was protruding through the RA wall into the pericardial cavity, with dense adhesions surrounding it [Figure 2a]. The cardioplegic arrest was achieved using del Nido cardioplegia at the dose of 30 mL/kg. The patient was cooled up to 28°C. Following cardioplegic arrest, RA was opened, and the stent was seen protruding into its cavity from the IVC [Figure 2b]. The IVC cannula was removed after reducing circuit flows to 50% using only the superior vena cava cannula for CPB support. In-stent thrombus was noted. After adhesiolysis and separating the stent from the cardiac walls, it was seen lying on the previous IVC rent site. Intermittent short-duration total circulatory arrest (TCA) was used for complete removal of thrombus and stent extraction [Figure 2c and d]. Total TCA duration was 5 min. A length of 1.5 cm of the stent was cutoff thus explanting the intracardiac part of the stent, leaving behind the IVC portion. The IVC rent site was repaired with polypropylene 5-0 continuous sutures. The patient was rewarmed. The RA was closed in two layers and a thorough pericardial lavage was done. The patient was then weaned off CPB, decannulated, and shifted to cardiac surgical intensive care unit. Her postoperative course remained uneventful, and she was discharged. She has been on routine follow-up for 1 year with no current cardiac issues.

DISCUSSION AND CONCLUSION

Patients with BCS have elevated portal pressures leading to intractable ascites and variceal bleeds.^[2] Portosystemic shunting is done to decompress the portal vein and alleviate the symptoms. TIPS is a commonly done procedure. However, due to the technical difficulty and potential pathoanatomic findings in liver cirrhosis, the

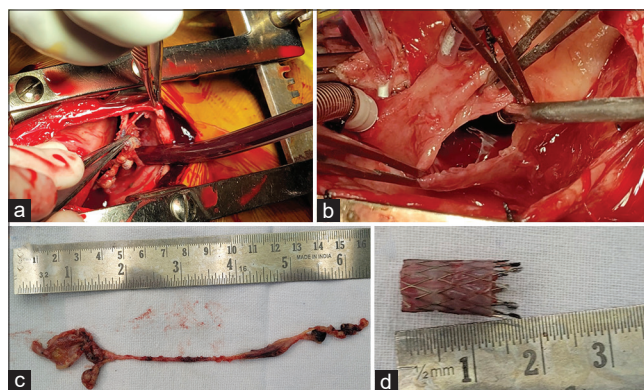


Figure 2: (a) Dense adhesions of right atrium with surrounding pericardium at the inferior vena cava site. (b) Right atriotomy showing stent with sharp edges inside the right atrial. (c) In-stent clot retrieved. (d) Extracted stent of length 1.5 cm

creation of TIPS is not always successful. In 2001, an endovascular alternative, called DIPS, was published by Petersen and Binkert^[3] It has been reported as a feasible and safe endovascular alternative to TIPS insertion.^[4] The original DIPS technique described by Peterson *et al.* involved the use of endovascular ultrasound to guide the puncture site of the portal vein and for the introduction of guide wire. Following numerous modifications to this technique, a percutaneous technique to approach the portal vein has been widely accepted.^[3] They have been reported to be more feasible, faster, and have comparable patency rates to the original ultrasound-guided DIPS.

However, the lack of experience of interventional radiologists stems from the technically challenging nature of the procedure and vice-versa.^[5] Moreover, the experience of the interventional portosystemic shunts in children is limited.^[6]

The potential complications associated with any interventional portosystemic shunt include acute liver failure, hepatic encephalopathy, hemorrhage, biliary injury, injury to surrounding organs, stent thrombosis, stent dysfunction, and stent migration.^[7] Although embolization into the right heart structures has been reported,^[8] injuries to the IVC and cardiac structures are rare.^[9] These life-threatening complications can be tackled with timely surgical intervention.

Management of these complications is challenging given the previously decompensated liver disease. Percutaneous retrieval of migrated stents is usually unsuccessful and surgical retrieval is advocated.^[10] Te *et al.*^[11] reported a case of surgical retrieval along with a combined liver transplant in a 62-year-old patient awaiting transplant. In 2022, Xiong *et al.*^[12] reported a case of a fractured segment of stent falling into the right ventricle causing severe tricuspid regurgitation. During the surgery, stent fragments were found to be tightly attached to the posterior leaflet of the tricuspid valve and the RV trabeculae. The stent fragments were retrieved, and tricuspid valve replacement was done.

Our patient developed acute hemopericardium and cardiac tamponade with cardiovascular collapse on the table during stent placement. She was managed by deploying another stent over the stent by the interventional radiology team. Although the hemopericardium resolved after drainage and the patient's cardiovascular status stabilized, the possibility of an ongoing leak could not have been ruled out. Further, interventions done after 2 weeks for stent blockage could have also caused iatrogenic injury or trauma.

DIPS is a technically challenging procedure, associated with life-threatening complications. The technical limitations in the pediatric population, the long learning curve, and its potential to cause fatal complications must be understood

by the intervention radiologists. In addition, multiple interventional procedures done through the same route increase the risk of iatrogenic trauma and must be kept in mind while following up with these patients. In our case, timely surgical intervention to repair the IVC rent and retrieval of the migrated stent could have avoided cardiovascular decompensation in this child.

Hence, we suggest that these life-threatening complications must be meticulously addressed by multi-disciplinary team with adequate infrastructure available under one roof. Postcomplication surgical assessment and follow-up evaluation in the form of contrast-enhanced cardiac computed tomography or echocardiography are advisable.

Declaration of patient consent

The authors certify that they have obtained all appropriate patient consent forms. In the form, the legal guardian has given his consent for images and other clinical information to be reported in the journal. The guardian understands that names and initials will not be published and due efforts will be made to conceal the identity, but anonymity cannot be guaranteed.

Financial support and sponsorship

Nil.

Conflicts of interest

There are no conflicts of interest.

REFERENCES

1. Gaba RC, Khiatani VL, Knuttinen MG, Omene BO, Carrillo TC, Bui JT, *et al.* Comprehensive review of TIPS technical complications and how to avoid them. *AJR Am J Roentgenol* 2011;196:675-85.
2. El Ray A, Azab MM, El-Aziz IM, El-Aleem AA, El-Talkawy MD, El-Badea MA, *et al.* Non-invasive predictors for the presence, grade and risk of bleeding from esophageal varices in patients with post-hepatic cirrhosis. *J Egypt Soc Parasitol* 2015;45:421-8.
3. Petersen B, Binkert C. Intravascular ultrasound-guided direct intrahepatic portacaval shunt: Midterm follow-up. *J Vasc Interv Radiol* 2004;15:927-38.
4. Mostafa K, Trentmann J, Andersson J, Günther R, Braun F, Schäfer PJ. Percutaneous creation of direct intrahepatic portosystemic shunts - An alternative for failed TIPS creation. *CVIR Endovasc* 2022;5:16.
5. Artru F, Moschouri E, Denys A. Direct intrahepatic portocaval shunt (DIPS) or transjugular transcaval intrahepatic portosystemic shunt (TTIPS) to treat complications of portal hypertension: Indications, technique, and outcomes beyond Budd-Chiari syndrome. *Clin Res Hepatol Gastroenterol* 2022;46:101858.
6. Shin D, Shivaram G, Koo K, Monroe E. Pediatric transjugular intrahepatic portosystemic shunts. *Dig Dis Interv* 2017;1:277-85.

7. Suhocki PV, Lungren MP, Kapoor B, Kim CY. Transjugular intrahepatic portosystemic shunt complications: Prevention and management. *Semin Intervent Radiol* 2015;32:123-32.
8. White A. A fatal complication. *Acupunct Med* 1995;13:119.
9. Hayashi PH, Mao J, Slater K, Liao R, Durham JD, Carroll J, *et al.* Atrial septal perforation from TIPS stent migration. *J Vasc Interv Radiol* 2004;15:629-32.
10. Fehervari I, Szonyi L, Fazakas J, Gerlei Z, Lazar I. TIPS stent migration into the heart with 6-year follow-up. *Ann Transplant* 2011;16:109-12.
11. Te HS, Jeevanandam V, Millis JM, Cronin DC, Baker AL. Open cardiectomy for removal of migrating transjugular intrahepatic portosystemic shunt stent combined with liver transplantation. *Transplantation* 2001;71:1000-3.
12. Xiong F, Tan K, Cheng L, Luo Y, Zhao Z. A rare case of severe tricuspid regurgitation caused by detached stent falling into the right ventricle after transjugular intrahepatic portosystemic shunt. *J Cardiothorac Surg* 2022;17:42.