

Original Article

Diosmin protects the testicles from doxorubicin-induced damage by increasing steroidogenesis and suppressing oxido-inflammation and apoptotic mediators

Mega O Oyowwi^{1,2}, Benneth Ben-Azu³, Edesiri P Tesi⁴, Abodunrin A Ojetola¹, Temitope G Olowe⁵, Uchechukwu G Joseph⁶, Victor Emojevwe⁵, Onome B Oghenetega⁷, Rume A Rotu⁸, Rotu A Rotu⁹, Faith Y Falajiki¹

¹Department of Physiology, Adeleke University, Ede, Osun State, Nigeria; ²Department of Hunan Physiology, Achievers University, Owo, Ondo State, Nigeria; ³DELSU Joint Canada-Israel Neuroscience and Biopsychiatry, Department of Pharmacology, Faculty of Basic Medical Sciences, Delta State University, Abraka, Delta State, Nigeria; ⁴Department of Science Laboratory Technology, Delta State Polytechnic, Ogwashi-Uku, Delta State, Nigeria; ⁵Department of Physiology, University of Medical Sciences, Ondo, Ondo State, Nigeria; ⁶Department of Medical Laboratory Science, Adeleke University, Ede, Osun State, Nigeria; ⁷Department of Physiology, School of Basic Medical Science, Babcock University, Illisan, Ogun State, Nigeria; ⁸Department of Physiology, Faculty of Basic Medical Science, College of Health Sciences, University of Ibadan, Ibadan, Oyo State, Nigeria; ⁹Department of Industrial Safety and Environmental Management, School of Maritime Technology, Burutu, Delta State, Nigeria

Received September 17, 2023; Accepted April 15, 2024; Epub April 15, 2024; Published April 30, 2024

Abstract: Background: Cancer chemotherapy with doxorubicin (DOX) has been linked to serious testicular damage and spermatotoxicity due to the induction of oxidative stress, inflammation, and apoptosis. Thus, the current study was carried out to assess the potential ameliorative impact of diosmin, an antioxidant drug, against DOX-mediated spermatotoxicity and testicular injury in rats. Material and Methods: In the experimental protocol, rats were grouped into 4: Group 1 received vehicle and saline for 8 weeks while group 2 received diosmin and saline concomitantly for 8 weeks. Group 3 was given 3 mg/kg intraperitoneal DOX once every 7 days for 8 weeks. Group 4 was given 40 mg/kg of diosmin orally for 56 days followed by DOX diosmin administration after one hour. After 56 days of treatment, sperm quality, hormonal testing, biochemical parameters, and histological alterations in the testes were evaluated. Results: DOX-induced reduce spermatogenic function, testicular 3- and 17 β -Hydroxysteroid dehydrogenases, and serum follicle stimulating hormone, luteinizing hormone, and testosterone. It also enhanced inflammation, testicular oxidative damage, and apoptosis. The histopathologic examinations corroborated the biochemical results obtained. Significantly, diosmin treatment reduced DOX-induced injury, as evidenced by restored testicular architecture, increased steroidogenesis, preservation of spermatogenesis, suppression of oxide-inflammatory response, and apoptosis. Conclusion: It was found that through diosmin antioxidant, anti-apoptotic, and anti-oxido-inflammatory it presents a possible therapeutic alternative for protecting testicular tissue against DOX's harmful effects.

Keywords: Gonadotoxicity, diosmin, doxorubicin, inflammation, oxidative stress, spermatotoxicity, apoptosis

Introduction

Doxorubicin (DOX), commonly known as Adriamycin, is an antibiotic and anti-cancer agent with harmful effects on human fertility and reproductive health. DOX treatment has been associated with gonadal damage, resulting in male reproductive deficiency [1, 2]. DOX administration promotes a decrease in testicular spermatogenic cells, resulting in long-term damage to sperm cells and increased testicular

oxidative stress [2-5]. DOX's major target in the testes is spermatogonia, resulting in gonadal destruction [6, 7]. In rats, DOX therapy is associated with severe damage including early spermatocyte breakdown, decreased spermatogonia, sperm motility, with reduced epididymal and sperm count and alteration of pituitary-gonadal (HPG) axis hormones [8-10]. Additionally, DOX affects testicular lipid metabolism, allowing for changes in neutral lipids, glycopospholipids, and sphingolipids [11-14],

Reproductive protective property of diosmin

and dysregulation of 17β -hydroxysteroid dehydrogenase (17β -HSD) and 3β -hydroxysteroid dehydrogenase (3β -HSD) [10, 14, 15]. Previous studies have also shown that DOX induces male reproductive failure via increased oxidative and endoplasmic reticulum stress by aggravating oxygen radical-induced lipid breakdown in membranes [9, 10, 16]. Of note, administration of DOX decreases the levels of antioxidant enzymes such as catalase, glutathione peroxidase, and superoxide dismutase [10], however, these were reversed by antioxidant supplementation [10].

Natural antioxidants such as diosmin, have gained significant interest due to its potential curative effects against various diseases. Diosmin is an unsaturated flavone glycoside found in citrus fruits [17, 18]. Diosmin is a semi-synthetic medicine used to treat varicose veins and venous insufficiency. Studies have shown that diosmin inhibits oxido-inflammatory processes [17, 18]. Additionally, diosmin is known for its anti-cancer, anti-diabetic [16], lung-protective [16], and renoprotective [17] effects. In terms of neuroprotective effects, diosmin inhibits ketamine- and lipopolysaccharide (LPS)-elevated levels of acetylcholinesterase activity, nitroergic stress and lipid peroxidation [19, 20]. Diosmin also reduces the release of pro-inflammatory enzymes such as myeloperoxidase and cytokines, notably tumor necrosis factor-alpha (TNF- α) and interleukin-6 (IL-6) in the striatum, prefrontal cortex, and hippocampus in LPS exacerbated ketamine-induced experimental psychosis [20]. Additionally, through its antioxidant and antiapoptotic properties, diosmin attenuates numerous reproductive organ damage caused by cisplatin via inhibition of caspase-3 and Bax expressions with increased levels of Bcl-2, CD44 and Ki67 in the prostate and seminal vesicles [21]. Hence, this study investigated the potential protective benefits of diosmin against DOX-induced reproductive impairment in male rats.

Materials and methods

Drug and chemicals

Drugs (DOX, DIOS) and oral vehicle (carboxymethyl cellulose, CMC) were procured from Sigma-Aldrich, with high-quality analytical substances used. Doses of DOX and diosmin were

selected according to the previous findings [10] and [22] respectively.

Animals

The study was carried out with 20 male Wistar rats aged 8-10 weeks at Achievers University in Owo, Ondo State. They were housed in steel cages with 12-hour light/dark cycles and standard temperature, with unrestricted access to food and salt water. The experimental procedures were in accordance with ARRIVE standards and the National Institutes of Health Standards of Animal Care and Experimentation Protocol.

Experimental protocol

Rats were separated into 4 different groups ($n = 5$ /group). Group 1 served as vehicular group and received solvent [0.5% CMC (1 mL/animal p.o.) and saline (1 mL/animal, i.p.)] for 56 days, group 2 received diosmin (40 mg/kg, p.o.) and a concomitant dose of saline (1 mL/kg, p.o.) for 56 days, group 3 received weekly doses of DOX intraperitoneally (3 mg/kg) on days 7, 14, 21, 28, 35, 42, 49 and 56 of the experiment. However, group 4 received diosmin (40 mg/kg p.o.) for 56 days and DOX was administered 1 h after diosmin (40 mg/kg, p.o.) administration, commencing at an interval of 7 days (i.e. 7th, 14th, 21st, 28th, 35th, 42nd, 49th and 56th). The whole experiment lasted for 56 days.

Tissue collection and preparation

To avoid noticeable chemical changes, the treated rats were euthanized under low-level ether anesthesia 24 h after the last dosage of the 56-day treatment. Each rat's blood was thereafter extracted via the retro-orbital sinus into a plain bottle. To extract plasma samples, the blood samples were centrifuged for 10 min at 3000 rpm. The plasma samples were stored frozen at -20°C after the hormone tests were performed using an ELISA reader (Robonik India Private Limited, Mumbai, India). Furthermore, the testes and cauda epididymis were extracted, cleared of any fat or connective tissues that clung to them, and weighed. Each animal's cauda epididymis was utilized to measure the sperm parameters (count, motility, viability, and morphology). Additionally, one testis was homogenized for 10 min at 4°C in a

Reproductive protective property of diosmin

radioimmunoprecipitation assay buffer that contained 150 mM NaCl, 1 mM EDTA, 10 g/mL phenylmethylsulfonyl fluoride, 1 percent Triton X-100, and 20 mM Tris-HCl, pH 7.4. The supernatants were then collected and kept at 20°C until they were required for biochemical assays. For histological analysis, the second testis was maintained in Bouin's fluid.

Sperm characterization

The study examined the rats' caudal epididymis and sperm motility using a hemocytometer. Sperm count was calculated using Czubaszek et al.'s [23] method, and sperm morphology was assessed using aniline blue staining. Epididymal volume was identified by displaced volume past the epididymis [24]. DSP was measured in adult rats by homogenizing testes in 0.9% sodium chloride solution and counting the resulting aliquot under a 40× objective light microscope [25].

Sperm acrosomal reaction assessment

The Coomassie Brilliant Blue (CBB) staining procedure was used to measure sperm acrosomal condition by fixing, air drying, and soaking samples in a 5% paraformaldehyde solution. Undamaged sperm shows blue staining, while untreated sperm shows no staining [26].

Sperm chromatin integrity determination

Dried smears were fixed in 96% ethanol and acetic acid (1:1) for 30 min, and then hydrolyzed with 0.1 N, HCl for 5 min in 4°C. The slides were washed with distilled water 3 times for 2 min and stained with 0.05% toluidine blue (TB) for 5 min. Sperms with light blue heads were normal with good DNA integrity, while those with dark heads (purple) were abnormal with poor DNA integrity [27].

Hypo-osmotic swelling test (HOST)

HOST was carried out following established methods [28]. The hypo-osmotic solution was prepared by the addition of 0.735 g of sodium citrate dehydrate and 1.351 g of fructose in 100 mL of distilled water. Approximately 0.1 mL of well-mixed epididymal sperm suspension was added to 1 mL of the hypo-osmotic solution. The sperm suspension reaction mixture was mixed and then incubated at 37°C for

30-60 min. After incubation, a drop of the mixture was placed on a glass slide and covered with a clean coverslip. The slide was viewed under ×40 lens to observe sperm tail swelling. Sperm with swollen tails (normal spermatozoa) were regarded as HOST Positive/reactive, while those without swollen tails (abnormal spermatozoa) were regarded as HOST negative. One hundred sperm cells were counted from which the percentage of HOST positive cells was determined.

Hormone assays

The sample's levels of FSH, LH, and testosterone were measured using the ELISA technique. This was completed in accordance with the manufacturer's instructions (Enzo Life Sciences, San Diego, CA).

Testicular androgenic enzymes assessment

The concentrations of reproductive hormones (follicle stimulating hormone (FSH), luteinizing hormone (LH) and testosterone) were determined using standard laboratory enzyme-linked immunosorbent assay (ELISA) kits obtained from BioVision, Inc. These assays were completed in accordance to the manufacturers' instructions. The activities of 3β-HSD and 17β-HSD were measured by the methods earlier described by Oyovwi et al. [15]. The reaction mixture in a volume of 2.0 mL contained 100 μmol of sodium pyrophosphate buffer (pH 9.0) and 0.5 μmol cofactor NAD for 3β-HSD and NADPH for 17β-HSD, 0.08 μmol of substrate (dehydroepiandrosterone for 3β-HSD and androstenedione for 17β-HSD) and 100 μL of testicular protein. The reactions were carried out in a quartz cuvette of 1.0 cm path length at 23±1°C. The absorbance at 340 nm was measured at 20 s intervals for 3 min in a UV-Vis spectrophotometer (UV-1700 Shimadzu, Japan). The enzyme activities were expressed as nmol of NAD converted to NADH/min/mg protein (3β-HSD) or nmol of NADPH converted to NADP/min/mg protein (17β-HSD).

Assessment of oxidative stress marker and antioxidant enzyme concentrations

Lipid peroxidation [29], glutathione concentration, superoxide dismutase activity [30], and catalase [31] levels were measured in tissue samples. 8-hydroxy-2-deoxyguanosine (8OHdG)

Reproductive protective property of diosmin

was determined using the traditional ELISA method based on the producer's procedure (Enzo Life Sciences, San Diego, CA). Catalase concentration was calculated from tissue H₂O₂ breakdown.

Testicular marker enzymes estimations

Evaluation of the enzyme activities of lactate dehydrogenase (LDH), sorbitol dehydrogenase (SDH), gamma-glutamyltransferase (GGT), acid phosphatase (ACP), and alkaline phosphatase (ALP) were performed using the traditional ELISA methods based on producer's procedure (Qumica Clinica Aplicada S.A., Spain).

Estimations of proinflammatory cytokines levels in testicular

Pro-inflammatory cytokines and proteins such as TNF- α , IL-1 β , and NF- κ β levels of testicular homogenate were measured prepared as previously described [29] and quantified using ELISA kits purchased from R&D Systems as well as Thermo Fisher Scientific.

Apoptotic-related protein assays

BioVision, Sigma-Aldrich, and Cusabio ELISA kits were used to assess B-cell lymphoma-2 and testicular caspases 3 and 9 using indirect analysis of mitochondrial cytochrome C. Oyovwi et al. [32] used spectrophotometry at 550 and 540 nm to identify mitochondrial cytochrome C in the supernatants.

Membrane potential ($\Delta\psi_m$) of the mitochondria

Following the application of the fluorescent dye rhodamine 123, the mitochondrial membrane potential was assessed in accordance with the method described by Zorova et al. [33]. Sperm were treated with Rh123 and read at wavelengths of 488 and 530 nm. The intensity of the Rh123 fluorescence was then determined by measuring the mitochondrial membrane potential.

Sperm DNA fragmentation assay

Sperm DNA fragmentation was examined using Tesi et al.'s [31] aniline blue staining method, with at least 200 sperm detected per slide. Testicular DNA fragmentation index (tDFI) was used to determine the percentage of stained sperm heads.

Histopathological examination of testes

Histological and morphometric studies: Testicular tissues were kept in 10% buffered formalin for microscopic examination, dried in ethanol alcohols of increasing strength, washed in xylene, cast, embedded, microtomed at 5 μ m thickness, and stained with hematoxylin-eosin prior to microscopic examination based on previous protocol [34].

Data analysis

Data were analysed using Graph pad prism 8 Biostatistics software (Graph pad Software, Inc., Lajolla, USA version 8.0). All data were presented as mean \pm S.E.M. Thereafter, analysis was carried out by one-way analysis of variance (ANOVA) and followed by a post hoc test (Bonferroni) for multiple comparisons. The level of significance for all tests was set at $P < 0.05$.

Results

Diosmin abrogates DOX-induced alterations in serum hormonal parameters in male Wistar rats

The ability of diosmin to reverse DOX-induced alterations in serum hormone markers was examined. Accordingly, DOX significantly decreased the levels of FSH (**Figure 1A**), LH (**Figure 1B**), and testosterone (**Figure 1C**), although diosmin treatment reversed these defects (**Figure 1A-C**).

Diosmin mitigates DOX-induced perturbations in sperm parameters in rats

DOX reduced ($P < 0.0001$) sperm count (**Figure 2A**), sperm motility (**Figure 2B**), sperm viability (**Figure 2C**), sperm volume (**Figure 2D**), daily sperm production (**Figure 2E**), and sperm morphology (**Figure 2F**) in rats compared to healthy control groups. However, diosmin reversed these changes, but treatment alone had no discernible effect on sperm indices.

Diosmin reverses DOX-induced decrease in testicular androgenic enzymes activities in rats testes

Diosmin significantly improved the DOX-induced reduction in the concentrations of testicular

Reproductive protective property of diosmin

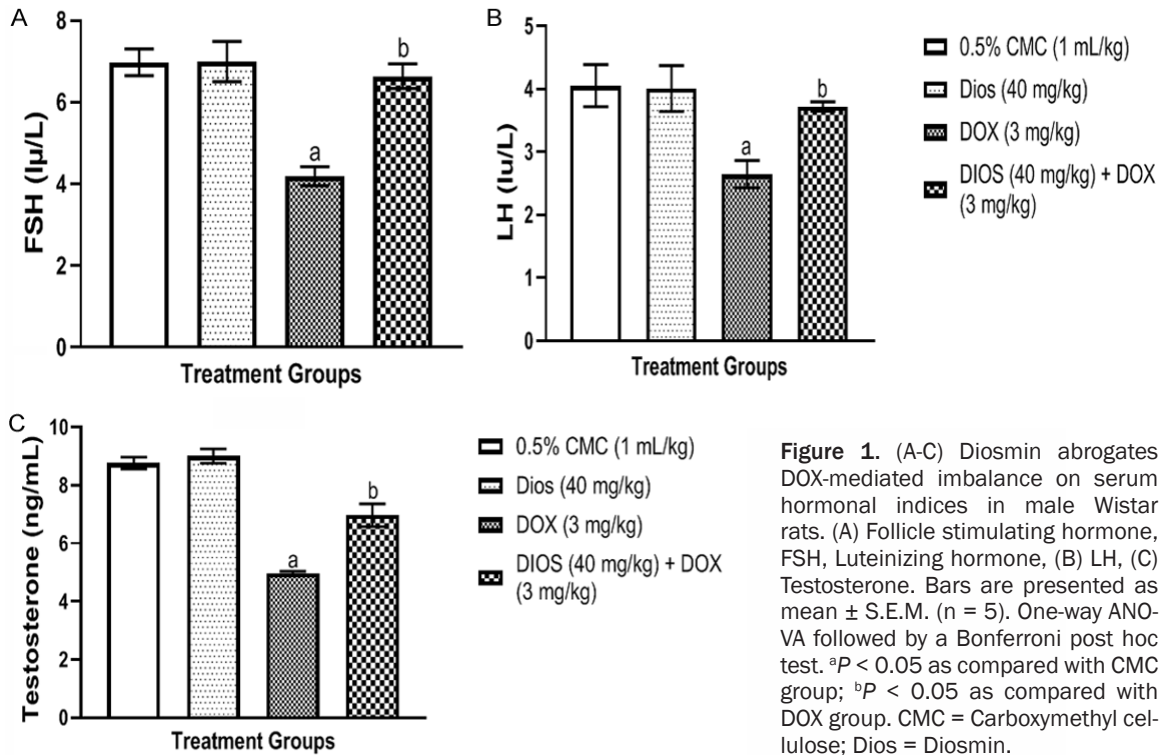


Figure 1. (A-C) Diosmin abrogates DOX-mediated imbalance on serum hormonal indices in male Wistar rats. (A) Follicle stimulating hormone, FSH, Luteinizing hormone, (B) LH, (C) Testosterone. Bars are presented as mean \pm S.E.M. (n = 5). One-way ANOVA followed by a Bonferroni post hoc test. ^aP < 0.05 as compared with CMC group; ^bP < 0.05 as compared with DOX group. CMC = Carboxymethyl cellulose; Dios = Diosmin.

androgenic enzymes, 3 β -HSD (**Figure 3A**) and 17 β -HSD (**Figure 3B**) in rat testes. Diosmin alone did not significantly change these enzymes compared to normal controls.

Diosmin attenuates alteration in sperm membrane integrity of rats treated with DOX using hypo-osmotic swelling test analysis

HOST was used in the study to examine the effect of diosmin on DOX-induced changes in sperm membrane integrity. In contrast to control animals, diosmin alone showed no significant differences in the integrity of the sperm membrane abnormalities produced by DOX in rat cauda epidymal spermatozoa. However, diosmin reversed DOX-induced altered sperm membrane integrity relative to DOX group (**Figure 4**).

Diosmin attenuates alteration in sperm chromatin integrity of rats treated with DOX using toluidine blue staining (TBS) in male rats

TBS was used to study the influence of diosmin on DOX-induced changes in sperm chromatin integrity as shown in **Figure 5**. Notably, DOX reduced sperm chromatin integrity, but diosmin significantly reduced the defects caused

by DOX compared to DOX-treated rats. When compared to controls, no appreciable difference was found in rats treated with diosmin alone.

Diosmin inhibits DOX-induced decrease in acrosome-reacted capacitated sperm in rats

Figure 6 shows the impacts of diosmin on acrosome-reacted capacitated sperm in male rats receiving DOX. DOX significantly (P < 0.05) reduced acrosome-reacted sperm, but diosmin (40 mg/kg) reversed the decline. Significant differences in diosmin therapy were observed in naïve rats compared to the control group.

Diosmin prevents DOX-induced alterations in testicular oxidative status in rats

DOX significantly increased oxidative damage, as shown by increased MDA levels (**Figure 7A**), with significant decrease in SOD, CAT, and GSH levels (**Figure 7B-D**, respectively) compared to the controls. The diosmin therapy significantly decreased the testicular oxidative stress, as shown by decreased MDA level, and increased levels of antioxidant armouries (SOD, CAT, and GSH).

Reproductive protective property of diosmin

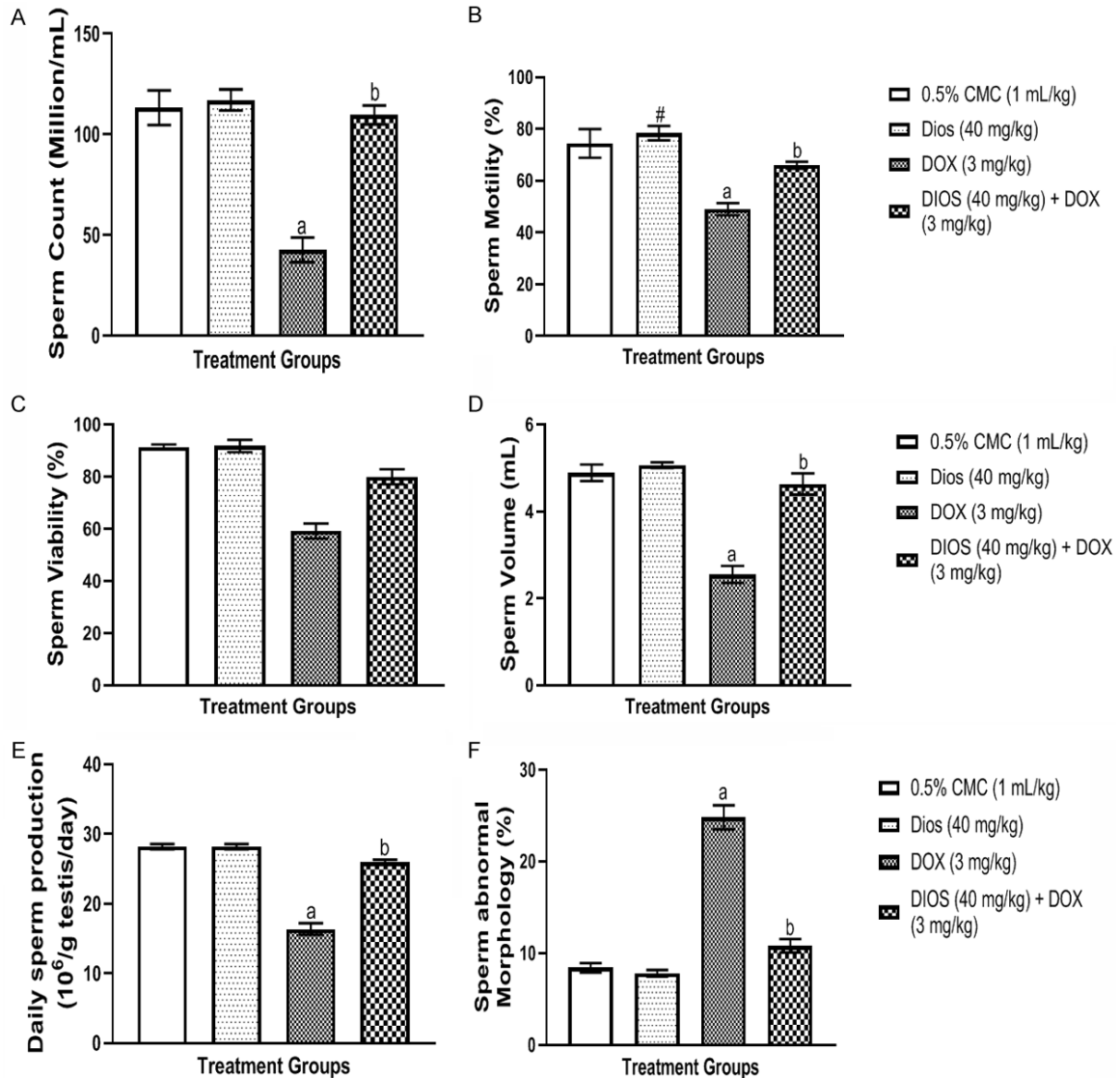
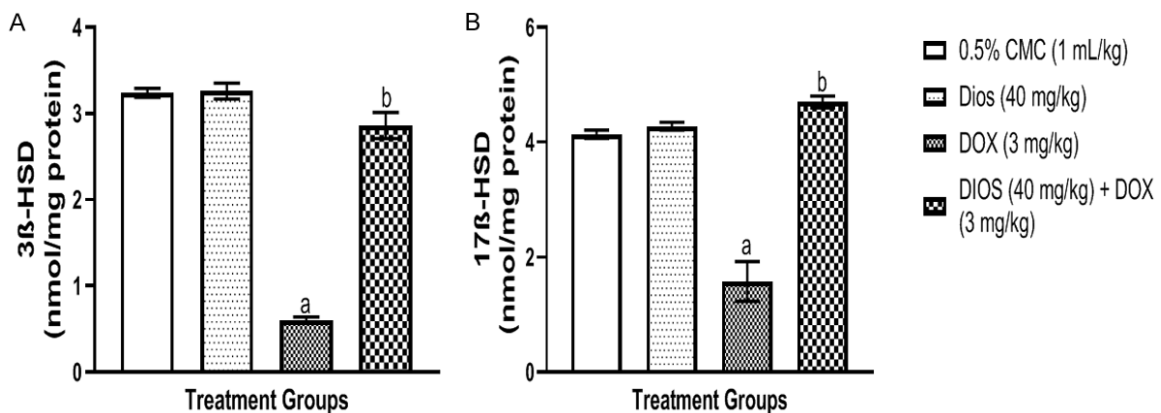


Figure 2. (A-F) Diosmin reverses the altered spermatogenesis ((A) sperm count, (B) sperm motility, (C) sperm viability, (D) sperm volume, (E) daily sperm production, and (F) sperm morphology) induced by DOX according to one-way ANOVA followed by the Bonferroni post hoc test. Mean \pm S.E.M. to represent (n = 5). ^aP < 0.05 vs CMC group and ^bP < 0.05 vs the DOX group. CMC = Carboxymethyl cellulose; Dios = Diosmin.



Reproductive protective property of diosmin

Figure 3. (A, B) Diosmin reduces the effects of DOX on the rats' testicular androgenic enzymes: (A) 3 β -HSD = 3beta-hydroxysteroid dehydrogenase and (B) 17 β -HSD = 17beta-hydroxysteroid dehydrogenase. The results of a one-way ANOVA following the Bonferroni post hoc test are represented as mean \pm S.E.M. (n = 5). ^aP < 0.05 in comparison to the CMC group and ^bP < 0.05 in comparison to the DOX group. CMC = Carboxymethyl cellulose; Dios = Diosmin.

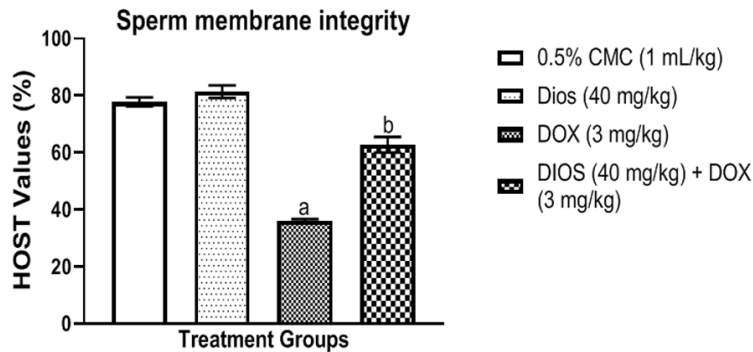


Figure 4. Diosmin attenuates alteration in sperm membrane integrity of rats treated with DOX using hypo-osmotic swelling test analysis (HOST). Bars show the mean \pm S.E.M. (n = 5) (one way ANOVA with Bonferroni post hoc test). ^aP < 0.05 versus the CMC group and ^bP < 0.05 versus the DOX group. CMC = Carboxymethyl cellulose; Dios = Diosmin.

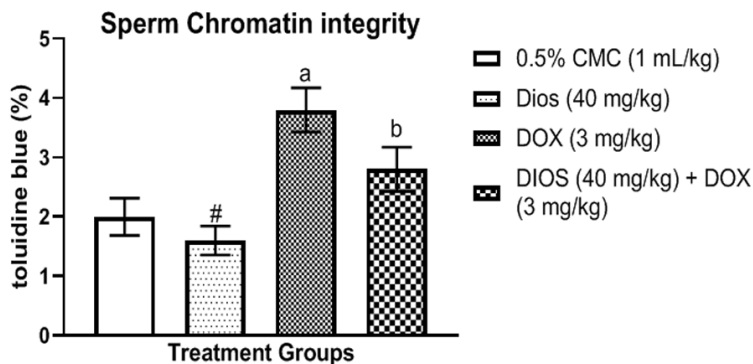


Figure 5. Diosmin attenuates alteration in sperm chromatin integrity of rats treated with DOX using toluidine blue staining (TBS) in male rats. Bars show the mean and standard error of the mean (n = 5). ^aP < 0.05 in comparison to the CMC group and ^bP < 0.05 in comparison to the DOX group. CMC = Carboxymethyl cellulose; Dios = Diosmin.

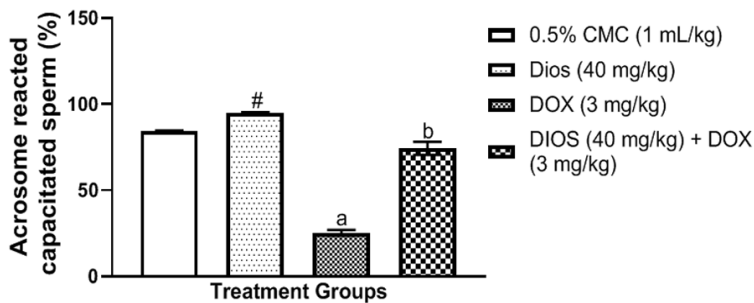


Figure 6. Diosmin inhibits DOX-induced decrease in acrosome-reacted capacitated sperm in rats. Bars were shown as mean \pm S.E.M. (n = 5); one-way ANOVA was followed by the post-hoc Bonferroni test. ^aP < 0.05 in comparison to CMC, and ^bP < 0.05 in comparison to DOX. CMC = Carboxymethyl cellulose; Dios = Diosmin.

Diosmin prevents DOX-induced testicular oxidative damage in rats

The effect of diosmin on DOX-induced oxidative damage is shown in **Figure 8**. Accordingly, **Figure 8** shows that DOX-induced increased 8OHdG levels relative to control. However, treatment with diosmin significantly ameliorated DOX-induced oxidative damage in the testes of rats (P < 0.05) by reducing 8OHdG levels.

Diosmin reverses DOX-induced alteration in testicular marker enzyme functions in rats

The effects of diosmin on DOX induced alteration in testicular marker enzymes functions in rats are shown in **Figure 9A-E**. DOX treatment increased LDH (**Figure 9A**), SDH (**Figure 9B**), GGT (**Figure 9C**) and ACP (**Figure 9D**) while ALP activities was decreased (**Figure 9E**), but these were reversed by diosmin.

Diosmin abates DOX-induced pro-inflammation in rats' testes

The effect of diosmin on DOX-induced testicular inflammation is shown in **Figure 10**. DOX increases the release of pro-inflammatory protein and cytokines such as NF- κ B (**Figure 10A**), TNF- α (**Figure 10B**), and IL-1 β (**Figure 10C**). Notably, diosmin (40 mg/kg) reduces the levels of NF- κ B, TNF- α , and IL-1 β relative to DOX groups.

Reproductive protective property of diosmin

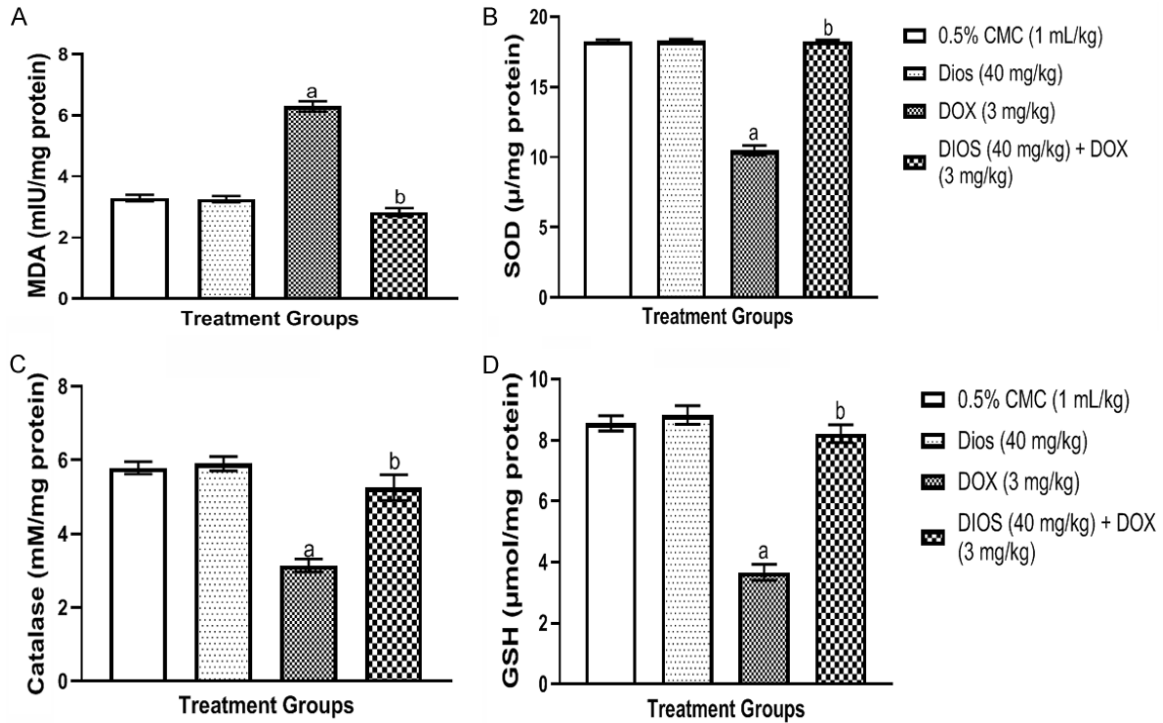


Figure 7. Diosmin prevents DOX-induced alterations in testicular oxidative status in rats: (A) Malondialdehyde, MDA, (B) Superoxide dismutase, SOD, (C) Catalase, and (D) Glutathione, GSH. Bars were provided as mean \pm S.E.M. (n = 5) and were subjected to a one-way ANOVA and the Bonferroni's post hoc test. ^aP < 0.05 when compared to CMC; ^bP < 0.05 when compared to DOX. CMC = Carboxymethyl cellulose; Dios = Diosmin.

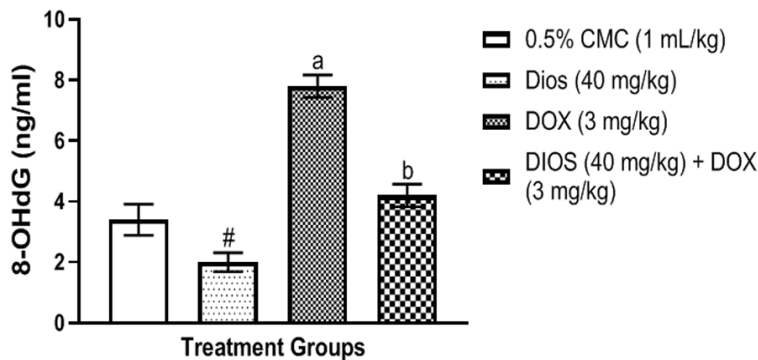


Figure 8. Diosmin prevents DOX-induced increase in testicular 8-hydroxy-2'-deoxyguanosine (8-OHdG) in rats. The results were provided as mean \pm S.E.M. using one-way ANOVA following the Bonferroni post hoc test. ^aP < 0.05 in comparison to CMC; ^bP < 0.05 in comparison to DOX. CMC = Carboxymethyl cellulose; Dios = Diosmin.

Diosmin abates DOX-induced alterations in apoptotic related factor in rats' testes

DOX therapy significantly reduced Bcl-2 level (**Figure 11A**), although no major change was observed on $\Delta\psi$ level (**Figure 11B**) relative

to controls. As regards tDFI, DOX markedly increased tDFI (**Figure 11C**), mitochondrial cytochrome C (**Figure 11D**), as well as caspases-3 and -9 (**Figure 11E, 11F**). However, the DOX-induced changes were reversed in diosmin-treated rats.

Diosmin prevents DOX-induced histopathological changes of the testes of rats

Figure 12 shows the influence of diosmin on the histological changes in the rat testis caused by DOX. Diosmin had no effect on testicular architecture, seminiferous tubules, or sperm. DOX-exposed rats showed decreased spermatogenesis with degraded seminiferous tubules, necrosis, atrophy, and homogeneous and vascular congestion. Conversely, diosmin was shown to reduce DOX-induced defects in testicu-

Reproductive protective property of diosmin

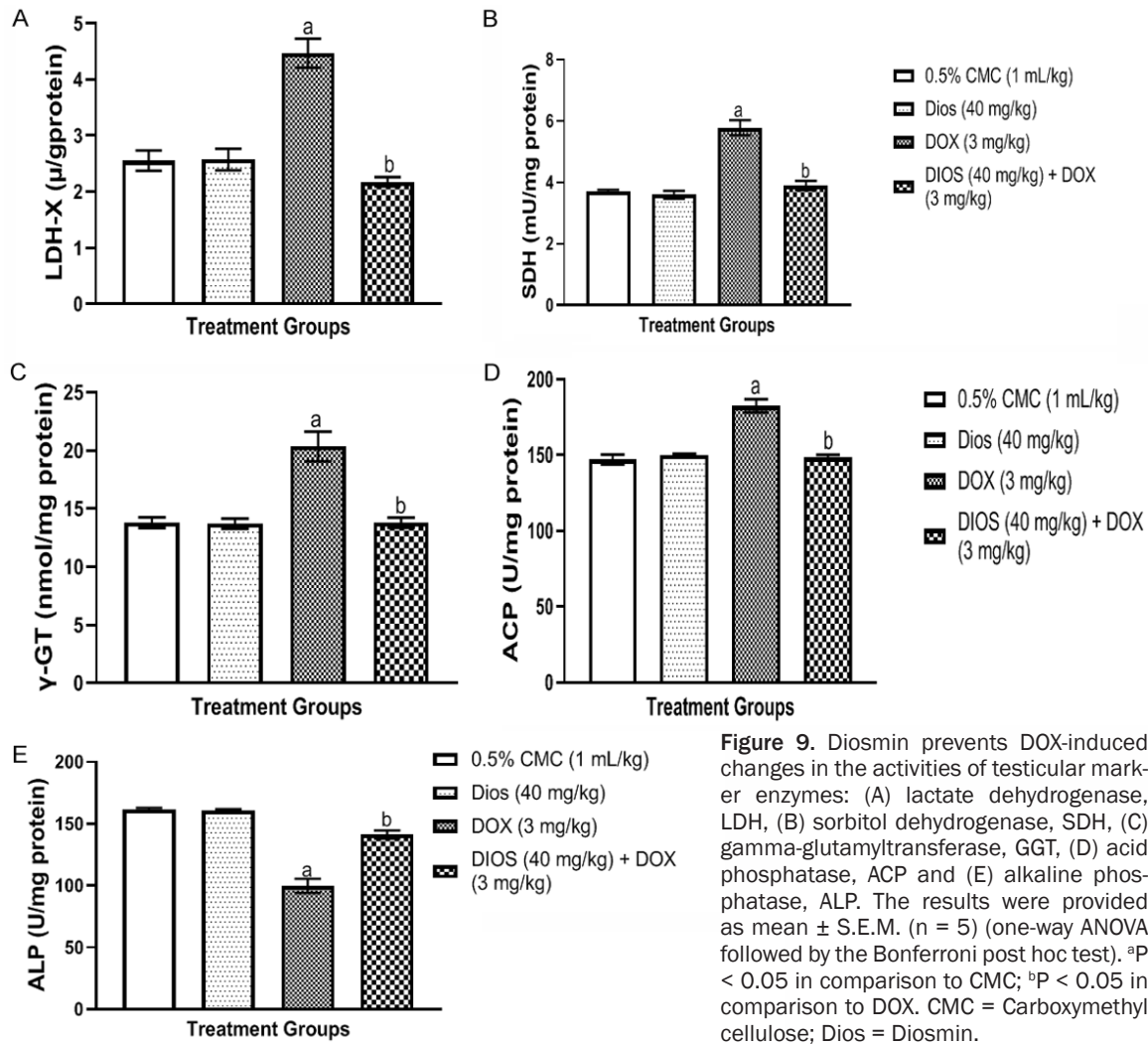


Figure 9. Diosmin prevents DOX-induced changes in the activities of testicular marker enzymes: (A) lactate dehydrogenase, LDH, (B) sorbitol dehydrogenase, SDH, (C) gamma-glutamyltransferase, GGT, (D) acid phosphatase, ACP and (E) alkaline phosphatase, ALP. The results were provided as mean \pm S.E.M. (n = 5) (one-way ANOVA followed by the Bonferroni post hoc test). ^aP < 0.05 in comparison to CMC; ^bP < 0.05 in comparison to DOX. CMC = Carboxymethyl cellulose; Dios = Diosmin.

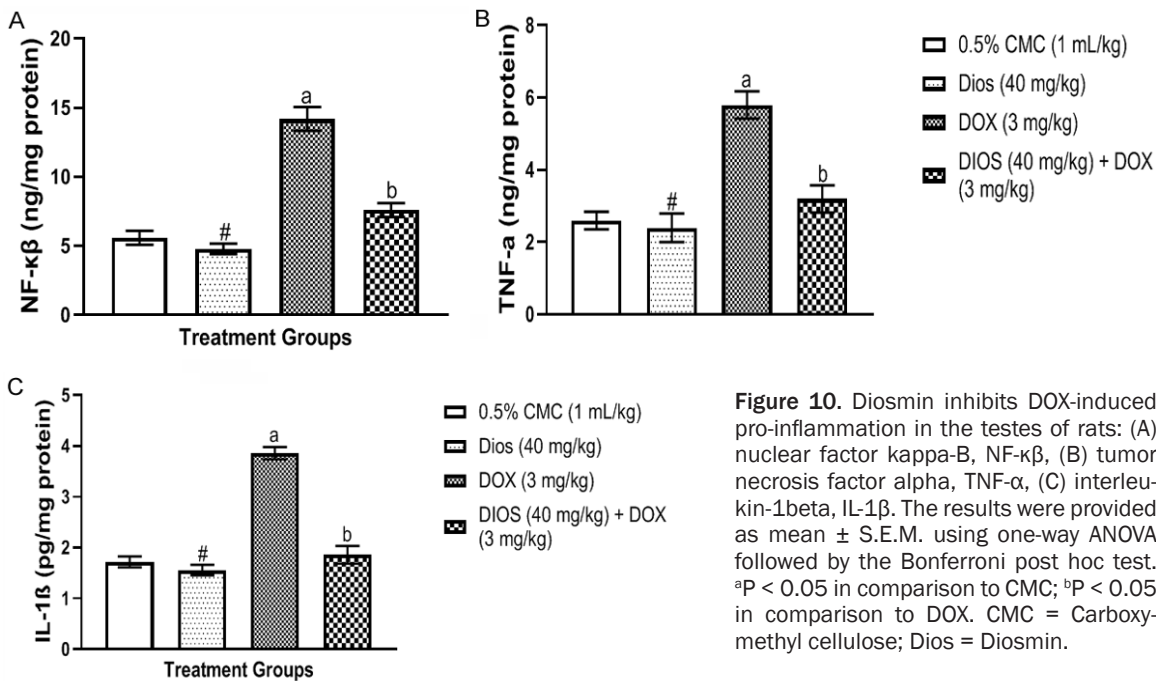


Figure 10. Diosmin inhibits DOX-induced pro-inflammation in the testes of rats: (A) nuclear factor kappa-B, NF-κβ, (B) tumor necrosis factor alpha, TNF-α, (C) interleukin-1beta, IL-1β. The results were provided as mean \pm S.E.M. using one-way ANOVA followed by the Bonferroni post hoc test. ^aP < 0.05 in comparison to CMC; ^bP < 0.05 in comparison to DOX. CMC = Carboxymethyl cellulose; Dios = Diosmin.

Reproductive protective property of diosmin

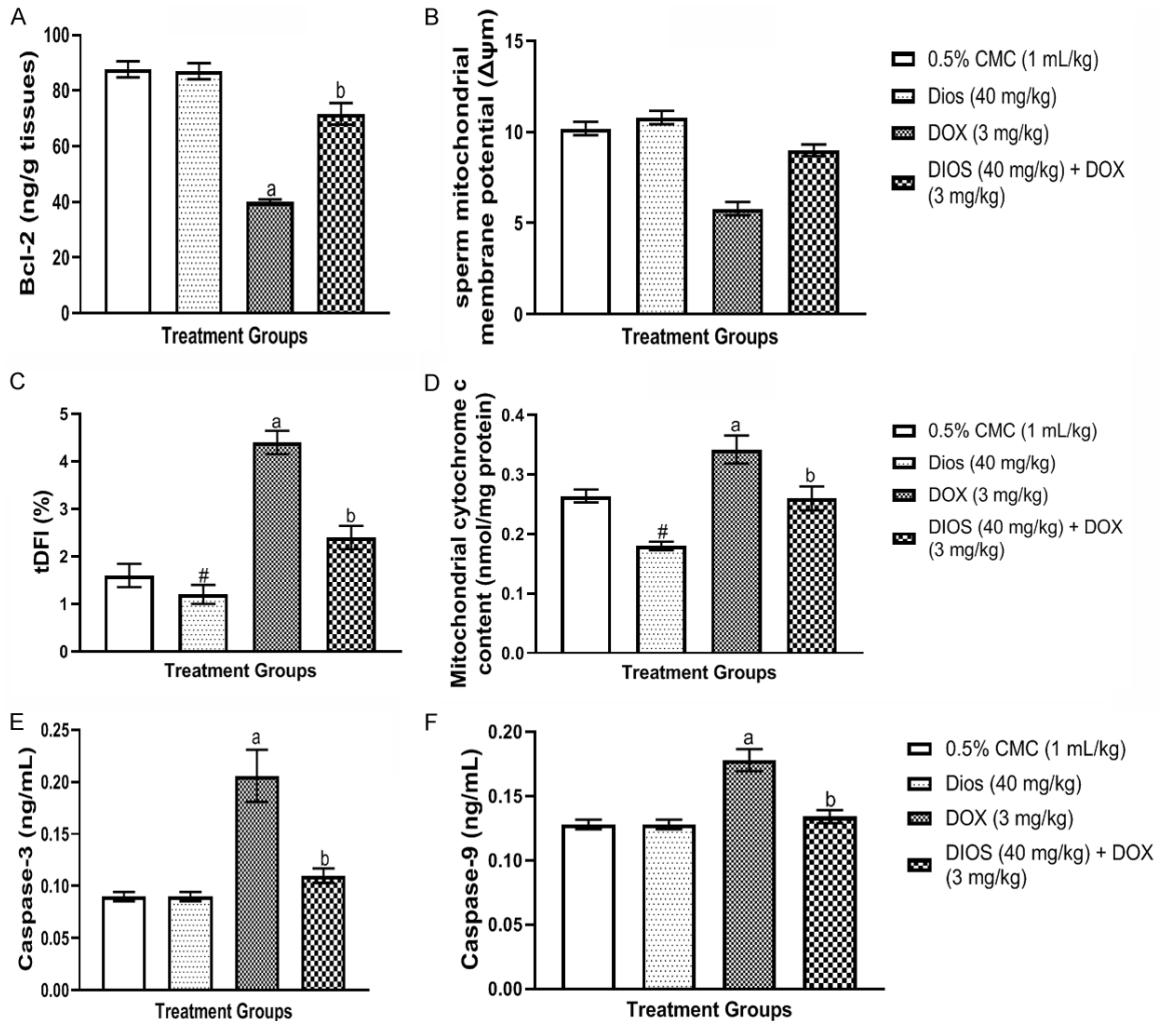


Figure 11. Diosmin inhibits DOX-induced changes in apoptotic associated factors ((A) Bcl-2, (B) $\Delta\psi_m$, (C) tDFI, (D) mitochondrial cytochrome C, (E, F) caspases-3 and -9). Bars were presented as mean \pm S.E.M. (n = 5). ^aP < 0.05 in comparison to CMC; ^bP < 0.05 in comparison to DOX. CMC = Carboxymethyl cellulose; Dios = Diosmin.

lar architecture, seminiferous tubules and sperm.

Diosmin increases the mean of the diameter of seminiferous tubules, germinal layer thickness, and number of spermatogonia, Sertoli, and Leydig cells in the testes of rats treated with DOX

Table 1 shows that rats in the control group had larger seminiferous tubules, thicker germ layers, more spermatogonia, and Sertoli and Leydig cells. Diosmin and diosmin + DOX groups had higher mean scores for spermatogonia, Sertoli and Leydig cells, seminiferous tubule diameter, and germ layer thickness. DOX reduced seminiferous tubule diameter, but diosmin + DOX cells rebounded.

Discussion

Anti-carcinogenic medications are gonadotoxic and spermatotoxic [35-37], notably causing oxidative stress, apoptosis, and immunological changes in reproductive cells [38]. Natural antioxidant flavonoids with gonadoprotective actions have been employed to alleviate these negative effects [31, 32, 39]. Hence, our study examined rats treated with DOX (3 mg/kg) intraperitoneally at intervals of 7 days. The most effective dose of diosmin (40 mg/kg/p.o.) was used to evaluate reproductive hormones, spermatogenesis, histopathological observation, pro-inflammation, apoptotic-related protein, and oxidative stress biomarkers. The study found a decrease in spermatogenesis

Reproductive protective property of diosmin

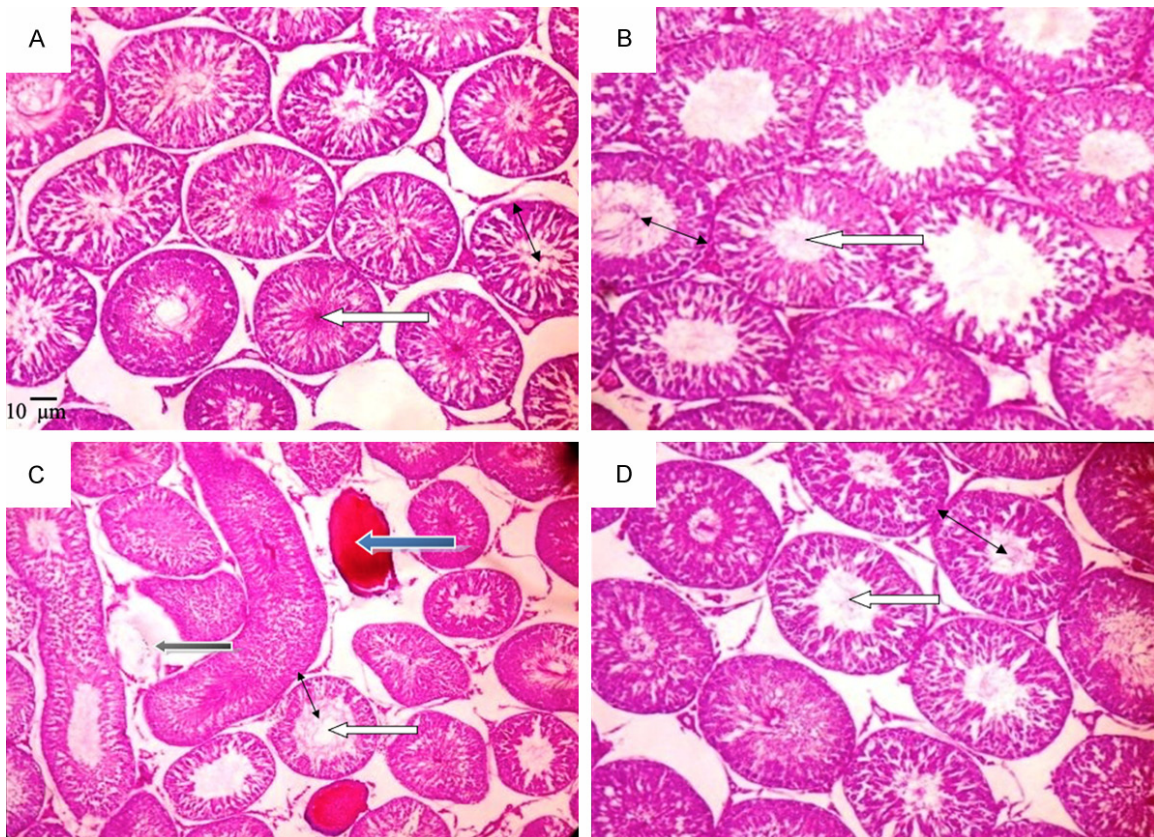


Figure 12. Photomicrographs showing the ability of diosmin to suppress DOX-induced histopathological changes in rat testes. (A) 0.5% CMC (1 mL/kg) as control; (B) Dios (4 mg/kg); (C) DOX (3 mg/kg); (D) Dios (40 mg/kg) plus DOX (3 mg/kg). In the control group (A) and the Dios group (40 mg/kg), normal seminiferous tubule structure and normal germinal layer thickness were observed. In the DOX-treated group (C), reduced germ layer thickness, atrophy, significant deterioration of seminiferous tubules (ST), necrosis of spermatocytes and spermatids, and defoliation of numerous spermatocytes into the lumen of the ST were observed. In the group treated with diosmin + DOX (D), a typical seminiferous tubule structure was observed. The seed layer thickness is indicated by the black arrows in the figures; Atrophy is indicated by the blue arrows; Spermatocytes and spermatids are indicated by the white arrows; dead pyknotic cells are indicated by the blue arrows; and homogeneous and vascular congestion is indicated by the white arrows. The original magnification of the hematoxylin-eosin stain was 100 \times . The calibration bar for each plate was 0.01 mm (10 m).

Table 1. Effects of diosmin on mean of the diameter of seminiferous tubules, germinal layer thickness, number of spermatogonia, Sertoli, and Leydig cells in the testes of rats treated with DOX

Groups	Diameter of seminiferous tubule (μ)	Germinal layer thickness (μ)	Number of spermatogonia (mm^2)	Number of leydig cells (mm^2)	Number of sertoli cells (mm^2)
0.5% CMC (1 mL/kg)	306.1 \pm 12.63	101.09 \pm 8.12	1411.22 \pm 12.46	687.47 \pm 13.4	143.38 \pm 6.4
Dios (40 mg/kg)	307.4 \pm 11.59	102.84 \pm 8.10	1412.19 \pm 23.28	688.45 \pm 16.41	144.32 \pm 8.36
DOX (3 mg/kg)	239.41 \pm 6.78 ^a	60.17 \pm 4.97 ^a	1132.70 \pm 15.52 ^a	499.38 \pm 12.28 ^a	118.83 \pm 7.25 ^a
DIOS (40 mg/kg) + DOX (3 mg/kg)	288.09 \pm 10.17 ^b	96.50 \pm 8.37 ^b	1378.39 \pm 32.46 ^b	587.89 \pm 18.35 ^b	135.42 \pm 5.37 ^b

The values represent the mean \pm S.E.M. (n = 5). The one-way ANOVA was followed by the Bonferroni posthoc test. ^aP < 0.05 in comparison to CMC; ^bP < 0.05 in comparison to DOX. CMC = Carboxymethyl cellulose; Dios = Diosmin.

among the DOX-treated rats, which was consistent with previous studies [5, 40-43]. The decrease in spermatogenic activity may be due

to alterations in androgenic status, as supported by histopathological findings [5, 42, 43]. The study also found that DOX treatment caused

significant structural alterations in the testis, including seminiferous tubule atrophy and degeneration. We suggest that changes may be attributed to oxidative stress, imbalance between the antioxidants and pro-oxidants [5, 40-43], and elevated NF- κ B, TNF- α , and IL-1 β , which might have negatively affected testicular functions and structure as shown in this study [44-46]. However, diosmin treatment significantly preserved testicular function by maintaining seminiferous tubular shapes, reducing oxidative stress-mediated damages in sertoli cells, spermatogonia, and Leydig cells, and improving physiological functions. This might have led to increased germinal cell layer thickness in both diosmin and DOX groups. Sertoli cells play a crucial role in regulating spermatogonia proliferation and differentiation, and diosmin prevented the impairment in sperm proliferation by DOX [2, 47].

Altered sperm motility is crucial for male infertility [48], which is linked to asthenozoospermia as a major cause [49, 50]. TNF- α has been indicated to cause a decrease in sperm motility due to its potential to induce increased generation of free radicals [5, 42, 43, 51, 52]. In this study, diosmin demonstrated protective effect against DOX-induced sperm deficiency. Oxidative stress is believed to play a significant role in testicular dysfunction and infertility caused by DOX. Specifically, increased DOX concentration is known to result in reduced glutathione content, SOD, and CAT activities with increase MDA and 8-OHdG concentrations. Indeed, these findings are consistent with previous findings that established that DOX exposure reduces antioxidant defense systems and promotes lipid peroxidation in testicular tissue [53-56]. Diosmin also decreased oxidative stress by reducing MDA generation and 8-OHdG levels and improving testicular anti-oxidant status through increasing GSH and CAT levels. This finding supports previous studies that diosmin attenuates oxidative stress [19, 40, 57, 58]. Additionally, diosmin mitigates dexamethasone-induced osteoporosis *in vivo* by modulating receptor activators of NF- κ B ligand, Runt-related transcription factor 2, and downregulating osteoprotegerin (OPG) [39]. Rats treated with DOX plus diosmin displayed decreased testicular oxidative stress in the current investigation.

Oxidative stress is crucial for the release of cytokines [20, 59-61], and diosmin has been previously shown to elicit an anti-inflammatory function [20]. Notably, DOX-mediated testicular damage involves induction of inflammation [44-46], characterized by elevated TNF- α levels, NF- κ B expression, and inducible IL-1 β production [44-46]. The ability of diosmin to significantly reduce the levels of these inflammatory mediators, confirms the findings of previous findings, showing that diosmin inhibits DOX-induced cytokine signaling pathway activation [20, 44-46]. Together, this study supports the importance of diosmin in the prevention of testicular damage caused by DOX. Accordingly, the finding that diosmin reverses DOX-induced testicular inflammation supports its ability to effectively reverse DOX-induced testicular architectural changes, as demonstrated by histological examination, oxido-inflammation, and sperm analysis. The therapeutic action of diosmin in DOX-induced testicular toxicity may involve functional markers of spermatogenesis, such as ACP, ALP, SDH, and LDH [62]. Previous studies have shown that biomarkers such as γ -GT and LDH determine sertoli and Leydig cell functions, and changes in their physiological levels indicate a depletion of germ cells in the seminiferous tubule. ALP is involved in mobilizing metabolites for accessory sex organ development or sperm cell maintenance [62]. To maintain the physiology of the sperm, acid phosphatase is, however, predominantly distributed within the testes [62]. In this investigation, testicular ALP was significantly decreased after DOX treatment, while LDH, ACP, γ -GT and SDH activities were elevated, and diosmin significantly reversed these effects, suggesting protection against testicular injury or damage.

The role of hypothalamic-pituitary-testicular (HPT) axis dysfunction in DOX-induced testicular damage has been well established [10, 14], notably associated with endocrine disturbances via a mechanism linked to damage to Leydig cells. Leydig cells are highly vulnerable to toxic effects involving oxidative stress and impacting hormonal outputs [10]. Decreased Leydig cell count causes reduced sperm production due to decreased serum testosterone levels. In this study, it is important to mention that DOX notably reduces Leydig cell count, and testicular LH receptor levels, thereby reducing testosterone

Reproductive protective property of diosmin

production in rats. Furthermore, DOX exposure has also been shown to attenuate testicular enzymes such as 17 β -HSD and 3 β -HSD levels, which are crucial enzymes needed for testicular androgenesis. Mechanistically, excessive TNF- α release inhibits gonadal functions, particularly Leydig cell steroidogenesis and steroidogenic enzyme expression [62, 63], thus leading to a dramatic decrease in plasma testosterone levels, possibly due to suppression of testicular steroidogenic enzyme activities [64]. However, in this study, diosmin was found to increase testosterone levels, possibly due to the inhibition of TNF- α substrates involved in the testosterone conversion to estrone. Moreover, previous studies have shown that TNF- α blockers prevent testosterone conversion into estrogen [65]. Of note, we also found that diosmin reversed DOX-induced decreased testicular 17 β -HSD and 3 β -HSD enzyme activities and blood testosterone levels. This may be due to decreased TNF- α in testicular tissue and its anti-oxidative function, a naturally viable mechanism which protects Leydig cells from oxidative stress thereby promoting testicular steroidogenesis and associated spermatogenesis [62]. Thus, the ability of diosmin to testicular steroidogenesis and spermatogenesis possibly suggests its beneficial role in improving the functionality of the HPT axis.

Convincing bodies of evidence have also shown that testicular germ cell death is associated with hormonal changes or treatment with toxic agents such as DOX [66]. Indeed, reduced testosterone levels was previously shown to cause germ cell detachment from the seminiferous epithelium, notably triggering apoptosis [66]. Caspase-3, 9 and Bcl2 as well as mitochondria cytochrome C, are a reliable biomarker of apoptosis-related activity and were used in previous studies as indicators of compounds with anti-apoptotic markers [66]. In this study, reduced germ layer thickness, atrophy, significant deterioration of seminiferous tubules, necrosis of spermatocytes and spermatids, as well as defoliation of numerous spermatocytes into the lumen of the testes were observed in the DOX group compared to other groups, suggesting that DOX-induced testicular damage is also strongly associated with apoptosis. In this study, diosmin was found to significantly abate DOX-induced activation of testicular caspases 3 and 9, evidenced by increased germ layer

thickness, atrophy, improved seminiferous tubules, increased spermatocytes, and spermatids, possibly owing to its anti-inflammatory and antioxidant properties and fertility-enhancing effects. Although the study showed promising results, there are some limitations that need to be addressed to have a comprehensive understanding of the protective effects of diosmin against DOX-induced reproductive deficiency, especially as regards testicular damage. However, one of the major strengths of this study was the evidence of the involvement of the antioxidant and anti-inflammatory actions of diosmin as well as hormone-modulatory effects against DOX-induced testicular damage. On the long run, human studies are needed to determine the appropriate diosmin treatment for doxorubicin-induced reproductive impairment.

Conclusion

Diosmin treatment prevents DOX-induced testicular damage by promoting spermatogenesis, facilitating hormones, and anti-inflammatory activity, and reducing oxidative damage and apoptosis in rats.

Acknowledgements

We would like to express our gratitude to all of the technicians in the physiology departments at Achievers University's Faculty of Basic Medical Sciences.

Disclosure of conflict of interest

None.

Address correspondence to: Dr. Benneth Ben-Azu, DELSU Joint Canada-Israel Neuroscience and Biopsychiatry, Department of Pharmacology, Faculty of Basic Medical Sciences, Delta State University, Abraka 330105, Delta State, Nigeria. Tel: +234-8030881152; E-mail: pharmben4ever@yahoo.com; bben-azu@delsu.edu.ng; Dr. Mega O Oyovwi, Department of Physiology, Adeleke University, Ede 232104, Osun State, Nigeria. Tel: +234-8066-096369; E-mail: megalect@gmail.com; oyovwi.obukohwo@adelekeuniversity.edu.ng

References

- [1] Sridevi T, Nisha PV and Arulnathan GA. Effect of Doxorubicin on the morphology, histology and karyology of male reproductive system of

Reproductive protective property of diosmin

- white mice, *Mus musculus*. *Indian Journal of Science and Technology* 2012; 2614-8.
- [2] Owumi SE, Ijalede AO, Arunsi UO and Odunola OA. Luteolin abates reproductive toxicity mediated by the oxido-inflammatory response in Doxorubicin-treated rats. *Toxicol Res Appl* 2020; 4: 2397847320972040.
- [3] Kabel AM. Zinc/alogliptin combination attenuates testicular toxicity induced by doxorubicin in rats: role of oxidative stress, apoptosis and TGF- β 1/NF- κ B signaling. *Biomed Pharmacother* 2018; 97: 439-49.
- [4] Abdelaziz MH, Salah EL-Din EY, El-Dakdoky MH and Ahmed TA. The impact of mesenchymal stem cells on doxorubicin-induced testicular toxicity and progeny outcome of male prepubertal rats. *Birth Defects Res* 2019; 111: 906-19.
- [5] Erdem Guzel E, Kaya Tektemur N and Tektemur A. Alpha-lipoic acid may ameliorate testicular damage by targeting dox-induced altered antioxidant parameters, mitofusin-2 and apoptotic gene expression. *Andrologia* 2021; 53: e13990.
- [6] Bar-Joseph H, Ben-Aharon I, Tzabari M, Tsarfay G, Stemmer SM and Shalgi R. In vivo bioimaging as a novel strategy to detect doxorubicin-induced damage to gonadal blood vessels. *PLoS One* 2011; 6: e23492.
- [7] Rawat PS, Jaiswal A, Khurana A, Bhatti JS and Navik U. Doxorubicin-induced cardiotoxicity: an update on the molecular mechanism and novel therapeutic strategies for effective management. *Biomed Pharmacother* 2021; 139: 111708.
- [8] Antonucci S, Di Sante M, Tonolo F, Pontarollo L, Scalcon V, Alanova P, Menabò R, Carpi A, Bindoli A, Rigobello MP, Giorgio M, Kaludercic N and Di Lisa F. The determining role of mitochondrial reactive oxygen species generation and monoamine oxidase activity in doxorubicin-induced cardiotoxicity. *Antioxid Redox Signal* 2021; 34: 531-50.
- [9] Mannan A, Germon ZP, Chamberlain J, Sillar JR, Nixon B and Dun MD. Reactive oxygen species in acute lymphoblastic leukaemia: reducing radicals to refine responses. *Antioxidants (Basel)* 2021; 10: 1616.
- [10] Ward JA, Bardin CW, Knight M, Robinson J, Gunsalus G and Morris ID. Delayed effects of doxorubicin on spermatogenesis and endocrine function in rats. *Reprod Toxicol* 1988; 2: 117-126.
- [11] Aljobaily N, Viereckl MJ, Hydock DS, Aljobaily H, Wu TY, Busekrus R, Jones B, Alberson J and Han Y. Creatine alleviates doxorubicin-induced liver damage by inhibiting liver fibrosis, inflammation, oxidative stress, and cellular senescence. *Nutrients* 2020; 13: 41.
- [12] van der Zanden SY, Qiao X and Neefjes J. New insights into the activities and toxicities of the old anticancer drug doxorubicin. *FEBS J* 2021; 288: 6095-111.
- [13] Amaral CL, Bueno Rde B, Burim RV, Queiroz RH, Bianchi Mde L and Antunes LM. The effects of dietary supplementation of methionine on genomic stability and p53 gene promoter methylation in rats. *Mutat Res* 2011; 722: 78-83.
- [14] Mohan UP, P B TP, Iqbal STA and Arunachalam S. Mechanisms of doxorubicin-mediated reproductive toxicity - a review. *Reprod Toxicol* 2021; 102: 80-9.
- [15] Oyovwi MO, Ben-Azu B, Edesiri TP, Arientare RR, Emojevwe V, Nwangwa KE, Edje KE and Adebayo OG. Lutein attenuates cyclosporin-induced testicular impairment in male rats through modulation of androgenic hormones and enzymes. *Pharmacology and Toxicology of Natural Medicines (ISSN: 2756-6838)* 2022; 2: 12-24.
- [16] Islam J, Shree A, Afzal SM, Vafa A and Sultana S. Protective effect of Diosmin against benzo(a) pyrene-induced lung injury in Swiss Albino mice. *Environ Toxicol* 2020; 35: 747-57.
- [17] Ali N, AlAsmari AF, Imam F, Ahmed MZ, Alqahatani F, Alharbi M, AlSwayyed M, AlAsmari F, Alasmari M, Alshammari A, Fantoukh OI and Alanazi MM. Protective effect of diosmin against doxorubicin-induced nephrotoxicity. *Saudi J Biol Sci* 2021; 28: 4375-83.
- [18] Pari L and Srinivasan S. Antihyperglycemic effect of diosmin on hepatic key enzymes of carbohydrate metabolism in streptozotocin-nicotinamide-induced diabetic rats. *Biomed Pharmacother* 2010; 64: 477-81.
- [19] Okubo Eneni AE, Ben-Azu B, Mayowa Ajayi A and Oladele Aderibigbe A. Diosmin attenuates schizophrenia-like behavior, oxidative stress, and acetylcholinesterase activity in mice. *Drug Metab Pers Ther* 2020; 35: 20200119.
- [20] Eneni AO, Ben-Azu B, Ajayi AM and Aderibigbe AO. Lipopolysaccharide exacerbates ketamine-induced psychotic-like behavior, oxidative stress, and neuroinflammation in mice: ameliorative effect of diosmin. *J Mol Neurosci* 2023; 73: 129-42.
- [21] Abou-Elghait AT, Elgamal DA, Abd el-Rady NM, Hosny A, Abd El-Samie EZAA and Ali FEM. Novel protective effect of diosmin against cisplatin-induced prostate and seminal vesicle damage: role of oxidative stress and apoptosis. *Tissue Cell* 2022; 79: 101961.
- [22] Saghaei E, Nasiri Boroujeni S, Safavi P, Borjian Boroujeni Z and Bijad E. Diosmetin mitigates cognitive and memory impairment provoked by chronic unpredictable mild stress in mice. *Evid Based Complement Alternat Med* 2020; 2020: 5725361.

Reproductive protective property of diosmin

- [23] Czubaszek M, Andraszek K, Banaszewska D and Walczak-Jędrzejowska R. The effect of the staining technique on morphological and morphometric parameters of boar sperm. *PLoS One* 2019; 14: e0214243.
- [24] Madill S and Kustritz MV. Evaluation of semen. *Veterinary Cytology* 2020; 531-51.
- [25] Kyjovska ZO, Boisen AM, Jackson P, Wallin H, Vogel U and Hougaard KS. Daily sperm production: application in studies of prenatal exposure to nanoparticles in mice. *Reprod Toxicol* 2013; 36: 88-97.
- [26] Kim SW, Lee JY, Kim CL, Ko YG and Kim B. Evaluation of rooster semen quality using CBB dye based staining method. *Journal of Animal Reproduction and Biotechnology* 2022; 37: 55-61.
- [27] Talebi AR, Ghasemzadeh J, Khalili MA, Halvaei I and Fesahat F. Sperm chromatin quality and DNA integrity in partial versus total globozoospermia. *Andrologia* 2018; 50: e12823.
- [28] Patón-Romero JD, Baldassarre MT, Rodríguez M, Runeson P, Höst M and Piattini M. Governance and management of green IT: a multi-case study. *Inf Softw Technol* 2021; 129: 106414.
- [29] Ben-Azu B, Moke EG, Chris-Ozoko LE, Jaiyeoba-Ojigbo EJ, Adebayo OG, Ajayi AM, Oyowwi MO, Odjugo G, Omozioje VI, Ejomafuwe G, Onike N, Eneni AO, Ichipi-Ibukor CP and Achuba IF. Diosgenin alleviates alcohol-mediated escalation of social defeat stress and the neurobiological sequelae. *Psychopharmacology (Berl)* 2024; 241: 785-803.
- [30] Oyowwi MO, Ben-Azu B, Tesi EP, Oyeleke AA, Uruaka CI, Rotu RA and Aya-Ebi EO. Repeated endosulfan exposure induces changes in neurochemicals, decreases ATPase transmembrane ionic-pumps, and increased oxidative/nitrosative stress in the brains of rats: reversal by quercetin. *Pestic Biochem Physiol* 2021; 175: 104833.
- [31] Tesi EP, Ben-Azu B, Mega OO, Mordi J, Knowledge OO, Awele ED, Rotu RA, Emojevwe V, Adebayo OG and Eneni OA. Kolaviron, a flavonoid-rich extract ameliorates busulfan-induced chemo-brain and testicular damage in male rats through inhibition of oxidative stress, inflammatory, and apoptotic pathways. *J Food Biochem* 2022; 46: e14071.
- [32] Mega OO, Edesiri TP, Victor E, Kingsley NE, Rume RA, Faith FY, Simon OI, Oghenetega BO and Agbonifo-Chijiokwu E. D-ribose-l-cysteine abrogates testicular maladaptive responses induced by polychlorinated bisphenol intoxication in rats via activation of the mTOR signaling pathway mediating inhibition of apoptosis, inflammation, and oxidonitrergic flux. *J Biochem Mol Toxicol* 2022; 36: e23161.
- [33] Zorova LD, Demchenko EA, Korshunova GA, Tashlitsky VN, Zorov SD, Andrianova NV, Popkov VA, Babenko VA, Pevzner IB, Silachev DN, Plotnikov EY and Zorov DB. Is the mitochondrial membrane potential ($\Delta\Psi$) correctly assessed? Intracellular and intramitochondrial modifications of the $\Delta\Psi$ probe, Rhodamine 123. *Int J Mol Sci* 2022; 23: 482.
- [34] Emojevwe V, Nwangwa EK, Naiho AO, Oyowwi MO, Igiehon O, Ogunwole E, Makinde-Taylor MS, Ayotomide OA, Akinola AO, Edesiri PT, Oghenetega BO and Ovuakporaye SI. Therapeutic efficacy of N-acetylcysteine and zinc sulphate against di-(2-ethylhexyl) phthalate-induced testicular oxido-nitrergic stress in male Wistar rat. *Andrologia* 2022; 54: e14508.
- [35] Ashraf MA. Phytochemicals as potential anticancer drugs: time to ponder nature's bounty. *Biomed Res Int* 2020; 2020: 8602879.
- [36] Hossainey MRH, Sazed SA, Nima MK, Rahman MS, Ashraf T, Chowdhury AA, Rashid MA, Haque R and Alam MS. Investigation of anti-malarial activity and cytotoxicity profiling of a Bangladeshi plant *Syzygium cymosum*. *J Infect Dev Ctries* 2020; 14: 924-8.
- [37] Ansari MHR, Saher S, Parveen R, Khan W, Khan IA and Ahmad S. Role of gut microbiota metabolism and biotransformation on dietary natural products to human health implications with special reference to biocheminformatics approach. *J Tradit Complement Med* 2022; 13: 150-60.
- [38] Mustafa S, Ijaz MU, ul Ain Q, Afsar T, Almajwal A, Shafique H and Razak S. Isorhamnetin: a flavonoid, attenuated doxorubicin-induced testicular injury via regulation of steroidogenic enzymes and apoptotic signaling gene expression in male rats. *Toxicol Res (Camb)* 2022; 11: 475-85.
- [39] Arafa EA, Elgendy NO, Elhemely MA, Abdelal-eem EA and Mohamed WR. Diosmin mitigates dexamethasone-induced osteoporosis in vivo: role of Runx2, RANKL/OPG, and oxidative stress. *Biomed Pharmacother* 2023; 161: 114461.
- [40] Gurel C, Kuscu GC, Buhur A, Dagdeviren M, Oltulu F, Karabay Yavasoglu NU and Yavasoglu A. Fluvastatin attenuates doxorubicin-induced testicular toxicity in rats by reducing oxidative stress and regulating the blood-testis barrier via mTOR signaling pathway. *Hum Exp Toxicol* 2019; 38: 1329-43.
- [41] Ahmed ZA, Abtar AN, Othman HH and Aziz TA. Effects of quercetin, sitagliptin alone or in combination in testicular toxicity induced by doxorubicin in rats. *Drug Des Devel Ther* 2019; 13: 3321-9.
- [42] Ujah GA, Nna VU, Suleiman JB, Eleazu C, Nwo-kocha C, Rebene JA, Imowo MU, Obi EO, Ama-

Reproductive protective property of diosmin

- chree C, Udechukwu EC and Mohamed M. Tert-butylhydroquinone attenuates doxorubicin-induced dysregulation of testicular cytoprotective and steroidogenic genes, and improves spermatogenesis in rats. *Sci Rep* 2021; 11: 5522.
- [43] Zi T, Liu Y, Zhang Y, Wang Z, Wang Z, Zhan S, Peng Z, Li N, Liu X and Liu F. Protective effect of melatonin on alleviating early oxidative stress induced by DOX in mice spermatogenesis and sperm quality maintaining. *Reprod Biol Endocrinol* 2022; 20: 105.
- [44] Yang HL, Hsieh PL, Hung CH, Cheng HC, Chou WC, Chu PM, Chang YC and Tsai KL. Early moderate intensity aerobic exercise intervention prevents doxorubicin-caused cardiac dysfunction through inhibition of cardiac fibrosis and inflammation. *Cancers (Basel)* 2020; 12: 1102.
- [45] Qin D, Yue R, Deng P, Wang X, Zheng Z, Lv M, Zhang Y, Pu J, Xu J, Liang Y, Pi H, Yu Z and Hu H. 8-Formyllophipogonanone B antagonizes doxorubicin-induced cardiotoxicity by suppressing heme oxygenase-1-dependent myocardial inflammation and fibrosis. *Biomed Pharmacother* 2021; 140: 111779.
- [46] Shi S, Chen Y, Luo Z, Nie G and Dai Y. Role of oxidative stress and inflammation-related signaling pathways in doxorubicin-induced cardiomyopathy. *Cell Commun Signal* 2023; 21: 61.
- [47] Anwar HM, Hamad SR, Salem GEM, Soliman RHM and Elbaz EM. Inflammatory modulation of miR-155 inhibits doxorubicin-induced testicular dysfunction via SIRT1/FOXO1 pathway: insight into the role of acacetin and *Bacillus cereus* protease. *Appl Biochem Biotechnol* 2022; 194: 5196-219.
- [48] Petrunkina AM and Harrison RA. Fluorescence technologies for evaluating male gamete (dys) function. *Reprod Domest Anim* 2013; 48 Suppl 1: 11-24.
- [49] Habib R, Wahdan SA, Gad AM and Azab SS. Infliximab abrogates cadmium-induced testicular damage and spermiotoxicity via enhancement of steroidogenesis and suppression of inflammation and apoptosis mediators. *Ecotoxicol Environ Saf* 2019; 182: 109398.
- [50] Sarma S, Derosé S, Govindarajan N, Essa MM, Qoronfleh MW, Chidambaram SB and Al-Bulushi B. Fortification methods of coenzyme Q10 in yogurt and its health functionality-a review. *Front Biosci (Schol Ed)* 2021; 13: 131-40.
- [51] Wang XM, Ma ZY and Song N. Inflammatory cytokines IL-6, IL-10, IL-13, TNF- α and peritoneal fluid flora were associated with infertility in patients with endometriosis. *Eur Rev Med Pharmacol Sci* 2018; 22: 2513-2518.
- [52] Fesahat F, Norouzi E, Seifati SM, Hamidian S, Hosseini A and Zare F. Impact of vitamin C on gene expression profile of inflammatory and anti-inflammatory cytokines in the male partners of couples with recurrent pregnancy loss. *Int J Inflamm* 2022; 2022: 1222533.
- [53] Hamed MA, Akhigbe TM, Akhigbe RE, Aremu AO, Oyedokun PA, Gbadamosi JA, Anifowose PE, Adewole MA, Aboyeji OO, Yisau HO, Tajudeen GO, Titiloye MM, Ayinla NF and Ajayi AF. Glutamine restores testicular glutathione-dependent antioxidant defense and upregulates NO/cGMP signaling in sleep deprivation-induced reproductive dysfunction in rats. *Biomed Pharmacother* 2022; 148: 112765.
- [54] Tekeli MY, Eraslan G, Çakır Bayram L and Soyer Sarıca Z. Effect of diosmin on lipid peroxidation and organ damage against subacute deltamethrin exposure in rats. *Environ Sci Pollut Res Int* 2021; 28: 15890-908.
- [55] Ichikawa Y, Ghanefar M, Bayeva M, Wu R, Khechaduri A, Naga Prasad SV, Mutharasan RK, Naik TJ and Ardehali H. Cardiotoxicity of doxorubicin is mediated through mitochondrial iron accumulation. *J Clin Invest* 2014; 124: 617-30.
- [56] Bahar O and Eraslan G. Investigation of the efficacy of diosmin against organ damage caused by bendiocarb in male Wistar albino rats. *Environ Sci Pollut Res Int* 2023; 30: 55826-45.
- [57] Renu K and Valsala Gopalakrishnan A. Deciphering the molecular mechanism during doxorubicin-mediated oxidative stress, apoptosis through Nrf2 and PGC-1 α in a rat testicular milieu. *Reprod Biol* 2019; 19: 22-37.
- [58] Mahgoub S, Sallam AO, Sarhan HKA, Ammar AAA and Soror SH. Role of Diosmin in protection against the oxidative stress induced damage by gamma-radiation in Wistar albino rats. *Regul Toxicol Pharmacol* 2020; 113: 104622.
- [59] Ojetola AA, Asiwe JN, Adeyemi WJ, Ogundipe DJ and Fasanmade AA. Dietary supplementation with D-Ribose-L-Cysteine prevents hepatic stress and pro-inflammatory responses in male wistar rats fed a high-fructose high-fat diet. *Pathophysiology* 2022; 29: 631-639.
- [60] Xu Y, Li A, Li X, Deng X and Gao XJ. Zinc deficiency induces inflammation and apoptosis via oxidative stress in the kidneys of mice. *Biol Trace Elem Res* 2023; 201: 739-50.
- [61] Li L, Qiu N, Meng Y, Wang C, Mine Y, Keast R and Guyonnet V. Preserved egg white alleviates DSS-induced colitis in mice through the reduction of oxidative stress, modulation of inflammatory cytokines, NF- κ B, MAPK and gut microbiota composition. *Food Sci Hum Wellness* 2023; 12: 312-23.

Reproductive protective property of diosmin

- [62] Oyowwi MO, Ben-Azu B, Edesiri TP, Victor E, Rotu RA, Ozegbe QEB, Nwangwa EK, Atuada V and Adebayo OG. Kolaviron abates busulfan-induced episodic memory deficit and testicular dysfunction in rats: the implications for neuroendopathobiological changes during chemotherapy. *Biomed Pharmacother* 2021; 142: 112022.
- [63] Obembe OO, Ojetola AA, Atere TG, Abayomi TA, Dare BJ, Adeyemi DH and Oyeyipo IP. Buchholzia coriacea seed induce antifertility by interfering with steroidogenic enzymes and inflammatory cytokines in rat testis. *J Reprod Immunol* 2023; 157: 103923.
- [64] Arabaci Tamer S, Yildirim A, Koroğlu MK, Çevik Ö, Ercan F and Yeğen BÇ. Nesfatin-1 ameliorates testicular injury and supports gonadal function in rats induced with testis torsion. *Peptides* 2018; 107: 1-9.
- [65] Cutolo M, Sulli A, Capellino S, Villaggio B, Montagna P, Pizzorni C, Paolino S, Serio B, Felli L and Straub RH. Anti-TNF and sex hormones. *Ann N Y Acad Sci* 2006; 1069: 391-400.
- [66] Habas K, Anderson D and Brinkworth MH. Germ cell responses to doxorubicin exposure in vitro. *Toxicol Lett* 2017; 265: 70-6.