



# Nylon Suture Loop for Tagging Lymphatic Channels during Lymphaticovenular Anastomosis

Grace Hui-Min Tan<sup>1</sup>  Jiajun Feng<sup>1</sup> Yee Onn Kok<sup>1</sup>  Pearlie Woon Woon Tan<sup>1</sup> Allen Wei-Jiat Wong<sup>1</sup> 

<sup>1</sup>Plastic, Reconstructive and Aesthetic Surgery Service, Department of General Surgery, Sengkang General Hospital, Singapore, Singapore

Indian J Plast Surg 2024;57:136–139.

Address for correspondence Allen Wei-Jiat Wong, MBBS (S'pore), MMed (Surg), FAMS (Plastic Surgery), Department of General Surgery, Plastic, Reconstructive and Aesthetic Surgery Service, Medical Centre, Level 9, 110 Sengkang East Way, Singapore 544886, Singapore (e-mail: allen.wong.wei.jiat@gmail.com).

## Abstract

### Keywords

- ▶ lymphaticovenular anastomosis
- ▶ lymphaticovenous anastomosis
- ▶ supermicrosurgery
- ▶ vessel loop
- ▶ micro-ligaclip

**Background** Lymphaticovenular anastomosis (LVA) requires special supermicrosurgery techniques designed for vessels less than 0.8 mm in size. While preparing the field for LVA, it is often difficult to handle the lymphatic vessel directly without injuring it or fracturing it entirely.

**Method** We propose a novel technique, which is used in LVA for tagging of lymphatic vessels, with the use of a nylon 6–0 suture and micro-ligaclip.

**Results** We have successfully performed 78 LVAs in 26 cases with this method. The average lymphatic vessel size was 0.3 mm (0.15–0.8 mm).

**Conclusion** This novel technique to implement the use of a nylon suture with a micro-ligaclip to use as a vessel loop for lymphatics has not been previously described in the literature. It is a useful technique that we find beneficial to lymphatic identification through tagging of the lymphatic channels, contributing to greater success in each anastomosis.

## Introduction

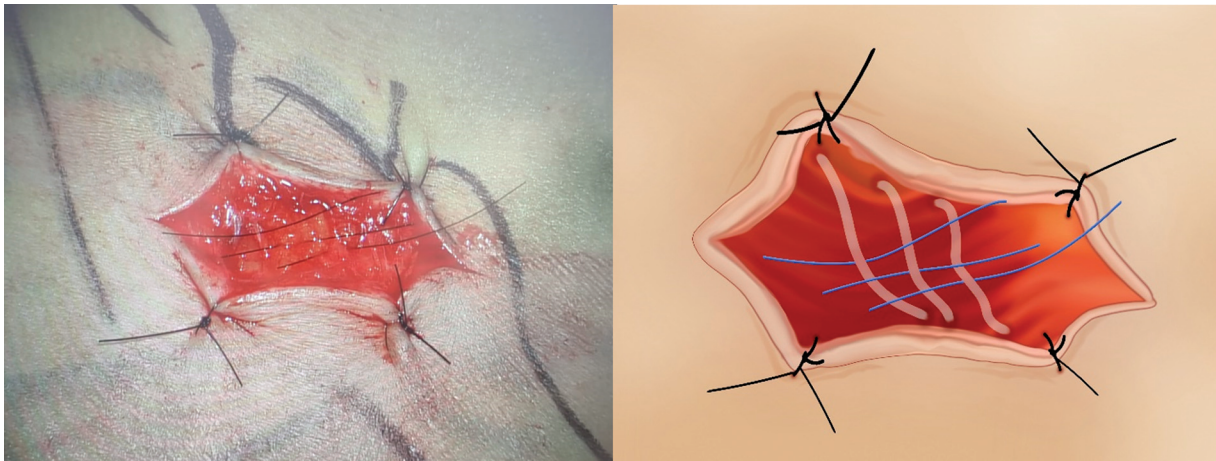
Supermicrosurgery is a term first defined by Masia et al in 2010<sup>1</sup> in which special techniques are required for vessels smaller than 0.8 mm in size. The advent of the supermicrosurgery era has allowed us to treat lymphedema from a new angle, that of lymphaticovenular anastomosis (LVA). With recent advances in imaging, microscope, and operating instruments, such as ultrasound-guided LVA, indocyanine green (ICG) videolymphography,<sup>2,3</sup> we can now identify finer lymphatics and perform LVA on vessel calibers that were once thought impossible. The prerequisite for performing an LVA is a good eye for identification of the lymphatic vessel and vein. As lymphatic vessels can be notoriously translu-

cent, the search for one adds to the complexity of the surgery. Having to find a vein that is of a good match to set the stage for a successful LVA is another. As the vessels become smaller in size, the ability of the surgeon to manipulate the vessel in an atraumatic manner also becomes harder. Repetitive grasping can lead to fracturing of the vessel, forcing the surgeon to commit to a short length for anastomosis, or even abandon it altogether. In routine microsurgery, vessel loops that are 0.8 mm in diameter are used to manipulate vessels atraumatically. However, such silicone loops are too big to use on lymphatic vessels. Hence, we propose a novel technique of using a nylon suture as a vessel loop that can be used to tag the lymphatic channels, to simplify the process of lymphatic vessel identification during surgery.

article published online  
February 2, 2024

DOI <https://doi.org/10.1055/s-0044-1779477>.  
ISSN 0970-0358.

© 2024. Association of Plastic Surgeons of India. All rights reserved. This is an open access article published by Thieme under the terms of the Creative Commons Attribution-NonDerivative-NonCommercial-License, permitting copying and reproduction so long as the original work is given appropriate credit. Contents may not be used for commercial purposes, or adapted, remixed, transformed or built upon. (<https://creativecommons.org/licenses/by-nc-nd/4.0/>)  
Thieme Medical and Scientific Publishers Pvt. Ltd., A-12, 2nd Floor, Sector 2, Noida-201301 UP, India



**Fig. 1** Nylon 6-0 sutures placed under the lymphatic vessel (blue lines).

## Method

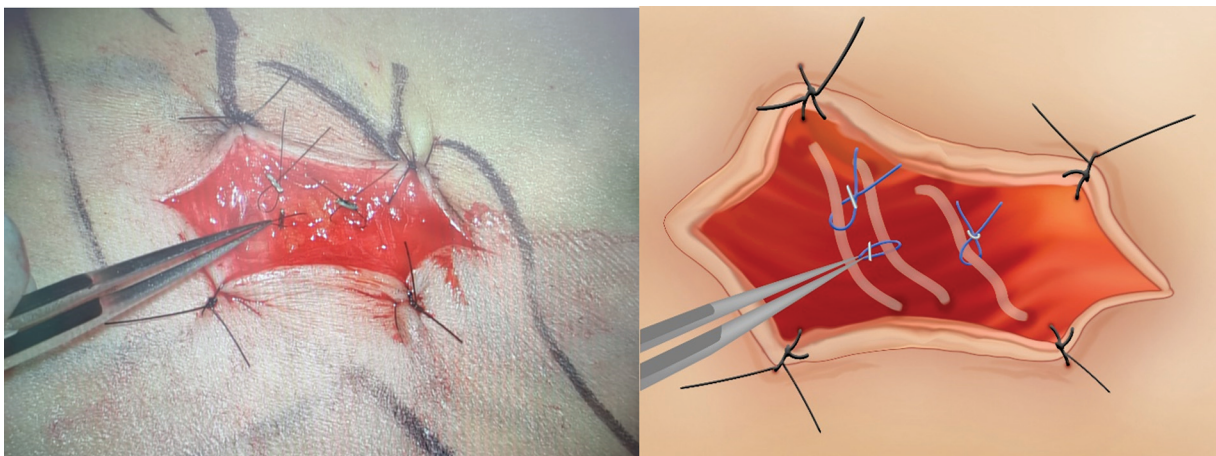
We collected retrospective data of all patients who underwent LVA in our center from June 2020 to December 2021 in this case series, whether primary or secondary LVA, when the main surgeon started utilizing this technique during LVA.

This method was used by the senior author in all his LVA cases. When a potential lymphatic vessel has been identified, a nylon 6-0 suture is used to loop around the vessel, and cut to a length of approximately 1.5 cm (→**Fig. 1**). To secure and fix the loop, both ends of the suture is secured together with a micro-ligaclip (→**Fig. 2**). Thus, the loop encircles the lymphatic vessel (→**Fig. 3**). This is done with caution such that the lymphatic vessel is not injured or twisted by accident. By holding the loop with the Jeweller's forceps, the surgeon does not have to directly grasp the lymphatic vessel to manipulate it, hence minimizing trauma and unwanted transection. After identifying all the lymphatic vessels and veins, the surgeon decides which lymphatic vessel and vein is the best, and the LVA is then performed. The success of the LVA is determined by direct visualization of clear lymphatic fluid from the lymphatic vessel into the venule. At times when the lymphatic fluid flow is not clear, ICG lymphogra-

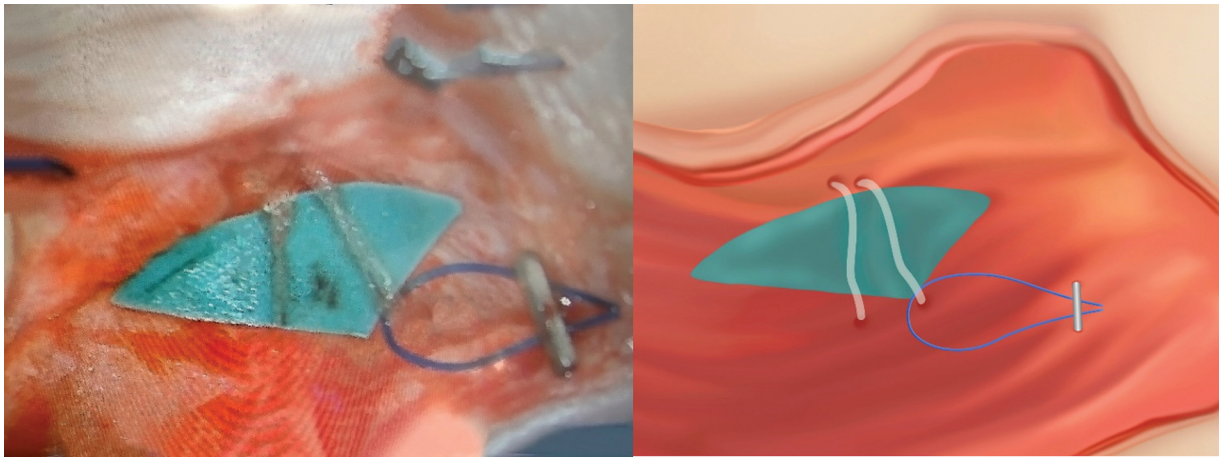
phy was performed with our microscope to determine the patency of the anastomosis.

## Results

We included a total of 26 patients, with 78 LVAs, from June 2020 to December 2021. All of these patients were females with breast cancer. The senior author performed prophylactic LVA for the patients who underwent axillary clearance. ICG was injected into the webspace of the digits of the ipsilateral hand of the axillary clearance performed. The lymphatic vessels are then mapped out on the arm with a marker pen. The senior author then performed LVAs in the forearm or upper arm depending on where the lymphatic vessel was located. The mean age of the patients was 54 years (range: 35–79 years). The body mass index of these patients was 25.2 (range: 18.7–33.8). The average lymphatic vessel size was 0.3 mm (0.15–0.8 mm). →**Table 1** shows the type of breast surgery and the location of the LVAs performed in patients who underwent breast surgery. All LVAs have been shown to be patent either by direct visualization of lymphatic fluid into the vein or with the use of ICG after the initial anastomosis has been performed.



**Fig. 2** Jeweller's forceps point to the micro-ligaclip that is used to secure the ends of the nylon suture. Three vessel loops are shown in the picture.



**Fig. 3** Vessel loop encircling the lymphatic vessel.

## Discussion

The use of vessel loops in plastic surgery has a myriad of uses. This ranges from identification of vessels, nerves, or tendons, atraumatic retraction on perforators during dissection to even closure of fasciotomy wounds with the use of larger vessel loops.<sup>4</sup>

When searching for and identifying lymphatic vessels, care should be undertaken to minimize direct handling of the lymphatic itself to avoid injury to the vessel. Any injury to the lymphatic vessel can result in damage, which may then preclude the use of the lymphatic vessel in LVA. The smallest diameter of vessel loops that are available commercially is  $0.8 \times 406$  mm (Aspen Surgical, United States). In addition, the vessel loops are heavier; hence, the pure mass of the vessel loops may cause the lymphatic vessel to fracture, whereas the nylon suture is not as thick. As such, these vessel loops are not ideal to be used to tag the lymphatics due to the high risk of injury to the vessel. Thus, the use of nylon suture as a vessel loop to improve the visibility of the lymphatic will aid in the overall operation.

This novel technique of creating a vessel loop with the use of a nylon 6-0 suture and micro-ligaclip has been employed by the main surgeon for 90 LVAs in 30 cases, and has been shown to be successful. The patency of each LVA was checked

by visualization of the flow of clear lymphatic fluid into the vein or through the use of ICG.

The use of this technique is meant to identify and simplify the manipulation of the lymphatic vessel. Lymphatic vessels can be notoriously translucent, so this technique is used to “tag” the lymphatic vessel for easy identification. Using this technique, the surgeon does not have to worry about not being able to find the previously identified lymphatic, and can proceed to look for other lymphatics for the LVA. When all the potential lymphatic vessels and veins have been identified, the surgeon can select the best match. This is akin to performing an inventory of available lymphatic vessels and venules, and streamlines the process of identifying structures that we can go back to later. Much like the management of the spaghetti wrist, tagging structures saves time and minimizes the need to go back to search for it.<sup>5</sup>

This technique is also used to allow manipulation of the lymphatic vessel during the surgery. Gentle traction on the vessel during LVA helps provide the necessary tension on the vessel to identify the lumen before the anastomosis.

However, the authors do acknowledge that it may be difficult to attribute the success of the patency of the LVA solely to the use of this technique as there are many factors such as surgeon’s expertise and tissue handling that may affect the end result of the anastomosis. Also, the use of our

**Table 1** Demographics of patients

Type of surgery	Location of LVA	No. of patients	No. of anastomoses performed
Skin sparing mastectomy	Left upper limb	9	26
	Right upper limb	10	31
Nipple sparing mastectomy	Left upper limb	2	5
	Right upper limb	2	6
Lumpectomy	Right upper limb	1	3
Chest wall resection	Left upper limb	2	7
Total		26	78

technique for lymphatic handling requires practice, as placing the suture and using the micro-ligaclip to create the loop can result in more damage than good if the vessel is not handled well. Also, use of silicone loops for lymphatic identification has been described in the literature,<sup>6</sup> but not with the use of nylon suture, which is smaller and more delicate for the fragile lymphatic vessel.

## Conclusion

This novel technique to implement the use of a nylon suture with a micro-ligaclip to use as a vessel loop for lymphatics has not been previously described in the literature. It is a useful technique that we find beneficial for identification of the lymphatics, so as to select the best matched lymphatic vessel to set the stage for a successful LVA. This technique also aids in careful manipulation of the vessel to reduce lymphatic injury. All of these benefits contribute to a successful LVA.

### Authors' Contributions

G.H.-M.T. contributed to the investigation, resources, data curation, writing of the original draft, review, and editing, visualization, and project administration. J.F. contributed to the methodology, validation, investigation, resources, visualization, and supervision. Y.O.K. contributed to the methodology, validation, investigation, resources, visualization, and supervision. T.W.W.P. contributed to the investigation, resources, visualization, and supervision. A.W.-J.W. contributed to the conceptualization, method-

ology, visualization, validation, investigation, resources, writing of the original draft, review, and editing, visualization, supervision, and project administration.

### Informed Consent

Written informed consent was obtained from the patient to publish this report in accordance with the journal's patient consent policy.

### Conflict of Interest

None declared.

## References

- 1 Masia J, Olivares L, Koshima I, et al. Barcelona consensus on supermicrosurgery. *J Reconstr Microsurg* 2014;30(01):53–58
- 2 Hara H, Mihara M. Ultrasound-guided lymphaticovenous anastomosis without indocyanine green lymphography mapping: a preliminary report. *Microsurgery* 2023;43(03):238–244
- 3 Seki Y, Kajikawa A, Yamamoto T, Takeuchi T, Terashima T, Kurogi N. Real-time indocyanine green videolymphography navigation for lymphaticovenular anastomosis. *Plast Reconstr Surg Glob Open* 2019;7(05):e2253
- 4 Singh H, Khazanchi RK, Aggarwal A, Mahendru S, Brajesh V, Singh S. Uses of vessel loops in plastic surgery. *Indian J Plast Surg* 2018; 51(01):103–105
- 5 Meals CG, Chang J. Ten tips to simplify the spaghetti wrist. *Plast Reconstr Surg Glob Open* 2018;6(12):e1971
- 6 Ito R, Wu CT, Lin MC, Cheng MH. Successful treatment of early-stage lower extremity lymphedema with side-to-end lymphovenous anastomosis with indocyanine green lymphography assisted. *Microsurgery* 2016;36(04):310–315