

# Short bowel syndrome: a nutritional and medical approach

Khursheed N. Jeejeebhoy

## Case

A 40-year-old woman with a history of Crohn's disease presents with a 3-week history of intermittent abdominal pain, about 8 watery bowel movements a day and weight loss of 8 kg from her baseline weight of 50 kg. Three years previously, she required surgical intervention for a small bowel obstruction, and on that occasion about 130 cm of ileum and 30 cm of the colon were resected. She recovered from this surgery and gained weight, and she has been taking 5-amino salicylic acid, 4 g/day, to prevent a recurrence of her inflammatory bowel disease. You decide to admit the patient for investigation and treatment of a possible recurrence of her Crohn's disease. An upper gastrointestinal series with small bowel follow-through reveals multiple small intestinal strictures with dilatation of the small bowel between these strictures. In order to control the progression of the disease, the patient was prescribed prednisone starting at 40 mg/day and tapered by 5 mg/week. In addition, azathioprine, 100 mg/day, was started concurrently to allow withdrawal of the prednisone, but the patient develops vomiting, abdominal distension and worse abdominal pain and is judged to be suffering from a bowel obstruction. She is taken to the operating room, where another 120 cm of bowel are resected. After this surgery, she develops profuse, watery diarrhea after eating or drinking anything. How do you explain to her the origin of her diarrhea? Which vitamins and minerals could you expect her to be deficient in? From a nutritional perspective, what can be done to help minimize her diarrhea?

The normal adult small intestine is about 400 cm in length and consists of the duodenum, 25–30 cm, and the jejunum, 160–200 cm, and the rest is the ileum. Most carbohydrate and protein absorption takes place in the duodenum and jejunum, and the ileum is responsible for absorbing fats bound to bile salts (secreted by the liver), fat-soluble vitamins and vitamin B<sub>12</sub> (bound to intrinsic factor secreted by the stomach). Most fluids and electrolytes are absorbed in the ileum and the large intestine. Normally, 2–3 L of ingested food and water, on top of 7–9 L of secreted fluid, are absorbed per day in the distal gastrointestinal tract.

Short bowel syndrome occurs after extensive small bowel resection disturbs the normal absorptive processes for nutrients and fluids. It occurs most commonly following resections of the terminal ileum (such as in Crohn's disease or postradiation enteritis), massive intestinal resection of infarcted bowel (due to compromised blood supply) and gastric bypass surgery as a therapy for weight loss. Common pediatric causes of short bowel syndrome include resections after episodes of necrotizing enterocolitis and repair of a volvulus.

The symptoms of short bowel syndrome are often evident in the immediate postoperative period and include profuse watery diarrhea exacerbated by oral intake. There are short-term and long-term problems with malabsorption, leading to disruptions in fluid balance, weight loss, anemia and vitamin deficiencies. A better understanding of the relative sites of absorption for different nutrients can

help determine the deficiencies that occur with malabsorption (Fig. 1) and explain the stepwise therapeutic and nutritional management approach proposed here (Table 1).

## Predicting changes in intestinal function after bowel resection

A first step in approaching patients with short bowel syndrome is to determine to what extent the site and extent of the surgery may induce diarrhea, malabsorption and malnutrition. Diarrhea and malnutrition related to short bowel syndrome are caused by malabsorption, changes in gastric motility and the ability of other sections of the intestine to compensate for the resected parts. The site and extent of the resection will also affect whether the patient will require nutritional supplementation.

Small intestine resections involving the loss of more than 100 cm of ileum frequently lead to severe problems with malabsorption. Unabsorbed bile salts enter the colon and stimulate fat and water secretion, which results in diarrhea. In addition, bile salt deficiency leads to fat malabsorption, which also contributes to the patient's diarrhea in the form of steatorrhea.<sup>1</sup> Such patients can be managed with a low-fat diet and a bile salt-binding resin, such as cholestyramine. It is often not necessary to perform any investigations when this scenario develops immediately after

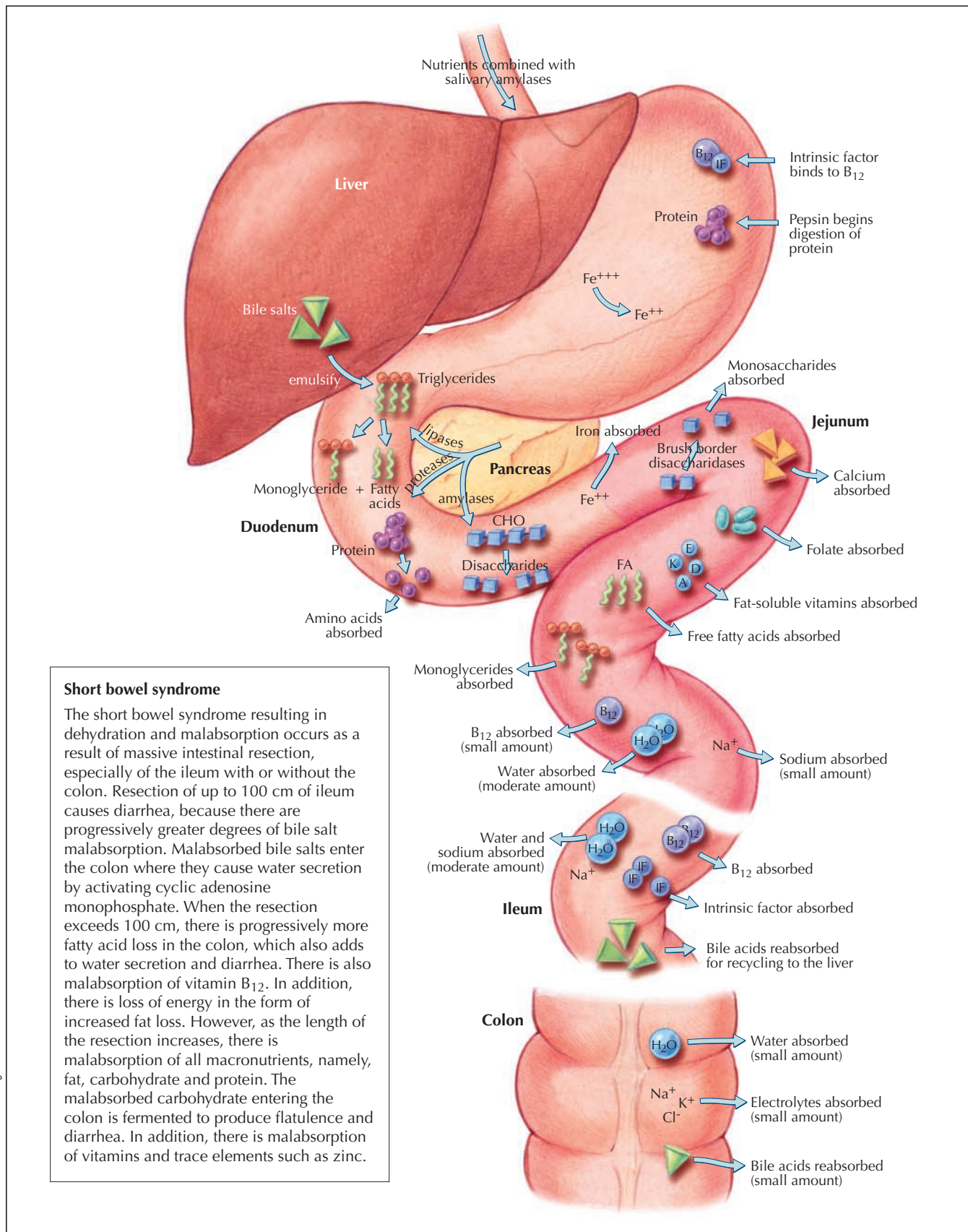


Fig. 1: The relative locations of digestion and absorption of nutrients in the healthy gastrointestinal tract. CHO = carbohydrate.

resection, because clinical recurrence of Crohn's disease is unusual within 2–4 weeks after intestinal resection.

Any significant small intestinal resection increases gastric motility,<sup>2</sup> but the consequences of this depend on the site as well as the extent of the resection. Proximal (jejunal) resection does not increase the rate of intestinal transit, because the remaining ileum continues to absorb bile salts and thus only a small amount reaches the colon to impede salt and water resorption.<sup>3</sup> When the ileum is resected, the colon receives a much larger load of fluid and electrolytes and also receives bile salts, which reduce its ability to absorb salt and water, resulting in diarrhea. In addition, if the colon is resected the patient's ability to maintain fluid and electrolyte homeostasis is severely impaired. In patients with a short bowel and without a colon, a marker taken by mouth will be completely excreted in a few hours.<sup>4</sup>

As with malabsorption and diarrhea, the likelihood and severity of malnutrition that occurs after intestinal resection is determined by the location and extent of intestinal resection. Despite the important role in nutrient absorption played by the jejunum, especially with regard to fat absorption, if the jejunum alone is removed, malabsorption and energy malnutrition do not seem to occur. This is because the intact ileum assumes what is normally the jejunum's function of fat absorption. In contrast, even a loss of a 100 cm of ileum causes steatorrhea.<sup>1</sup> The degree of malabsorption increases and the variety of nutrients malabsorbed increases with the length of the resection.<sup>5,6</sup> Balance studies of energy absorption after total ileal and partial jejunal resection leaving between 30 and 100 cm of small bowel show that the absorption of fat and carbohydrate is

reduced to between 50% and 75% of intake.<sup>7</sup> However, nitrogen absorption is not as severely affected and remains approximately 80% of intake. The degree of absorption of calcium, magnesium, zinc and phosphorus is reduced, but the extent of malabsorption does not correlate well with the remaining length of bowel. In my experience, the situation of total ileal and partial jejunal resection will require parenteral nutrition, especially for the provision of electrolytes and divalent ions (as oral intake is often sufficient for meeting a patient's energy and nitrogen requirements). A review of the literature published before the availability of parenteral nutrition shows that distal (from the ileocecal valve upward) resections of up to 33% of the small bowel length result in no protein–energy malnutrition. Resections of up to 50% may be tolerated without nutritional support, but those in excess of 75% will predictably require parenteral nutritional support to avoid severe malnutrition.

It would be reasonable to expect that preservation of the ileocecal valve would improve absorption by delaying the transit of intestinal contents. However, this concept has not been supported by experimental evidence. Fich and colleagues<sup>8</sup> showed that removal of the valve while leaving the small bowel intact does not alter intestinal transit, because the valve plays a minor role in controlling intestinal transit.

Thus, the approach to the patient with small bowel syndrome is dependent upon the extent of the resection. Other important factors include the presence of continuing intestinal disease that reduces the functional length of the intestine and the amount of time it takes for the intestine to adapt to its required change in function. The progress of the patient with time will lead to modifications of therapy.

**Table 1: A stepwise medical and dietary approach to managing short bowel syndrome**

Patient has had surgery leading to resection of segments of the small intestine	
Step 1	Determine the location of the intestine that was resected and the amount in order to estimate the likelihood of diarrhea, malabsorption and malnutrition: <ul style="list-style-type: none"> <li>• resection of large sections of jejunum is well tolerated (as long as the terminal ileum is intact)</li> <li>• resection of only 100 cm of terminal ileum results in severe malabsorption, diarrhea and eventually malnutrition</li> </ul>
Step 2	Replace fluid losses and manage the diarrhea: <ul style="list-style-type: none"> <li>• have the patient take nothing by mouth in the immediate postoperative period</li> <li>• give the patient fluids intravenously in the immediate postoperative period to replace sodium, potassium and magnesium, eventually switching to oral intake</li> <li>• reduce gastric hypersecretion with proton pump inhibitors</li> <li>• slow gastric transit with opioid medications such as loperamide or codeine, or combinations of opioids and anticholinergics (such as Lomotil)</li> </ul>
Step 3	Select appropriate oral nutrition: General principle is to maximize the energy content from fats and carbohydrate (without worsening the diarrhea) and maximize the nitrogen content; diet should be lactose free <ul style="list-style-type: none"> <li>• patients should receive carbohydrate–electrolyte feeds composed of glucose, 100 mmol/L, sodium chloride, 60 mmol/L, and sodium citrate, 60 mmol/L, and sodium chloride tablets, 10–15 g</li> </ul>
Step 4	Replace specific mineral and vitamin deficiencies: <ul style="list-style-type: none"> <li>• Zinc</li> <li>• Potassium</li> <li>• Magnesium</li> <li>• Vitamins A, B<sub>12</sub>, D, E, K</li> </ul>

## Management of diarrhea in the patient with short bowel syndrome

A key step in the management of short bowel syndrome is the replacement of the fluid losses and control of the diarrhea. Diarrhea is typically profuse and is caused by a combination of increased secretions and increased motility and osmotic stimulation of water secretion due to malabsorption of intestinal luminal contents. Initially, diarrhea is controlled by having the patient take nothing by mouth to reduce any osmotic component. Gastric hypersecretion occurs immediately after intestinal resection and tends to be transient, but in some patients leads to peptic ulceration. Treatment with proton pump inhibitors is routine in the immediate postoperative period using pantoprazole intravenously, given as an 80-mg bolus followed by an infusion at 8 mg/hour. On resumption of oral intake, proton pump inhibitors are given orally twice a day as omeprazole, 20 mg, lansoprazole, 30 mg, or pantoprazole, 40 mg, to suppress hypersecretion. In addition, loperamide, 2–12 tablets, can be used to slow gastric and intestinal transit to 1–3 bowel movements per day. If loperamide does not work, then codeine or diphenoxylate-atropine (Lomotil) may be used.<sup>9</sup> Intravenous fluids will be required to replace fluid and electrolyte losses in the immediate postoperative period. In general, replace gastric juice losses with normal saline, pancreatic and upper small bowel losses with a mixture 4:1 of normal saline: sodium lactate or sodium acetate. Add about 20 mmol/L of potassium and 7–10 mmol/L of magnesium sulfate. Sodium and potassium chloride as well as magnesium are the most important ions to be replaced; their serum concentrations will require frequent (daily) monitoring. Fluid is infused according to measured losses and to maintain an adequate urine output. The infusion is tapered as oral intake is increased.

### Selecting the appropriate oral nutrition

After managing the diarrhea and fluid losses, the next major concern is determining the nature of oral feeds that the patient will require and will be best tolerated. In patients who have little small bowel, that is, no ileum and about 60 cm of jejunum, the initial target should be small-volume isotonic feeds containing a glucose–electrolyte content similar to oral rehydration solution. The composition of this solution should be glucose, 100 mmol/L, with sodium chloride, 60 mmol/L, and sodium citrate, 60 mmol/L.<sup>10</sup> It has been shown that fluid absorption improves with increasing sodium concentration. Furthermore, in order to provide sufficient sodium to absorb dietary carbohydrate, it is necessary to ingest 10–15 g of sodium chloride as tablets with meals. Such a regimen avoids osmotic stimulation of secretion and yet stimulates the bowel to absorb, thus promoting adaptation.

In patients with intermediate lengths of small bowel, that is, less than 100 cm of jejunum as the only small bowel remaining, dietary intake and fluids cause increased fluid loss.<sup>11</sup> For these patients, progressive feeding should be attempted with the following plan. The same carbohydrate–electrolyte feeds as described for patients with little small bowel should be started. A mixture of a similar composition has been shown to be well absorbed by patients with massive resection who have previously been dependent on intravenous fluids. The diet should be lactose free, because lactase levels in patients with short bowel syndrome are reduced.<sup>12</sup>

Although physicians often try a defined formula diet in these patients, studies by McIntyre and colleagues<sup>13</sup> have shown that this is not absorbed better than a solid diet. Early observations had suggested that a low-fat diet with added medium-chain triglycerides together with a high carbohydrate content was better for patients with a short bowel. The theory behind these suggestions was the finding that malabsorbed long-chain fatty acids can cause colonic water secretion, resulting in higher fecal output with steatorrhea and consequently greater loss of divalent ions. However, such studies were not controlled, and medium-chain triglycerides can also cause osmotic diarrhea. The results of 2 controlled crossover studies<sup>4,7</sup> showed that a high-fat diet was comparable to a high-carbohydrate diet with regard to total fluid, energy, nitrogen, sodium, potassium and divalent ion absorption. I therefore recommend a low-lactose diet containing high-energy intake from both fat and carbohydrate and a high nitrogen intake. For adults who require about 30 kcal/kg per day (125 kJ/kg per day), we aim to increase intake gradually to about 60 kcal/kg per day (251 kJ/kg per day) to provide sufficient absorbed energy despite malabsorption. Balance studies have shown that as the intake is increased, the absolute intake of energy is proportionately increased.<sup>14</sup> Therefore, the objective is to induce hyperphagia to permit the absorbed energy to meet requirements.<sup>7,14</sup> In patients who have more than 100 cm of jejunum left, refeeding should be progressive following the principles outlined here with a view ultimately to feeding a normal oral diet.

In general, most patients with a short bowel can be managed with an oral diet and appropriate fluid and electrolyte management.

### Replacing specific deficiencies: minerals and vitamins

There are several nutrients that patients with short bowel syndrome can become deficient in, including zinc, potassium, magnesium and vitamins absorbed in the resected sections of intestine. The serum zinc concentration is neither a sensitive nor a specific indicator of zinc deficiency, although a reduced concentration (in the context of

normal serum albumin) suggests deficiency. Zinc intake is estimated on the basis of the volume of stool or stomal output. The losses are about 12 mg/L of output and because the absorption of zinc in these patients is about 30% of intake, patients should receive 36–40 mg of zinc gluconate by mouth per litre of output, or 50–100 mg/day.

Potassium gluconate may be added to a concentration of 12 mmol/L in the carbohydrate–electrolyte fluid. In addition, I have found that magnesium heptogluconate (Magnesium-Rougier) in doses of 30 mmol/L may be added to the glucose–electrolyte mixture and sipped over the course of the day. I recently found that magnesium pyroglutamate (Mag 2) was more effective in increasing serum and urine magnesium in patients with a short bowel without causing diarrhea. Unfortunately, this product is no longer available in Canada, although it is available in Europe and the United Kingdom.

Many patients will not be able to tolerate or may not be able to absorb sufficient amounts of magnesium to meet their requirements and losses. Under the circumstances, serum magnesium often remains low and severe magnesium deficiency can develop. The only way to treat this problem is to insert a central venous catheter and give infusions of magnesium as required. In my experience, these patients often can be treated 2 or 3 times a week with an infusion of magnesium sulfate in normal saline.

Except for vitamin B<sub>12</sub>, which requires an intact stomach (for intrinsic factor) and ileum (to absorb the intrinsic factor–B<sub>12</sub> complex), patients with a short bowel can absorb the water-soluble vitamins. Vitamin B<sub>12</sub> absorption should be measured and, if subnormal, injections of 200 µg per month should be started. Patients have difficulty absorbing fat-soluble vitamins possibly because of the lack of bile salts and loss of absorptive surface. Hence, they require large doses of vitamins A, D and E to avoid deficiency. Liquid preparations are necessary, because tablets or capsules are typically excreted intact. I recommend the measurement of these vitamin levels and supplementation with vitamin A, 10 000 IU/day, 1,25 dihydroxy-vitamin D (calcitriol), 0.25–1.0 µg/day, and vitamin E, 1200 IU/day, with the aim of normalizing plasma levels. The dose of calcitriol must be titrated to avoid hypercalciuria. Normalization may not be possible with oral vitamins in some individuals, especially vitamin E.

## Late complications after massive small bowel resection

### *Cholelithiasis*

After ileal resection, there is interruption of the enterohepatic cycle of bile salts. Bile salt loss then exceeds the capacity of the liver to increase synthesis, and the bile salt concentration in bile falls. The reduction of the concentration of chenodeoxycholate in the bile increases cholesterol

secretion, a combination of events that makes the bile lithogenic. Clinically, in this situation, an increased incidence of gallstones has been observed. Recently, a study in experimental animals has shown an increased incidence of pigment stones.<sup>15</sup>

### *Renal stones*

Hyperoxaluria occurs both in patients with an ileal resection and in patients with a short bowel who have had a distal small bowel resection. It is caused by increased absorption of oxalate by the colon. Bile salts in the colon increase oxalate absorption. Hyperoxaluria is associated with renal stone formation, and the propensity to form stones is reduced when citrate intake is reduced. Treatment involves having a low-oxalate diet and taking cholestyramine to bind bile salts and citrate to prevent stone formation. Low-oxalate diets typically exclude cocoa, peanut products, tea, coffee, wheat germ, rhubarb, beets, collards, spinach, tofu and soybeans and restrict citrus drinks, tomatoes and fruit.<sup>16</sup>

### *D-lactic acidosis*

Some patients with a short bowel have episodes of a syndrome of slurred speech, ataxia and altered affect. Superficially, the patient appears to be “drunk.” The cause of this syndrome is fermentation of malabsorbed carbohydrate in the colon to D-lactate and absorption of this metabolite.<sup>17</sup> An illustrative example of this is a man aged 40 years who had 30 cm of remaining jejunum connected to an intact colon following an intestinal infarct. After being on total parenteral nutrition at home for 5 years, he presented to hospital with a history of incoherent speech and ataxia during which his sister accused him of being drunk. His condition resolved after he was placed on a diet involving restricted carbohydrate intake and metronidazole.

## The case revisited

This patient still had most of her colon and about 150 cm of residual small bowel, some of which was diseased. The short bowel is the cause of her diarrhea. Along with medical management of her Crohn’s disease, her initial therapy included intravenous fluid resuscitation and electrolyte and vitamin (including magnesium and zinc) supplementation, and treatment with proton pump inhibitors and loperamide was instituted. She continued to take regular food by mouth, supplemented with fat-soluble vitamins, including calcitriol. The volume of postprandial diarrhea decreased greatly, and the patient was soon able to tolerate a normal, low-oxalate diet, eating solid foods 30 minutes before fluids. She was able to maintain normal serum magnesium levels by adding magnesium heptogluconate to the glucose–electrolyte mixture and sipping this slowly over the course of the day.

This article has been peer reviewed.

Dr. Jeejeebhoy is with St. Michael's Hospital and the Department of Medicine, University of Toronto, Toronto, Ont.

Competing interests: None declared.

## References

- Hoffman AF, Poley JR. Role of bile acid malabsorption in the pathogenesis of diarrhea and steatorrhea in patients with ileal resection. I. Response to cholestyramine or replacement of dietary long-chain triglycerides by medium-chain triglycerides. *Gastroenterology* 1972;62:918-34.
- Nylander G. Gastric evacuation and propulsive intestinal motility following resection of the small intestine in the rat. *Acta Chir Scand* 1967;133:131-8.
- Booth CC, Aldis D, Read AE. Studies on the site of fat absorption. 2. Fat balances after resection of varying amounts of small intestine in man. *Gut* 1961; 2:168-74.
- Woolf GM, Miller C, Kurian R, Jeejeebhoy KN. Diet for patients with a short bowel: High fat or high carbohydrate? *Gastroenterology* 1983;84:823-8.
- Hylander E, Ladefoged K, Jarnum S. Nitrogen absorption following small intestinal resection. *Scand J Gastroenterol* 1980;15:853-8.
- Ladefoged K, Nicolaidou P, Jarnum S. Calcium, phosphorus, magnesium, zinc and nitrogen balance in patients with severe short bowel syndrome. *Am J Clin Nutr* 1980;33:2137-44.
- Woolf GM, Miller C, Kurian R, Jeejeebhoy KN. Nutritional absorption in short bowel syndrome: evaluation of fluid, calorie, and divalent cation requirements. *Dig Dis Sci* 1987;32:8-15.
- Fich A, Steadman CJ, Phillips SF, Camilleri M, Brown ML, Haddad AC, et al. Ileocolonic transit does not change after right hemicolectomy. *Gastroenterology* 1992;103:794-9.
- Nightingale JM. Management of patients with a short bowel. *Nutrition* 1999; 15:633-7.
- McIntyre PB, Wood SR, Powell-Tuck J, Lennard-Jones JE. Nocturnal nasogastric tube feeding at home. *Postgrad Med J* 1983;59(698):767-9.
- Nightingale JM, Lennard-Jones JE, Walker ER, Farthing MJ. Jejunal efflux in short bowel syndrome. *Lancet* 1990;336:765-8.
- Richards AJ, Condon JR, Mallinson CN. Lactose intolerance following extensive small intestinal resection. *Br J Surg* 1971;58:493-4.
- McIntyre PB, Fitchew M, Lennard-Jones JE. Patients with a high jejunostomy do not need a special diet. *Gastroenterology* 1986;91:25-33.
- Jeppesen PB, Mortensen PB. Intestinal failure defined by measurements of intestinal energy and wet weight absorption. *Gut* 2000;46:701-6.
- Mok KT. Hepatobiliary complications in healthy, intra-abdominally infected, and high-output fistula rats receiving total parenteral nutrition. *JPEN J Parenter Enteral Nutr* 1993;17(5):449-53.
- Morton AR, Iliescu EA, Wilson JW. Nephrology: 1. Investigation and treatment of recurrent kidney stones. *CMAJ* 2002;166(2):213-8. Available: [www.cma.ca/cgi/content/full/166/2/213](http://www.cma.ca/cgi/content/full/166/2/213)
- Hudson M, Pocknee R, Mowat NA. D-lactic acidosis in short bowel syndrome—an examination of possible mechanisms. *Q J Med* 1990;74(274):157-63.

**Correspondence to:** Dr. Khurshed N. Jeejeebhoy, Rm. 041B, 16th floor, Victoria Wing, St. Michael's Hospital, 30 Bond St., Toronto ON M4V 2V5; fax 416 864-5882; [khush.jeejeebhoy@utoronto.ca](mailto:khush.jeejeebhoy@utoronto.ca)

## A CMAJ Call for Medical Images: Clinical Vistas

### Send us your interesting clinical images!

Through scopes and scanners, on film and computer screens, with ultrasonography and microscopy, clinicians capture stunning images of illness and healing. *CMAJ* invites you to share your normally privy visual perspectives on anatomy, pathology, diagnostic procedures and therapeutic techniques. Let colleagues outside your specialty take a close look at the characteristic signs of rare conditions (Kayser-Fleischer rings in Wilson's disease) or the interior marvels of your clinical terrain (colonoscopic view of an adenomatous polyp). We're also interested in images that take a wider angle on the context of care (a recently cord-clamped newborn on a cold steel scale). If you have original, unpublished images that are beautiful or informative, rare or classic, we'd like to include them in *CMAJ's* Clinical Vistas.

### Send your images or queries to:



Editorial Fellow • Canadian Medical Association Journal  
1867 Alta Vista Drive • Ottawa ON K1G 3Y6 Canada  
or email [pubs@cma.ca](mailto:pubs@cma.ca)