




RESEARCH ARTICLE

REVISED **An investigation of syrinx morphometry and sound frequency association in lovebirds (*Agapornis fischeri*) chirps**
[version 3; peer review: 2 approved]

Previously titled: An investigation of syrinx morphometry and sound frequency association during the chirping period in lovebirds (*Agapornis fischeri*)

Cytra Meyliana Surya Dewi^{1,2}, Yeni Dhamayanti², Faisal Fikri^{1,3}, Agus Purnomo⁴, Shafia Khairani⁵, Shekhar Chhetri⁶, Muhammad Thohawi Elziyad Purnama ^{1,2}

¹School of Health and Life Sciences, Universitas Airlangga, Surabaya, 60115, Indonesia

²Division of Veterinary Anatomy, Department of Veterinary Science, Faculty of Veterinary Medicine, Universitas Airlangga, Surabaya, 60115, Indonesia

³Division of Veterinary Clinical Pathology and Physiology, Department of Veterinary Science, Faculty of Veterinary Medicine, Universitas Airlangga, Surabaya, 60115, Indonesia

⁴Department of Veterinary Surgery and Radiology, Faculty of Veterinary Medicine, Universitas Gadjah Mada, Yogyakarta, 55281, Indonesia

⁵Department of Biomedical Science, Faculty of Medicine, Universitas Padjajaran, Bandung, 45363, Indonesia

⁶Department of Animal Science, College of Natural Resources, Royal University of Bhutan, Lobesa, Punakha, 13001, Bhutan

V3 **First published:** 24 Mar 2022, 11:354
<https://doi.org/10.12688/f1000research.108884.1>
Second version: 20 Jan 2023, 11:354
<https://doi.org/10.12688/f1000research.108884.2>
Latest published: 22 May 2024, 11:354
<https://doi.org/10.12688/f1000research.108884.3>

Abstract

Background




In the issue of biodiversity, the domestication of birds as pets and trade animals requires special attention as a conservation effort. Lovebirds (*Agapornis fischeri*) are popular birds worldwide, due to their varied ornamentation and melodic chirping sound. Syrinx structure is suspected to be the main source of sound production during the chirping period. This study aimed to investigate syrinx morphometry and its correlation with sound frequency produced in lovebirds.


Methods

A total of 24 lovebirds of different ages and gender were investigated. Polymerase chain reaction method was performed to determine lovebird gender, meanwhile bird age was identified based on post-

Open Peer Review

Approval Status  

	1	2
version 3 (revision) 22 May 2024		
version 2 (revision) 20 Jan 2023	 view	 view
version 1 24 Mar 2022	 view	

1. **Abdulmojeed Yakubu** , Nasarawa State University, Lafia, Nigeria

2. **Abdul Razak Alimon**, Putra Malaysia University, Serdang, Malaysia

Any reports and responses or comments on the

hatch recordings at the breeding farm. Thus, we enrolled male (n=12) and female (n=12) lovebirds aged 2 (n=4), 3 (n=4), and 4 (n=4) months in the investigation group, respectively. Fast Fourier Transform (FFT) was performed to evaluate sound frequency during chirping period. Then, syrinx morphometry was identified using a topographic approach and methylene blue staining. Each variable was evaluated with Image J software and vernier caliper.

.....
article can be found at the end of the article.

Results

Based on a topographical approach, we reported the general cartilage structure of the tracheosyringeal, bronchosyringeal, paired protrusions, tracheolateral muscles, sternotracheal muscles, and syringeal muscles in lovebird syrinx. In particular, the tympaniform membranes lateral lead a crucial role in modulating the frequency of male lovebirds more significantly ($p=0,009$) compared to female. On the other hand, the tympaniform membranes lateral dexter ($p=0,02$) and sinister ($p=0,05$) in females showed wider compared to male. We also reported a negative correlation between sound frequency compared to tympaniform membranes lateral dexter ($y = -913,56x + 6770,8$) and sinister ($y = -706,16x + 5736$).

Conclusions

It can be concluded that the tympaniform membranes lateral produced the lovebirds' primary sound. The sound frequency of male lovebirds was higher compared to female, however negatively correlated with the area of tympaniform membranes lateral.

Keywords

Agapornis fischeri, biodiversity, lovebird, sound frequency, syrinx morphometry

Corresponding authors: Faisal Fikri (faisalfikri@fkh.unair.ac.id), Muhammad Thohawi Elziyad Purnama (thohawi@fkh.unair.ac.id)

Author roles: Dewi CMS: Data Curation, Formal Analysis, Investigation; Dhamayanti Y: Data Curation, Formal Analysis, Investigation; Fikri F: Project Administration, Resources, Software, Validation, Visualization, Writing – Original Draft Preparation; Purnomo A: Project Administration, Resources, Software, Validation, Visualization; Khairani S: Project Administration, Resources, Software, Validation, Visualization, Writing – Original Draft Preparation; Chhetri S: Data Curation, Formal Analysis, Writing – Review & Editing; Purnama MTE: Conceptualization, Methodology, Supervision

Competing interests: No competing interests were disclosed.

Grant information: This work was supported by the Faculty of Veterinary Medicine, Universitas Airlangga (No.649/UN3/2020), awarded to Muhammad Thohawi Elziyad Purnama and Faisal Fikri.

Copyright: © 2024 Dewi CMS *et al.* This is an open access article distributed under the terms of the [Creative Commons Attribution License](#), which permits unrestricted use, distribution, and reproduction in any medium, provided the original work is properly cited.

How to cite this article: Dewi CMS, Dhamayanti Y, Fikri F *et al.* **An investigation of syrinx morphometry and sound frequency association in lovebirds (*Agapornis fischeri*) chirps [version 3; peer review: 2 approved]** F1000Research 2024, 11:354 <https://doi.org/10.12688/f1000research.108884.3>

First published: 24 Mar 2022, 11:354 <https://doi.org/10.12688/f1000research.108884.1>

REVISED Amendments from Version 2

In this third amendment, the author has modified the title briefly and emphasized the findings. In addition, we compare previous reports on the physiology of sonation so that bird chirps can be produced. In the discussion, we compared Anna's hummingbird and Mourning Dove (*Zenaidura macroura*). We have also added study limitations for consideration in future studies. Reference numbering has been sorted according to journal guidelines.

Any further responses from the reviewers can be found at the end of the article

Introduction

In the last decade, various birds have been domesticated as pets. In Indonesia, lovebirds (*Agapornis fischeri*) are popularly reared in captivity and are traded pets. Lovebird is an attractive ornamental bird because it has a characteristic feather color pattern and distinctive behavior. In addition, the sound of birds chirping and variations in sound can attract the attention of breeders to rear lovebirds.¹ Lovebird is a small parrot that often participates in chirping contests, thereby increasing its economic value as a traded pet. In Indonesia, the lovebird contests are organized by enthusiastic bird communities to evaluate the criteria for plumage color and chirp production. However, the risk of bird population sustainability must be a concern²

In some groups of avians, the syrinx is a crucial organ for producing sound and melody during chirping.³ The chirping variation is a manifestation of the articulation formed by the syrinx cartilage. In previous studies, syrinx organs were morphometrically revealed in pigeons,⁴ parakeets and canaries,⁵ chickens and rock dove,⁶ sparrows⁷ and penguins.⁸ The syrinx will stimulate the vibrations reflected from each cartilage to produce sound frequency.⁹ Lovebirds voice articulation develops in five phases from 0 to 91 days old, thereafter lovebirds can produce clear sound with different configurations. The duration of the sound and chirping frequency produced by the syrinx is significantly increased due to the reflection of the tympaniform membrane lateral.¹⁰

A pair of tympaniform membrane lateral are found in the lateral wall of the syrinx at the tracheobronchial junction. This structure extends from the tympanum to the first bronchial ring in chickens and pigeons or is composed of short membranes between the bronchosyringeal rings.¹¹ The tympaniform membrane medial connects the pessulus to the medial portion of the primary bronchus. This structure connects the ring portion of the bronchosyringeal cartilage dorsoventrally.¹² The labia are a pair of elastic cords found in the lateral and medial tympaniform membranes that physiologically produce the primary sound.¹³

The difference between male and female lovebirds requires further information, in particular, to determine the eligible age for the Lovebirds contest. Age may influence syrinx morphometry and normal function of the tympaniform membrane lateral to produce sound. In addition, it is very important to investigate the association of syrinx morphometry and sound frequency. This study was expected to provide an evidence of syrinx topography and morphometry in lovebirds and their association on the sound frequency produced with differences in gender and age.

Methods**Ethics statement**

This study was approved by the Ethical committee of animal care and use, Universitas Airlangga (No.445/HRECC.FODM/X/2020). This study was also reported according to the Animal Research: Reporting of in vivo Experiments (ARRIVE) guidelines 2.0: author checklist (see *Reporting guidelines*⁵²). All efforts were made to ameliorate any suffering of animals.

Based on legislation from the Ministry of Forestry and Biodiversity, Republic of Indonesia with reference number (No.20/2018) and Government Regulation with reference number (No.8/1999), Fischer's Lovebird is not included in the red list in Indonesia. In addition, the owners of the rearing farm held special conservation permission and is reported periodically with an increase in the Fischer's Lovebird population at the rearing farm.

Study period and location

This study was conducted over five months (November 2020 - March 2021). These lovebirds were reared in Mr. Sutoro farm, Solo, Central Java, Indonesia (7°33'29.6"S 110°51'43.0"E). Sound frequencies evaluation and syrinx morphometry were investigated at the biology laboratory, Universitas Surakarta.

Table 1. The primary sequence of nucleotides in this study.

Code	Nucleotide	Primer
NP-F ¹⁵	5'-GAGAAACTGTGCAAAACAG-3'	Forward
P2-R ¹⁵	5'-TCTGCATCGCTAAATCCTTT-3'	Reverse
MP-R ¹⁶	5'-AGTCACTATCAGATCCGGAA-3'	Reverse

Experimental design

The sample size was determined using Federer's formula: $t(n-1) \geq 15$ with a combination of age and gender for six groups. This formula design was considered due to two aspects of the same thing i.e. randomization and replication are necessary to obtain a valid estimate of the error variance of a contrast.¹⁴ There were four replications in each group, meaning a total of 24 lovebirds of different ages and gender (12 males and 12 females) were investigated. Inclusion criteria were that the birds were healthy (no animals were excluded). These lovebirds were reared in a fenced enclosure, fed millet seeds, and fresh water ad libitum. Our study was conducted on 2, 3, and 4-month-old (mo) birds based on post-hatch recordings at the breeding farm.

Sex determination in lovebirds

Meanwhile, sexing was performed on feather samples using the polymerase chain reaction (PCR) method. Deoxyribonucleic acid (DNA) isolation was performed using the Gsync DNA Extraction Kit protocol (Geneaid Biotech Ltd, Taiwan). DNA extraction was carried out overnight to produce clear DNA bands. DNA fragment amplification was carried out targeting the CHD gene using primers and reference primary markers (Table 1). The reaction mixture of bird DNA was mixed as much as 25 μ l consisting of 12,5 μ l MyTaq™ DNA Polymerase (Labgene Scientific SA, Switzerland), 1 μ l forward primer, 1 μ l reverse primer, and 9,5 μ l isolated DNA. Thereafter, the mixture was incubated in a PCR machine followed by pre-denaturation at 94°C for 2 mins, denaturation at 94°C for 20 sec, annealing at 46°C for 30 sec, extension at 72°C for 40 sec, and final extension at 72°C for 10 mins. All stages were repeated for 40 cycles. The results of the electrophoresis were then determined by comparing all samples with a 100 bp HyperLadder™ marker (Bioline, UK). The results of the electrophoresis are available in *Underlying data*.⁴⁹ Visualization was revealed PCR products of 400 bp and 350 bp for females, meanwhile only 400 bp for males. Of the 33 collected samples, only male (n=12) and female (n=12) lovebirds aged 2 (n=4), 3 (n=4), and 4 (n=4) mo were enrolled in the investigation group, respectively. Randomization and blinding of the collected samples were performed in replicated gender and age groups using the following steps: (1) Lovebird populations aged 2, 3, and 4 months in the respective fenced enclosures were assigned as the investigated group, (2) lovebirds were caught one by one randomly and then their gender was determined using the PCR method, (3) only 4 male and 4 female lovebirds in the respective age were enrolled and labeled as samples, (4) this method was repeated for the 3 and 4 month age groups.

Fast Fourier Transform (FFT) method

We evaluated each bird separately. The Fast Fourier Transform (FFT)¹⁷ method was performed to record the lovebirds' sound frequency in an insulation room to avoid noise. The analog recording process was performed in an interval of 30 mins to record the number of bird sounds. Analog data on the recording device was transferred to a computer using a soundcard and then converted into WAV (Microsoft Waveform Audio Files) format files using Microsoft Sound Recording software (Windows Voice Recorder for Windows 10, Microsoft Corporation) (see *Underlying data*⁵⁰). The visualization of voice phrases described the characteristics of the sound in a time interval in the form of a spectrogram (see *Underlying data*⁵¹). In addition, the visualization of sound phrases was observed as a continuous wave to reduce errors due to noise and phase differences in the FFT method.

Methylene blue staining¹⁸

Euthanasia was performed by injection of a lethal dose (LD50) of 99.5 mg/kg BW of ketamine intramuscularly then observed for 8-15 mins.¹⁹ The dissection procedure was performed on the dorsal recumbency with a focus on the thoracic cavity and then the topography of the dorsal, ventral, and lateral site of the syrinx was observed. The lower respiratory organs were dissected and then stored for 2 \times 24 h using 10% formalin solution, then as a stopping point, moved the organs into 70% alcohol solution. Syrinx organs were immersed in 1% methylene blue for 15 mins and then rinsed using 50% and 70% alcohol.

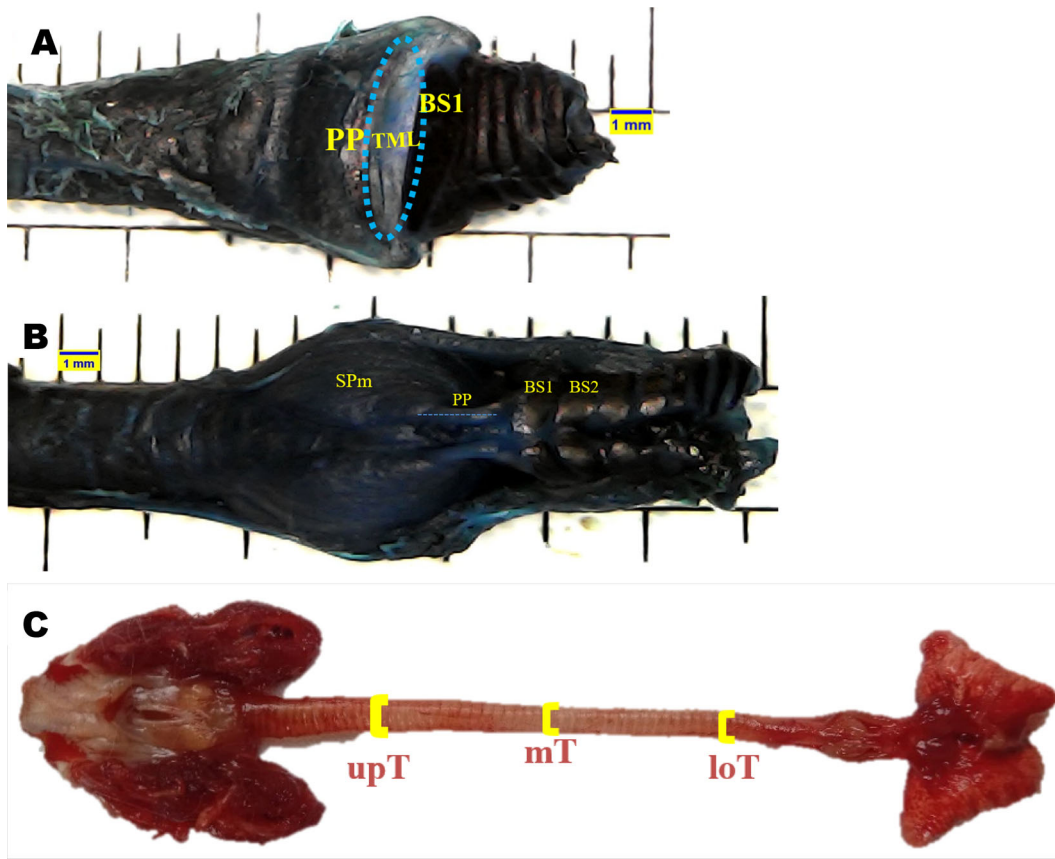


Figure 1. Syrinx morphometric determination. (A) area of tympaniform membrane lateral (TML), (B) length of paired protrusions (PP), (C) trachea diameter.

Syrinx morphometric evaluation

Topographical anatomical observations of the syrinx were performed for the following variables: tympanum (Ty), processus tympanicus (PT), tracheosyringeal (TS), bronchosyringeal (BS), bronchus (B), trachea bifurcation (BT), tracheolateral muscle (TLm), sternotracheal muscle (STm), profundal syringeal muscle (SPm), and superficial syringeal muscle (SSm). Meanwhile, syrinx morphometric were evaluated for the following variables: tympaniform membrane lateral dexter (TMLd), tympaniform membrane lateral sinister (TMLs), upper trachea (upT), middle trachea (mT), lower trachea (loT), paired protrusions dorsal (PPd), and paired protrusions ventral (PPv). Each variable was observed using a stereo microscope and then evaluated using **Image J** version 1.8.0 software.²⁰

The area of tympaniform membrane lateral dexter and sinister were determined according to the curved line around the lateral side of the tympaniform membrane lateral. The cranial and caudal margins of the tympaniform membrane lateral are the paired protrusions and bronchosyringeal cartilages (**Figure 1A**).⁴ The length of the paired protrusions dorsal and paired protrusions ventral were determined according to the cranial to caudal line. This line is emphasized from the end profundal syringeal muscle to the bronchosyringeal-1 cartilage (**Figure 1B**).⁵ For trachea diameter, evaluation was performed on the upper trachea, middle trachea, and lower trachea sides using a vernier caliper (**Figure 1C**).

Statistical analysis

The normality of the data was analyzed using the Shapiro–Wilk test with a normality value of $p > 0,05$. All the data were expressed as mean \pm standard error (SE) then analyzed using multivariate analysis of variance (MANOVA) followed by Duncan's comparison test. Values were considered significantly different at $p < 0,05$. The sound frequency of male and female birds were analyzed using independent T-test with a significance level ($p < 0,05$). Meanwhile, to investigate the association between the area of tympaniform membrane lateral and the lovebirds sound frequency produced, an association test was performed. Statistical analysis was performed using **SPSS** v.25 software (IBM, USA).

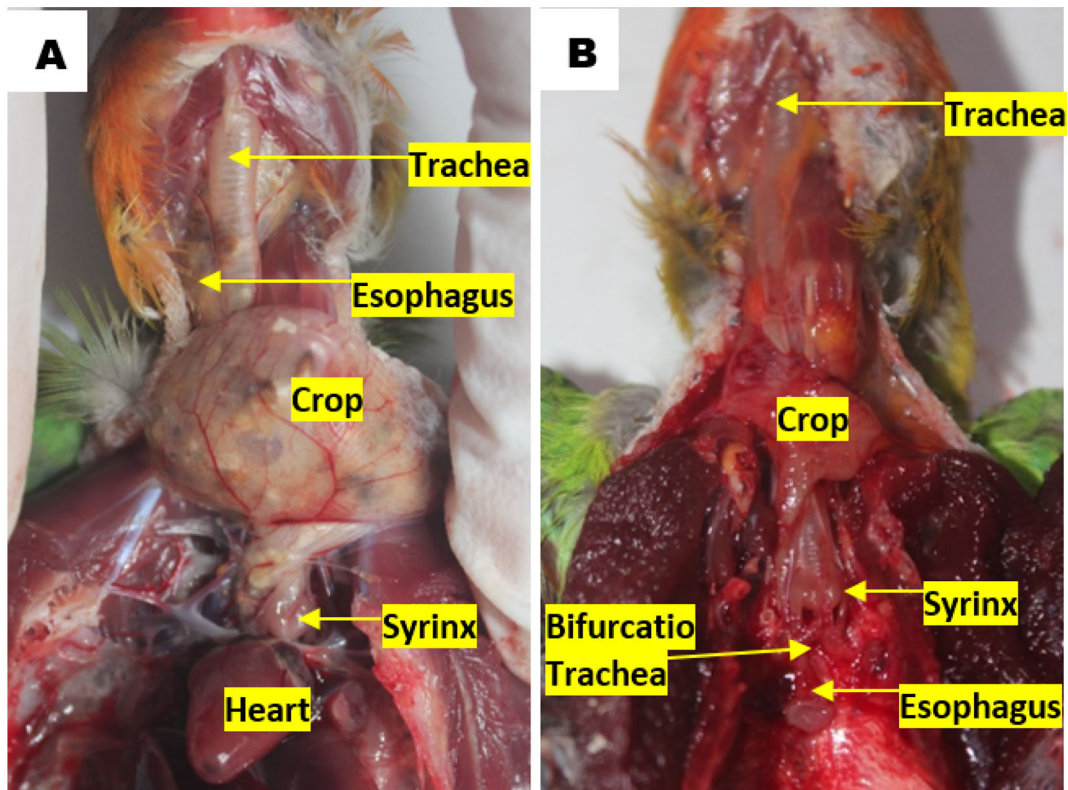


Figure 2. Location of the syrx to (A) the heart and (B) the esophagus in the thoracic cavity.

Results

Topographic anatomy and morphometry of the syrx

The raw, uncropped images associated with syrx morphometry and topography are available in *Underlying data*.⁴⁸ The topographical observations of lovebird syrx showed that there was no anatomical topographic variation across the various age and gender groups. Syrx location in the thoracic cavity tends to the left side compared to the esophagus, on the dorsocranial of the heart and caudal of the crop. Tracheal organs were found in the ventral esophagus. The trachea in the cervical region was found on the left side of the esophagus, before the thoracic cavity of the trachea is on the dorsal side of the esophagus. The crop continues to the caudal side of the transformed esophagus parallel to the syrx. The esophagus continues to the caudal side by crossing to the dorsal bifurcation of the trachea then being on the ventral of the lung and transformed into the proventriculus (Figure 2).

Using methylene blue staining, clearly visible tympaniform membrane lateral was observed from both primary bronchi. The cranial margin of the tympaniform membrane lateral is paired protrusions covered by profundal syringeal muscle and the caudal margin of the tympaniform membrane lateral is the bronchosyringeal-1 cartilage. An evidence revealed that pessulus and labia were not found in the lovebird syrx. It was found tympanum modification in the form of caudal protrusion called processus tympanicus on the dorsal and ventral sides. Processus tympanicus structure was found between a pair of paired protrusions which are tympanic plates and are connected to the cranial side of the tympaniform membrane lateral. Paired protrusions and tympanum structures are part of the tracheosyringeal cartilage. Paired protrusions is tracheosyringeal-1 cartilage, meanwhile tympanum is composed of three cartilages i.e. tracheosyringeal 2-4 (Figure 3). Bronchosyringeal cartilage was found on the cranial side of the trachea bifurcation and the caudal side of the tympaniform membrane lateral. All samples from each gender and age group had three pairs of bronchosyringeal cartilage on the right and left sides (Figure 4).

Observation of the muscles revealed that in all gender and age groups the lovebird syrx was identified as tracheolateral muscle, sternotracheal muscle, profundal syringeal muscle and superficial syringeal muscle. Tracheolateral muscle was found on the lateral side of the trachea. Meanwhile, sternotracheal muscle was found on the lateral side of the lower trachea and then split into two in the dexter and sinister syrx (Figure 5). The muscular structure gets thinner on the mediastinal side and eventually forms the sternotracheal muscle tendon, which then attaches to the lungs and

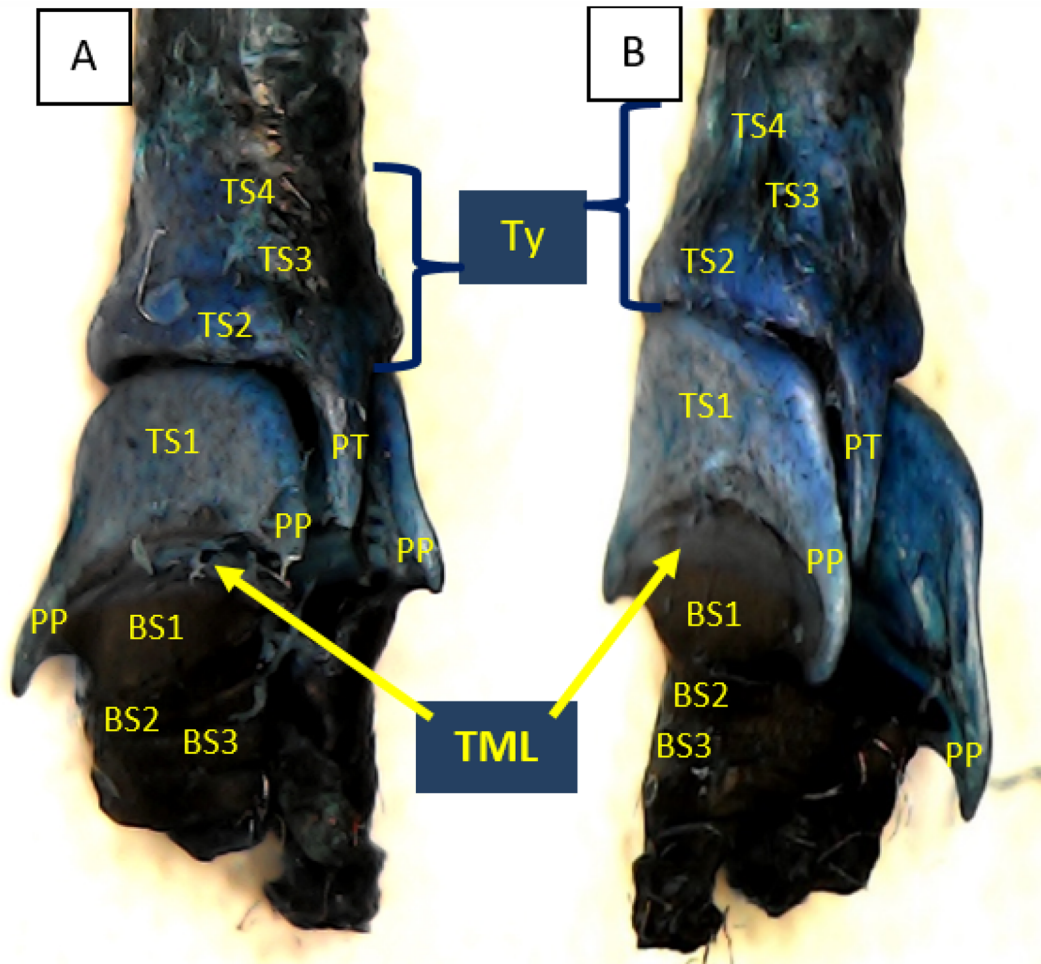


Figure 3. Syrinx structures with methylene blue staining (A) dorsolateral view and (B) ventrolateral view. TML= tympaniform membrane lateral, Ty = tympanum, PT = processus tympanicus, PP = paired protrusions, TS1-4 = tracheosyringeal 1-4, BS1-3 = bronchosyringeal 1-3.

extrapulmonary bronchi. Sternotracheal muscle on both sides looks asymmetrical, however the sinister is more inclined to the dorsal compared to the dexter is inclined ventrally. Profundal syringeal muscle was found from tympanum to paired protrusions with the caudal end of the muscle connected to the cranial portion of the tympaniform membrane lateral. Superficial syringeal muscle was identified from the lateral side of tympanum to the primary bronchus. The difference was found in the location of the connection of the caudal end of the profundal syringeal muscle and the bronchial cartilage. In groups aged 2 and 3 mo, both male and female, it was reported that there was a connection of the caudal end of the profundal syringeal muscle with the bronchus-2 cartilage, meanwhile, in the aged 4 mo group, both male and female, it was found in the bronchus-3 cartilage (Figure 6).

In this syrinx morphometric study, it was reported that the area of the tympaniform membrane lateral dexter and sinister increased with the increasing age of lovebirds. Tympaniform membrane lateral dexter and sinister in female lovebirds were observed more widely compared to male lovebirds. In the paired protrusions variables, upper, middle, and lower tracheal diameters, there was no significant difference reported in gender and age groups (Table 2). The full data associated with the Syrinx morphometry and sound frequency evaluation is available in *Underlying data*.⁴⁷

Sound frequency evaluation

In this present study, the evaluation of sound frequency was performed only on lovebirds aged 4 mo because at that age they are considered a mature lovebird during contest. The sound frequency produced by male lovebirds ($3500,00 \pm 204,12$) was significantly higher compared to female lovebirds ($2687,50 \pm 62,50$) (Table 3). This study also revealed that there was a negative association between sound frequencies compared with the area of tympaniform membranes lateral dexter ($y = -913,56x + 6770,8$) and sinister ($y = -706,16x + 5736$) (Figure 7). This finding indicated that the smaller area

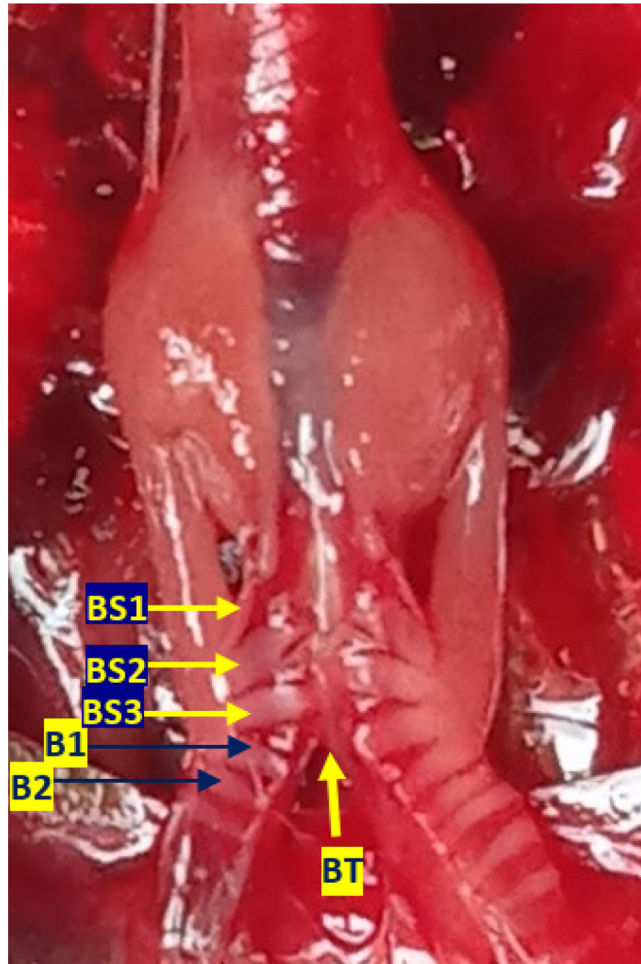


Figure 4. The structure of the syrinx cartilage. BS1-3 = bronchosyringeal 1-3, B1-2 = bronchus 1-2, BT = trachea bifurcation.

of lateral tympaniform membranes followed by an increase in the sounds frequency produced by the syrinx cartilage articulation.

Discussion

Modification of the syrinx in male birds is related to dimorphism of muscle mass and nerve fiber components in the laryngeal canal. Sexually dimorphic vocal behavior arises from each vibration reflected by the pesulus and often represents a more significant evolution in bird vocal complexity. This adaptation illustration allows the potential to generate an enhanced frequency range.²¹ The syrinx is a vocal organ in the avian family with the physiological principle of flowing air from the lungs across the narrow bronchotracheal tract and vibrating the tympaniform membranes lateral and medial.²² In respective bird species there is a variety of sounds due to differences in the syrinx anatomical structure.²³ In this present study, we observed a modified syrinx cartilage in the form of processus tympanicus and paired protrusions which are only owned by the Psittacidae bird family.²⁴ Paired protrusions are classified into tracheosyringeal cartilages with a composition similar to the tympanum compared to the structure of the bronchosyringeal cartilages.²⁵

In a previous study involving male Budgerigars (*Melopsittacus undulatus*), the tympanum was composed of six elements,²⁶ meanwhile in this study the tympanum was only composed of three elements. Lovebird syrinx was found on the caudal side of the lower trachea and not yet connected to the trachea bifurcation. The syrinx type in the Psittacidae family has a single set of membranes so that it produces only a single sound, unlike other bird species with the tracheobronchial syrinx type and can produce multiple sounds independently.²⁷ The sternotracheal muscle was identified from the lower trachea and then transformed into a tendon that connects to the lung area near the end of the extrapulmonary bronchus called the septum obliquum.²⁸

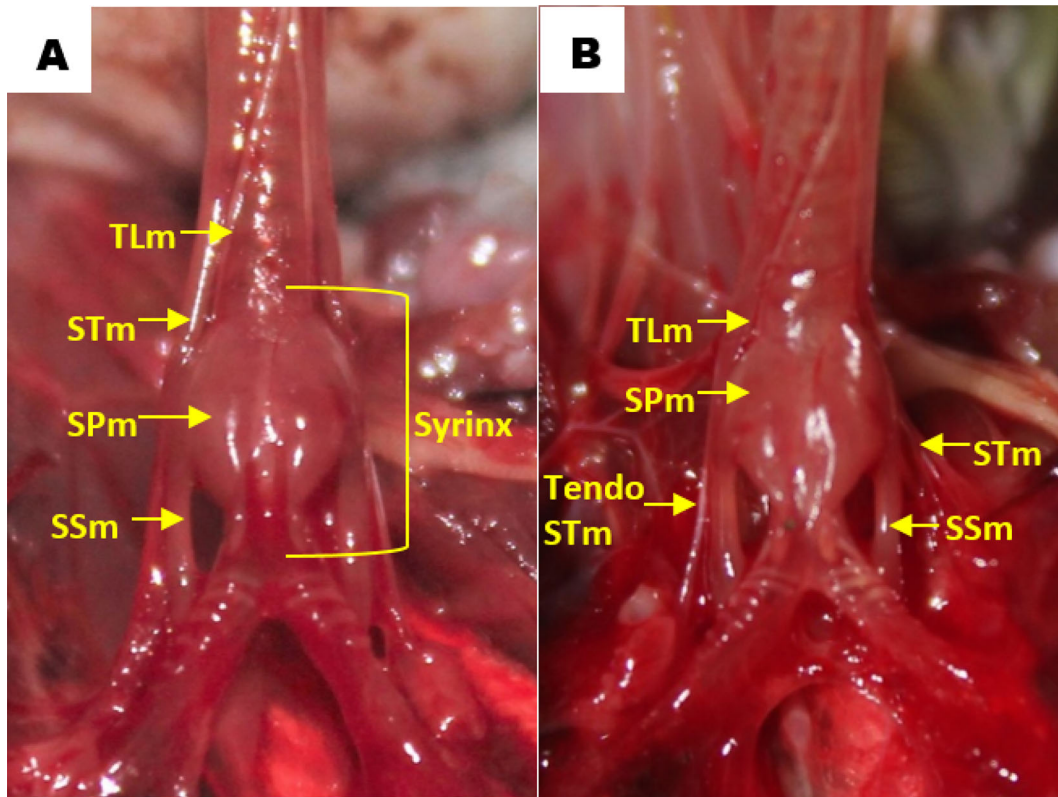


Figure 5. Muscle structures in the syrinx (A) dorsal view and (B) ventral view. TLm = tracheolateral muscle, STm = sternotracheal muscle, SPm = profundal syringeal muscle, SSm = superficial syringeal muscle.

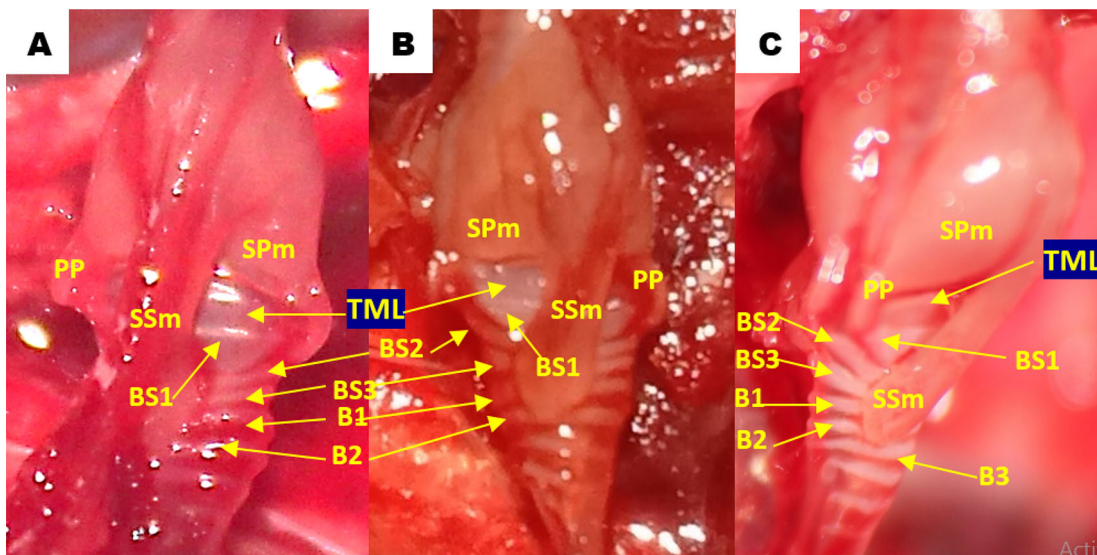


Figure 6. Lateral view of the lovebirds syrinx aged (A) 2 months old (mo), (B) 3 mo and (C) 4 mo. TML = tympaniform membrane lateral, PP = paired protrusions, SPm = profundal syringeal muscle, SSm = superficial syringeal muscle, BS1-3 = bronchosyringeal 1-3, B1-3 = bronchus 1-3.

In another study, the sternotracheal muscle appeared asymmetrical because the syrinx crossed with the esophagus, thus the muscle junction was not parallel between the dexter and sinister sides.²⁹ Another characteristic of the Psittacidae family, it has the Syringeal profundus and superficial muscle which is found in all gender and age groups with insertions starting from the cranial tympanum. Lovebirds only have two intrinsic muscles, i.e. the syringeal profundus and

Table 2. Syrinx morphometric investigation of lovebirds aged 2, 3, and 4 months old (mo).

Variables	Male (n = 12)			Female (n = 12)			p-value between gender
	2 mo (n = 4)	3 mo (n = 4)	4 mo (n = 4)	2 mo (n = 4)	3 mo (n = 4)	4 mo (n = 4)	
Area of TMLd (mm ²)	1,81 ± 0,14 ^a	2,89 ± 0,09 ^b	3,75 ± 0,20 ^c	1,38 ± 0,55 ^a	3,74 ± 0,21 ^b	4,33 ± 0,13 ^c	0,02*
Area of TMLs (mm ²)	1,58 ± 0,11 ^a	2,64 ± 0,23 ^b	3,56 ± 0,23 ^c	1,19 ± 0,19 ^a	3,27 ± 0,15 ^b	3,90 ± 0,19 ^c	0,05*
Diameter of upT (mm)	2,53 ± 0,29	2,83 ± 0,20	2,50 ± 0,30	2,88 ± 0,08	2,47 ± 0,35	2,91 ± 0,20	0,29
Diameter of mT (mm)	2,40 ± 0,10	2,33 ± 0,18	2,24 ± 0,23	2,47 ± 0,32	2,37 ± 0,23	2,58 ± 0,13	0,17
Diameter of loT (mm)	2,75 ± 0,23	2,35 ± 0,31	2,00 ± 0,09	2,52 ± 0,38	2,60 ± 0,35	2,48 ± 0,38	0,27
Length of PPD (mm)	2,39 ± 0,06	2,48 ± 0,15	2,47 ± 0,26	2,64 ± 0,09	2,50 ± 0,14	2,58 ± 0,35	0,21
Length of PPV (mm)	2,88 ± 0,19	3,06 ± 0,33	3,34 ± 0,24	3,25 ± 0,35	2,95 ± 0,11	3,42 ± 0,38	0,41

Values are expressed in mean ± SE (n = 4 samples for each different gender and age groups). Multivariate analysis of variance was carried out followed by Duncan's comparison test. ^{a,b,c} different superscripts in the same row indicate significant differences (p < 0,05). TMLd = tympaniform membrane lateral dexter, TMLs = tympaniform membrane lateral sinister, upT = upper trachea, mT = middle trachea, loT = lower trachea, PPD = paired protrusions dorsal, PPV = paired protrusions ventral.

Table 3. Sound frequency of male and female lovebirds aged 4 months old.

Gender	Peak frequency	Interval (sec)	Frequency (Hz)	Mean ± SE	p-value for frequency
Male (n = 4)	2	0,1	3500	3500,00 ± 204,12	0,009**
	2	0,1	3000		
	1	0,3	4000		
	1	0,2	3500		
Female (n = 4)	2	0,1	2750	2687,50 ± 62,50	
	2	0,2	2750		
	1	0,1	2500		
	2	0,2	2750		

Independent T-test was carried out with a significance level (p<0,05).

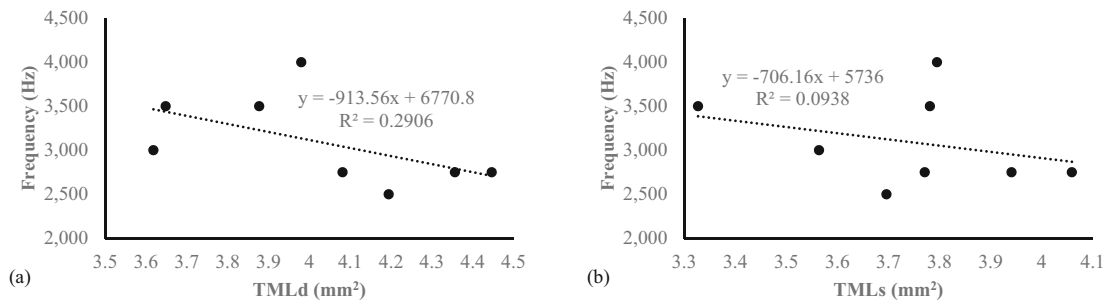


Figure 7. Association between lovebirds sound frequencies on (a) TMLd = tympaniform membrane lateral dexter (b) TMLs = tympaniform membrane lateral sinister.

superficial muscles compared to other species of chirping birds due to the muscle structure is more complex, i.e. the tracheobronchial dorsal, ventral and brevis muscles and the syrinx dorsal and ventral muscles.³⁰

In this syrinx morphometric study, there were significant differences in the area of tympaniform membranes lateral dexter and sinister in lovebirds aged 2, 3, and 4 mo. The area of the tympaniform membranes lateral increases with age in both male and female lovebirds. Tympaniform membranes lateral are functional membranes that produce melodic sounds in the Psittacidae family.³¹ The development of the tympaniform membranes lateral is triggered by the development of the chirping sound. The rapid development that occurs in pubertal birds will then decrease gradually at aged 9 mo.³²

In another study, tympaniform membranes lateral were reported to be larger in male pigeons than in female pigeons.³³ This is supported by studies of the duration and number of chirping periods being greater in females than males. Studies on artificial vocal cords reported that the larger area of the vibrating membrane produces lower sound frequencies.³⁴ The area of the tympaniform membranes can be one of the factors that trigger the difference in the sound of chirping in male and female lovebirds. In addition, the body weight of female lovebirds is significantly heavier than males. Generally, bird species with larger bodies have lower sound frequencies.³⁵ Hormonal factors also affect the character of the sound produced.³⁶ Repeated administration of testosterone in peridix birds resulted in a longer duration of chirping with a lower frequency.³⁷ The same study stated that birds treated with testosterone showed a significant widening of the lumen of the trachea and bronchi and a thicker syrinx membrane.³⁸

Tympaniform membranes lateral in chickens are composed of connective tissue and an extracellular matrix consisting of carbohydrates, hyaluronic acid and collagen.³⁹ The vocal folds are sensitive to the hormone estrogen. The decrease in estrogen has an impact on changes in the expression of molecules in the extracellular matrix, whereas testosterone does not affect the extracellular matrix.⁴⁰ Studies on sparrows after hatching at 3, 10 and 17 days old showed that androgen receptors can be found in the muscles around the syrinx and estrogen receptors are found in many syrinx chondrocytes.⁴¹ Estrogens and androgens can affect the development of the syrinx of birds after hatching in the skeletal and muscular parts, but their effect on the differentiation process is unidentified. Hormones have an influence on the nervous system which controls sound production. Testosterone has two effects, i.e. anatomically controlling the growth of vocal control stations and physiologically controlling the number of enzymes required during neural transmission.⁴²

In another study evaluated Anna's hummingbird, the feather's flapping at its resonance frequency creates the sound. The investigations showed that the R5's trailing vane is the source of the sound, indicating that the resonance is related to the feather's mechanical characteristics. Both flags and wind instruments' reeds are examples of structures whose elastic modulus and shape cause them to vibrate in fluid flow at a resonant frequency. The R5 feathers feature a critical fluttering velocity as well as a critical minimum velocity for sound creation. The frequency that R5 produces varies very little with wind velocity above the critical velocity.⁴³ Meanwhile, the Mourning Dove (*Zenaida macroura*) produces a tone that seems to be generated by the wings in a mechanical way. This sound is mostly heard during takeoff, which could be because of the high wingtip velocity brought on by the kinematics of takeoff. The primary means of modulating local air velocity to surpass a feather's critical velocity for other feathers, including tail feathers, is to alter flight speed. Birds can make a wide variety of sounds, and non-vocal techniques like this tail feather sonation increase that diversity. The size of their syrinxes may restrict the volume of vocalizations that little birds may make. This implies that it has been able to overcome the inherent limitations on vocal sound volume by converting to feather sonations.⁴⁴

Vocal control stations on the central nervous system have androgen and estrogen receptors that affect sound sensitivity.⁴⁵ Studies on adult canaries require estrogen to produce a chirp with a high rate of repeating syllables.⁴⁶ The duration of the chirp, the length of the chirping element and the frequency range can be influenced by the hormone testosterone but only in certain species so that there are differences in the expression of hormone receptors in the central nervous system which differ in each species and even gender. Further investigation is required to determine how the anatomical and morphometric variations of the syrinx, light-dark cycles, breeding cycles, and seasonal changes, relate to the features of the chirping noises generated. Furthermore, it is strongly advised to compare the sound intensities recorded during the study with the publicly available Xeno-Canto World Wild Bird Sounds collection in order to manage bird classification records and deliver quick, real-time information for the aim of determining biodiversity. Furthermore, the problem of urbanization today presents significant obstacles for animal communication, meaning that the singing habits of birds depend on both urban ecology and human activities.

Conclusions

In conclusion, we identified tympanum, processus tympanicus, tracheosyringeal cartilage, bronchosyringeal, bronchi, trachea bifurcation, paired protrusions, tracheolateral muscle, sternotracheal muscle, profundal and superficial syringeal muscle in lovebird syrinx. Our study emphasized that tympaniform membranes lateral initiates the lovebirds' primary sound, specifically in male birds. This finding also highlighted that the narrower tympaniform membranes lateral reflects the enhanced frequency of chirping in a single vocal period.

Data availability

Underlying data

Figshare: Syrinx morphometry and sound frequency evaluation. <https://doi.org/10.6084/m9.figshare.18382925.v4>.⁴⁷

This project contains the following underlying data:

- Syrinx morphometry and sound frequency evaluation.xlsx

Figshare: Syrinx morphometry and topography. <https://doi.org/10.6084/m9.figshare.18386744.v2>.⁴⁸

This project contains the following underlying data:

- 1a.png (Figure 1A Tympaniform membrane lateral evaluation).
- 1b.png (Figure 1B Paired protrusions evaluation).
- 1c.png (Figure 1C Trachea evaluation).
- 2a.png (Figure 2A Location of the syrinx compared to the heart in the thoracic cavity).
- 2b.png (Figure 2B Location of the syrinx compared to the esophagus in the thoracic cavity).
- 3a.png (Figure 3A Syrinx structures with methylene blue staining on dorsolateral view).
- 3b.png (Figure 3B Syrinx structures with methylene blue staining on ventrolateral view).

- 4.png (Figure 4 Bronchosyringeal cartilage).
- 5a.png (Figure 5A Syrinx muscle structures on dorsal view).
- 5b.png (Figure 5B Syrinx muscle structures on ventral view).
- 6a.png (Figure 6A Lovebird syrinx aged 2 months on lateral view).
- 6b.png (Figure 6B Lovebird syrinx aged 3 months on lateral view).
- 6c.png (Figure 6C Lovebird syrinx aged 4 months on lateral view).

Figshare: Gel electrophoresis result to determine Lovebird gender. <https://doi.org/10.6084/m9.figshare.19248182.v1>.⁴⁹

This project contains the following underlying data:

- Gel session 1.jpeg (Gender determination of sample number 1-12).
- Gel session 2.jpeg (Gender determination of sample number 13-24).
- Gel session 3.jpeg (Gender determination of sample number 25-33).

Figshare: Individually recorded Lovebird sounds in WAV format. <https://doi.org/10.6084/m9.figshare.19327490.v1>.⁵⁰

This project contains the following underlying data:

- ML1.wav (Sound recording for male lovebird sample No.1).
- ML2.wav (Sound recording for male lovebird sample No.2).
- ML3.wav (Sound recording for male lovebird sample No.3).
- ML4.wav (Sound recording for male lovebird sample No.4).
- FL1.wav (Sound recording for female lovebird sample No.1).
- FL2.wav (Sound recording for female lovebird sample No.2).
- FL3.wav (Sound recording for female lovebird sample No.3).
- FL4.wav (Sound recording for female lovebird sample No.4).

Figshare: Spectrogram analysis in respective bird sound. <https://doi.org/10.6084/m9.figshare.19327856.v1>.⁵¹

This project contains the following underlying data:

- ML1.PNG (Spectrogram figure for male lovebird sample No.1).
- ML2.PNG (Spectrogram figure for male lovebird sample No.2).
- ML3.PNG (Spectrogram figure for male lovebird sample No.3).
- ML4.PNG (Spectrogram figure for male lovebird sample No.4).
- FL1.PNG (Spectrogram figure for female lovebird sample No.1).

- FL2.PNG (Spectrogram figure for female lovebird sample No.2).
- FL3.PNG (Spectrogram figure for female lovebird sample No.3).
- FL4.PNG (Spectrogram figure for female lovebird sample No.4).

Reporting guidelines

Figshare: ARRIVE checklist for ‘An investigation of syrinx morphometry and sound frequency correlation during the chirping period in lovebirds (*Agapornis fischeri*)’. <https://doi.org/10.6084/m9.figshare.18394103.v2>.⁵²

Data are available under the terms of the [Creative Commons Attribution 4.0 International license](https://creativecommons.org/licenses/by/4.0/) (CC-BY 4.0).

Acknowledgments

We thank Mr. Sutoro who allowed us to perform the experiments on their lovebird farm. Last but not least, thanks to Aulia, Dara, Sera, Teja for all facilities support and mini equipment during this study.

References

1. Van der Zwan H, Visser C, Van der Sluis R: **Plumage colour variations in the *Agapornis* genus: a review.** *Ostrich*. 2019; **90**(1): 1–10. [PubMed Abstract](#) | [Publisher Full Text](#)
2. Hanesia WI, Hidayat B, Sunarya U: **Klasifikasi Suara Lovebird Dengan Metode Mel Frequency Cepstral Coefficient (mfcc) Dan Fuzzy Logic.** *Proc. Eng.* 2015; **2**(2): 2968.
3. Suthers RA, Zollinger SA: **Producing song: the vocal apparatus.** *Ann. N. Y. Acad. Sci.* 2004; **1016**(1): 109–129. [PubMed Abstract](#) | [Publisher Full Text](#)
4. Alonso RG, Kopuchian C, Amador A, et al.: **Difference between the vocalizations of two sister species of pigeons explained in dynamical terms.** *J. Comp. Physiol.* 2016; **202**(5): 361–370. [PubMed Abstract](#) | [Publisher Full Text](#)
5. Gündemir O, Alpak H: **Macroanatomic and histological examination of the trachea and syrinx in budgerigars and canaries.** *Harran Üniv. Vet. Fak. Derg.* 2020; **9**(1): 19–23. [PubMed Abstract](#) | [Publisher Full Text](#)
6. Maksoud A, Ibrahim A, Hussein M, et al.: **The Gross Anatomy of the Syrinx of Adult Male Domestic Fowl *Gallus gallus domesticus*.** *J. Vet. Res. Med.* 2019; **1**(1): 1–5.
7. Riede T, Goller F: **Functional morphology of the sound-generating labia in the syrinx of two songbird species.** *J. Anat.* 2010; **216**(1): 23–36. [PubMed Abstract](#) | [Publisher Full Text](#)
8. Kriesell HJ, Le Bohec C, Cerwenka AF, et al.: **Vocal tract anatomy of king penguins: morphological traits of two-voiced sound production.** *Front. Zool.* 2020; **17**(1): 1–11. [PubMed Abstract](#) | [Publisher Full Text](#)
9. Soobramoney S, Perrin M: **A comparison of the alarm calls of five species of African lovebirds: genus *Agapornis*.** *Trans. Royal Soc. South Africa.* 2014; **69**(1): 9–18. [PubMed Abstract](#) | [Publisher Full Text](#)
10. Hongzhen Y, Dongfeng L, Jinchang J: **The call development of *Psittacula agapornis*.** *Shengwu Wuli Xuebao.* 2006; **22**(2): 101–109.
11. Casteleyn C, Cornillie P, Van Cruchten S, et al.: **Anatomy of the upper respiratory tract in domestic birds, with emphasis on vocalization.** *Anat. Histol. Embryol.* 2018; **47**(2): 100–109. [PubMed Abstract](#) | [Publisher Full Text](#)
12. Mohamed R: **Sexual dimorphism in the anatomical features of the Syrinx in the White Pekin ducks (*Anas platyrhynchos*).** *Int. J. Agric. Sci. Vet. Med.* 2017; **5**(5): 78–85.
13. Ladich F, Winkler H: **Acoustic communication in terrestrial and aquatic vertebrates.** *J. Exp. Biol.* 2017; **220**(13): 2306–2317. [PubMed Abstract](#) | [Publisher Full Text](#)
14. Federer WT: **Randomization and sample size in experimentation.** *Food and Drug Administration Statistics Seminar.* 1966; pp. 2–3.
15. Sigeman H, Ponnikas S, Hansson B: **Whole-genome analysis across 10 songbird families within Sylvioidea reveals a novel autosome–sex chromosome fusion.** *Biol. Lett.* 2020; **16**(4): 20200082. [PubMed Abstract](#) | [Publisher Full Text](#)
16. Gan HM, Falk S, Morales HE, et al.: **Genomic evidence of neo-sex chromosomes in the eastern yellow robin.** *GigaSci.* 2019; **8**(9): giz111. [PubMed Abstract](#) | [Publisher Full Text](#)
17. Prapcoyo H, Putra BPA, Perwira RI: **Implementation of Mel Frequency Cepstral Coefficient and Dynamic Time Warping For Bird Sound Classification.** *In Conference SENATIK.* 2019; **5**(1): 139–148. [PubMed Abstract](#) | [Publisher Full Text](#)
18. Abdel-Maksoud FM, Hussein MM, Hamdy A, et al.: **Anatomical, Histological, and Electron Microscopic Structures of Syrinx in Male Budgerigars (*Melopsittacus undulatus*).** *Microsc. Microanal.* 2020; **26**(6): 1226–1235. [PubMed Abstract](#) | [Publisher Full Text](#)
19. Alatrushi AN, Naser AS: **The Safety Profile of the Anesthetic Effect of Alfaxalone and its Interaction with Xylazine and Ketamine in Chick's Model.** *Maced. Vet. Rev.* 2021; **44**(2): 203–209. [PubMed Abstract](#) | [Publisher Full Text](#)
20. Riede T, Olson CR: **The vocal organ of hummingbirds shows convergence with songbirds.** *Sci. Rep.* 2020; **10**(1): 1–14.
21. Riede T, Fisher JH, Goller F: **Sexual dimorphism of the zebra finch syrinx indicates adaptation for high fundamental frequencies in males.** *PLoS One.* 2010; **5**(6): e11368. [PubMed Abstract](#) | [Publisher Full Text](#)
22. Kingsley EP, Eliason CM, Riede T, et al.: **Identity and novelty in the avian syrinx.** *Proc. Nat. Acad. Sci.* 2018; **115**(41): 10209–10217. [PubMed Abstract](#) | [Publisher Full Text](#)
23. Degrange FJ: **A revision of skull morphology in Phorusrhacidae (Aves, Cariamiformes).** *J. Vertebr. Paleontol.* 2020; **40**(6): e1848855. [PubMed Abstract](#) | [Publisher Full Text](#)
24. Gaban-Lima R, Höfling E: **Comparative anatomy of the syrinx in the tribe Arini (Aves: Psittacidae).** *J. Morphol. Sci.* 2017; **23**(3): 501–512.
25. McInerney PL, Lee MS, Clement AM, et al.: **The phylogenetic significance of the morphology of the syrinx, hyoid and larynx, of the southern cassowary, *Casuarius casuarius* (Aves, Palaeognathae).** *BMC Evol. Biol.* 2019; **19**(1): 1–18.
26. Abdel-Maksoud FM, Hussein MM, Hamdy A, et al.: **Anatomical, Histological, and Electron Microscopic Structures of Syrinx in Male Budgerigars (*Melopsittacus undulatus*).** *Microsc. Microanal.* 2020; **26**(6): 1226–1235. [PubMed Abstract](#) | [Publisher Full Text](#)
27. Crosta L: **Respiratory Diseases of Parrots: Anatomy, Physiology, Diagnosis and Treatment.** *Vet. Clin. Exotic. Anim. Pract.* 2021; **24**(2): 397–418. [PubMed Abstract](#) | [Publisher Full Text](#)
28. Monte A, Cerwenka AF, Ruthensteiner B, et al.: **The hummingbird syrinx morphome: a detailed three-dimensional description of**

- the black jacobin's vocal organ. *BMC Zool.* 2020; **5**(1): 1–15.
[Publisher Full Text](#)**
29. Doğan GK, Takaci I: **Anatomy of respiratory system in poultry.** *Vet. J. Mehmet. Akif. Ersoy. Univ.* 2018; **3**(2): 141–147.
[Publisher Full Text](#)
30. Kumar R, Singh M: **Bird fancier's lung: clinical-radiological presentation in 15 cases.** *Adv. Respir. Med.* 2015; **83**(1): 39–44.
[Publisher Full Text](#)
31. Ibrahim IAA, Hussein MM, Hamdy A, et al.: **Comparative morphological features of syrinx in male domestic fowl *Gallus gallus domesticus* and male domestic pigeon *Columba livia domestica*: A histochemical, ultrastructural, scanning electron microscopic and morphometrical study.** *Micros. Microanal.* 2020; **26**(2): 326–347.
[Publisher Full Text](#)
32. Putranto HD, Brata B, Yumiati Y: **Study on contour feathers growth of White-rumped Shama during fledgling phase.** *In IOP Conf. Ser. Earth Environ. Sci.* 2021; **788**(1): 012085.
[Publisher Full Text](#)
33. Al-badri AMS: **Macroscopic study of syrinx in the common bulbul (*Pycnonotus barbatus*) and indigenous pigeon (*Columba livia domestica*).** *Al-Qadisiyah J. Vet. Med. Sci.* 2014; **13**(1): 88–93.
[Publisher Full Text](#)
34. Zhang YS, Takahashi DY, Liao DA, et al.: **Vocal state change through laryngeal development.** *Nat. Commun.* 2019; **10**(1): 1–12.
[Publisher Full Text](#)
35. Walløe S, Chakraborty M, Balsby TJ, et al.: **A Relationship between the Characteristics of the Oval Nucleus of the Mesopallium and Parrot Vocal Response to Playback.** *Brain Behav. Evol.* 2021; **96**(1): 37–48.
[Publisher Full Text](#)
36. Ghosh R, Mishra RC, Choi B, et al.: **Exposure to sound vibrations lead to transcriptomic, proteomic and hormonal changes in Arabidopsis.** *Sci. Rep.* 2016; **6**(1): 1–17.
[Publisher Full Text](#)
37. Chiver I, Schlinger BA: **Sex-specific effects of testosterone on vocal output in a tropical subsocial bird.** *Anim. Behav.* 2019; **148**(1): 105–112.
[Publisher Full Text](#)
38. Gahr M: **How hormone-sensitive are bird songs and what are the underlying mechanisms?.** *Acta Acust. United Acust.* 2014; **100**(4): 705–718.
[Publisher Full Text](#)
39. Goller F: *Sound production and modification in birds—Mechanisms, methodology and open questions. Comparative Bioacoustics: An Overview.* Brown C, Riede T, editors. Sharjah, United Arab Emirates: Bentham Science Publishers; 2016; 165–230.
40. Kunduk M, Vansant MB, Ikuma T, et al.: **The effects of the menstrual cycle on vibratory characteristics of the vocal folds investigated with high-speed digital imaging.** *J. Voice.* 2017; **31**(2): 182–187.
[PubMed Abstract](#) | [Publisher Full Text](#)
41. Tehrani MA, Venev SL: **Intracranial administration of the G-protein coupled estrogen receptor 1 antagonist, G-15, selectively affects dimorphic characteristics of the song system in zebra finches (*Taeniopygia guttata*).** *Develop Neurobiol.* 2018; **78**(8): 775–784.
[PubMed Abstract](#) | [Publisher Full Text](#)
42. Cornez G, Shevchouk OT, Ghorbanpoor S, et al.: **Testosterone stimulates perineuronal nets development around parvalbumin cells in the adult canary brain in parallel with song crystallization.** *Horm. Behav.* 2020; **119**(1): 104643.
[PubMed Abstract](#) | [Publisher Full Text](#)
43. Clark CJ, Feo TJ: **The Anna's hummingbird chirps with its tail: a new mechanism of sonation in birds.** *Proceed. Royal Soc. B Biol. Sci.* 2008; **275**(1637): 955–962.
[Publisher Full Text](#)
44. Hayslette SE, Mirarchi RE: **Patterns of food preferences in mourning doves.** *J. Wildlife Manag.* 2001; **65**(4): 816–827.
[Publisher Full Text](#)
45. Caras ML, Remage-Healey L: **Modulation of peripheral and central auditory processing by estrogens in birds.** *Hear Horm.* 2016; **57**(4): 77–99.
[Publisher Full Text](#)
46. Ko MC, Van Meir V, Vellema M, et al.: **Characteristics of song, brain anatomy and blood androgen levels in spontaneously singing female canaries.** *Horm. Behav.* 2020; **117**(1): 104614.
[PubMed Abstract](#) | [Publisher Full Text](#)
47. Purnama MTE, Dewi CMS, Dhamayanti Y, et al.: **Syrinx morphometry and sound frequency evaluation.** *figshare. Dataset.* 2022.
[Publisher Full Text](#)
48. Purnama MTE, Dewi CMS, Dhamayanti Y, et al.: **Syrinx morphometry and topography.** *figshare. Figure.* 2022.
[Publisher Full Text](#)
49. Purnama MTE, Dewi CMS, Dhamayanti Y, et al.: **Gel electrophoresis result to determine Lovebird gender.** *figshare. Figure.* 2022.
[Publisher Full Text](#)
50. Purnama MTE, Dewi CMS, Dhamayanti Y, et al.: **Individually recorded Lovebird sounds in WAV format.** *figshare. Media.* 2022.
[Publisher Full Text](#)
51. Purnama MTE, Dewi CMS, Dhamayanti Y, et al.: **Spectrogram analysis in respective bird sound.** *figshare. Figure.* 2022.
[Publisher Full Text](#)
52. Purnama MTE, Dewi CMS, Dhamayanti Y, et al.: **ARRIVE report checklist: Syrinx morphometry and sound frequency evaluation during chirping period in Lovebirds (*Agapornis fischeri*).** *figshare.* 2022. Online resource.
[Publisher Full Text](#)

Open Peer Review

Current Peer Review Status:  

Version 2

Reviewer Report 10 May 2024

<https://doi.org/10.5256/f1000research.143256.r266111>

© 2024 Alimon A. This is an open access peer review report distributed under the terms of the [Creative Commons Attribution License](#), which permits unrestricted use, distribution, and reproduction in any medium, provided the original work is properly cited.



Abdul Razak Alimon

¹ Department of Animal Science, Faculty of Agriculture, Putra Malaysia University, Serdang, Selangor, Malaysia

² Department of Animal Science, Faculty of Agriculture, Putra Malaysia University, Serdang, Selangor, Malaysia

I have read the paper and in my opinion this paper is well written and has scientific merits. In Indonesia lovebirds are popular ornamental birds kept for their beautiful colours and melodious chirps. In fact these birds are used in competition for their chirping ability. This study investigated the chirping frequency in relation to the morphology of the syrinx, which is where the voice originate. The description of methodology was clear and appropriate for this kind of study. The results of this study were well presented and showed significant relationships between sound frequency and syrinx. Overall, an interesting paper.

Is the work clearly and accurately presented and does it cite the current literature?

Yes

Is the study design appropriate and is the work technically sound?

Yes

Are sufficient details of methods and analysis provided to allow replication by others?

Yes

If applicable, is the statistical analysis and its interpretation appropriate?

Yes

Are all the source data underlying the results available to ensure full reproducibility?

Yes

Are the conclusions drawn adequately supported by the results?

Yes

Competing Interests: No competing interests were disclosed.

Reviewer Expertise: Animal nutrition and physiology.

I confirm that I have read this submission and believe that I have an appropriate level of expertise to confirm that it is of an acceptable scientific standard.

Reviewer Report 23 January 2023

<https://doi.org/10.5256/f1000research.143256.r161020>

© 2023 Yakubu A. This is an open access peer review report distributed under the terms of the [Creative Commons Attribution License](#), which permits unrestricted use, distribution, and reproduction in any medium, provided the original work is properly cited.



Abdulmojeed Yakubu 

¹ Department of Animal Science/Centre for Sustainable Agriculture and Rural Development, Faculty of Agriculture, Nasarawa State University, Lafia, Nigeria

² Department of Animal Science/Centre for Sustainable Agriculture and Rural Development, Faculty of Agriculture, Nasarawa State University, Lafia, Nigeria

I have read the revised version of the manuscript entitled 'An investigation of syrinx morphometry and sound frequency association during the chirping period in lovebirds (*Agapornis fischeri*)'. It has been substantially improved by the authors. Therefore, the manuscript can be accepted for indexing in its current form.

Is the work clearly and accurately presented and does it cite the current literature?

Yes

Is the study design appropriate and is the work technically sound?

Yes

Are sufficient details of methods and analysis provided to allow replication by others?

Yes

If applicable, is the statistical analysis and its interpretation appropriate?

Yes

Are all the source data underlying the results available to ensure full reproducibility?

Yes

Are the conclusions drawn adequately supported by the results?

Yes

Competing Interests: No competing interests were disclosed.

Reviewer Expertise: Animal Breeding and Genetics

I confirm that I have read this submission and believe that I have an appropriate level of expertise to confirm that it is of an acceptable scientific standard.

Version 1

Reviewer Report 02 August 2022

<https://doi.org/10.5256/f1000research.120324.r144637>

© 2022 Yakubu A. This is an open access peer review report distributed under the terms of the [Creative Commons Attribution License](#), which permits unrestricted use, distribution, and reproduction in any medium, provided the original work is properly cited.



Abdulmojeed Yakubu

¹ Department of Animal Science/Centre for Sustainable Agriculture and Rural Development, Faculty of Agriculture, Nasarawa State University, Lafia, Nigeria

² Department of Animal Science/Centre for Sustainable Agriculture and Rural Development, Faculty of Agriculture, Nasarawa State University, Lafia, Nigeria

³ Department of Animal Science/Centre for Sustainable Agriculture and Rural Development, Faculty of Agriculture, Nasarawa State University, Lafia, Nigeria

Abstract:

Background:

- I thought the location of study will be a thing of interest.

Methods:

- A brief description of the statistical analysis is required under Methods.
- This sentence appears incomplete: 'On the other hand, the tympaniform membranes lateral dexter ($p=0,02$) and sinister ($p=0,05$) in females showed wider compared to male'
- You gave regression equations without the corresponding correlation values, except you want to replace 'correlation' with 'association'.

Conclusions:

- Please try and conclude in the context of the biological implication of your findings.

Introduction:

- Please expatiate on 'Lovebirds contest'.

Methods:

Experimental design:

- Try and separate experimental design from PCR part of the study.
- Provide a reference for the Federer's formula: $t(n-1) \geq 15$, and why is it adopted in this study considering the sample size of only 24 lovebirds?
- What gel and dye were used for the PCR?
- 'Of the 33 samples'. There is a need to elaborate on this.
- Briefly describe the term 'blinding'.

Methylene blue staining:

- How soon does lethal dose (LD50) have effect on the bird?

Statistical analysis:

- Did you test for the homogeneity of variance and normality of your data?
- You are mixing up Correlation and Regression (Association). Although the two has to do with 'Relationship', they provide different values.

Results:

Sound frequency evaluation:

- You should have tested sound frequency for other ages as it would have provided additional information for comparison.

Discussion:

- Briefly discuss syrinx morphometrics in the context of adaptation before relating with sound frequency.

Conclusions:

- Try and beef up this section especially as it relates to biological implication and future study.

References

- Please revisit for accuracy and correct formatting.

NB: There is a need for language editing of the entire text.

Is the work clearly and accurately presented and does it cite the current literature?

Yes

Is the study design appropriate and is the work technically sound?

Yes

Are sufficient details of methods and analysis provided to allow replication by others?

Yes

If applicable, is the statistical analysis and its interpretation appropriate?

Partly

Are all the source data underlying the results available to ensure full reproducibility?

Yes

Are the conclusions drawn adequately supported by the results?

Partly

Competing Interests: No competing interests were disclosed.

Reviewer Expertise: Animal Breeding and Genetics

I confirm that I have read this submission and believe that I have an appropriate level of expertise to confirm that it is of an acceptable scientific standard, however I have significant reservations, as outlined above.

Author Response 15 Jan 2023

Muhammad Thohawi Elziyad Purnama

Dear Reviewer,

Thank you for your valuable comments and suggestions on the manuscript entitled:

"An investigation of syrinx morphometry and sound frequency association during the chirping period in lovebirds (*Agapornis fischeri*)"

We welcome feedback. We have made modifications to the study on the following points:

Background:

I thought the location of study will be a thing of interest.

Response: We have added the location and study period to the background abstract and methods section.

Methods:

A brief description of the statistical analysis is required under Methods.

Response: We have added a brief description of the statistical method to the abstract.

This sentence appears incomplete: 'On the other hand, the tympaniform membranes lateral dexter ($p=0,02$) and sinister ($p=0,05$) in females showed wider compared to male'

Response: We have modified the interpretation of these results.

You gave regression equations without the corresponding correlation values, except you want to replace 'correlation' with 'association'.

Response: We have revised that the association test was used in the present study.

Conclusions:

Please try and conclude in the context of the biological implication of your findings.

Response: We have modified the conclusions according to crucial information on syrinx morphometry and biologic implications.

Introduction:

Please expatiate on 'Lovebirds contest'.

Response: We have added crucial information about lovebird contests and information gaps from this study.

Methods:

Experimental design:

Try and separate experimental design from PCR part of the study.

Response: We have separated the experimental design section from the sex determination method.

Provide a reference for the Federer's formula: $t(n-1) \geq 15$, and why is it adopted in this study considering the sample size of only 24 lovebirds?

Response: We have added references and reasons why this formula was implemented in determining the sample for this study.

What gel and dye were used for the PCR?

Response: We have added manufacturing information for gel products and dyes used.

'Of the 33 samples'. There is a need to elaborate on this.

Response: We have added a description of why the number of birds was collected, then determined the sex as a qualification for the sample studied.

Briefly describe the term 'blinding'.

Response: We have described the randomization and blinding stages of the sample.

Methylene blue staining:

How soon does lethal dose (LD50) have effect on the bird?

Response: We have added information on the onset of action LD50 at the euthanasia stage.

Statistical analysis:

Did you test for the homogeneity of variance and normality of your data?

Response: We added a brief description of the Shapiro-Wilk test for homogeneity analysis in the present study.

You are mixing up Correlation and Regression (Association). Although the two has to do with 'Relationship', they provide different values.

Response: We have revised that the association test was used in the present study.

Results:

Sound frequency evaluation:

You should have tested sound frequency for other ages as it would have provided additional information for comparison.

Response: A limitation of our study was not evaluating the frequency of birdsong at all ages due to the full rearing period up to 4 months of age prior to euthanasia. However, we will use this design for further studies so that we can provide more comprehensive information

and compare it to other ages.

Discussion:

Briefly discuss syrinx morphometrics in the context of adaptation before relating with sound frequency.

Response: We have added a brief description of the adaptive context of the syrinx morphometrics prior to its physiological function in producing sound vibrations.

Conclusions:

Try and beef up this section especially as it relates to biological implication and future study.

Response: We have modified the conclusions according to crucial information on syrinx morphometry and biological implications.

References

Please revisit for accuracy and correct formatting.

Response: We have revised and reformatted the references according to the guidelines.

Competing Interests: All authors declare no competing interests

The benefits of publishing with F1000Research:

- Your article is published within days, with no editorial bias
- You can publish traditional articles, null/negative results, case reports, data notes and more
- The peer review process is transparent and collaborative
- Your article is indexed in PubMed after passing peer review
- Dedicated customer support at every stage

For pre-submission enquiries, contact research@f1000.com

F1000Research