

Retrorectal Hernia: A Rare Cause of Constipation Diagnosed on Magnetic Resonance (MR) Defecography

Review began 04/16/2024
Review ended 04/18/2024
Published 04/23/2024

© Copyright 2024
Ogunleye et al. This is an open access article distributed under the terms of the Creative Commons Attribution License CC-BY 4.0., which permits unrestricted use, distribution, and reproduction in any medium, provided the original author and source are credited.

Olanrewaju Ogunleye ¹, Abeer H. Abdelhafez ¹, Eduardo Matta ¹, Larry Kramer ¹

1. Department of Radiology, University of Texas Health Science Center at Houston, Houston, USA

Corresponding author: Olanrewaju Ogunleye, olanrewaju.a.ogunleye@uth.tmc.edu

Abstract

Retrorectal herniation of the sigmoid colon is a rare condition characterized by the protrusion of a segment of the colon into the pre-sacral space and posterior to the rectum. This herniation occurs through a defect in the peritoneum, which may have developed secondary to congenital mechanisms, surgery, trauma, or inflammatory processes. Here, a case of retrorectal herniation of the sigmoid colon in an elderly female patient presenting with constipation is reported, with a review of the literature.

Categories: Gastroenterology, Radiology

Keywords: rectocele, mr defecography, sigmoid colon, rectum, hernia

Introduction

Retrorectal hernias are a rare type of internal hernia, with only a few cases reported in the literature [1,2]. Retrorectal herniation of the sigmoid colon is the protrusion of a segment of the sigmoid colon through a defect in the peritoneum into the pre-sacral space and posterior to the rectum [1,3]. This peritoneal defect can be secondary to congenital mechanisms, surgery, trauma, or inflammatory processes [4]. As with other internal hernias, patients may develop nonspecific chronic symptoms such as abdominal pain, constipation, and obstipation. More severe symptoms may include acute bowel obstruction, intermittent bowel obstruction, peritonitis, and sepsis [4,5]. We present a case of a 73-year-old female patient with a finding of retrorectal hernia of the sigmoid colon.

Case Presentation

A 73-year-old female patient, with a history of diverticulosis and prior hysterectomy, was referred to our department for magnetic resonance defecography following complaints of constipation. MR imaging revealed herniation of the sigmoid colon within the presacral space, posterior to the rectum (Figures 1, 2). There was no evidence of bowel obstruction. A moderate pelvic floor laxity with moderate anorectal descent and a 2 cm anterior wall rectocele were also reported during the straining and evacuation phases (Figure 3). The patient was subsequently seen by the referring physician and managed conservatively.

How to cite this article

Ogunleye O, Abdelhafez A H, Matta E, et al. (April 23, 2024) Retrorectal Hernia: A Rare Cause of Constipation Diagnosed on Magnetic Resonance (MR) Defecography. *Cureus* 16(4): e58848. DOI 10.7759/cureus.58848

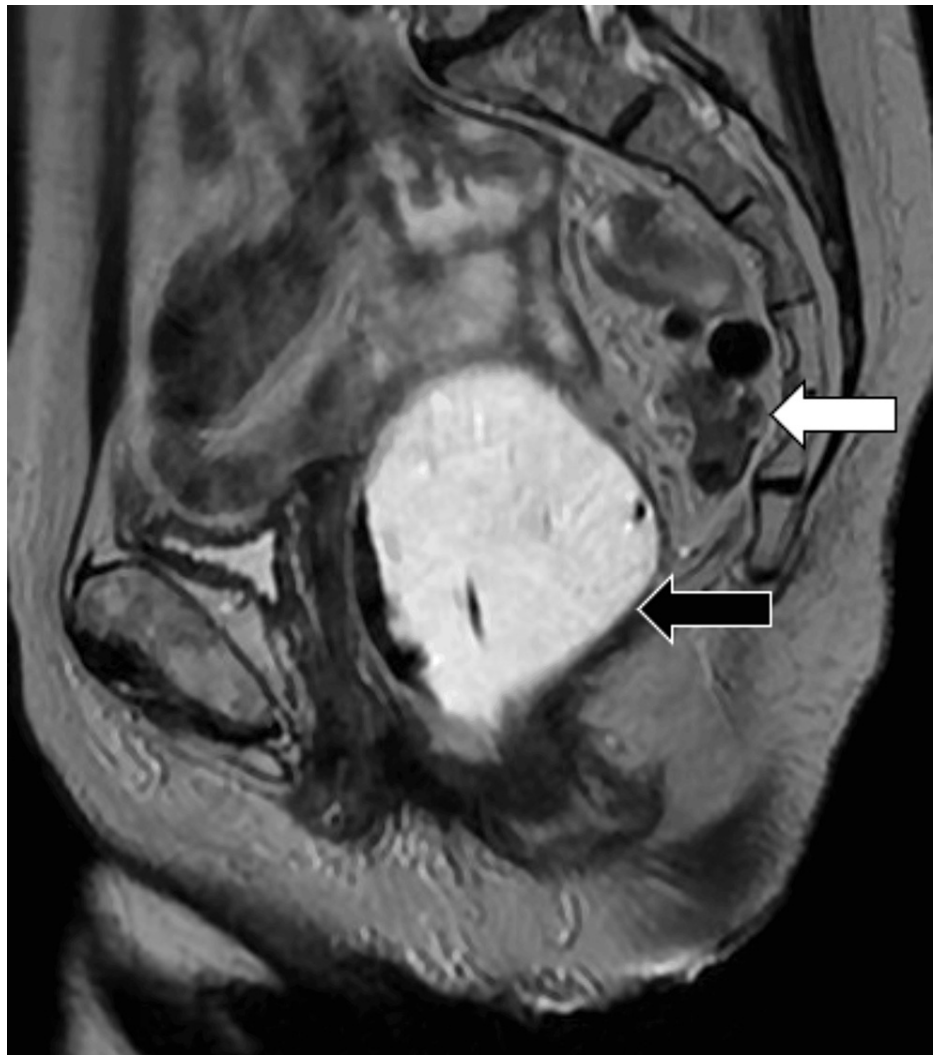

FIGURE 1: Sagittal T2-weighted image of the pelvis showing the sigmoid colon (white arrow) in the presacral space – posterior to the rectum (black arrow) during the rest phase of MR defecography. The rectum is distended with T2 hyperintense gel per MR defecography protocol.

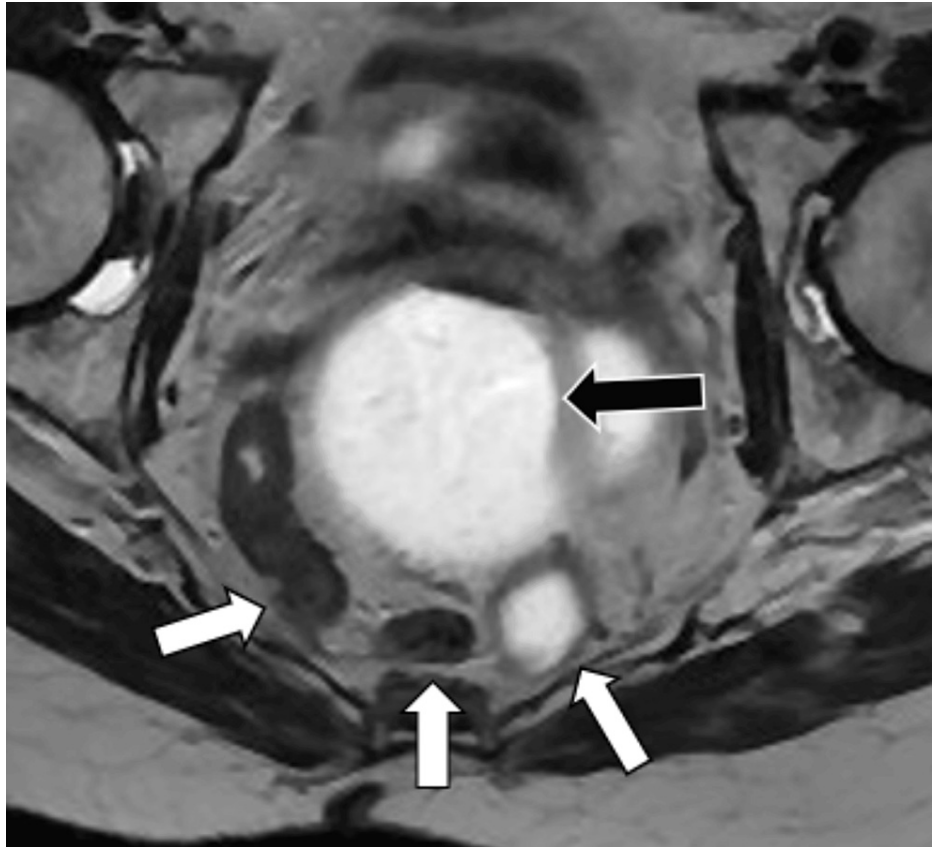


FIGURE 2: Axial T2-weighted image of the pelvis during MR defecography showing loops of the sigmoid colon (white arrows) in the presacral space – posterior to the distended rectum (black arrow).

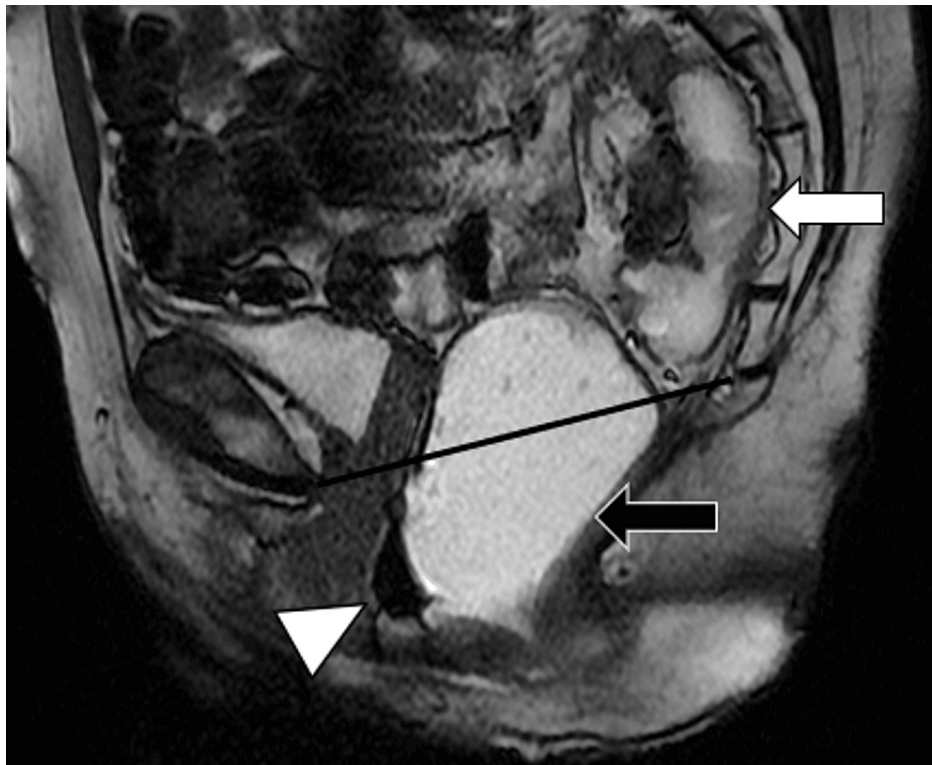


FIGURE 3: Sagittal T2-weighted image of the pelvis showing persistent retrorectal herniation of the sigmoid colon (white arrow) and pelvic floor laxity during the evacuation phase of MR defecography. The distended rectum (black arrow) descends below the pubococcygeal line (black line). An anterior wall rectocele is seen (white arrowhead).

Discussion

Retrorectal hernia is extremely uncommon, with limited reports of cases encountered in published scientific literature [1,6]. Retrorectal herniation is the pelvic floor protrusion of bowel loops through a defect in the peritoneum into the retrorectal space or other extraperitoneal spaces such as the Douglas' and Retzius' spaces [6]. Retrorectal herniation of the sigmoid colon is the protrusion of a segment of the sigmoid colon into the presacral space and posterior to the rectum through a defect in the peritoneum [1].

The symptoms of herniation vary from mild, non-specific chronic complaints such as vague abdominal pain, abdominal distension, pelvic pain, and constipation to more severe symptoms such as intermittent colicky pain and recurrent intestinal obstruction [5,7]. The severity of symptoms experienced by subjects also varies, mostly depending on the duration of herniation, the hernia's reducibility, and the development of complications. Patients with untreated large bowel obstruction may develop severe dehydration, peritonitis, or sepsis [8,9].

Like other internal hernias, retrorectal hernias tend to reduce spontaneously and are best imaged when symptomatic [10]. Retrorectal hernias, like other pelvic hernias, can be assessed by various imaging modalities, including fluoroscopy, ultrasound, and MR defecography. Fluoroscopy has long been regarded as the gold standard, but major limitations include its invasive nature and the use of potentially harmful ionizing radiation [11].

MR defecography is a safe, relatively non-invasive imaging method that enables the acquisition of multiplanar and multiparametric images, which assist physicians in evaluating pelvic compartments without exposure to potentially dangerous ionizing radiation [12]. Compared to other modalities, MR defecography is superior in evaluating the preoperative static and dynamic pelvic anatomy of patients with pelvic pathologies [13].

Conclusions

In conclusion, this case report details the finding of a rare case of retrorectal hernia in a patient with a complaint of constipation. The diagnosis of retrorectal hernia was made during pre-treatment MR

defecography. The management of retrorectal herniation depends on the severity of the patient's symptoms and varies from conservative to surgical reduction.

Additional Information

Author Contributions

All authors have reviewed the final version to be published and agreed to be accountable for all aspects of the work.

Concept and design: Olanrewaju Ogunleye, Eduardo Matta, Abeer H. Abdelhafez, Larry Kramer

Acquisition, analysis, or interpretation of data: Olanrewaju Ogunleye, Abeer H. Abdelhafez, Larry Kramer

Drafting of the manuscript: Olanrewaju Ogunleye, Eduardo Matta, Larry Kramer

Critical review of the manuscript for important intellectual content: Olanrewaju Ogunleye, Eduardo Matta, Abeer H. Abdelhafez, Larry Kramer

Supervision: Larry Kramer

Disclosures

Human subjects: Consent was obtained or waived by all participants in this study. **Conflicts of interest:** In compliance with the ICMJE uniform disclosure form, all authors declare the following: **Payment/services info:** All authors have declared that no financial support was received from any organization for the submitted work. **Financial relationships:** All authors have declared that they have no financial relationships at present or within the previous three years with any organizations that might have an interest in the submitted work. **Other relationships:** All authors have declared that there are no other relationships or activities that could appear to have influenced the submitted work.

References

1. Tully TE, Klatt FR, Feinberg SB: Retrorectal herniation of the sigmoid colon: report of a case . *Dis Colon Rectum*. 1976, 19:632-5. [10.1007/BF02590983](https://doi.org/10.1007/BF02590983)
2. Mansoori B, Paspulati RM, Herrmann KA: Mesentery, omentum, peritoneum: internal hernias and abdominal wall hernias. *Abdom Imaging*. Hamm B, Ros PR (ed): Springer, Berlin, Heidelberg; 2015. [10.1007/978-3-642-13327-5_202](https://doi.org/10.1007/978-3-642-13327-5_202)
3. Takeyama N, Gokan T, Ohgiya Y, et al.: CT of internal hernias. *Radiographics*. 2005, 25:997-1015. [10.1148/rg.254045035](https://doi.org/10.1148/rg.254045035)
4. Ghiassi S, Nguyen SQ, Divino CM, Byrn JC, Schlager A: Internal hernias: clinical findings, management, and outcomes in 49 nonbariatric cases. *J Gastrointest Surg*. 2007, 11:291-5. [10.1007/s11605-007-0086-2](https://doi.org/10.1007/s11605-007-0086-2)
5. Doishita S, Takeshita T, Uchima Y, et al.: Internal hernias in the era of multidetector CT: correlation of imaging and surgical findings. *Radiographics*. 2016, 36:88-106. [10.1148/rg.2016150113](https://doi.org/10.1148/rg.2016150113)
6. Cappabianca S, Reginelli A, Iacobellis F, et al.: Dynamic MRI defecography vs. entero-colpo-cysto-defecography in the evaluation of midline pelvic floor hernias in female pelvic floor disorders. *Int J Colorectal Dis*. 2011, 26:1191-6. [10.1007/s00384-011-1218-4](https://doi.org/10.1007/s00384-011-1218-4)
7. Martin LC, Merkle EM, Thompson WM: Review of internal hernias: radiographic and clinical findings . *AJR Am J Roentgenol*. 2006, 186:703-17. [10.2214/AJR.05.0644](https://doi.org/10.2214/AJR.05.0644)
8. Kahi CJ, Rex DK: Bowel obstruction and pseudo-obstruction . *Gastroenterology Clinics*. 2003, 32:1229-47. [10.1016/S0889-8553\(03\)00091-8](https://doi.org/10.1016/S0889-8553(03)00091-8)
9. Yeo HL, Lee SW: Colorectal emergencies: review and controversies in the management of large bowel obstruction. *J Gastrointest Surg*. 2013, 17:2007-12. [10.1007/s11605-013-2343-x](https://doi.org/10.1007/s11605-013-2343-x)
10. Paliogiannis P, Delogo L, Contu G, et al.: Small bowel emergencies: two surgical centers' experience and literature review. *European Surgery*. 2016, 48:18-25. [10.1007/s10353-015-0356-2](https://doi.org/10.1007/s10353-015-0356-2)
11. Lienemann A, Anthuber C, Baron A, Kohz P, Reiser M: Dynamic MR colpocystorectography assessing pelvic-floor descent. *Eur Radiol*. 1997, 7:1309-17. [10.1007/s003300050294](https://doi.org/10.1007/s003300050294)
12. Torricelli P, Pecchi A, Vetrucchio E, Vetrucchio S, Romagnoli R: Magnetic resonance imaging in evaluating functional disorders of female pelvic floor. *La Radiologia Medica*. 2002, 105:488-500.
13. Pescatori M, Zbar AP: Reinterventions after complicated or failed STARR procedure . *Int J Colorectal Dis*. 2009, 24:87-95. [10.1007/s00384-008-0556-3](https://doi.org/10.1007/s00384-008-0556-3)