



THE CONUNDRUM OF FELINE TRICHOMONOSIS

The more we learn the 'trickier' it gets

Jody L Gookin, Katherine Hanrahan and Michael G Levy



The culprit of infection

Trichomonads are members of the class Parabasalia, order Trichomonadida. These protozoa reside as parasites or commensals of animals, where they live in mucous membrane-lined, anaerobic-to-microaerophilic, non-sterile organ cavities such as the gastrointestinal and reproductive tracts. As is the case for most anaerobic protozoa, trichomonads lack many of their own biosynthetic pathways and rely on the salvage of nutrients from their host for survival. They are spindle to

tear-drop shaped, highly motile flagellates, similar in size to *Giardia* species. Only trophozoites are present in the life cycle (no true cyst stage), division is by binary fission, and transmission occurs directly between hosts via ingestion of trophozoites.

Trophozoites bear characteristic numbers of anteriorly directed flagella. In addition there is a single, posteriorly directed flagellum that arises at the anterior end and courses along the body creating an undulating membrane, which is a characteristic feature. A rigid, rod-shaped organelle, the axostyle, runs through the trophozoite and protrudes from the posterior end (Figure 1).

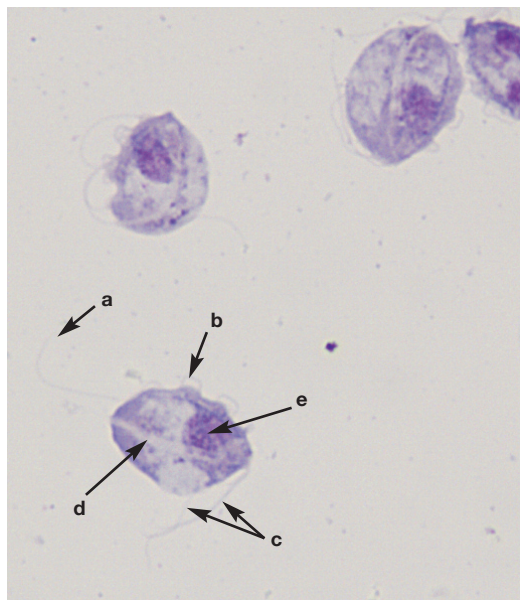


Figure 1 Cytological preparation of cultured feline *Tritrichomonas* species; note the posterior flagellum (a), undulating membrane (b), anterior flagella (c), axostyle (d) and nucleus (e). Wright-Giemsa, x100 magnification

Jody L Gookin
DVM, PhD, DACVIM

Katherine Hanrahan
DVM

Department of Clinical Sciences, College of
Veterinary Medicine, North Carolina State University,
Raleigh NC, USA

Michael G Levy
PhD

Department of Population Health and Pathobiology,
College of Veterinary Medicine, North Carolina
State University, Raleigh NC, USA

*Corresponding author: Jody_Gookin@ncsu.edu

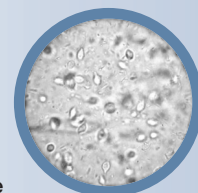


Practical relevance: Trichomonosis of the large intestine of the cat was described as a cause of chronic diarrhea over 20 years ago. The trichomonad was identified as *Tritrichomonas foetus*, with a genotype that is distinct from venereal *T foetus* of cattle.

Clinical challenges: Despite multiple means for diagnosis of the infection, including light microscopy, protozoal culture and PCR amplification using species-specific primers, tests with even greater sensitivity are needed. Feline trichomonosis is resistant to all commonly used antiprotozoal drugs. Ronidazole is currently the only drug demonstrated to be effective in eliminating the infection from cats; however, this drug has a narrow safety margin and clinical resistance is increasingly recognized. The more we learn about trichomonosis in cats, the more complicated and controversial the infection has become, ranging from what we should call the organism to whether we should even bother trying to treat it.

Global importance: Feline trichomonosis is recognized to occur worldwide and is regarded as one of the most common infectious causes of colitis in the domestic cat. The infection is widespread in catteries and shelters; and, while remission of diarrhea may occur over time, persistence of the infection is common.

Evidence base: This review provides a comprehensive examination of what is currently known about feline trichomonosis and pinpoints areas, based on the authors' opinion, where further research is needed.



JFMS Premier Reviews are invited state-of-the-art review papers on key issues in feline medicine and surgery. Written by expert international authors, these reviews are made freely available to maximise their impact.

Historical timeline

Feline *Tritrichomonas foetus* was first molecularly identified as a cause of chronic large bowel diarrhea in cats in 2001.¹ The duration of its existence as a feline pathogen before that time is unknown. Descriptions of feline trichomonosis date back to the early 1900s,²⁻⁷ with re-emergence in the contemporary literature in a series of two case reports in 1996 and 2000 by Dr Joseph Romatowski.^{8,9} While Romatowski assumed the observed trichomonads were a previously described, non-pathogenic species called *Pentatrichomonas hominis*, it seems likely in retrospect that these organisms were in fact feline *T foetus*.

As demonstrated in both experimentally and clinically infected cats, feline *T foetus* colonizes the distal ileum and colon,¹⁰ resulting in lymphoplasmacytic and neutrophilic colitis,¹¹ and chronic foul-smelling diarrhea.^{12,13}

A historical timeline of key advances in our understanding of feline *Tritrichomonas* species infection is shown in Table 1.

Table 1 Advances in recognition, diagnosis, treatment and understanding of disease pathogenesis of feline trichomonosis

Year	Discovery	Reference(s)
1996	✦ Trichomonads described in feces of three Pixie-bob kittens with colitis	8,9
1999	✦ Feline trichomonosis is refractory to treatment using common antiprotozoal drugs	12
2001	✦ Feline trichomonads molecularly identified as <i>Tritrichomonas foetus</i> ✦ Experimental infection of cats with feline <i>T foetus</i> results in diarrhea	1,14 10
2002	✦ Culture and PCR methods optimized for diagnosis of feline <i>T foetus</i> infection	15,16
2004	✦ Prevalence of <i>T foetus</i> in US purebred cats reported to be 31%	17
2005	✦ Histological lesions described associated with feline <i>T foetus</i> infection	11
2006	✦ Ronidazole reported as effective for treatment of feline <i>T foetus</i> infection	18
2007/ 2008	✦ Cross-transmission studies between cats and cattle demonstrate biological and pathogenic differences between feline and bovine <i>T foetus</i> isolates	19,20
2010	✦ Feline <i>T foetus</i> and bovine <i>T foetus</i> demonstrated to be genetically distinct	21-24
2013	✦ In vitro studies of feline <i>T foetus</i> identify cytopathic effects on intestinal epithelium ✦ Proposal to rename the feline trichomonad <i>Tritrichomonas blagburni</i> to distinguish it from the 'cattle genotype' of <i>T foetus</i>	25 26

Epidemiology and transmission

Tritrichomonas species have now been described in cats residing in many countries, with prevalence of infection ranging from 2–59%.^{17,27-47} Trichomonosis is presumed to be transmitted from cat to cat via the fecal-oral route. Trichomonads do not form true cysts and therefore do not persist for more than a few hours under clean, dry and aerobic conditions.¹⁵ Under laboratory conditions, trichomonads can survive for several days in moist feces¹⁵ and up to 24 h in contaminated water or urine.^{48,49} Garden slugs fed canned cat food spiked with feline *Tritrichomonas* species can subsequently pass trichomonads in their feces for several days. While slugs are an improbable source for normal dissemination of infection, these findings support the idea that transport of trichomonads from one time and location to another is possible through the intestinal tract of a second species.⁵⁰

T foetus is sexually transmitted in cattle; however, there is little evidence for venereal transmission of *T foetus* in cats. Studies conducted on the reproductive organs of purebred cats, where a high prevalence of intestinal *T foetus* infection was identified, found no light microscopic, immunohistochemical or molecular evidence of colonization by *T foetus*.⁵¹ Infection of the feline uterus with *T foetus* was reported in one cat, although it was unclear whether *T foetus* was a primary or opportunist



It is unlikely that reproductive tract infection by *T foetus* has a significant role in transmission of feline trichomonosis.

pathogen.⁵² One of the authors (JLG) has also observed and molecularly identified *T foetus* in purulent exudate from the uterus of a cat with pyometra, but this event is suspected to be rare. From these data, it is unlikely that reproductive tract infection by feline *T foetus* has a significant role in transmission of the disease in cats or is a frequent cause of reproductive tract pathology in breeding catteries.

Relationship between *Tritrichomonas* species from different hosts

The question regarding the relationship between feline isolates of *T foetus*, bovine isolates of *T foetus* and porcine *Tritrichomonas suis* has been a source of considerable debate. As discussed on page 263, several avenues have been pursued in an attempt to explore this.

Clinical presentation

Feline *Tritrichomonas* species infection is characterized by a waxing and waning large bowel diarrhea.^{12,72} The duration of diarrhea in the published literature ranges from 1 day to 8 years, and 59% of owners report that their cat has had diarrhea 'since adoption'.⁷² Frequency of bowel movements ranges from once to eight times a day;⁷² the feces often contains mucus (59% of cats) and/or fresh blood (46% of cats), and there may be accompanying

Relationship of feline *T foetus* to bovine *T foetus* and porcine *T suis*

*T foetus*⁵³ is a well recognized pathogen of cattle and is sexually transmitted from bull to cow. In the cow *T foetus* infects the vagina, cervix and uterus and may result in mild infection or more severe sequela including vaginitis, early abortion and occasional pyometra, resulting in permanent infertility.⁵⁴ The porcine trichomonad *T suis* colonizes hollow organs including the nasal cavity, stomach, small and large intestines, and cecum of swine.⁵⁵ It had earlier been described as a putative pathogen associated with rhinitis in pigs.^{56,57} However, additional investigation has shown it to be a harmless commensal in that host.^{58,59} When trichomonosis was first described in cats in the late 1990s the infectious agent was identified as *T foetus* based on limited molecular comparison between bovine and feline isolates.¹

The identity of the bovine, porcine and feline isolates is of more than academic interest as many jurisdictions have endeavored to eliminate *T foetus* from their cattle populations using a variety of methods including testing the preputial membranes of bulls and, if found positive for this pathogen, culling these animals from the breeding population. Such efforts might prove futile if the trichomonads from swine and cats are able to re-infect cattle, although the means by which this might occur are not clear. If these organisms are related 'sister species', but not identical, then elimination of *T foetus* from cattle would allow an area to be declared free of this known cattle pathogen even when trichomonads persist in swine and cats. Several approaches have been undertaken in an attempt to answer this question.

Based on a plethora of comparisons, including cross-transmission studies, virulence assays, molecular analyses, geographic distribution, morphological characteristics and immunological analyses, there appear to be few differences between the *T foetus* bovine 'genotype' and porcine *T suis*.^{60,61} Experimental infection of cattle with *T suis* resulted in similar pathology as infection with the autologous cattle parasite, and pigs have been found to be easily infected with the cattle trichomonad.⁶²⁻⁶⁴ This has led to the conclusion that these sister species are one and the same.⁶⁵ Some investigators favor suppressing the name *T suis* in favor of *T foetus* for isolates from these two hosts.²¹ Some favor suppressing *T foetus* in favor of the earlier assigned (and accepted by Genbank) *T suis*. However, others suggest caution and favor development of additional data before a final decision is made – which may further add to the confusion regarding these 'species'.⁶⁶ Despite their similarity and experimental cross-transmissibility between species, it appears that naturally occurring transmission of *T foetus/T suis* infection between swine and cattle is uncommon.⁶⁷

While strikingly similar to one another, recent studies have demonstrated significant genetic differences between the *T suis/T foetus* 'cattle genotype' and the *T foetus* 'feline genotype'.⁶⁸

Sequencing of ITS-1–5.8 rDNA gene through ITS-2 of both cattle and feline isolates revealed a single nucleotide polymorphism that distinguishes feline isolates from those of cattle and swine. Furthermore, DNA sequencing revealed 10 distinct genotypic polymorphisms between the *T suis/T foetus* 'cattle genotype' and the *T foetus* 'feline genotype' for a total of 1.03% difference between genotypes from these hosts, with the greatest difference noted for the cysteine protease (CP) genes.²² Additional differences between cattle and feline isolates have also been reported for the eukaryotic elongation factor 1 α (EF-1 α) locus and CP8.^{21,23} Based on this and other data it has been concluded that the feline and cattle isolate may be divided into two distinct genotypes.^{22,24} It has been proposed that the feline trichomonad be renamed *Tritrichomonas blagburni* based on molecular, host specificity and pathology.²⁶ It is important to note that *T blagburni* is not a new trichomonad infection in cats, it is merely a proposal to rename the feline *T foetus* organism to distinguish it from the bovine organism (which is a notifiable infection in many countries) and has no impact on diagnosis or treatment of trichomonosis in cats.

In contrast to cross-transmission studies between swine and cattle trichomonads, experimental infection of cattle with a feline *T foetus* isolate resulted in a similar, but not identical, course of colonization of the vagina, cervix and uterus but less endometrial pathology than caused by bovine *T foetus*.¹⁹ When cats were infected with a bovine *T foetus* isolate the investigators reported that the bovine isolate was less pathogenic for cats than a feline isolate.²⁰ The conclusion that these studies indicate lack of pathogenicity of bovine *T foetus* in cats or feline *T foetus* in cattle needs to be interpreted with caution as only one isolate was examined. Moreover, based on experimental studies in cats, even feline *T foetus* does not always cause diarrhea when used in experimental infections of cats.⁶⁹ In addition, 'feline genotypes' of *T foetus* can reportedly be isolated from pigs;⁷⁰ and aborted fetuses from *T foetus*-infected cows have trichomonads in their intestinal tract,⁷¹ with subepithelial invasion by the trichomonads appearing identical to that described in some cats.¹¹ Accordingly, additional studies of cross-transmission of the *T foetus* 'cattle genotype' and *T foetus* 'feline genotype' between cattle, cats and pigs are warranted to prove or disprove the potential for cross-infection.

Based on a contemporary controversy over renaming the agent(s) of bovine and porcine trichomonosis,^{21,65,66} cross-transmissibility studies between cattle and cats that have involved only a single feline isolate,^{19,20} and the rapidly evolving field of research pertaining to these organisms and their host specificity, it is the authors' opinion that renaming the feline infection at this time may be premature.

straining (43% of cats).⁷² Diarrhea is typically semi-formed to 'cow pie' in consistency and malodorous. In most cases infected cats maintain good health, and a normal appetite and body condition, which presumably reflects confinement of the infection to the colon. However, some kittens will develop fecal incontinence, and overt swelling and inflammation of the anal region from fecal scalding.

Cats with diarrhea and concurrent trichomonosis are generally young (median age, 1 year),^{30,31,72,73} but have ranged in age from 1 month to 16 years.^{13,72} Older infected cats may be more likely to be clinically healthy or may have a long history of diarrhea dating back to kittenhood. Cats originating from catteries (ie, pedigreed) or shelters appear to be at increased risk for becoming infected,^{30,41,46}

Feline trichomonosis is characterized by a waxing and waning large bowel diarrhea. Most infected cats maintain good health, and a normal appetite and body condition.



presumably because of dense housing conditions and increased likelihood of fecal–oral transmission. For example, in the USA the prevalence of trichomonosis among cats in large-scale hoarding operations is 39%,⁷⁴ among pedigree cats is 31%,¹⁷ and among mixed populations of pet cats ranges from 4–10%.^{33,75} There does not appear to be any sex predilection nor consistent reports in support of any specific breed predilections for trichomonosis in cats.

A common feature of *Tritrichomonas* species diarrhea is that during administration of antimicrobial drugs fecal consistency improves and trichomonads are difficult to detect, but diarrhea containing trichomonads reappears shortly after treatment is discontinued.¹² This is presumably due to a decrease in the population of bacteria in the colon on which the trichomonads thrive and not a direct effect of the antimicrobial drugs on trichomonad viability.

Misdiagnosis of *Giardia* species infection is common in cats with trichomonosis. Cats diagnosed with *Giardia* species based on observation of trophozoites on a direct fecal wet mount examination, and that fail to respond to appropriate antimicrobial therapy for *Giardia* species, should be re-evaluated for the possibility that the observed trophozoites were *Tritrichomonas* species.

Pathogenesis

Great strides have been made in the past 15 years in determining the molecular identity and genetics of feline *Tritrichomonas* species; and also in developing diagnostic tests and, to some extent, effective treatments for this infection. However, very little is known about how these organisms actually cause diarrhea. Based on what is understood about the pathogenic mechanisms of bovine *T foetus* in the reproductive tract, and what can be observed in cats infected with feline *Tritrichomonas* species, multiple factors are likely.⁷⁶

Pathogenic factors associated with trichomonosis include interaction with endogenous bacterial flora, adherence to host mucus and epithelium, and elaboration of cytotoxins and enzymes.⁷⁷ Infection of specific-pathogen-free cats with cultures of feline *Tritrichomonas* species results in chronic colonization of the terminal ileum, cecum and colon, and large bowel diarrhea similar to that observed in

naturally infected cats.¹⁰ In naturally infected cats, *Tritrichomonas* species reside within the superficial mucus and in contact with the surface epithelium of the cecum and colon.¹¹ Moreover, uptake of *Tritrichomonas* species specific antigen by the colonic surface epithelial cells can be demonstrated.¹⁰ This is associated histologically with infiltration of lymphocytes, plasma cells and neutrophils into the colonic lamina propria.¹¹ In rare instances, trichomonads can be observed invading the subepithelium.¹¹ Studies have demonstrated that feline *Tritrichomonas* species isolates adhere directly to monolayers of intestinal epithelial cells in vitro by specific ligand–receptor interactions.²⁵ Cysteine proteases appear to mediate both adhesion and cytotoxic effects on the intestinal epithelium, and are being explored as possible treatment targets to ameliorate the clinical signs of infection.^{68,78,79}

Large scale studies to define the transcriptome and proteome of *Tritrichomonas* species to identify virulence factors and to screen large libraries of drugs for effectiveness in killing *Tritrichomonas* species are actively ongoing by several teams of investigators.^{68,80}

Diagnosis of feline trichomonosis

Feline *Tritrichomonas* species infection is diagnosed on the basis of identifying the organism on a fecal wet mount examination, after culture of feces in media that foster the growth of *Tritrichomonas* species, or by PCR performed on DNA extracted from a fecal sample (Table 2).

Table 2 Approaches used for diagnosis of feline trichomonosis, with key attributes and limitations of each method

Diagnostic approach	Techniques and considerations
Direct fecal wet mount	<ul style="list-style-type: none"> ❖ Feces must be fresh and diarrheic ❖ Use a scant amount of feces in saline and mount under a coverslip ❖ Lower the microscope condenser ❖ Look for motile flagellates <ul style="list-style-type: none"> – distinguish trichomonads from <i>Giardia</i> species trophozoites ❖ Sensitivity is ≤14% for diagnosis of infection ❖ Difficult to differentiate <i>Tritrichomonas</i> species from <i>Pentatrichomonas hominis</i>
Fecal culture	<ul style="list-style-type: none"> ❖ Needs to be performed ‘in-house’ (shipping not recommended) ❖ Only use a very small amount of feces (rice grain size) ❖ Numbers of organisms and time needed for growth depends on temperature used for incubation ❖ Sensitivity is approximately 55% for diagnosis of infection ❖ Does not differentiate <i>Tritrichomonas</i> species from <i>P hominis</i>
PCR	<ul style="list-style-type: none"> ❖ Can detect both live and dead organisms ❖ Most sensitive means for diagnosis of infection ❖ False-negative test results are likely common <ul style="list-style-type: none"> – avoid by collecting the ‘best’ fecal sample (see box on page 265)
Histopathology	<ul style="list-style-type: none"> ❖ Trichomonads can be very difficult to identify without special detection methods ❖ Suspected to be a very insensitive means for diagnosis of infection ❖ Microscopic examination of multiple tissue sections is required ❖ Pathologist should be made aware that trichomonosis is a differential diagnosis

Fecal sampling for diagnosis of trichomonosis

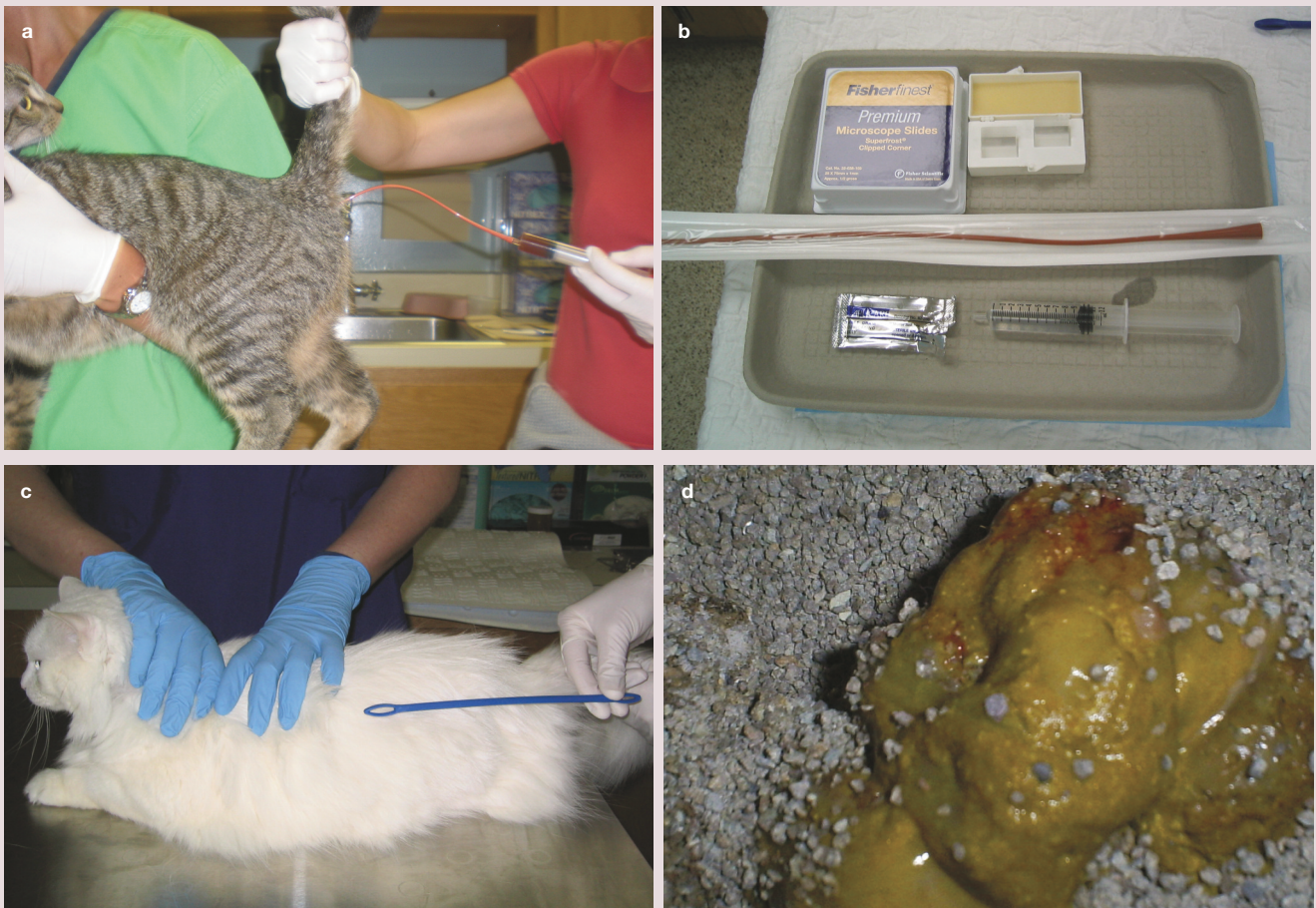

Figure 2 (a) A liquid feces sample can be obtained from the proximal colon by inserting a red rubber catheter into the colon and gently introducing around 10 ml of sterile saline and then re-aspirating the sample. The authors refer to this as a 'colon flush'. A video demonstrating how to perform a colon flush to collect feces for *Tritrichomonas* species testing can be viewed at JodyGookin.com. (b) A typical 'kit' for performing a colon flush, which includes a red rubber catheter, catheter-to-syringe adapter, syringe with 10 ml of saline, lubricant, microscope slides and coverslips. (c) A fecal loop can be inserted into the anus. As long as the loop passes with ease and the cat is cooperative, the loop can be passed as far as the proximal colon (insertion distance shown by holding the fecal loop alongside the cat). (d) A freshly voided fecal sample from a cat with diarrhea (note the lack of form, and presence of mucus and fresh blood)

Tritrichomonas species cannot be detected by routine fecal analyses such as centrifugation flotation, and the organisms do not survive refrigeration. Suitable fecal samples may be obtained by (in order of preference): (1) passing a red rubber catheter into the proximal colon for the instillation and recovery of several milliliters of sterile saline; (2) inserting a fecal loop per rectum into the proximal colon; or (3) collecting a freshly voided specimen free of contaminating litter (Figure 2).

For the colon flush technique, approximately 10 ml of sterile saline is flushed through the catheter into the colon and then gently aspirated. A drop of the recovered solution can then be examined directly under the microscope for trichomonads or placed in a fecal culture pouch. Alternatively, the solution can be sedimented in a centrifuge at approxi-

How to collect the 'best' fecal sample

- ❖ Select only fresh and diarrheic feces for diagnostic testing
- ❖ Any oral antimicrobial agents should be withdrawn for a minimum of several days prior to fecal collection
- ❖ Collect feces using the colon flush technique (+++), using a fecal loop inserted per rectum (++) , or immediately after voiding (+)
- ❖ Do not refrigerate feces intended for wet mount examination or culture, as this will kill the trichomonads
- ❖ Collect the recommended amount of feces for optimal test results

mately 2000 x g for 5 mins and the resulting fecal pellet submitted for PCR analysis.

Fecal samples should always be fresh, devoid of contaminating litter, and kept unrefrigerated before testing. If a fecal sample is being transported to the veterinary clinic or a diagnostic laboratory, survival of trichomonads can be extended by diluting the

sample with saline to prevent desiccation (3 ml of 0.9% saline per 2 g of feces).¹³ After 6 h of delay, analysis results for the sample will begin to lose diagnostic sensitivity for observation or culture of live organisms.⁴⁸ Samples obtained from non-diarrheic or dry stools are not suitable for use in testing for *Tritrichomonas* species and rarely yield positive test results, even if infection is present. Further, concurrent administration of antibacterial drugs at the time the sample is collected appears to decrease the success of finding *Tritrichomonas* species. Therefore, antimicrobial therapy of any type should be discontinued for a minimum of several days before collecting samples for testing.

Direct fecal wet mount

For the direct examination of feces for the presence of motile trophozoites, commonly referred to as a ‘wet mount’, a scant amount of feces is diluted with saline solution and examined under a coverslip using a light microscope equipped with a 20 x or 40 x objective. It is imperative that the fecal sample is diarrheic and fresh (preferably examined immediately after collecting from the cat), because visualization of trichomonads is highly dependent on their motility and therefore viability. If the feces are formed or aged then motile organisms are unlikely to be present and dead organisms are very difficult to identify. The most important thing to look for is motile flagellates. Lowering the microscope condenser will increase contrast and enhance visualization of trichomonads (Figure 3).

Interpretation of diagnostic tests for trichomonosis

It is important to recognize that no available diagnostic test has 100% sensitivity for detection of *Tritrichomonas* species infection and that shedding of trichomonads may be intermittent.⁷³ If test results are positive, the cat is considered to be infected with *Tritrichomonas* species. However, if test results are negative, the possibility of infection with *Tritrichomonas* species cannot be excluded, particularly in cases where there is a high index of suspicion for infection. In these cases, veterinarians should strongly consider repeated testing.



Samples obtained from non-diarrheic or dry stools rarely yield positive test results, even if *Tritrichomonas* infection is present.

While a direct fecal wet mount examination is the easiest way to make a diagnosis of trichomonosis in cats, it is also the least sensitive.^{10,17} In cats with asymptomatic, experimentally induced infection, only 2% of cases could be diagnosed on the basis of a fecal wet mount examination.¹⁰ In cases of naturally occurring infection, diagnosis rates on the basis of a wet mount examination range from 2.6–14%.^{17,31,39} In other words, it is always worth performing a fecal wet mount examination because it might yield an easy diagnosis. However, due to low sensitivity, a negative wet mount examination cannot be relied upon to rule out trichomonosis. Moreover, *Tritrichomonas* species can be difficult to distinguish from *Giardia* species (see below) and also (what are assumed to be non-pathogenic) intestinal trichomonads such as *P hominis* based on light microscopic examination of live organisms. *P hominis* is diagnosed uncommonly in cats,^{81–83} and so feline trichomonads are generally presumed to be *Tritrichomonas* species. If desired, *P hominis* can be distinguished from *Tritrichomonas* species on the basis of species-specific *P hominis* PCR testing.^{16,81}

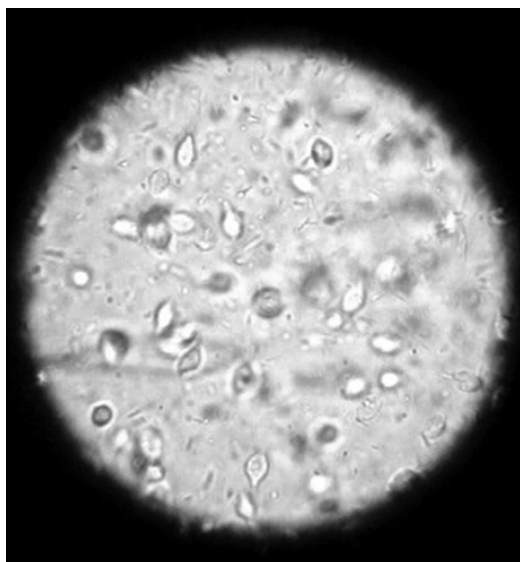


Figure 3 Fecal wet mount photographed through the ocular lens of a light microscope. Copious numbers of tear-drop shaped trichomonads can be observed in various depths within the saline solution. Courtesy of Dr Bronya Redden

Trichomonosis, giardiasis or both?

Misdiagnosis of *Giardia* species infection is common in cats with trichomonosis. So too is coinfection.



Trichomonad trophozoites are nearly identical in size to *Giardia* species. *Giardia* species trophozoites have a concave shape similar to a rose petal and sluggish motility that is reminiscent of a ‘falling leaf’. In contrast, trichomonads are tear-drop shaped, possess an undulating membrane that courses the entire length of the body, and demonstrate vigorous motility. A video comparing the light microscopic appearances of live trichomonads with *Giardia* species trophozoites can be viewed at JodyGookin.com.

If difficulty is encountered in distinguishing trichomonads from *Giardia* species trophozoites, a *Giardia* species antigen test can be performed on the feces. The presence of trichomonads will not produce a positive *Giardia* species antigen test result. However, coinfection with *Giardia* species can be observed in up to 22–54% of cats with *Tritrichomonas* species infection.^{17,35,39,72} Therefore, a positive *Giardia* species antigen test result does not rule out the possibility of coinfection with *Tritrichomonas* species.

Fecal culture

If repeated fecal wet mount examination results are negative for trichomonads, feces may be cultured using commercially available pouches (InPouch TF Feline; Biomed Diagnostics)¹⁵ (Figure 4). Fecal culture using the InPouch TF is more sensitive than fecal wet mount examination for diagnosis of *Tritrichomonas* species infection;¹⁷ approximately 55% of cats with naturally occurring *Tritrichomonas* species infection can be diagnosed using this culture system.^{15,17} The pouches are made of clear plastic and contain a proprietary culture medium and antibiotics that suppress unwanted growth of fecal bacteria.

For diagnosis of feline *Tritrichomonas* species, the pouches should be inoculated with 0.05 g of feces (approximately the size of a grain of rice) and incubated in an upright position in the dark at either 37°C (98.6°F) or room temperature (25°C [77°F]). At 37°C, the trichomonads will multiply quickly and many organisms can be observed by light microscopy within 72 h. Incubation at room temperature will produce fewer trichomonads, and it may take up to 12 days after inoculation to obtain positive results. The fecal sample must contain live organisms to obtain positive results from fecal culture, and optimum growth conditions for the organisms must be maintained during the test period. Therefore, care is required in handling the specimen and the pouch to avoid a false-negative result. It is strongly recommended that these cultures are performed in the clinic rather than by an external diagnostic laboratory to avoid the risk of the trichomonads dying during shipment of the fecal sample or pouch.

Trichomonads can be observed within the pouch by placing it directly on the stage of a light microscope under a 20 x or 40 x objective. *Giardia* species cannot survive in the culture medium for longer than 24 h¹⁵ and therefore any trophozoites proliferating within the pouch can be presumed to be trichomonads. Both feline *Tritrichomonas* species and feline *P hominis* are able to survive in the InPouch TF medium.⁸² *P hominis*, however, is considerably less common than *Tritrichomonas* species in cats.^{12,17,81} As mentioned, *P hominis* can be distinguished from *Tritrichomonas* species on the basis of species-specific *P hominis* PCR testing.^{16,81}



Figure 4 Pouch system for culture of feline *Tritrichomonas* species. A video demonstrating how to inoculate the pouch with a fecal sample for culture of *Tritrichomonas* species can be viewed at JodyGookin.com



Periods of asymptomatic infection are common in *Tritrichomonas* species infected cats and can be very difficult to diagnose.

Polymerase chain reaction

A sensitive and specific single-tube nested PCR based on amplification of a conserved portion of the *Tritrichomonas* species internal transcribed spacer region (ITS1 and ITS2) and 5.8S rRNA gene from feline feces has been described.¹⁶ PCR-based testing is superior to fecal culture for diagnosis of naturally infected cats,^{17,73} can detect both live and dead organisms, and has an analytical sensitivity of 10 *Tritrichomonas* species organisms per 100 mg of fecal sample.⁸⁴

For PCR analysis, the authors prefer to submit feces in 70% isopropyl alcohol (ie, rubbing alcohol) in order to preserve the DNA and kill the fecal bacteria. This also allows the sample to be both held for several days and shipped at room temperature, which saves on the overall cost of PCR testing. Caution should be taken when submitting samples to a commercial laboratory that uses DNA extraction methods based on PCR diagnosis of trichomonosis in cattle. These methods may not be suited to extracting quality DNA from feline fecal samples.⁸⁴

A sensitive and specific PCR for amplification of *P hominis* 18S rRNA genes from DNA extracted from fecal samples is also commercially available.⁸¹

Histopathology

Trichomonads can be observed by routine light microscopic methods in the lumen of crypts or within mucus lining the surface epithelium of the colon. However, because trichomonads are lumen-dwelling and extremely fragile, their preservation in intestinal biopsy specimens is highly unreliable. Trichomonads can also be difficult to differentiate from individually shed epithelial cells. It is advisable to indicate to the pathology service that *Tritrichomonas* species infection is a differential diagnosis, as a minimum of six tissue sections will need to be examined to achieve at least 95% confidence that any trichomonads would be identified.¹¹ Immunohistochemistry,^{10,11} fluorescence in situ hybridization⁸⁵ and chromogenic in situ hybridization⁸³ techniques have been described as means to enhance detection of *Tritrichomonas* species in histologic specimens, but are not commercially available. For tissue in which trichomonads are observed, DNA can be extracted from the formalin-fixed, paraffin-embedded specimen and used in PCR to identify the trichomonads as *Tritrichomonas* species.⁸⁵

Treatment of feline trichomonosis using ronidazole

Ronidazole (RDZ), a nitroimidazole similar to metronidazole (see box), is the only antimicrobial for which convincing efficacy for treatment of feline *Tritrichomonas* species infection has been demonstrated.^{18,31,72,87} Most cats with *Tritrichomonas* species infection show significant improvement in fecal consistency, or resolution of diarrhea, during the course of treatment with RDZ.

Pharmacology and pharmacokinetics

RDZ is not approved by the US Food and Drug Administration for human or veterinary use in the USA and is banned from use in food animals because of potential human hazards. Accordingly, due diligence is required to protect humans from exposure to RDZ, and veterinarians are advised to prescribe the drug only in cases of confirmed *Tritrichomonas* species infection after obtaining the owner's informed consent. Several pharmacies compound chemical grade RDZ for veterinary use. Because of its foul taste and undetermined stability, compounding into gelatin capsules rather than flavored liquids is recommended. Several formulations of RDZ for treatment of trichomonosis in birds can be obtained without prescription from pigeon supply warehouses. However, these products are not recommended due to their undetermined quality, composition and low active drug concentration.

Studies investigating the pharmacokinetics of RDZ in cats suggest that 30 mg/kg PO q24h for 14 days is likely to be most effective in resolving diarrhea and eradicating *Tritrichomonas* species infection⁸⁸ (see box below). There is no evidence that higher or more frequent doses of RDZ, or administration over a longer period of time, is more effective. Following oral administration, RDZ is rapidly and completely absorbed by the gastrointestinal tract into the systemic circulation, where the drug has a long elimination half-life. This suggests that RDZ gains access to trichomonads in the colon by first entering the

Nitroimidazole antimicrobials

Trichomonads are generally susceptible to treatment with nitroimidazoles because the organisms use anaerobic metabolic pathways that reduce these drugs to cytotoxic nitro anions that disrupt their DNA. Resistance of feline *Tritrichomonas* species to metronidazole is presumed to be prevalent based on common treatment failure with this drug and has prompted investigation of related nitroimidazoles such as tinidazole and ronidazole for treatment of the infection.^{12,18,69,86} Tinidazole at high doses fails to consistently eradicate the infection from experimentally infected cats⁶⁹ and has not been rewarding for treatment of naturally infected cats.

Due diligence is required to protect humans from exposure to ronidazole. The drug should only be prescribed in cases of confirmed infection.



bloodstream. These properties likely predispose some cats to neurotoxicity, particularly with higher than recommended doses.

'Colon-targeted' formulations of RDZ have been investigated in an effort to increase the effectiveness and decrease the toxicity of RDZ.⁸⁹⁻⁹¹ These formulations consist of encapsulating RDZ inside an indigestible coating of guar gum or chitosan. The coating prevents drug release until the capsule or tablet reaches the colon. Once in the colon, bacteria digest the coating and release RDZ directly at the site of infection.

Toxicity

Signs of RDZ neurotoxicity include lethargy, inappetence, ataxia and seizures.⁹² Until recently, the prevalence of these side effects among cats undergoing treatment with RDZ was unknown. However, a newer retrospective study by Xenoulis et al reports discontinuation of RDZ in only 4/79 (5%) of cats due to development of anorexia or neurological signs.⁹³ Side effects of RDZ in cats generally resolve if the drug is withdrawn immediately, though may continue to worsen for the next few days before slowly subsiding, and may require costly and intensive emergency veterinary care.

Cats must be monitored closely while receiving RDZ. If signs of toxicity are observed, owners should be advised to discontinue treatment. Continuing treatment

Recommendations when treating with ronidazole

- ❖ **Ensure appropriate case selection:**
 - confirmed *Tritrichomonas* species infection
 - ≥12 weeks of age and not currently nursing kittens
 - not otherwise systemically ill
- ❖ **Obtain informed consent from owner**
- ❖ **Order RDZ from a veterinary compounding pharmacy:**
 - compound into gelatin capsules (avoid liquid formulations)
 - only use 100% pure RDZ
 - Dose as closely as possible to the patient's body weight
 - 30 mg/kg PO q24h for 14 days
- ❖ **Avoid the possibility of reinfection:**
 - keep litterbox clean and dry
 - quarantine during treatment and until outcome can be assessed
- ❖ **Monitor for side effects:**
 - inappetence, lethargy, neurological signs or any new clinical sign
 - stop immediately if seen
 - do not reinstitute or repeat treatment if signs of toxicity occur

after onset of toxicity could result in life-threatening complications. RDZ should be avoided in cats with systemic illnesses that could confound recognition of adverse drug effects and should not be given to pregnant or nursing queens or their unweaned kittens. If treatment with RDZ must be discontinued due to clinical signs of toxicity, the cat should be retested for *Tritrichomonas* species infection. Many of these cats will have received sufficient RDZ to have cleared the infection.

Efficacy

Until recently, the efficacy of RDZ treatment of naturally infected cats under field conditions was unknown. In a retrospective study by Xenoulis et al, outcome data was reported for 45/79 cats diagnosed with *Tritrichomonas* species infection and undergoing treatment with RDZ at a dose of 30 mg/kg PO q24h.⁹³ A complete, or close to complete, resolution of diarrhea was reported for 64% (29/45) of cats and partial or no improvement or relapse of diarrhea in 36% (16/45) of cats. Among the cats not responding, 31% (5/16) were treated with less than the recommended dose or duration of RDZ. Follow-up testing for persistence of underlying *Tritrichomonas* species infection in these cats was not reported.

A study by Holliday et al reported 100% resolution or dramatic reduction in clinical signs of diarrhea in 24 cats with *Tritrichomonas* species treated with RDZ at 30 mg/kg PO q12h.³¹ Upon completion of treatment, all cats were negative for *Tritrichomonas* species by culture of a rectal swab; however, positive results were observed in the only cat tested by means of PCR. Bell et al reported 100% resolution of diarrhea in 12 cats with *Tritrichomonas* species treated with RDZ at 30 mg/kg PO q12h.³⁶ After treatment, nine cats tested negative for *Tritrichomonas* species by means of PCR (seven cats) or fecal wet mount (two cats). Finally, Grellet et al reported treating 25 *Tritrichomonas* species infected cats with guar gum-coated RDZ at 30 mg/kg q24h for 14 days. After treatment, 21 cats (84%) tested negative for *Tritrichomonas* species by means of PCR performed on a fecal swab. The effect of RDZ on the clinical signs of diarrhea was not reported.⁹⁰

Based on these studies, a conservative estimate is that 60% of cats treated with RDZ will have close to complete resolution of clinical signs. What remains unclear is to what extent RDZ has eradicated vs merely suppressed the infection below the limit of detection. Additionally, small fecal sample sizes (eg, swab) and use of tests with lower sensitivity than PCR (wet mount or culture) are apt to increase false-negative test results in the aforementioned studies.

Post-treatment testing

Determining whether RDZ has eliminated vs concealed *Tritrichomonas* species infection in any given cat remains an area of considerable frustration. If diarrhea persists or recurs ≥ 2 weeks after completion of RDZ treatment then cats should be retested for *Tritrichomonas* species by means of PCR performed on a fecal sample collected by the colon flush technique (see page 265). If this test result is negative in a cat with diarrhea then persistent infection is considered unlikely. Repeating this testing with confirmatory negative results would further support the absence of persistent infection.

The greatest difficulty arises in confidently ruling out persistent infection in a cat that no longer has diarrhea. In the authors' experience, periods of asymptomatic infection are common in *Tritrichomonas* species infected cats and can be very difficult to diagnose. In cases where confirmation of *Tritrichomonas* species eradication is of particular relevance (eg, re-introduction of a treated cat into a cattery), the authors will treat the cat with lactulose 'to effect' to induce a soft diarrhea and then test a colon flush sample for *Tritrichomonas* species by means of PCR. Negative test results in this instance would come as close as possible to supporting the absence of infection.

Treatment failure

Treatment failure with RDZ should be established by confirmation of persistent *Tritrichomonas* species infection and not presumed on the basis of failure of the diarrhea to resolve. Some cats with persistent or recurrent diarrhea after treatment with RDZ may no longer have *Tritrichomonas* species infection. The cause of diarrhea and its clinical course in these cats remains unknown. In such cases a search for other infectious and non-infectious causes of diarrhea may be warranted, as well as empiric treatment with fenbendazole for occult parasitism. Common coinfections observed in pedigree cats with *Tritrichomonas* species diarrhea include coronaviruses, *Clostridium perfringens* and *Giardia* species.⁴⁶

If *Tritrichomonas* species infection is confirmed following treatment with RDZ, three possibilities need to be considered (see box below). First, underdosing: the cat may have been administered an insufficient dose or duration of RDZ, or an impotent formulation of RDZ (eg, 10% powder formulation for



Determining whether ronidazole has eliminated or simply concealed *Tritrichomonas* species infection in an individual cat remains an area of considerable frustration.

The prevalence in cats of RDZ-resistant *Tritrichomonas* species infection is unknown, but likely significant.



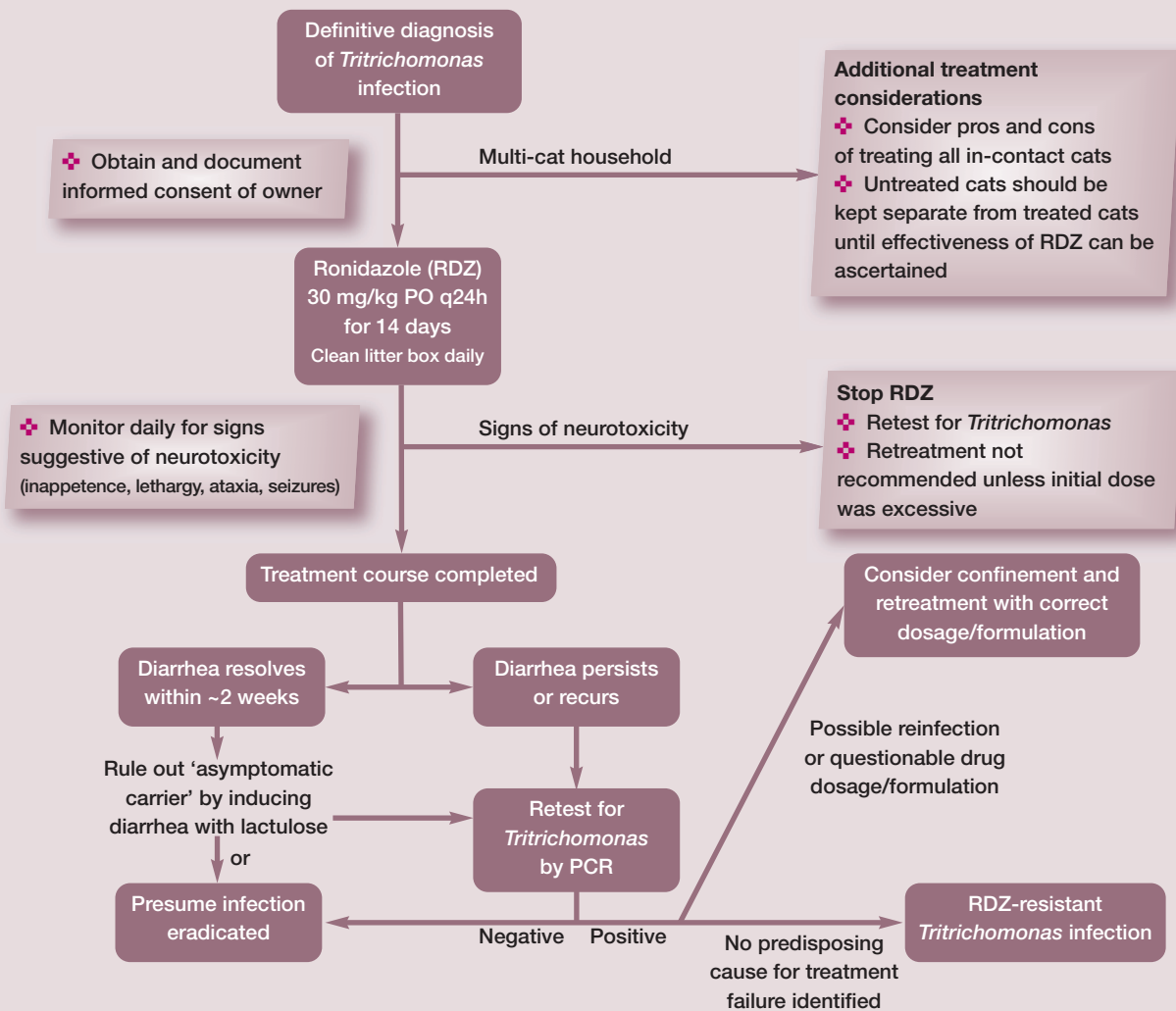
pigeons); or it may have failed to consume sufficient amounts of the RDZ. These issues can be largely prevented by treating cats with gelatin capsule-compounded pure RDZ at the recommended dosage.

Second, treatment failure could be attributed to reinfection by another cat in the household that may or may not be showing clinical signs of diarrhea. It is a common misconception in multi-cat settings that only cats with diarrhea are infected with *Tritrichomonas* species. When presumed uninfected cats are allowed contact with cats that later fail treatment with RDZ, reinfection (whether likely or unlikely) can

never be ruled out. This possibility can be prevented by confining *Tritrichomonas* species infected cats during treatment and until their treatment outcome can be assessed.

Finally, if other causes of treatment failure can be ruled out, persistent infection can likely be attributed to infection by a 'strain' of *Tritrichomonas* species that is resistant to RDZ.⁹⁴ The prevalence of RDZ-resistant *Tritrichomonas* species infection in cats is unknown, but suspected to be significant. While resistance can be documented in the laboratory, it can be largely assumed if treatment failure is observed in a cat that receives the appropriate dosage of RDZ and has not been exposed to other cats during or after treatment. In the authors' experience, higher doses, more frequent administration or longer durations of treatment with RDZ have been ineffective in eradicating *Tritrichomonas* species from such cats and are apt to directly increase the risk of neurotoxicity.

Treatment of *Tritrichomonas* species infections in cats: approach, monitoring and assessment of efficacy



Unanswered questions pivotal to future progress

Etiology

- ❖ Are feline and bovine *T foetus* genotypes truly biologically distinct, residing in separate host reservoirs?

Transmission

- ❖ How common is *Tritrichomonas* species infection in asymptomatic cats and what risk do these cats pose for transmission of the infection to others?
- ❖ Should all cats in contact with a *Tritrichomonas* species infected cat also be treated?

Diagnosis

- ❖ What is the true sensitivity of PCR testing for diagnosis of *Tritrichomonas* species infection?
- ❖ Can alternative diagnostic approaches (eg, fecal antigen or serum antibody detection) provide more sensitive detection of infection?

Pathogenesis

- ❖ How does *Tritrichomonas* species cause diarrhea and can these mechanisms be targeted in order to ameliorate clinical signs or promote clearance of infection?

Treatment

- ❖ What is the prevalence of RDZ resistance in cats with *Tritrichomonas* species infection?
- ❖ What is the influence of diet, probiotics, the colonic microenvironment and the microbiome on clinical manifestations of *Tritrichomonas* species infection?
- ❖ Can safer and more effective drugs for treatment of the infection be identified?

Prognosis

- ❖ What is the long-term effect of *Tritrichomonas* species infection on feline gastrointestinal health?

Other avenues for treatment of feline trichomonosis

Other therapies for the treatment of *Tritrichomonas* species infection in cats are limited in their efficacy and anecdotal. Many approaches to control diarrhea have been tried without apparent success, including changes in diet, use of different antimicrobials, and supplementation with nutraceuticals and probiotics.^{12,13,69,95,96} However, there have been no well controlled studies of any of these therapies.

It has been suggested that frequent changes in diet and indiscriminate use of antimicrobials prolongs the time it takes for cats to resolve the diarrhea on their own.¹³ Veterinarians should be cautious in embracing the success of any particular antimicrobial drug for treatment of *Tritrichomonas* species infection because many drugs merely suppress detection of the organisms rather than eradicate them.

To treat or not to treat

If left untreated, it is estimated that most cats (88%) with *Tritrichomonas* species infection will undergo spontaneous resolution of their diarrhea within 2 years (median 9 months; range 5 months to 2 years).¹³ However, most of these cats will remain infected based on positive PCR test results for *Tritrichomonas* species. This suggests that cats do not develop an effective immune response to *Tritrichomonas* species infection and are incapable of eliminating the parasite. At present, no studies have been conducted to examine cats for the presence of any long-term

It is a common misconception in multi-cat settings that only cats with diarrhea are infected with *Tritrichomonas* species.



adverse health effects of asymptomatic *Tritrichomonas* species infection.

Recently, the European Advisory Board on Cat Diseases recommended that treatment of *Tritrichomonas* species infection is indicated only in cats with diarrhea that are positive for the organism on direct fecal wet mount or culture.⁹⁷ It is the authors' opinion that non-PCR approaches are too insensitive for use in routine diagnosis of the infection, even in cats with diarrhea. Moreover, the role of 'asymptomatic carriers' in disease transmission remains unclear. Asymptomatic cats can experience full relapses of diarrhea that is teeming with trichomonads as long as 6+ years after onset of their clinical 'remission'. Accordingly, any cat harboring *Tritrichomonas* species, whether asymptomatic or not, should be considered a liability for transmission of infection and detection of such cats for the sake of preventing disease transmission appears warranted.

KEY POINTS

- ❖ *Tritrichomonas foetus* is a prevalent parasite of the feline large intestine that is recognized in cats worldwide.
- ❖ The infection is chronic, can be challenging to diagnose, and is difficult to treat.
- ❖ While research has come a long way in advancing our understanding of this infection, key unanswered questions remain (see box above).
- ❖ We still know very little about how this pathogen causes diarrhea and are in urgent need of new, safe and effective therapeutics for the infection.



Acknowledgements

The authors acknowledge the indispensable contributions of the following individuals and funding agencies in support of research on feline trichomonosis: Edward Breitschwerdt, Adam Birkenheuer, Mark Papich, Katie Tolbert, Derek Foster, Dana LeVine, Marty Stebbins, Michael Yaeger, Mac Law, Stephen Stauffer, Maria Stone, Gigi Davidson, Mathew Poore, Henry Marr, Robin Gager, Judy Benrud, and the many veterinary students who coauthored much of the work presented here.

Funding

Funding for the authors' research on feline trichomonosis has been received from the Morris Animal Foundation, Winn Feline Foundation, State of North Carolina Appropriated Research Funds, Fort Dodge Animal Health, Presutti Laboratories and North Carolina State University Veterinary Medical Foundation Support for *Tritrichomonas* species Research Innovation and Veterinary Education (STRIVE) Fund.

Conflict of interest

The corresponding author (JLG) offers a for-profit molecular diagnostic service for detection of feline *Tritrichomonas* species infection by means of PCR testing.

References

- 1 Levy MG, Gookin JL, Poore M, et al. *Tritrichomonas foetus* and not *Pentatrichomonas hominis* is the etiologic agent of feline trichomonal diarrhea. *J Parasitol* 2003; 89: 99–104.
- 2 Da Cunha AM and Muniz J. **Trabalhos do instituto Oswaldo Cruz: sobre um flagelado parasito do gato.** *Braz Med* 1922; 36: 285–286.
- 3 Brumpt E. **Recherches morphologiques et experimentales sur le *Trichomonas felis* da cunha et muniz, 1922, parasite du chat et du chien.** *Ann Parasitol* 1925; 3: 239–251.
- 4 Simic T. **Etude biologique et experimentale du *Trichomonas intestinalis*, infectant spontanement l'homme, le chat et le chien.** *Ann Parasitol* 1932; 10: 209–224.
- 5 Kessel JF. **Trichomoniasis in kittens.** *Trans Royal Soc Tropic Med Hyg* 1928; 22: 61–80.
- 6 Hegner R and Eskridge L. **Absence of pathogenicity in cats infected with *Trichomonas felis* from cats and *Trichomonas hominis* from man.** *Am J Hyg* 1935; 22: 322–325.
- 7 Jordan HE. ***Trichomonas* spp in feline: a case report.** *Vet Med* 1956; 51: 23–24.
- 8 Romatowski J. **An uncommon protozoan parasite (*Pentatrichomonas hominis*) associated with colitis in three cats.** *Feline Pract* 1996; 24: 10–14.
- 9 Romatowski J. ***Pentatrichomonas hominis* infection in four kittens.** *J Am Vet Med Assoc* 2000; 216: 1270–1272.
- 10 Gookin JL, Levy MG, Law JM, et al. **Experimental infection of cats with *Tritrichomonas foetus*.** *Am J Vet Res* 2001; 62: 1690–1697.
- 11 Yaeger MJ and Gookin JL. **Histologic features associated with *Tritrichomonas foetus*-induced colitis in domestic cats.** *Vet Pathol* 2005; 42: 797–804.
- 12 Gookin JL, Breitschwerdt EB, Levy MG, et al. **Diarrhea associated with trichomonosis in cats.** *J Am Vet Med Assoc* 1999; 215: 1450–1454.
- 13 Foster DM, Gookin JL, Poore MF, et al. **Outcome of cats with diarrhea and *Tritrichomonas foetus* infection.** *J Am Vet Med Assoc* 2004; 225: 888–892.
- 14 Levy MG, Gookin JL, Poore MF, et al. **Information on parasitic gastrointestinal tract infections in cats.** *J Am Vet Med Assoc* 2001; 218: 194–195.
- 15 Gookin JL, Foster DM, Poore MF, et al. **Use of a commercially available culture system for diagnosis of *Tritrichomonas foetus* infection in cats.** *J Am Vet Med Assoc* 2003; 222: 1376–1379.
- 16 Gookin JL, Birkenheuer AJ, Breitschwerdt EB, et al. **Single-tube nested PCR for detection of *Tritrichomonas foetus* in feline feces.** *J Clin Microbiol* 2002; 40: 4126–4130.
- 17 Gookin JL, Stebbins ME, Hunt E, et al. **Prevalence of and risk factors for feline *Tritrichomonas foetus* and giardia infection.** *J Clin Microbiol* 2004; 42: 2707–2710.
- 18 Gookin JL, Copple CN, Papich MG, et al. **Efficacy of ronidazole for treatment of feline *Tritrichomonas foetus* infection.** *J Vet Intern Med* 2006; 20: 536–543.
- 19 Stockdale H, Rodning S, Givens M, et al. **Experimental infection of cattle with a feline isolate of *Tritrichomonas foetus*.** *J Parasitol* 2007; 93: 1429–1434.
- 20 Stockdale HD, Dillon AR, Newton JC, et al. **Experimental infection of cats (*Felis catus*) with *Tritrichomonas foetus* isolated from cattle.** *Vet Parasitol* 2008; 154: 156–161.
- 21 Reinmann K, Muller N, Kuhnert P, et al. ***Tritrichomonas foetus* isolates from cats and cattle show minor genetic differences in unrelated loci ITS-2 and EF-1alpha.** *Vet Parasitol* 2012; 185: 138–144.
- 22 Slapeta J, Muller N, Stack CM, et al. **Comparative analysis of *Tritrichomonas foetus* (Riedmuller, 1928) cat genotype, *T. foetus* (Riedmuller, 1928) cattle genotype and *Tritrichomonas suis* (Davaine, 1875) at 10 DNA loci.** *Int J Parasitol* 2012; 42: 1143–1149.
- 23 Sun Z, Stack C and Slapeta J. **Sequence differences in the diagnostic region of the cysteine protease 8 gene of *Tritrichomonas foetus* parasites of cats and cattle.** *Vet Parasitol* 2012; 186: 445–449.
- 24 Slapeta J, Craig S, McDonnell D, et al. ***Tritrichomonas foetus* from domestic cats and cattle are genetically distinct.** *Exp Parasitol* 2010; 126: 209–213.
- 25 Tolbert MK, Stauffer SH, Gookin JL. **Feline *Tritrichomonas foetus* adhere to intestinal epithelium by receptor-ligand-dependent mechanisms.** *Vet Parasitol* 2013; 192: 75–82.
- 26 Walden HS, Dykstra C, Dillon A, et al. **A new species of *Tritrichomonas* (Sarcocystidophora: Trichomonida) from the domestic cat (*Felis catus*).** *Parasitol Res* 2013; 112: 2227–2235.
- 27 Burgener I, Frey C, Kook P, et al. ***Tritrichomonas fetus*: a new intestinal parasite in Swiss cats [article in German].** *Schweizer Arch Tierheilkd* 2009; 151: 383–389.
- 28 Bissett SA, Gowan RA, O'Brien CR, et al. **Feline diarrhoea associated with *Tritrichomonas cf. foetus* and *Giardia* coinfection in an Australian cattery.** *Aust Vet J* 2008; 86: 440–443.
- 29 Bissett SA, Stone ML, Malik R, et al. **Observed occurrence of *Tritrichomonas foetus* and other enteric parasites in Australian cattery and shelter cats.** *J Feline Med Surg* 2009; 11: 803–807.
- 30 Gunn-Moore DA, McCann TM, Reed N, et al. **Prevalence of *Tritrichomonas foetus* infection in cats with diarrhoea in the UK.** *J Feline Med Surg* 2007; 9: 214–218.
- 31 Holliday M, Deni D and Gunn-Moore DA. *Tritrichomonas*

- foetus infection in cats with diarrhoea in a rescue colony in Italy.** *J Feline Med Surg* 2009; 11: 131–134.
- 32 Kingsbury DD, Marks SL, Cave NJ, et al. **Identification of *Tritrichomonas foetus* and *Giardia* spp. infection in pedigree show cats in New Zealand.** *N Z Vet J* 2010; 58: 6–10.
 - 33 Stockdale HD, Givens MD, Dykstra CC, et al. ***Tritrichomonas foetus* infections in surveyed pet cats.** *Vet Parasitol* 2009; 160: 13–17.
 - 34 van Doorn DC, de Bruin MJ, Jorritsma RA, et al. **Prevalence of *Tritrichomonas foetus* among Dutch cats** [article in Dutch]. *Tijdschr Diergeneeskd* 2009; 134: 698–700.
 - 35 Kuehner KA, Marks SL, Kass PH, et al. ***Tritrichomonas foetus* infection in purebred cats in Germany: prevalence of clinical signs and the role of co-infection with other enteroparasites.** *J Feline Med Surg* 2011; 13: 251–258.
 - 36 Bell ET, Gowan RA, Lingard AE, et al. **Naturally occurring *Tritrichomonas foetus* infections in Australian cats: 38 cases.** *J Feline Med Surg* 2010; 12: 889–898.
 - 37 Lim S, Park SI, Ahn KS, et al. **First report of feline intestinal trichomoniasis caused by *Tritrichomonas foetus* in Korea.** *Korean J Parasitol* 2010; 48: 247–251.
 - 38 Miro G, Hernandez L, Montoya A, et al. **First description of naturally acquired *Tritrichomonas foetus* infection in a Persian cattery in Spain.** *Parasitol Res* 2011; 109: 1151–1154.
 - 39 Tysnes K, Gjerde B, Nodtvedt A, et al. **A cross-sectional study of *Tritrichomonas foetus* infection among healthy cats at shows in Norway.** *Acta Vet Scand* 2011; 53: 39.
 - 40 Doi J, Hirota J, Morita A, et al. **Intestinal *Tritrichomonas suis* (= *T. foetus*) infection in Japanese cats.** *J Vet Med Sci* 2012; 74: 413–417.
 - 41 Hosein A, Kruth SA, Pearl DL, et al. **Isolation of *Tritrichomonas foetus* from cats sampled at a cat clinic, cat shows and a humane society in southern Ontario.** *J Feline Med Surg* 2013; 15: 706–711.
 - 42 Profizi C, Cian A, Meloni D, et al. **Prevalence of *Tritrichomonas foetus* infections in French catteries.** *Vet Parasitol* 2013; 196: 50–55.
 - 43 Raab O, Greenwood S, Vanderstichel R, et al. **A cross-sectional study of *Tritrichomonas foetus* infection in feral and shelter cats in Prince Edward Island, Canada.** *Can Vet J* 2016; 57: 265–270.
 - 44 Hinney B, Ederer C, Stengl C, et al. **Enteric protozoa of cats and their zoonotic potential – a field study from Austria.** *Parasit Res* 2015; 114: 2003–2006.
 - 45 Dabrowska J, Karamon J, Kochanowski M, et al. ***Tritrichomonas foetus* infection in cat – first detection in Poland.** *Acta Parasitol* 2015; 60: 605–608.
 - 46 Paris JK, Wills S, Balzer HJ, et al. **Enteropathogen co-infection in UK cats with diarrhoea.** *BMC Vet Res* 2014; 10: 13.
 - 47 Mancianti F, Nardoni S, Mugnaini L, et al. **A retrospective molecular study of select intestinal protozoa in healthy pet cats from Italy.** *J Feline Med Surg* 2015; 17: 163–167.
 - 48 Hale S, Norris JM and Slapeta J. **Prolonged resilience of *Tritrichomonas foetus* in cat faeces at ambient temperature.** *Vet Parasitol* 2009; 166: 60–65.
 - 49 Rosypal AC, Ripley A, Stockdale Walden HD, et al. **Survival of a feline isolate of *Tritrichomonas foetus* in water, cat urine, cat food and cat litter.** *Vet Parasitol* 2012; 185: 279–281.
 - 50 Van der Saag M, McDonnell D and Slapeta J. **Cat genotype *Tritrichomonas foetus* survives passage through the alimentary tract of two common slug species.** *Vet Parasitol* 2011; 177: 262–266.
 - 51 Gray SG, Hunter SA, Stone MR, et al. **Assessment of reproductive tract disease in cats at risk for *Tritrichomonas foetus* infection.** *Am J Vet Res* 2010; 71: 76–81.
 - 52 Dahlgren SS, Gjerde B and Pettersen HY. **First record of natural *Tritrichomonas foetus* infection of the feline uterus.** *J Small Anim Pract* 2007; 48: 654–657.
 - 53 Riedmuller L. **Ueber die morphologie, uebertragungsver-suche und klinische bedeutung der beim sporadishchen abortus des rindes vorkommenden trichomonaden.** *Zentralbl Bakteriol I Abt Orig* 1928; 108: 103–118.
 - 54 BonDurant RH and Honigberg BM. **Parasitic protozoa.** New York: Academic Press, 1994.
 - 55 Gruby D and Delafond O. **Recherches sur les animalcules se développant en grand nombre dan l'estomac dans les intestins, pendant la digestion des animaux herbivores et carnivores.** *Extrant d'une note CR Acad Sci Paris* 1843; 17: 1304–1308.
 - 56 Brion A and Cottereau P. **Presence of *Trichomonas* in the nasal cavities of swine with atrophic rhinitis** [article in French]. *C R Seances Soc Biol Fil* 1954; 148: 1415–1416.
 - 57 Spindler LA, Shorb DA and Hill CH. **The role of trichomonads in atrophic rhinitis of swine.** *J Am Vet Med Assoc* 1953; 122: 151–157.
 - 58 Backström L. **Atrophic rhinitis in swine.** *Agri-Practice* 1992; 13: 21–24.
 - 59 Runnels LJ. **Infectious atrophic rhinitis of swine.** *Vet Clin North Am Large Anim Pract* 1982; 4: 301–319.
 - 60 Tachezy J, Tachezy R, Hampl V, et al. **Cattle pathogen *Tritrichomonas foetus* (Riedmuller, 1928) and pig commensal *Tritrichomonas suis* (Gruby & Delafond, 1843) belong to the same species.** *J Eukaryot Microbiol* 2002; 49: 154–163.
 - 61 Morin-Adeline V, Mueller K, Conesa A, et al. **Comparative RNA-seq analysis of the *Tritrichomonas foetus* PIG30/1 isolate from pigs reveals close association with *Tritrichomonas foetus* BP-4 isolate 'bovine genotype'.** *Vet Parasitol* 2015; 212: 111–117.
 - 62 Cobo ER, Cano D and Campero CM. **Experimental infection with *Tritrichomonas suis* in heifers.** *Vet Parasitol* 2001; 99: 73–78.
 - 63 Kerr WR. **Experiments in cattle with *Tritrichomonas suis*.** *Vet Rec* 1958; 70: 613–615.
 - 64 Fitzgerald PR, Johnson AE, Hammond DM, et al. **Experimental infection of young pigs following intranasal inoculation with nasal, gastric, or cecal trichomonads from swine or with *Trichomonas foetus*.** *J Parasitol* 1958; 44: 597–602.
 - 65 Lun ZR, Chen XG, Zhu XQ, et al. **Are *Tritrichomonas foetus* and *Tritrichomonas suis* synonyms?** *Trends Parasitol* 2005; 21: 122–125.
 - 66 Frey CF and Muller N. ***Tritrichomonas* – systematics of an enigmatic genus.** *Mol Cell Probes* 2012; 26: 132–136.
 - 67 Mueller K, Morin-Adeline V, Gilchrist K, et al. **High prevalence of *Tritrichomonas foetus* 'bovine genotype' in faecal samples from domestic pigs at a farm where bovine trichomonosis has not been reported for over 30 years.** *Vet Parasitol* 2015; 212: 105–110.
 - 68 Morin-Adeline V, Lomas R, O'Meally D, et al. **Comparative transcriptomics reveals striking similarities between the bovine and feline isolates of *Tritrichomonas foetus*: consequences for in silico drug-target identification.** *BMC Genomics* 2014; 15: 955.
 - 69 Gookin JL, Stauffer SH, Cocco MR, et al. **Efficacy of tinida-**

- zole for treatment of cats experimentally infected with *Tritrichomonas foetus*. *Am J Vet Res* 2007; 68: 1085–1088.
- 70 Doi J, Abe N and Oku Y. Molecular survey of *Tritrichomonas suis* (= *T. foetus*) 'cat' and 'cattle' genotypes in pigs in Japan. *J Vet Med Sci* 2013; 75: 475–479.
- 71 Rhyan JC, Blanchard PC, Kvasnicka WG, et al. Tissue-invasive *Tritrichomonas foetus* in four aborted bovine fetuses. *J Vet Diagn Invest* 1995; 7: 409–412.
- 72 Xenoulis PG, Lopinski DJ, Read SA, et al. Intestinal *Tritrichomonas foetus* infection in cats: a retrospective study of 104 cases. *J Feline Med Surg* 2013; 15: 1098–1103.
- 73 Arranz-Solis D, Pedraza-Diaz S, Miro G, et al. *Tritrichomonas foetus* infection in cats with diarrhea from densely housed origins. *Vet Parasitol* 2016; 221: 118–122.
- 74 Polak KC, Levy JK, Crawford PC, et al. Infectious diseases in large-scale cat hoarding investigations. *Vet J* 2014; 201: 189–195.
- 75 Queen EV, Marks SL and Farver TB. Prevalence of selected bacterial and parasitic agents in feces from diarrheic and healthy control cats from Northern California. *J Vet Intern Med* 2012; 26: 54–60.
- 76 Tolbert MK and Gookin JL. Mechanisms of *Tritrichomonas foetus* pathogenicity in cats with insights from venereal trichomonosis. *J Vet Intern Med* 2016; 30: 516–526.
- 77 Felleisen RS. Host-parasite interaction in bovine infection with *Tritrichomonas foetus*. *Microbes Infect* 1999; 1: 807–816.
- 78 Tolbert MK, Stauffer SH, Brand MD, et al. Cysteine protease activity of feline *Tritrichomonas foetus* promotes adhesion-dependent cytotoxicity to intestinal epithelial cells. *Infect Immun* 2014; 82: 2851–2859.
- 79 Tolbert MK, Brand MD and Gould EN. In vitro effects of cysteine protease inhibitors on *Trichomonas foetus*-induced cytopathic changes in porcine intestinal epithelial cells. *Am J Vet Res* 2016; 77: 890–897.
- 80 Huang KY, Shin JW, Huang PJ, et al. Functional profiling of the *Tritrichomonas foetus* transcriptome and proteome. *Mol Biochem Parasitol* 2013; 187: 60–71.
- 81 Gookin JL, Stauffer SH and Levy MG. Identification of *Pentatrichomonas hominis* in feline fecal samples by polymerase chain reaction assay. *Vet Parasitol* 2007; 145: 11–15.
- 82 Ceplecha V, Svoboda M, Cepicka I, et al. InPouch TF-Feline medium is not specific for *Tritrichomonas foetus*. *Vet Parasitol* 2013; 196: 503–505.
- 83 Mostegl MM, Wetscher A, Richter B, et al. Detection of *Tritrichomonas foetus* and *Pentatrichomonas hominis* in intestinal tissue specimens of cats by chromogenic in situ hybridization. *Vet Parasitol* 2012; 183: 209–214.
- 84 Stauffer SH, Birkenheuer AJ, Levy MG, et al. Evaluation of four DNA extraction methods for the detection of *Tritrichomonas foetus* in feline stool specimens by polymerase chain reaction. *J Vet Diagn Invest* 2008; 20: 639–641.
- 85 Gookin JL, Stone MR, Yaeger MJ, et al. Fluorescence in situ hybridization for identification of *Tritrichomonas foetus* in formalin-fixed and paraffin-embedded histological specimens of intestinal trichomoniasis. *Vet Parasitol* 2010; 172: 139–143.
- 86 Kather EJ, Marks SL and Kass PH. Determination of the in vitro susceptibility of feline *Tritrichomonas foetus* to 5 antimicrobial agents. *J Vet Intern Med* 2007; 21: 966–970.
- 87 Lim S, Park SI, Ahn KS, et al. Efficacy of ronidazole for treatment of cats experimentally infected with a Korean isolate of *Tritrichomonas foetus*. *Korean J Parasitol* 2012; 50: 161–164.
- 88 LeVine DN, Papich MG, Gookin JL, et al. Ronidazole pharmacokinetics after intravenous and oral immediate-release capsule administration in healthy cats. *J Feline Med Surg* 2011; 13: 244–250.
- 89 Papich MG, Levine DN, Gookin JL, et al. Ronidazole pharmacokinetics in cats following delivery of a delayed-release guar gum formulation. *J Vet Pharmacol Ther* 2013; 36: 399–407.
- 90 Grellet A, Makhlof SE, Desquilbet L, et al. Efficacy of guar gum-based ronidazole capsules as a treatment for *Tritrichomonas foetus* infection in cats. *J Feline Med Surg*. Epub ahead of print 10 December 2015. DOI: 1098612X15621353.
- 91 Kavianiinia I, Plieger PG, Cave NJ, et al. Design and evaluation of a novel chitosan-based system for colon-specific drug delivery. *Int J Biol Macromol* 2016; 85: 539–546.
- 92 Rosado TW, Specht A and Marks SL. Neurotoxicosis in 4 cats receiving ronidazole. *J Vet Intern Med* 2007; 21: 328–331.
- 93 Xenoulis PG, Lopinski DJ, Read SA, et al. Intestinal *Tritrichomonas foetus* infection in cats: a retrospective study of 104 cases. *J Feline Med Surg* 2013; 15: 1098–1103.
- 94 Gookin JL, Stauffer SH, Dybas D, et al. Documentation of in vivo and in vitro aerobic resistance of feline *Tritrichomonas foetus* isolates to ronidazole. *J Vet Intern Med* 2010; 24: 1003–1007.
- 95 Gookin JL, Riviere JE, Gilger BC, et al. Acute renal failure in four cats treated with paromomycin. *J Am Vet Med Assoc* 1999; 215: 1821–1823.
- 96 Levy MG, Gookin J, Poore MF, et al. Intestinal trichomonosis in cats: pathology, diagnosis and susceptibility to antiprotozoal drugs. Proceedings of the Joint Meeting of the American Society of Parasitologists and the Society of Protozoologists; San Juan, Puerto Rico, 2000, p 108.
- 97 Gruffydd-Jones T, Addie D, Belak S, et al. *Tritrichomoniasis* in cats: ABCD guidelines on prevention and management. *J Feline Med Surg* 2013; 15: 647–649.

Available online at jfms.com

Reprints and permission: sagepub.co.uk/journalsPermissions.nav
For reuse of images only, contact the corresponding author