



OPEN ACCESS

Clinical science

Descemet's membrane endothelial keratoplasty is the predominant keratoplasty procedure in Germany since 2016: a report of the DOG-section cornea and its keratoplasty registry

Elias Flockerzi , Christina Turner, Berthold Seitz ,
GeKeR Study Group Collaborators, GeKeR Study Group

Department of Ophthalmology,
Saarland University Hospital and
Saarland University Faculty of
Medicine, Homburg, Saarland,
Germany

Correspondence to

Dr Elias Flockerzi, Department
of Ophthalmology, Saarland
University Hospital and Saarland
University Faculty of Medicine,
Homburg 66421, Saarland,
Germany; elias.flockerzi@uks.eu

Received 30 December 2022

Accepted 12 April 2023

Published Online First

16 August 2023

ABSTRACT

Background/aims This retrospective multicentric panel study provides absolute numbers, types of and indications for corneal transplantation in Germany from 2011 to 2021 and sets them into the international context.

Methods A questionnaire was sent to the 104 German ophthalmologic surgery departments and 93 (89%) provided their data.

Results The number of reported keratoplasties more than doubled from 2011 (n=4474) to 2021 (n=8998). Lamellar keratoplasties (49% posterior (n=2883), 4% anterior (n=231)) surpassed penetrating keratoplasty (PKP, 47%, n=2721) for the first time in 2014. Since 2016, Descemet's membrane endothelial keratoplasty (DMEK) has become the predominant keratoplasty procedure in Germany. Its number increased by 1.5-fold from 3850 (2016) to 5812 (2021). Main indications in 2021 were Fuchs' endothelial corneal dystrophy (FECD, 43%), pseudophakic corneal decompensation (12%), repeated keratoplasty (11%), infections (7%), keratoconus (6%) and corneal scarring (4%, others: 9%). The PKP percentage decreased from 70.2% in 2011 (n=3141) to 31.7% in 2021 (n=2853). Descemet's stripping (automated) endothelial keratoplasties (DSAEKs) decreased to 1% in 2021 (n=74). 98.6% of all posterior lamellar keratoplasties were DMEKs in Germany in 2021. The number of deep anterior lamellar keratoplasties (DALKs) remained comparable from 2011 (n=269) to 2021 (n=251, 2.8%).

Conclusion Main indications for corneal transplantation in Germany (2021) were FECD and pseudophakic corneal decompensation. DMEK is by far the predominant corneal transplantation procedure since 2016 followed by PKP, whose absolute number decreased only slightly during the decade from 2011 to 2021. DALK proportions remain low, but stable, whereas DSAEK decreased annually and plays a minor role in Germany.

Trial registration number NCT03381794.

INTRODUCTION

The beginnings of penetrating keratoplasty (PKP) date back to 1905 when Eduard Zirm performed the first successful full-thickness corneal transplantation¹ and PKP became the gold standard

WHAT IS ALREADY KNOWN ON THIS TOPIC

⇒ Lamellar keratoplasty procedures are on the rise. However, there exist different trends in the application of lamellar keratoplasty techniques worldwide.

WHAT THIS STUDY ADDS

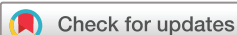⇒ This report summarises developments in Germany from 2011 to 2021 and sets them into the international context.

HOW THIS STUDY MIGHT AFFECT RESEARCH, PRACTICE OR POLICY

⇒ This report underlines the importance of Descemet's membrane endothelial keratoplasty as a relatively novel surgical technique which is likely to become more widely adopted internationally.

of corneal transplantation during the twentieth century. However, refined lamellar grafting techniques adapted to the wide range of indications for corneal transplantation that are precisely tailored to the individual corneal disease patterns have been introduced and set new standards in the last two decades.²

Deep anterior lamellar keratoplasty (DALK) consists of a corneal donor transplantation without endothelium after complete removal of the pathological stroma down to Descemet's membrane.³⁻⁴ Descemet's stripping (automated) endothelial keratoplasty (DSAEK) is a posterior lamellar corneal transplantation applied in endothelial corneal diseases, and comprises the preparation and transplantation of an endothelial donor tissue that was prepared using a microkeratome and includes a stromal layer, Descemet's membrane and the endothelium.⁵⁻⁷ Descemet's membrane endothelial keratoplasty (DMEK) is defined by the isolated preparation and transplantation of Descemet's membrane and corneal endothelium.⁸ Recent approaches that are designated as 'Descemet's stripping only' (DSO) or 'Descemetorhexis without endothelial keratoplasty' (DWEK) aim to remove only the central Descemet's membrane and endothelium without any transplantation.



© Author(s) (or their employer(s)) 2024. Re-use permitted under CC BY-NC. No commercial re-use. See rights and permissions. Published by BMJ.

To cite: Flockerzi E, Turner C, Seitz B, et al. *Br J Ophthalmol* 2024;**108**:646–653.

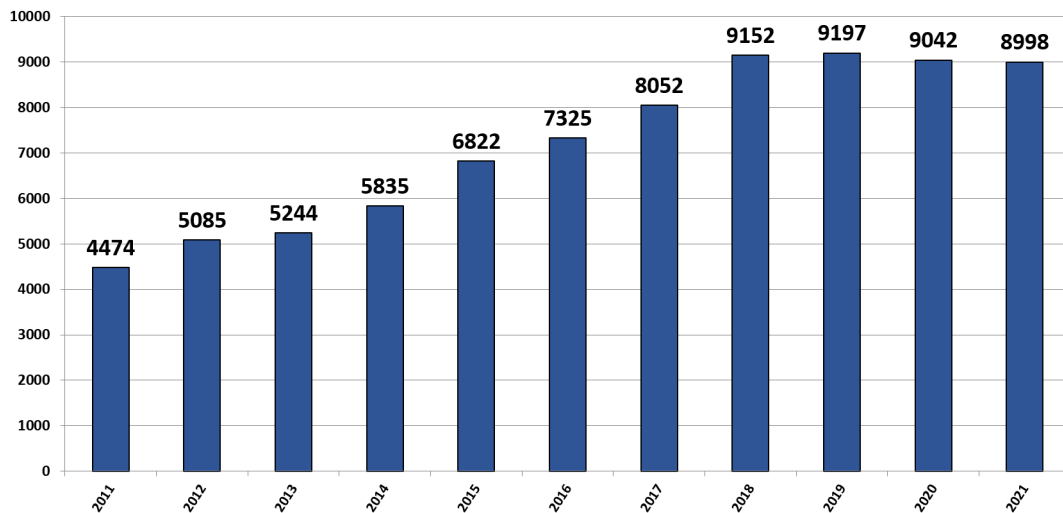


Figure 1 Absolute number of keratoplasties in Germany from 2011 to 2021. Increasing number of reported keratoplasties in Germany from 2011 (n=4474) to a maximum of n=9197 in 2019 followed by a slight decrease to n=8998 in 2021. The x-axis shows year; y-axis, number of reported corneal transplantations.

This study aimed to assess and analyse the absolute numbers, percentages, surgical techniques of and indications for corneal transplantations performed in Germany during the decade from 2011 to 2021 as raised by data from the German Keratoplasty Registry of the Cornea Section of the German Ophthalmological Society (Deutsche Ophthalmologische Gesellschaft, DOG).

METHODS

Data about keratoplasties performed in Germany have been collected by the Cornea Section of the German Ophthalmological Society (DOG, <http://www.dog.org/die-dog/sektionen-dog-kornea>) annually. A questionnaire asking for absolute numbers, surgical techniques of and indications for corneal transplantation has been sent each year to 104 ophthalmologic departments in Germany out of which 93 (89%) responded and provided their data in 2022.⁹ The 93 responses consisted of 36 (95%) of the 38 contacted chairmen of German university departments and 57 (86%) of the 66 contacted non-university-based heads of ophthalmologic departments in Germany. The study is a retrospective panel study (ideally) including all German patients treated with corneal transplantation from 2011 to 2021. It was registered at the public database ClinicalTrials.gov maintained by the U.S. National Institutes of Health and follows the principles of the declaration of Helsinki.

RESULTS

The number of reported keratoplasties increased from 4474 in 2011 to a maximum of 9197 in 2019 and slightly decreased to 8998 in 2021 (figure 1). The proportion of PKP performed annually decreased by more than half from 2011 (70.2%) to 2021 (31.7%, figure 2). Nevertheless, the absolute number of PKP decreased only slightly from 3141 (2011) to 2853 (2021) during the same period because of the overall increase of the number of corneal transplantations (figure 3).

Lamellar procedures (49% posterior (n=2883) and 4% anterior (n=231)) surpassed PKP (47%, n=2721) from 2014 on (figures 2 and 3). The proportion of DALK remained comparatively low each year, with a minimum of 212 (2016) and a maximum of 277 (2018, figure 3). Overall, there was no

major change from 2011 (n=269) to 2021 (n=251, figure 3) concerning anterior lamellar keratoplasties.

The number of DSAEK decreased from 10% in 2013 (n=507) to 1% in 2021 (n=77, figure 4). In contrast, the number of DMEK increased by 3.3-fold from 34% in 2013 (n=1773) to 65% in 2021 (n=5812, figure 4). Since 2016, DMEK has become the predominant keratoplasty procedure in Germany with 53%, 54%, 59%, 63%, 65% and 65% in 2016, 2017, 2018, 2019, 2020 and 2021, respectively (figure 4). Moreover, 98.6% of all posterior lamellar keratoplasties were performed as DMEKs in 2021 in Germany. With two exceptions, this development was reflected in the proportional distribution of the surgical procedures within the ten most active corneal transplantation centres in Germany (figure 5).

Main indications for corneal transplantation in 2021 were Fuchs' endothelial corneal dystrophy (FECD, 43%, increasing tendency since 2017), pseudophakic corneal decompensation (12%, stable), repeated keratoplasty (11%, increasing tendency

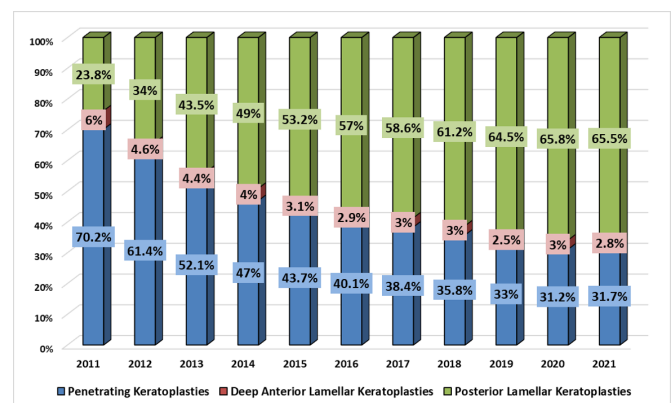


Figure 2 Proportions of penetrating, anterior and posterior lamellar keratoplasties in Germany from 2011 to 2021. Proportions of penetrating keratoplasties (blue), deep anterior lamellar keratoplasties (red) and posterior lamellar keratoplasties (green) in Germany from 2011 to 2021. The x-axis shows year; y-axis, proportions of keratoplasty techniques.

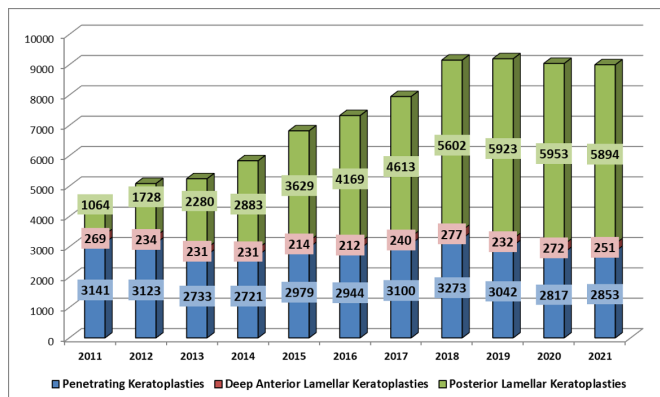


Figure 3 Absolute number of penetrating, anterior and posterior lamellar keratoplasties in Germany from 2011 to 2021. Absolute number of penetrating keratoplasties (blue), deep anterior lamellar keratoplasties (red) and posterior lamellar keratoplasties (green) in Germany from 2011 to 2021. The x-axis shows year; y-axis, absolute number of keratoplasties.

since 2017), infections (7%, increasing tendency since 2017), keratoconus (6%, stable) and corneal scarring (4%, stable, others: 9%, figure 6).

The number of patients on German waiting lists for corneal transplantation reached a maximum in 2018 (n=5313) and decreased to 4627 in 2020 (figure 7). Based on the responses to the questionnaire for 2021, the average waiting time for PKP in Germany was 9 weeks (n=57 centres reported the waiting time), for DMEK 12 weeks (n=52 reported) and for DALK 13 weeks (n=22 reported).

DISCUSSION

This retrospective panel study summarises the developments in corneal transplantation in Germany during the decade from 2011 to 2021. FECD has become the major indication and DMEK is the most commonly applied transplantation procedure followed by PKP, which decreased only slightly (in absolute

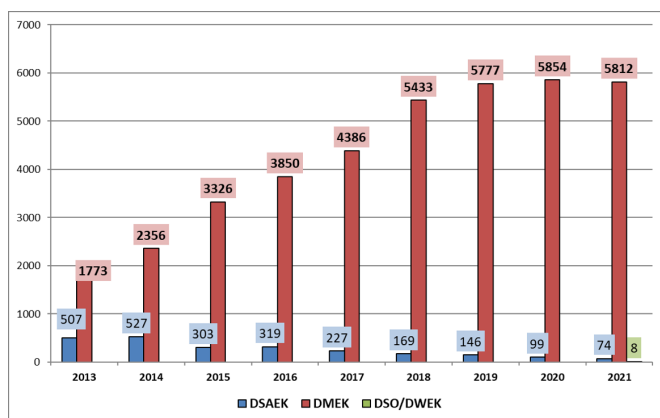


Figure 4 Absolute number of posterior lamellar keratoplasties in Germany from 2013 to 2021. Absolute number of Descemet's stripping automated endothelial keratoplasty (DSAEK, blue) vs Descemet's membrane endothelial keratoplasty (DMEK) from 2013 to 2021 in Germany. DSAEK decreasing from 507 (10%) in 2013 to 74 (1%) in 2021. DMEK increasing by 3.3-fold from 1773 (34%) in 2013 to 5812 (65%) in 2021. DSO (Descemet's stripping only) and DWEK (Descemetorhexis without endothelial keratoplasty) were reported in 2021 for the first time.

numbers) during this decade. The DALK and the posterior lamellar DSAEK procedure turned out to play minor roles in Germany.

These developments shall be put into the worldwide context in the following. For this purpose, published manuscripts and reports from cornea bank associations with data about corneal transplantation published from 2017 onwards were reviewed. A PubMed research was performed using the keywords 'corneal transplant registry' and 'eye bank report' for each country (each country was added after these keywords). It is therefore possible that existing reports not listed in PubMed or not written in English have been missed and were not included.

Europe

The European Cornea and Cell Transplantation Registry (ECCTR) collects data on corneal transplantation throughout Europe and published its first report in 2021 with 12913 registered corneal transplantations in Europe in 2019.^{10 11} This report did not include data from Germany but data from 10 other European Union Member States, the UK and Switzerland,^{10 11} with the UK (n=7491) and the Netherlands (n=3083) reporting the highest number of corneal transplantations.^{10 11} Because of the limited participation among European Union Member States, the authors assumed a total of approximately 30 000 corneal transplantations for the reported period.^{10 11} The main diagnoses that required corneal transplantation were FECD (n=5325, 41%) followed by repeated graft (n=2108, 16%), pseudophakic bullous keratopathy (n=1594, 12%) and keratoconus (n=1506, 12%).^{10 11} These results present a similar distribution of the indication spectrum as in our report for Germany. Differences arise when looking at the corneal transplantation procedures. Whereas DMEK has been the predominant corneal transplantation procedure in Germany since 2016, the ECCTR report stated that the predominant corneal transplantation procedure in its European survey was DS(A)EK (n=5918, 46%), followed by PKP (n=3886, 30%) and DMEK only in third place (n=1838, 9%).^{10 11} In view of these results, one could conclude that Germany would have a certain pioneering role in Europe with regard to the introduction and application of DMEK. However, such interpretations must consider that this ECCTR report with data from 10 out of 27 European Union Member States cannot (yet) provide a complete and representative picture of corneal transplantation trends in Europe.

The Great Britain Organ and Tissue Donation and Transplantation Activity Report 2019/2020 stated accordingly that DS(A)EK (33%) was the predominant corneal transplantation procedure followed by PKP (29%), DMEK (25%) and (D)ALK (10%).¹² The Italian Eye Bank Report 2020 reported similar results to our survey with more posterior lamellar than penetrating keratoplasties since 2016 and 1785 posterior lamellar, 1046 penetrating and 191 anterior lamellar keratoplasties in 2020 (total=3023).¹³

To satisfy the need of corneal transplantations, Europe also relies on the import of corneal grafts: The Eye Banking Statistical Report of the Eye Bank Association of America reported, for 2019, that a total of 1849 corneal grafts were exported to Europe (the majority of them to Germany, n=1290).¹⁴

North America

The Eye Banking Statistical Report of the Eye Bank Association of America reported 51 336 keratoplasties during 2019, composed of 30 650 posterior lamellar, 17 409 penetrating and 745 anterior lamellar keratoplasties.¹⁴ The proportion of posterior

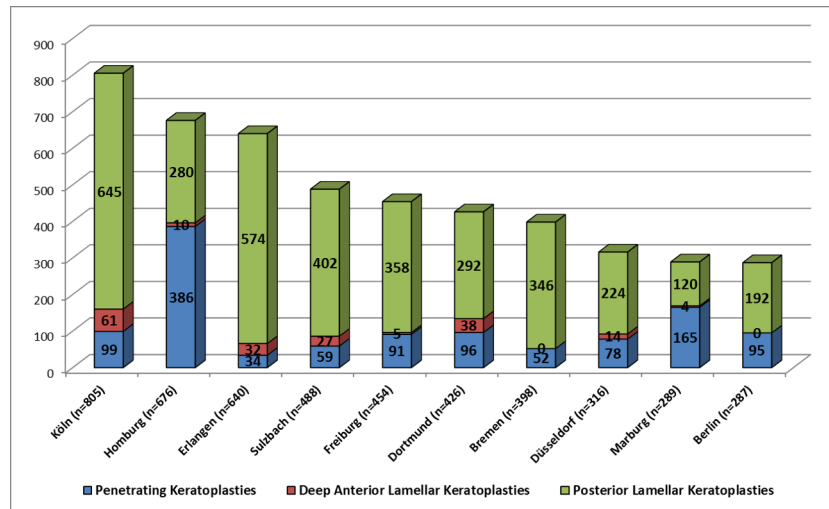


Figure 5 Ten most active corneal transplantation centres in Germany (2021). The 10 most active corneal transplantation centres in Germany (2021) show a preponderance of posterior lamellar keratoplasties (exceptions: Homburg and Marburg).

lamellar keratoplasty represented the majority (60%) and was composed of 17428 DS(A)EK and 13215 DMEK.¹⁴ For 2021, the majority of corneal transplantations were also posterior lamellar keratoplasties with the number of DMEK (n=14 128) gradually approaching, but not (yet) exceeding that of DS(A)EK (n=15 935).¹⁵ Although there were fewer corneal transplantations reported in 2021 (n=49 110) than 2019 (n=51 336) probably as a side-effect of the COVID-19 pandemic, the proportion of PKP remained almost the same (n=16 269, 33%).¹⁵ Despite a smaller total number of corneal transplantations in 2021, these numbers reveal a gradual trend towards DMEK (2019: 13 215; 2021: 14 128) and away from DSAEK (2019: 17 428; 2021: 15 935) for the USA.

As in the USA and in Germany, the Canadian Eye and Tissue Banking Statistics also reported the majority of corneal transplantations to be posterior lamellar procedures for 2020 (n=2264) followed by 845 penetrating and 106 anterior lamellar keratoplasties (total=3215).¹⁶ However, like in the USA, DSAEK dominated with 59% (n=1327) versus 41% DMEK (n=937) in view of posterior lamellar keratoplasty procedures.¹⁶

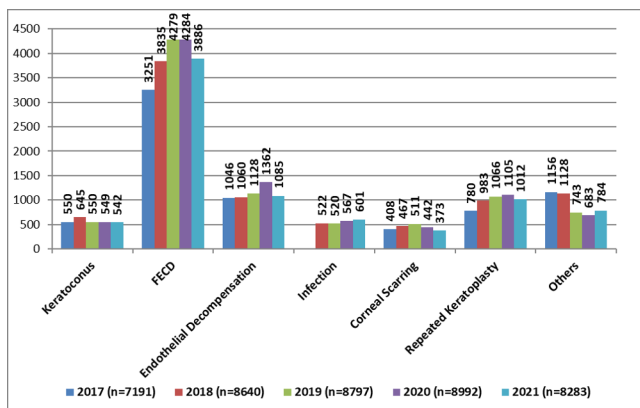


Figure 6 Main indications for keratoplasties in Germany from 2017 to 2021. Reported main indications for penetrating and lamellar corneal transplantations in Germany from 2017 to 2021. FECD, Fuchs' endothelial corneal dystrophy.

South America

The Organ Transplantation in Brazil Report indicated 14943 corneal transplantations in Brazil for 2019 without, however, providing more detailed information on the transplantation techniques.¹⁷ An earlier study from Brazil reported a 2.3-fold increase of corneal transplantations from 6193 (2001) to 14 641 (2016) and the main indications for corneal transplantation to be keratoconus, followed by infectious keratitis, post-infectious scarring and pseudophakic bullous keratopathy during this period.¹⁸ Similar results for main indications were stated in a report from Colombia covering the period from 2010 to 2017. These were corneal ectasias, followed by pseudophakic bullous keratopathy and repeated graft.¹⁹ The most common technique was PKP (90%); however, a trend towards lamellar grafts was reported.¹⁹ A report from Mexico reported 4729 corneal transplantations from March 2019 to February 2021 without providing information about indications and techniques.²⁰

Although there are fewer recent reports on corneal transplantation for the other South American countries, the export statistics of the USA can be used to draw conclusions about their transplantation activity: A total of 1499 corneal grafts were imported by South American countries, most of them to Argentina (n=377).¹⁴

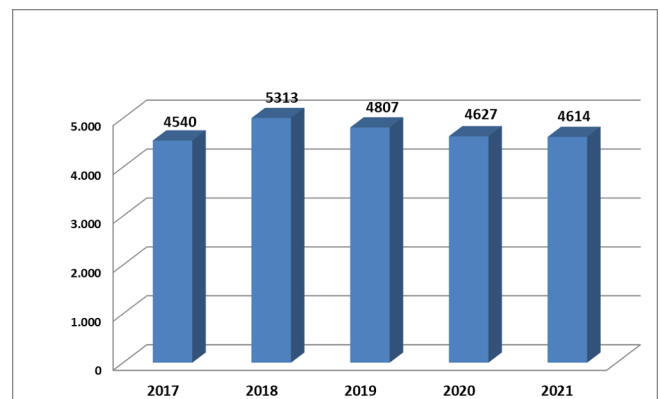


Figure 7 Waiting lists for corneal transplantation in Germany. Patients on waiting lists for corneal transplantation in Germany from 2017 to 2021, maximum of 5313 in 2018.

Asia

A similar spectrum of indications as in South America was reported in a survey from the Islamic Republic of Iran covering the period from 1991 to 2017. It reported 95 057 corneal transplants with the underlying diagnoses keratoconus (40%) followed by pseudophakic bullous keratopathy (19%), corneal scarring (16%) and graft failure (8%).²¹ The most common transplant technique was PKP (70%) which decreased slightly in favour of DSAEK (12%) until 2017, while DMEK played almost no role until 2017 (<0.1%)²¹ as opposed to the development in Germany with DMEK being the most frequently applied corneal transplantation procedure at that time (54.4%). Anterior lamellar keratoplasty accounted for 14%, which is probably attributable to the main indication of corneal ectasia.²¹ An early report of the eye banks in India from 2013 to 2014 reported the main indications for corneal transplantation to be infections (n=3023) followed by pseudophakic bullous keratopathy (n=934).²² Furthermore, the predominant transplantation technique in this report was PKP (n=7920), followed by DS(A)EK (n=1245) and DALK (n=437).²² The absence of DMEK in this survey may be due to the timing of the survey. In comparison, however, there was no major change in the distribution of transplantation techniques in a single eye bank in Hyderabad (India) in 2018: PKP continued to be the predominant technique (n=2955) followed by 1508 posterior lamellar and 164 anterior lamellar keratoplasties,²³ indicating that there had not yet been a transition towards lamellar procedures in this Indian eye bank equivalent to American or European conditions by the year 2018.

A survey from China reported an increase of corneal transplantations from 2014 (n=5377) to 2018 (n=8980) with main indications leukoma (21%), followed by bacterial keratitis (11%), dystrophies (11%), keratoconus (10%) and corneal perforation (8%).²⁴ The authors attributed the differing spectrum of indications compared with the aforementioned countries and continents to the large agricultural population and lower cataract surgery rates, resulting in a higher susceptibility to corneal scarring and infections, which in turn led to the predominant technique of PKP (54%), followed by anterior lamellar (38%) and a quite small proportion of posterior lamellar keratoplasties (7%).²⁴

The Eye Banking Statistical Report of the Eye Bank Association of America reported that 12 207 corneal grafts were exported to Asia in 2019 and that the largest importer was Japan (n=1999), followed by Pakistan (n=1800) and Saudi Arabia (n=1363).¹⁴

Australia

Like in South America and the Middle East (Iran), the main indication for corneal transplantation in New Zealand was keratoconus from 2010 to 2018 and was surpassed by repeated graft in 2019.²⁵ During this period, the main surgical procedure was PKP (n=1703), followed by DS(A)EK (n=888), (D)ALK (n=266) and DMEK (n=98).²⁵ Since nine times more DS(A)EK than DMEK have been carried out by 2020, this contrasts with the reverse development in Germany. The Australian Corneal Graft Registry 2020 reported 1831 conducted keratoplasties out of which 30% were PKP, 30% DMEK, 29% DS(A)EK, 8% DALK and 3% tectonic,²⁶ indicating that DMEK has just surpassed DS(A)EK whereas it has not exceeded PKP. Main indications were keratoconus followed by repeated graft and pseudophakic bullous keratopathy and the authors stated that the number of corneal grafts for FECD tends to increase rapidly²⁷ which might influence the ranking of the main indications in the years to come.

Africa

The basic problem in Africa is the lack of necessary infrastructure including cornea banks (apart from exceptions as, eg, the Gauteng Cornea and Eye Bank in South Africa).²⁸ For this reason, corneal transplants have to be imported, which in turn raises the threshold for the indication and performance of keratoplasty and results in a lower number of corneal transplantations overall.^{29 30} Since the corneal transplants are to be imported and not every African country published reports about corneal transplantations, conclusions about the number of corneal transplantations in Africa can be drawn from the exporters' data, for example, the Eye Banking Statistical Report of the Eye Bank Association of America. For 2019, it reported 10 711 donor corneas exported to Africa and the three most active countries in corneal transplantation were Egypt (n=5935), Djibouti (n=1409) and South Africa (n=851).¹⁴ Only a few recent reports exist from the individual African countries. One first survey reported 32 full-thickness grafts performed in Nigeria from 2008 to 2011.³¹ A second reported 118 PKP in Kenya from 2012 to 2014, which were mainly conducted because of keratoconus (66%) and corneal scarring (22%) with all donor tissues imported from the USA.²⁹ One more recent survey reported 75 corneal transplantations in Ghana from 2014 to 2018 (n=60 PKP, 14 DS(A)EK, 1 DALK) after import of all transplants and the main underlying diagnoses stated were pseudophakic bullous keratopathy and keratoconus.³⁰

Transition to DMEK in a global context

A worldwide review of PKP indications during the period of 1980 to 2014 reported FECD to be the fourth most common indication in North America and Europe.³² Much has changed since then and the proportion of posterior lamellar keratoplasties (mainly due to FECD) has already surpassed the number of PKP in many parts of the world, for example, in Germany (2021: 65%), in Europe (2019: 55%),^{10 11} in the USA (2021: 61%)¹⁵ and in Australia (2020: 59%),²⁶ which is why the twenty-first century is sometimes being referred to as the lamellar age or century²⁷ with regard to corneal transplantations techniques. While visual acuity may be affected after DSAEK by the shape and thickness of the graft or the stroma-stroma interface,³³ DMEK is reported to result in better visual acuity outcomes and an even lower hyperopic shift.^{34 35} In terms of 5-year survival rates and endothelial cell loss rates, both procedures seem to be comparable.³⁶ The American Academy of Ophthalmology confirmed a faster visual recovery and better visual outcome with DMEK when compared with DSAEK with an even lower endothelial rejection rate after DMEK than after DSAEK.³⁷ Since DMEK donor preparation and transplantation in the recipient eye may be technically more challenging, the question arises why DSAEK is constantly underrepresented in Germany. In the German-language literature, it has been suggested that DSAEK should be used especially in eyes with a shallow anterior chamber,³⁸ complex anterior segment pathologies (such as aphakia, larger iris defects, glaucoma implants, hypotonic eyes, eyes with silicone oil filling)³⁹ or in children³⁸ since the DSAEK lamella unfolds quasi-autonomously due to its inherent rigidity.⁴⁰ For the treatment of endothelial corneal diseases, DMEK has been considered the standard of care in Germany,² although the most important factor in deciding between DMEK and DSAEK remains the experience of the microsurgeon with one or the other surgical procedure.⁴¹ In view of these aspects, a further increase in the spread and number of DMEK conducted worldwide at the expense of DSAEK can be expected.

However, prevalence and genetic studies about FECD found a higher frequency of FECD in Caucasians when compared with Asians.⁴² Geographical and ethnic differences in FECD prevalence may therefore affect the relative proportions of indications for and techniques of corneal transplantations throughout the world. One recent study concluded that DMEK became the leading technique for the cure of endothelial corneal diseases in Spain.³³ Another reported 58% of keratoplasties in the Singapore National Eye Center to be endothelial keratoplasties with equal proportions of DSAEK (50%) and DMEK (50%).⁴² A survey among Canadian corneal surgeons revealed DMEK to be the preferred surgery method for endothelial corneal diseases.⁴³ When comparing DMEK and DSAEK for the treatment of FECD and pseudophakic bullous keratopathy, patients with DMEK showed a better graft survival and fewer rejections than patients treated with PKP or DSAEK receiving the same medical postoperative therapy.⁴⁴ A meta-analysis yielded better postoperative outcomes for DMEK in terms of best corrected visual acuity (BCVA), patient satisfaction and rejection rates.⁴⁵ In the direct comparison of DMEK and DSAEK, a distinction must be made in the DSAEK group between DSAEK, MT-(microthin, <130 µm graft thickness)⁴⁶ DSAEK and UT-(ultrathin <100 µm graft thickness)⁴⁰ DSAEK. The trend towards further reduced DSAEK graft thickness results from the fact that thinner grafts with the thinnest possible stromal lamella are associated with faster visual recovery.⁴⁷ Randomised controlled trials on the treatment of FECD or pseudophakic bullous keratopathy with DMEK or MT-DSAEK or UT-DSAEK concluded that DMEK leads to better visual outcomes after 3, 6 and 12 months,^{46 48–50} whereas both techniques lead to a minimal hyperopic shift and do not differ in terms of endothelial cell loss.⁵⁰ In addition, DMEK resulted in lower posterior corneal higher order aberrations compared with UT-DSAEK.⁵¹ Contrast and scatter sensitivity also recovered faster after DMEK.⁵¹ Although these studies document a superiority of DMEK, there exist also randomised controlled trials that showed comparable results between DMEK and UT-DSAEK in terms of postoperative BCVA, complication rates, endothelial loss and patient-reported quality-of-life scores.⁵² Finally, the growing number of posterior lamellar procedures is probably also attributable to the decreasing clinical threshold for surgery in corneal endothelial diseases.⁵³

The increasing use of sophisticated tomographic and biomechanical measurements^{54–56} helping to diagnose keratoconus at its very early stages and corneal crosslinking providing efficient keratoconus stabilisation⁵⁷ may contribute to decreasing numbers of keratoplasties (PKP and DALK). Although DALK aims to preserve the patient's own endothelium and is thus not threatened by endothelial rejection, it is technically challenging and may be considered still on its way to becoming the standard procedure for corneal pathologies located in the (anterior) corneal stroma.³⁸ Visual outcomes after DALK and PKP may show similar results,⁵⁸ yet there are several factors that contribute to the fact that DALK has not become widespread in Germany. First, corneal crosslinking increasingly succeeds in halting keratoconus progression, thus obviating at least in part the need for keratoplasty. Second, DALK does not always achieve the desired separation between Descemet's membrane and the corneal stroma⁵⁹ resulting in an average BCVA of 20/40^{60–62} in young patients with keratoconus or stromal corneal dystrophies. In Germany, the well-established eximer laser-assisted PKP technique may achieve a BCVA up to 20/28 on average.^{63 64} Third, a frustrated separation of Descemet's membrane and the corneal stroma may result in opacities in the interface between Descemet's membrane and the posterior corneal stroma.⁵⁹

Fourth, the rate of patients requiring intraoperative conversion from DALK to PKP (in Germany between 10%^{65 66} and 15%⁶⁷) may discourage the use of DALK as a routine technique in the patients with keratoconus.⁶⁸

Repeated keratoplasty was again the third most common indication for corneal transplantation in Germany in 2021. Unfortunately, the German Keratoplasty Registry did not collect data on the underlying diagnoses of repeated keratoplasty up to now. It is known that posterior lamellar procedures in abnormal anterior chamber anatomy subsequent to previous surgery have a higher failure rate.^{69 70} Detailed data about repeated keratoplasty in Germany are still to be collected and should be the main topic of the next German Keratoplasty Registry report. A recent German multicentre (n=7) study about 3200 DMEKs conducted to treat FECD or pseudophakic bullous keratopathy reported 3% graft failure (n=67) and a graft rejection rate of 1.5% (n=48), respectively.² Thus, (1) repeated PKP after graft failure, (2) repeated DMEK/DSAEK after graft failure, but also (3) DMEK on the PKP graft (also in case of transplanted guttae on the PKP graft⁷¹ or if a toric intraocular lens has been implanted earlier to correct corneal astigmatism) in previously well-functioning penetrating grafts are to be subsumed under the heading of repeated keratoplasty.⁷²

CONCLUSIONS

As in many other countries, the most common corneal transplantation in Germany is the posterior lamellar keratoplasty. Germany stands out in international comparison because of the high proportion of DMEK and very low proportion of DSAEK. Penetrating keratoplasty continues to be the second most frequent corneal transplantation procedure, although its number decreased proportionally from 2011 to 2021. The number of PKP is yet almost stable because of the increasing number of overall corneal transplantations. DALK seems to be underrepresented in Germany with about 3% and might further decrease due to an early and stage-appropriate therapy of keratoconus.

Collaborators German Keratoplasty Registry (GeKeR) Study Members and thereby contributing collaborators are in alphabetical order: Julita Adamiak-Kalinowska (Klinikum Frankfurt/Oder, Germany), Professor Dr Sabine Aisenbrey (Vivantes Klinikum, Neukölln, Germany), Dr Nasser Al Ashi (Oberlausitz-Kliniken gGmbH, Bautzen, Germany), Professor Dr Gerd Auffarth (Universitätsaugenklinik Heidelberg, Germany), Professor Dr Holger Baatz (Aurelios Augenzentrum Recklinghausen, Germany), Claudia Baier (HELIOS Klinikum Pforzheim, Germany), Dr Dirk Bahlmann (Universitätsaugenklinik Göttingen, Germany), Professor Dr Karl U Bartz-Schmidt (Universitätsaugenklinik Tübingen, Germany), Professor Dr Nikolaos E Bechrakis (Universitätsaugenklinik Essen, Germany), Professor Dr Marcus Blum (HELIOS Klinikum Erfurt GmbH, Germany), Professor Dr Andreas G Böhm (Elblandklinikum Radebeul, Germany), PD Dr Thorsten Böker (Klinikum Dortmund GmbH, Germany), Dr Simone Brandtner (Klinikum Bremen Mitte, Germany), Dr Christian K Brinkmann (Klinikum Dietrich Bonhoeffer Neubrandenburg GmbH, Germany), Professor Dr Reinhard Burk (Klinikum Bielefeld Rosenhöhe, Germany), Dr Erik Chankiewicz (Städtisches Klinikum Braunschweig, Germany), Professor Dr Claus Cursiefen (Universitätsaugenklinik Köln, Germany), Professor Dr Burkhard Dick (Universitätsaugenklinik Bochum, Germany), Dr Dirk Ehrlich (HELIOS Vogtland Kliniken, Germany), Professor Dr Karl-Heinz Emmerich (Klinikum Darmstadt, Germany), Professor Dr Katrin Engelmann (Klinikum Chemnitz gGmbH, Germany), Professor Dr Nicole Eter (Universitätsaugenklinik Münster, Germany), Professor Dr Carsten Framme (Medizinische Hochschule Hannover, Germany), PD Dr Ulrich Fries (Johanniter-Krankenhaus Bonn, Germany), Professor Dr Thomas A Fuchssluger (Universitätsaugenklinik Rostock, Germany), Professor Dr Matthias Fuest (Universitätsaugenklinik Aachen, Germany), Professor Dr Gerd Geerling (Universitätsaugenklinik Düsseldorf, Germany), Professor Dr Florian Gekeler (Klinikum Stuttgart-Katharinenhospital, Germany), Professor Dr Christos Haritoglou (Augenklinik Herzog Carl Theodor München, Germany), Professor Dr Lars-Olof Hattenbach (Klinikum Ludwigshafen gGmbH, Germany), Professor Dr Horst Helbig (Universitätsaugenklinik Regensburg, Germany), Professor Dr Fritz Hengerer (Bürgerhospital Frankfurt, Germany), Professor Dr Lutz Hesse (SLK-Kliniken Heilbronn GmbH, Germany), Professor Dr Konrad Hille (Ortenau Klinikum Offenbach,

Germany), Professor Dr Jost Hillenkamp (Universitätsklinikum Würzburg, Germany), PD Dr Fabian Höhn (Marienhospital Osnabrück, Germany), Professor Dr Frank G Holz (Universitätsaugenklinik Bonn, Germany), Professor Dr Antonia M Jousseaume (Charité Universitätsaugenklinik Berlin, Germany), Dr Bernd Junker (Maximilians-Augenklinik, Nürnberg, Germany), Dr Susanne Kaskel-Paul (Klinikum Lüdenscheld, Germany), Professor Dr Marcus Knorr (HELIOS Klinikum Krefeld, Germany), Professor Dr Leon Kohen (Helios Klinikum Aue, Germany), Professor Dr Markus Kohlhaas (St. Johannes-Hospital Dortmund, Germany), Professor Dr Thomas Kohnen (Universitätsaugenklinik Frankfurt, Germany), PD Dr Lothar Krause (Städtisches Klinikum Dessau, Germany), Professor Dr Friedrich E Kruse (Universitätsaugenklinik Erlangen, Germany), Dr Markus S Ladewig (Klinikum Saarbrücken gGmbH, Germany), Dr Catharina Latz (Augenklinik Dardenne Bonn, Germany), Professor Dr Wolfgang E Lieb (Vincentus-Diakonissen-Kliniken gAG Karlsruhe, Germany), Professor Dr Anja Liefeld (Klinikum Ernst von Bergmann gGmbH Potsdam, Germany), Professor Dr Matthias Maier (Klinikum rechts der Isar, Technische Universität München, Germany), Dr Joachim Magner (Park-Klinik Manhagen, Germany), Professor Dr Daniel Meller (Universitätsaugenklinik Jena, Germany), Dr Andreas Mohr (St. Joseph-Stift Bremen, Germany), Dr Markus Motschmann (AMEOS Klinikum Haldensleben, Germany), Prof Dr Arthur Mueller (Universitätsaugenklinik Augsburg, Germany), Professor Dr Thomas Neuhann (MVZ Thomas Neuhann GmbH, München, Germany), Dr Tobias Neuhann (Ophthalmologikum Neuhann MVZ GmbH, München, Germany), Dr Thomas Pahlitzsch (Augenklinik im Ring-Center GmbH, Berlin, Germany), Professor Dr Lutz E Pillunat (Universitätsaugenklinik Dresden, Germany), Dr Uwe P Press (Krankenhaus der Barmherzigen Brüder Trier, Germany), Professor Dr Siegfried G Priglinger (Universitätsaugenklinik München, Germany), Igor Prusiecki (Städtisches Klinikum Görlitz, Germany), PD Dr Mahdy Ranjbar (Universitätsaugenklinik Lübeck, Germany), Professor Dr Meus Rehak (Universitätsaugenklinik Giessen, Germany), Professor Dr Thomas Reinhard (Universitätsaugenklinik Freiburg, Germany), Professor Dr Peter Rieck (Schlosspark-Klinik Berlin, Germany), Professor Dr Johann B Roeder (Universitätsaugenklinik Kiel, Germany), Professor Dr Helmut Sachs (Carl-Thiem-Klinikum gGmbH, Cottbus, Germany), Professor Dr Gangolf Sauder (Charlottenklinik Stuttgart, Germany), Dr Hubert Scharf (Südharz-Klinikum gGmbH, Nordhausen, Germany), Professor Dr Marc Schargus (Asklepios Klinik Nord-Heidberg, Hamburg, Germany), Dr Armin Scharrer (MVZ Fürth, Germany), PD Dr Ulrich Schaudig (Asklepios Klinikum Barmbek, Hamburg, Germany), Dr Christian Scheib (Diakonissenkrankenhaus Karlsruhe, Germany), Professor Dr Andreas Scheider (Evangelisches Krankenhaus Essen-Werden, Germany), Professor Dr Josef Schmidbauer (Klinikum Nürnberg, Germany), Professor Dr Stefan Schrader (Universitätsklinikum Oldenburg, Germany), Professor Dr Norbert Schrage (Kliniken der Stadt Köln gGmbH, Germany), Dr Jens Schrecker (Rudolf Virchow Klinikum Glauchau gGmbH, Germany), Dr Frank Schröder (Universitätsaugenklinik Marburg, Germany), Dr Jörg Seewald (SRH Waldklinikum GmbH, Gera, Germany), Professor Dr Martin Spitzer (Universitätsaugenklinik Hamburg, Germany), Professor Dr Andreas Stahl (Universitätsaugenklinik Greifswald, Germany), Dr Annette Sturm (Städtisches Klinikum Brandenburg GmbH, Germany), Professor Dr Peter Szurman (Knappschaftsklinikum Saar GmbH Sulzbach, Germany), Professor Dr Hagen Thieme (Universitätsaugenklinik Magdeburg, Germany), Professor Dr Felix Treumer (Klinikum Kassel, Germany), Professor Dr Arne Viestenz (Universitätsaugenklinik Halle, Germany), Dr Burkhard von Jagow (Klinikum Barnim GmbH Eberswalde, Germany), Professor Dr Joachim Wachtlin (St. Gertrauden Krankenhaus, Berlin, Germany), PD Dr Joanna Wasielica-Posednik (Universitätsaugenklinik Mainz, Germany), PD Dr Christopher Wirbelauer (Augenklinik Berlin-Marzahn GmbH, Germany), Professor Dr Armin Wolf (Universitätsaugenklinik Ulm, Germany) and Professor Dr Focke Ziemssen (Universitätsaugenklinik Leipzig, Germany).

Contributors EF is guarantor.

Funding The authors have not declared a specific grant for this research from any funding agency in the public, commercial or not-for-profit sectors.

Competing interests None declared.

Patient consent for publication Not applicable.

Ethics approval The local ethics committee of Saarland (Ethikkommission bei der Ärztekammer des Saarlandes) was informed and decided to exempt this study because it does not contain individual-related data.

Provenance and peer review Not commissioned; externally peer reviewed.

Data availability statement All data relevant to the study are included in the article or uploaded as online supplemental information. Not applicable.

Open access This is an open access article distributed in accordance with the Creative Commons Attribution Non Commercial (CC BY-NC 4.0) license, which permits others to distribute, remix, adapt, build upon this work non-commercially, and license their derivative works on different terms, provided the original work is properly cited, appropriate credit is given, any changes made indicated, and the use is non-commercial. See: <http://creativecommons.org/licenses/by-nc/4.0/>.

ORCID iDs

Elias Flockerzi <http://orcid.org/0000-0002-0423-3624>

Berthold Seitz <http://orcid.org/0000-0001-9701-8204>

REFERENCES

- Zirm EK. Eine erfolgreiche totale keratoplastik (a successful total keratoplasty). *Albrecht von Graefes Archiv Für Ophthalmologie* 1906;64:580–93.
- Spaniol K, Hellmich M, Borgardt K, et al. DMEK outcome after one year-results from a large multicenter study in Germany. *Acta Ophthalmol* 2023;101:e215–25.
- Sugita J, Kondo J. Deep lamellar keratoplasty with complete removal of pathological stroma for vision improvement. *Br J Ophthalmol* 1997;81:184–8.
- Anwar M, Teichmann KD. Big-bubble technique to bare Descemet's membrane in anterior lamellar keratoplasty. *J Cataract Refract Surg* 2002;28:398–403.
- Melles GRJ, Wijdh RHJ, Nieuwendaal CP. A technique to excise the Descemet membrane from a recipient cornea (descemetorhexis). *Cornea* 2004;23:286–8.
- Price FW, Price MO. Descemet's stripping with endothelial keratoplasty in 50 eyes: a refractive neutral corneal transplant. *J Refract Surg* 2005;21:339–45.
- Gorovoy MS. Descemet-stripping automated endothelial Keratoplasty. *Cornea* 2006;25:886–9.
- Melles GRJ. Posterior lamellar keratoplasty: DLEK to DSEK to DMEK. *Cornea* 2006;25:879–81.
- Flockerzi E, Maier P, Böhringer D, et al. Trends in corneal transplantation from 2001 to 2016 in Germany: a report of the dog-section cornea and its keratoplasty registry. *Am J Ophthalmol* 2018;188:91–8.
- The European Cornea and Cell Transplantation Registry. Summary final report of the ECCTR project. Available: <https://ec.europa.eu/research/participants/documents/downloadPublic?documentId=080166e5c9cd246&appId=PPGMS> [Accessed 1 Jun 2022].
- Dunker SL, Armitage WJ, Armitage M, et al. Practice patterns of corneal transplantation in Europe: first report by the European cornea and cell transplantation registry. *J Cataract Refract Surg* 2021;47:865–9.
- National Health Service of the United Kingdom Health Departments. Organ and tissue donation and transplantation activity report; Available: <https://nhsbtbde.blob.core.windows.net/umbraco-assets-corp/24053/activity-report-2020-2021.pdf> [Accessed 1 Jun 2022].
- Fondazione banca degli occhi del veneto onlus; Available: https://www.fbov.org/images/Report/Report2020/fbov_web_.pdf
- Eye Bank Association of America. Eye banking statistical report. 2019. Available: <https://restoresight.org/wp-content/uploads/2020/04/2019-EBAA-Stat-Report-FINAL.pdf>
- Eye Bank Association of America. Eye banking statistical report. 2021. Available: <https://restoresight.org/statistical-report/>
- Canadian Blood Services. Canadian Eye and Tissue Data Committee Report; 2020. Available: https://profedu.blood.ca/sites/default/files/2021-12/2020%20ETDC%20Report_EN%20FINAL.pdf
- Brazilian Transplantation Registry. Organ transplantation in Brazil 2012–2019. n.d. Available: <https://site.abto.org.br/wp-content/uploads/2020/09/rbt-ingles-2019-leitura.pdf>
- Almeida HG, Hida RY, Kara-Junior N. Trends in corneal transplantation from 2001 to 2016 in Brazil. *Arq Bras Oftalmol* 2018;81:529–38.
- Mora M, Cortés M, Plata M, et al. Corneal transplant epidemiology in a reference center in Bogotá, Colombia (2010–2017). *Pan Am J Ophthalmol* 2021;3:39.
- Servin-Rojas M, Olivas-Martinez A, Ramirez Del Val F, et al. Transplant trends in Mexico during the COVID-19 pandemic: disparities within healthcare sectors. *Am J Transplant* 2021;21:4052–60.
- Ali Javadi M, Kanavi MR, Safi S. A 27-year report from the Central Eye Bank of Iran. *J Ophthalmic Vis Res* 2020;15:149–59.
- Sharma N, Arora T, Singhal D, et al. Procurement, storage and utilization trends of eye banks in India. *Indian J Ophthalmol* 2019;67:1056–9.
- Chaurasia S, Mohamed A, Garg P, et al. Thirty years of eye bank experience at a single centre in India. *Int Ophthalmol* 2020;40:81–8.
- Gao H, Huang T, Pan Z, et al. Survey report on keratoplasty in China: a 5-year review from 2014 to 2018. *Plos one* 2020;15:e0239939.
- Zhang J, Patel DV, McGhee CNJ. The rapid transformation of transplantation for corneal endothelial diseases: an evolution from penetrating to lamellar to cellular transplants. *Asia Pac J Ophthalmol* 2019;8:441–7.
- The Australian Corneal Graft Registry 2020 annual report; Available: <https://www.flinders.edu.au/content/dam/documents/research/fmri-eye-and-vision/australian-corneal-graft-registry-2020-annual-report.pdf>
- Williams KA, Keane MC. Outcomes of corneal transplantation in Australia, in an era of lamellar keratoplasty. *Clin Exp Ophthalmol* 2022;50:374–85.
- Makgotloe AM, Carmichael TR. Plummeting corneal donations at the Gauteng Cornea and Eye Bank. *South African medical Journal = Suid-Afrikaanse Tydskrif VIR Geneeskunde* 2009;99:797.
- Chen MC, Kunselman AR, Stetter CM, et al. Corneal transplantation at Tenwek hospital, Kenya, East Africa: analysis of outcomes and associated patient socioeconomic characteristics. *Plos one* 2017;12:e0187026.
- Lartey S, Antwi-Adjei EK, Mohammed AK, et al. Indications and outcomes of corneal transplant surgery in Ghana. *Ann Afr Surg* 2021;18:137–42.

- 31 Ulasi II, Ijoma CK. Organ transplantation in Nigeria. *Transplantation* 2016;100:695–7.
- 32 Matthaei M, Sandhaeger H, Hermel M, *et al.* Changing indications in penetrating keratoplasty: a systematic review of 34 years of global reporting. *Transplantation* 2017;101:1387–99.
- 33 Palma-Carvajal F, Morales P, Salazar-Villegas A, *et al.* Trends in corneal transplantation in a single center in Barcelona, Spain. Transitioning to DMEK. *J Fr Ophthalmol* 2020;43:1–6.
- 34 Ham L, Dapena I, Moutsouris K, *et al.* Refractive change and stability after Descemet membrane endothelial keratoplasty. Effect of corneal dehydration-induced hyperopic shift on intraocular lens power calculation. *J Cataract Refract Surg* 2011;37:1455–64.
- 35 van Dijk K, Ham L, Tse WHW, *et al.* Near complete visual recovery and refractive stability in modern corneal transplantation: Descemet membrane endothelial keratoplasty (DMEK). *Cont Lens Anterior Eye* 2013;36:13–21.
- 36 Price DA, Kelley M, Price FW, *et al.* Five-year graft survival of Descemet membrane endothelial keratoplasty (EK) versus Descemet stripping EK and the effect of donor sex matching. *Ophthalmology* 2018;125:1508–14.
- 37 Deng SX, Lee WB, Hammersmith KM, *et al.* Descemet membrane endothelial keratoplasty: safety and outcomes: a report by the American Academy of Ophthalmology. *Ophthalmology* 2018;125:295–310.
- 38 Cursiefen C, Schaub F, Bachmann BO. Update minimally invasive lamellar keratoplasty: DMEK, DSAEK and DALK. *Klin Monbl Augenheilkd* 2016;233:1033–42.
- 39 Cursiefen C, Steven P, Roters S, *et al.* „Descemet membrane endothelial keratoplasty“ (DMEK) und „Descemet stripping automated endothelial keratoplasty“ (DSAEK). *Ophthalmologie* 2013;110:614–21.
- 40 Bachmann B, Schaub F, Cursiefen C. Treatment of corneal endothelial disorders by DMEK and UT-DSAEK. indications, complications, results and follow-up. *Ophthalmologie* 2016;113:196–203.
- 41 Bachmann B, Schrittenlocher S, Matthaei M, *et al.* „Descemet membrane endothelial keratoplasty“ in komplexen augen. *Ophthalmologie* 2019;116:228–35.
- 42 Soh YQ, Kocaba V, Pinto M, *et al.* Fuchs endothelial corneal dystrophy and corneal endothelial diseases: East meets West. *Eye (Lond)* 2020;34:427–41.
- 43 Kisilevsky E, Sriksunaran D, Chew HF. Surgeon preferences for endothelial keratoplasty in Canada. *Cornea* 2021;40:1420–5.
- 44 Woo JH, Ang M, Htoon HM, *et al.* Descemet membrane endothelial keratoplasty versus Descemet stripping automated endothelial keratoplasty and penetrating keratoplasty. *Am J Ophthalmol* 2019;207:288–303.
- 45 Marques RE, Guerra PS, Sousa DC, *et al.* DMEK versus DSAEK for Fuchs' endothelial dystrophy: a meta-analysis. *Eur J Ophthalmol* 2019;29:15–22.
- 46 Matsou A, Pujari R, Sarwar H, *et al.* Microthin Descemet stripping automated endothelial keratoplasty versus Descemet membrane endothelial keratoplasty: a randomized clinical trial. *Cornea* 2021;40:1117–25.
- 47 Dapena I, Ham L, Melles GRJ. Endothelial keratoplasty: DSEK/DSAEK or DMEK – the thinner the better? *Curr Opin Ophthalmol* 2009;20:299–307.
- 48 Chamberlain W, Lin CC, Austin A, *et al.* Descemet endothelial thickness comparison trial: a randomized trial comparing ultrathin Descemet stripping automated endothelial keratoplasty with Descemet membrane endothelial keratoplasty. *Ophthalmology* 2019;126:19–26.
- 49 Hirabayashi KE, Chamberlain W, Rose-Nussbaumer J, *et al.* Corneal light scatter after ultrathin Descemet stripping automated endothelial keratoplasty versus Descemet membrane endothelial keratoplasty in Descemet endothelial thickness comparison trial: a randomized controlled trial. *Cornea* 2020;39:691–6.
- 50 Dunker SL, Dickman MM, Wisse RPL, *et al.* Descemet membrane endothelial keratoplasty versus ultrathin Descemet stripping automated endothelial keratoplasty: a multicenter randomized controlled clinical trial. *Ophthalmology* 2020;127:1152–9.
- 51 Dunker SL, Dickman MM, Wisse RPL, *et al.* Quality of vision and vision-related quality of life after Descemet membrane endothelial keratoplasty: a randomized clinical trial. *Acta Ophthalmol* 2021;99:e1127–34.
- 52 Pujari R, Matsou A, Kean J, *et al.* A randomized controlled trial comparing microthin Descemet stripping automated endothelial keratoplasty with Descemet membrane endothelial keratoplasty: two-year report. *Cornea* 2022;41:1519–24.
- 53 Chilibeck CM, Brookes NH, Gokul A, *et al.* Changing trends in corneal transplantation in Aotearoa/New Zealand, 1991 to 2020: effects of population growth, cataract surgery, endothelial keratoplasty, and corneal cross-linking for keratoconus. *Cornea* 2022;41:680–7.
- 54 Belin MW, Duncan JK. Keratoconus: the ABCD grading system. *Klin Monbl Augenheilkd* 2016;233:701–7.
- 55 Vinciguerra R, Ambrósio R, Elsheitk A, *et al.* Detection of keratoconus with a new biomechanical index. *J Refract Surg* 2016;32:803–10.
- 56 Flockezi E, Vinciguerra R, Belin MW, *et al.* Combined biomechanical and tomographic keratoconus staging: adding a biomechanical parameter to the ABCD keratoconus staging system. *Acta Ophthalmol* 2022;100:e1135–42.
- 57 Xanthopoulou K, Milioti G, Daas L, *et al.* Accelerated corneal crosslinking causes pseudoprogression in keratoconus within the first 6 weeks without affecting posterior corneal curvature. *Eur J Ophthalmol* 2022;32:2565–76.
- 58 Reinhart WJ, Musch DC, Jacobs DS, *et al.* Deep anterior lamellar keratoplasty as an alternative to penetrating keratoplasty. *Ophthalmology* 2011;118:209–18.
- 59 Cursiefen C, Siebelmann S, Bachmann B. Complications of deep anterior lamellar keratoplasty. Avoid, recognize and treat. *Der Ophthalmologe* 2015;112:961–8.
- 60 Bahar I, Kaiserman I, Srinivasan S, *et al.* Comparison of three different techniques of corneal transplantation for keratoconus. *Am J Ophthalmol* 2008;146:905–12.
- 61 Kubaloglu A, Sari ES, Koytak A. Deep anterior lamellar keratoplasty in eyes previously treated with collagen crosslinking for keratoconus: 3-year results. *Graefes Arch Clin Exp Ophthalmol* 2020;258:821–7.
- 62 Feizi S, Javadi MA, Karimian F, *et al.* Penetrating keratoplasty versus deep anterior lamellar keratoplasty for advanced stage of keratoconus. *Am J Ophthalmol* 2023;248:107–15.
- 63 Seitz B, Langenbacher A, Kus MM, *et al.* Nonmechanical corneal trephination with the excimer laser improves outcome after penetrating keratoplasty. *Ophthalmology* 1999;106:1156–64.
- 64 Seitz B, Hager T, Langenbacher A, *et al.* Reconsidering sequential double running suture removal after penetrating keratoplasty: a prospective randomized study comparing excimer laser and motor trephination. *Cornea* 2018;37:301–6.
- 65 Heindl LM, Riss S, Bachmann BO, *et al.* Split cornea transplantation for 2 recipients: a new strategy to reduce corneal tissue cost and shortage. *Ophthalmology* 2011;118:294–301.
- 66 Cursiefen C, Heindl LM. Perspectives of deep anterior lamellar keratoplasty. *Ophthalmologie* 2011;108:833–9.
- 67 Riss S, Heindl LM, Bachmann BO, *et al.* Pentacam-based big bubble deep anterior lamellar keratoplasty in patients with keratoconus. *Cornea* 2012;31:627–32.
- 68 Cursiefen C, Schaub F, Bachmann B. Update: deep anterior lamellar keratoplasty (DALK) for keratoconus. When, how and why. *Ophthalmologie* 2016;113:204–12.
- 69 Cohen E, Mimouni M, Sorkin N, *et al.* Risk factors for repeat Descemet membrane endothelial keratoplasty graft failure. *Am J Ophthalmol* 2021;226:165–71.
- 70 Kiel M, Bu JB, Gericke A, *et al.* Comparison of DMEK and DSAEK in eyes with endothelial decompensation after previous penetrating keratoplasty. *Cornea* 2021;40:1218–24.
- 71 Schönit S, Maamri A, Zemova E, *et al.* Prevalence and impact of cornea guttata in the graft after penetrating keratoplasty in Germany. *Cornea* 2022;41:1495–502.
- 72 Seitz B, Daas L, Wykrota AA, *et al.* Graft failure after PKP and DMEK: what is the best option? *Klin Monbl Augenheilkd* 2022;239:775–85.