

Research Article

Metallothionein expression in the central nervous system of multiple sclerosis patients

M. Penkowa^a, C. Espejo^{b,*}, A. Ortega-Aznar^c, J. Hidalgo^d, X. Montalban^b and E. M. Martínez Cáceres^{b,e}

^a The Panum Institute, Department of Medical Anatomy, University of Copenhagen, Copenhagen (Denmark)

^b Unitat de Neuroimmunologia Clínica, Hospital Universitari Vall d'Hebron, Ps. Vall d'Hebron 119-129 (2^a pl EUI), 08035 Barcelona (Spain), Fax + 34 93 2746084, e-mail: cespejo@hg.vhebron.es

^c Neuropathology Unit, Department of Pathology, Vall d'Hebron University Hospital, Barcelona (Spain)

^d Institute of Neurosciences and Department of Cellular Biology, Physiology and Immunology, Autonomous University of Barcelona, Barcelona (Spain)

^e Laboratory of Immunobiology for Research and Diagnostic Applications (LIRAD), Transfusion Center and Tissue Bank (CTBT), Germans Trias i Pujol University Hospital, Badalona, Barcelona (Spain)

Received 16 January 2003; received after revision 24 February 2003; accepted 4 April 2003

Abstract. Multiple sclerosis (MS) is a major chronic demyelinating and inflammatory disease of the central nervous system (CNS) in which oxidative stress likely plays a pathogenic role in the development of myelin and neuronal damage. Metallothioneins (MTs) are antioxidant proteins induced in the CNS by tissue injury, stress and some neurodegenerative diseases, which have been postulated to play a neuroprotective role. In fact, MT-I+II-deficient mice are more susceptible to developing experi-

mental autoimmune encephalomyelitis (EAE), and treatment of Lewis rats with Zn-MT-II reduces EAE severity. We show here that, as in EAE, MT-I+II proteins were expressed in brain lesions of MS patients. Cells expressing MT-I+II were mainly astrocytes and activated monocytes/macrophages. Interestingly, the levels of MT-I+II were slightly increased in the inactive MS lesions in comparison with the active lesions, suggesting that MTs may be important in disease remission.

Key words. Metallothionein; multiple sclerosis; neuronal damage; oxidative stress; antioxidant.

Multiple sclerosis (MS) is a chronic demyelinating inflammatory autoimmune disease of the central nervous system (CNS) with a multifactorial pathogenesis, polygenic and environmental factors acting concertedly. The mechanisms involved in disease development have been extensively studied and most of the available data support a model of lesion development mediated by Th1 CD4+ lymphocytes secreting proinflammatory cytokines such as interferon-gamma (IFN- γ) and tumor necrosis factor-alpha (TNF- α). In light of these findings, increasing evidence points to a direct role for oxidative stress in myelin

and neuronal damage. Activation of the inducible nitric oxide synthase (iNOS) and nitric oxide (NO) production in the CNS has been demonstrated during experimental autoimmune encephalomyelitis (EAE) [1–5] and MS [6, 7] and NO, both through direct interaction with CNS components and through its byproducts such as peroxynitrite has been suggested to cause a variety of toxic effects inducing strong axonal damage and demyelination [8–10]. The role of antioxidants in both EAE and MS is less known. Uric acid, a strong peroxynitrite scavenger, has been shown to have a protective role during EAE, and hyperuricemia has been postulated to have protective properties against MS [11–14].

* Corresponding author.

Metallothioneins (MTs) are a family of low-molecular-weight, heavy-metal-binding, cysteine-rich proteins that accumulate under conditions where oxidative stress has taken place. Four isoforms of MTs have been identified in the mouse (MT-I–IV) and MT-I plus MT-II have been related to antioxidant functions. Recently, our group showed that MT-I+II are induced in the brain of mice with EAE [15] and that MT-I+II knockout mice are more susceptible to and suffer from more severe EAE than wild-type controls [16]. Furthermore, Zn-MT-II treatment has been shown to reduce both the severity of and mortality from EAE in a time- and dose-dependent manner [17, 18]. All these data support a protective role for MT-I+II in EAE.

MT-I+II protein expression has been studied during neurodegenerative diseases such as Alzheimer's disease [19, 20], Pick's disease [21], amyotrophic lateral sclerosis [22] or following brain ischemia [23], in all of which oxidative stress has been implicated as a significant factor contributing to tissue injury. In contrast, MT-I+II expression has not been specifically analyzed in MS. Only a very recent report performing microarray analysis of MS brains showed a significant induction of MT-I+II gene expression in all samples analyzed [24].

Using immunohistochemistry, in this report we analyzed MT-I+II expression in active and inactive lesions of brains from three deceased MS patients and two controls. We found that in all MS cellular infiltrates, MT-I+II immunoreactivity increased significantly. The pattern of MT expression was similar to that found in the EAE model. Interestingly, the levels of MT-I+II were slightly increased in the inactive MS lesions in comparison with the active lesions, suggesting that they could be related to disease remission. The present results support the hypothesis that MT-I+II are involved in MS pathogenesis as factors attempting to cope with tissue injury and point to treatment with MT-I+II as a potentially useful therapy for MS.

Materials and methods

Paraffin-embedded human brain tissue sections were obtained at autopsy from three patients who had suffered from MS [*patient 1*: woman, 62 years old, relapsing-remitting (RR) course, cause of death – pulmonary embolism, brain removed 17 h after death; *patient 2*: man, 45 years old, RR course, cause of death – myocard infarct, brain removed 10 h after death; *patient 3*: woman, 50 years old, progressive course, cause of death – bacterial bronchopneumonia, brain removed 20 h after death] and two control patients without CNS pathology at the time of death (*control patient 1*: man, 50 years old, cause of death – acute myocardial infarct, brain removed 12 h after death; *control patient 2*: woman, 60 years old, cause of

death – respiratory failure due to pneumonia, brain removed 10 h after death), all from the Pathology Department, Hospital Vall d'Hebron, Barcelona. Prior to being paraffin-embedded, all brains were fixed by suspension from the basilar artery in 10% formaldehyde buffered to pH 7 and stabilized with methanol for 2 weeks. We analyzed 15 chronic active and 15 chronic inactive brain MS lesion sections, and 15 control sections. Active MS lesions were defined as areas infiltrated with numerous round macrophages and T lymphocytes while inactive MS lesions were brain areas with decreased macrophage and T cell infiltration but increased astrogliosis. Procedures were approved by the Ethics Committee and IRB of Hospital Vall d'Hebron.

The brain tissues were cut into serial, 4- μ m-thick sections for histochemistry and immunohistochemistry. Depending on the antibody to be used (see below), sections were subjected to specific antigen retrieval methods. For heat-induced antigen retrieval, some sections were boiled in citrate buffer, pH 9.1 or pH 6.0 in a microwave oven for 10 min. In some sections, epitope retrieval was obtained by preincubating the sections with Protease type XIV (0.025 g dissolved in 50 ml TBS) (Sigma-Aldrich) for 10 min, pH 7.4, at 37°C. Some stainings did not require specific epitope retrieval. All the sections were then incubated in 1.5% H₂O₂ in Tris-buffered saline (TBS)/Nonidet (TBS: 0.05 M Tris, pH 7.4, 0.15 M NaCl; with 0.01% Nonidet P-40) (Sigma-Aldrich) for 15 min at room temperature to quench endogenous peroxidase. Sections were incubated with 10% normal goat serum (In Vitro) or 10% normal donkey serum (The Binding Site) in TBS/Nonidet for 30 min at room temperature in order to block non-specific binding.

Histochemistry

Staining for tomato lectin from *Lycopersicon esculentum* and H&E were performed as previously described [17, 25].

Immunohistochemistry

The sections were incubated overnight at 4°C with mouse anti-human CD3 1:50 (Santa Cruz Biotech.) (microwave oven, citrate buffer, pH 9); mouse anti-human CD4 1:10 (Serotec) (microwave oven, citrate buffer, pH 9); mouse anti-human CD14 1:50 (Santa Cruz Biotech.) (microwave oven, citrate buffer, pH 6); goat anti-human glial fibrillary acidic protein (GFAP) 1:100 (Santa Cruz Biotech.); rabbit anti-human interleukin-6 (IL-6) 1:50 (Santa Cruz Biotech.); rabbit anti-human TNF- α 1:50 (Santa Cruz Biotech.) (microwave oven, citrate buffer pH 9); rabbit anti-rat MT-I+II 1:500 [25–28]; rabbit anti-nitrotyrosine (NITT) 1:100 (Alpha Diagnostic Int.) (a marker for peroxynitrite-induced nitration of tyrosine residues, which monitors oxidative stress) (microwave oven, citrate buffer, pH 6); rabbit anti-malondialdehyde

(MDA) 1:100 (Alpha Diagnostic Int.) (a marker for MDA produced as a byproduct of fatty acid peroxidation, thereby monitoring oxidative stress); mouse anti-non-phosphorylated neurofilaments (SMI-32) 1:50 (Sternberger Monoclonals Inc.) (detecting axonal transection and demyelination).

The primary antibody was detected using biotinylated goat anti-mouse IgG 1:200 (Sigma-Aldrich), biotinylated mouse anti-rabbit IgG 1:400 (Sigma-Aldrich), or biotinylated donkey anti-sheep IgG 1:20 (Amersham) for 30 min at room temperature followed by streptavidin-biotin-peroxidase complex (StreptABCComplex/HRP; Dakopatts) prepared at the manufacturer's recommended dilutions for 30 min at room temperature. Afterwards, sections were incubated with biotinylated tyramide and streptavidin-peroxidase complex (NEN, Life Science Products) prepared following the manufacturer's recommendations. The immunoreaction was visualized using DAB as a chromogen (see above).

To evaluate the extent of non-specific binding in the immunohistochemical experiments, control sections were incubated in the absence of primary antibody. Results were considered only if these controls were negative.

In situ detection of DNA fragmentation

Terminal deoxynucleotidyl transferase (TdT)-mediated deoxyuridine triphosphate (dUTP)-digoxigenin nick end labeling (TUNEL) staining was performed as previously described [16, 18, 25].

Fluorescence histochemistry

To determine which cells suffered apoptosis during MS, sections were incubated with fluorescein (FITC)-linked TUNEL (Oncor) according to the manufacturer's protocol, and afterwards incubated overnight at 4 °C with rabbit anti-human neuron-specific enolase (NSE) 1:1000 (Calbiochem) (marking neurons) and goat anti-human vimentin 1:50 (Santa Cruz Biotech.). The anti-NSE antibodies were detected using donkey anti-rabbit IgG linked with TexasRed (TXRD) 1:50 (Jackson ImmunoResearch), while the anti-vimentin antibodies were detected using donkey anti-goat IgG linked with aminomethylcoumarin (AMCA) 1:50 (Jackson ImmunoResearch).

Sections were also incubated with FITC-linked TUNEL (see above) and afterwards incubated overnight at 4 °C with mouse anti-human CD4 or mouse anti-human 2'3'cyclic nucleotide 3'phosphohydrolase (CNPase) 1:150 (Biogenesis). These monoclonal antibodies were detected using TXRD-linked goat anti-mouse IgG 1:50 (Southern Biotechnology).

To examine which cells showed oxidative stress, sections were incubated overnight at 4 °C with rabbit anti-NITT and one of the following antibodies: mouse anti-human neurofilaments (NF) (marking neurons) (ready-to-use) (Biogenex), or mouse anti-human CNPase 1:150, mouse

anti-human CD14 1:30 (Zymed), mouse anti-human GFAP 1:150 (Santa Cruz Biotech.) or mouse anti-human CD4. The anti-NITT antibodies were detected using goat anti-rabbit IgG linked with FITC 1:50 (Southern Biotechnology), while the mouse-derived antibodies were detected using TXRD-linked goat anti-mouse IgG.

To determine oxidative stress and its relationship to either apoptosis or neuronal damage during MS, sections were incubated overnight at 4 °C with either FITC-linked TUNEL and rabbit anti-NITT and mouse anti-MDA 1:50 (Alpha Diagnostic) or with rabbit anti-NITT and mouse anti-non-phosphorylated neurofilaments (SMI-32). These primary antibodies were detected using TXRD-linked goat anti-mouse IgG and goat anti-rabbit IgG linked with AMCA 1:50 (Jackson ImmunoResearch).

To determine which cells expressed MT-I+II, we performed double immunofluorescence by incubating sections overnight at 4 °C with TXRD-linked tomato lectin 1:500 (Sigma-Aldrich) simultaneously with rabbit anti-rat MT-I+II (as above). The primary antibodies were detected using FITC-linked goat anti-rabbit IgG. Other sections were incubated overnight at 4 °C with rabbit anti-human GFAP 1:250 (Santa Cruz Biotech.) simultaneously with mouse anti-horse MT-I+II 1:50 (Dakopatts). These antibodies were detected using TXRD-linked goat anti-mouse IgG and FITC-linked goat anti-rabbit IgG. Other sections were incubated overnight at 4 °C with mouse anti-human CNPase, 1:150, (Biogenesis), ready-to-use, mouse anti-human NF (Biogenex) or mouse anti-human CD3 and simultaneously with rabbit anti-rat MT-I+II. These antibodies were detected using TXRD-linked goat anti-mouse IgG and FITC-linked goat anti-rabbit IgG.

To determine the association between MT-I+II expression and cell death, other sections were incubated with FITC-linked TUNEL and afterwards incubated overnight at 4 °C with rabbit anti-rat MT-I+II. The anti-MT-I+II antibodies were detected using TXRD-linked goat anti-rabbit IgG 1:50 (Jackson ImmunoResearch).

To determine the association between MT-I+II expression and oxidative stress, sections were incubated overnight at 4 °C with rabbit anti-rat MT-I+II and mouse anti-NITT 1:100 (Alpha Diagnostic) or mouse anti-MDA 1:100 (Alpha Diagnostic). These antibodies were detected using TXRD-linked goat anti-mouse IgG and FITC-linked goat anti-rabbit IgG. The sections were embedded in 20 µl fluorescent mounting (Dakopatts) and kept in darkness at 4 °C.

The colors generated are primarily green (FITC), red (TXRD) and blue (AMCA). When green and red are colocalized, the color observed is yellow. When green and blue are colocalized, the color observed is turquoise. When red and blue are colocalized, the color observed is pink.

To evaluate the extent of non-specific binding of the antisera in the fluorescence stainings, control sections were

incubated in the absence of primary antibody. Results were considered only when these controls were negative. For the simultaneous examination and recording of the three stains, a Zeiss Axioplan2 light microscope equipped with a tripleband (FITC/TXRD/AMCA) filter was used.

Cell counts and statistical analysis

For statistical analysis of the results, positively stained cells (defined as those cells with cytoplasmic staining or, in the case of TUNEL, cells with nuclear staining) were counted in a blinded manner in representative matched 0.5-mm² brain areas. To this end, we used histologically matching areas from either temporal or frontal cerebral cortex. For example, if we counted cells from frontal cortex layer 4 (internal granular layer) of one patient with MS, we also counted cells from the matching frontal cortex layer 4 (internal granular layer) of the control brains. Statistical analysis was performed with either one-way analysis of variance (ANOVA) followed by the post hoc Scheffé test or Kruskal-Wallis test (Mann-Whitney U test). A difference was considered significant when $p < 0.05$.

Results

Inflammatory infiltrates

Brain sections were obtained from both chronic inactive and chronic active lesions of MS patients. These lesions were initially classified according to their histologic features after histochemical staining and light-microscopic study. The control brain tissues displayed no neuropathologic findings.

In control sections, round macrophages and T lymphocytes were not detected and immunoreactivity for the proinflammatory cytokines IL-6 and TNF- α was very rarely seen (data not shown). In MS brain sections, numerous inflammatory cells were detected in the active lesions in comparison with inactive lesions and control sections, as judged using H&E, Kluver-Barrera, lectin histochemistry and immunoreactivity for CD3, CD4 and CD14. Hence, in the active lesions, several lectin+ CD14+ macrophages and CD3+CD4+ T lymphocytes were seen, and these cells expressed increased levels of IL-6 and TNF- α (data not shown). Furthermore, these active lesions showed macrophages containing Luxol fast blue positive myelin debris. A pronounced GFAP+ reactive astrogliosis was also seen in the active MS lesions (fig.1). The number of macrophages and T cells were significantly reduced in inactive lesions, as were in the expression of IL-6 and TNF- α (table 1). In contrast, the number of astrocytes (both reactive and resting) observed in the inactive MS lesions was higher than in the active lesions (fig. 1, table 1).

Table 1. Cell counts from MS lesions and controls.

| | Control (n=15) | Inactive MS (n=15) | Active MS (n=15) |
|---------------|-------------------|-----------------------|---------------------|
| CD3 | 0.87±0.92 | 30.80±6.69 | 55.80±7.01 |
| CD14 | 1.47±0.92 | 70.67±14.78 | 130.93±17.62 |
| GFAP | 21.13±5.66 | 122.93±17.50 | 72.40±5.26 |
| IL-6 | 0.33±0.49 | 76.33±13.27 | 140.40±18.17 |
| TNF- α | 0.53±0.64 | 71.87±13.26 | 135.53±18.97 |
| NITT | 2.27±1.71 | 15.40±5.01 | 55.13±13.78 |
| MDA | 2.60±1.96 | 20.53±6.64 | 55.67±8.36 |
| TUNEL | 1.87±1.41 | 10.13±3.29 | 59.07±10.02 |
| MT-I+II | 25.87±7.88 | 86.20±10.85 | 69.33±8.72 |

Counts of positive cellular immunostaining were carried out in a blinded manner in 15 representative 0.5-mm² brain areas from active or inactive MS lesions and from control sections. All differences between control sections and both inactive and active MS lesions, and between inactive and active MS lesions were statistically significant ($p < 0.001$).

Oxidative stress, apoptosis and neuronal damage

In sections of the control human brains, immunoreactivity for NITT (monitoring nitrotyrosine/oxidative stress) and TUNEL staining (monitoring apoptotic cell death) were rarely detected (fig. 2 A, D). Similarly, immunoreactivity for non-phosphorylated neurofilaments, indicating axonal damage, was little detected in control sections (fig. 2 G).

In contrast, the active MS lesions showed several cells with immunoreactivity for NITT as well as many TUNEL+ cells (fig. 2 B, E). As judged by using triple- or double-fluorescence stainings, the cells undergoing apoptosis were mainly NSE+ neurons (fig. 3 A), and there were also some vimentin+ astrocytes that suffered apoptotic cell death (fig. 3 A). Moreover, concomitant with apoptotic cell death, these TUNEL+ cells also contained the oxidative stress markers NITT and MDA (fig. 3 B) and non-phosphorylated neurofilaments, indicating axonal demyelination-related damage (fig. 2 H). In addition, in the active MS lesions, some oligodendrocytes were positively stained for TUNEL as well as for NITT and MDA (data not shown). Macrophages and T cells were not TUNEL+ (data not shown).

In the inactive MS lesions, the number of cells containing NITT and MDA immunoreactivity and the numbers of TUNEL+ cells were clearly reduced in comparison with the active MS lesions (fig. 2 C, F, table 1). Accordingly, the levels of apoptotic cell death of the inactive lesions were similar to those of control sections (fig. 2). However, in the case of apoptosis in the inactive MS lesions, the TUNEL+ cells were mainly neurons and some astrocytes (data not shown). Both neurons and astrocytes, and oligodendrocytes of the inactive MS lesions showed immunoreactivity for NITT and MDA and suffered apoptotic cell death as judged using triple- or double-fluorescence stainings (data not shown).

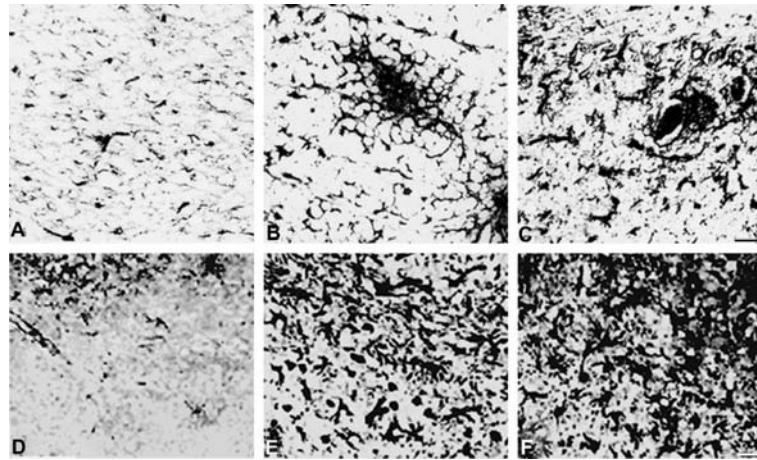


Figure 1. GFAP and MT-I+II immunoreactivity in control sections, active MS lesions and inactive MS lesions. Scale bars, A–C = 55 μ m; D–F = 66 μ m. (A) In control sections, GFAP expression was seen in some scattered astrocytes throughout the CNS. (B) In the active MS lesions, GFAP immunostaining was increased relative to controls, showing some clusters of reactive astrocytes in the MS lesions in the white matter. (C) In the inactive MS lesions, GFAP immunoreactivity was increased when compared to that of active MS lesions. Accordingly, several GFAP+ astrocytes were seen in the white matter. (D) Some scattered astrocytes showed MT-I+II expression in control sections. (E) In the active MS lesions, MT-I+II were increased in astrocytes and macrophages/microglia. (F) MT-I+II expression was significantly increased in the inactive MS lesions in comparison with control sections.

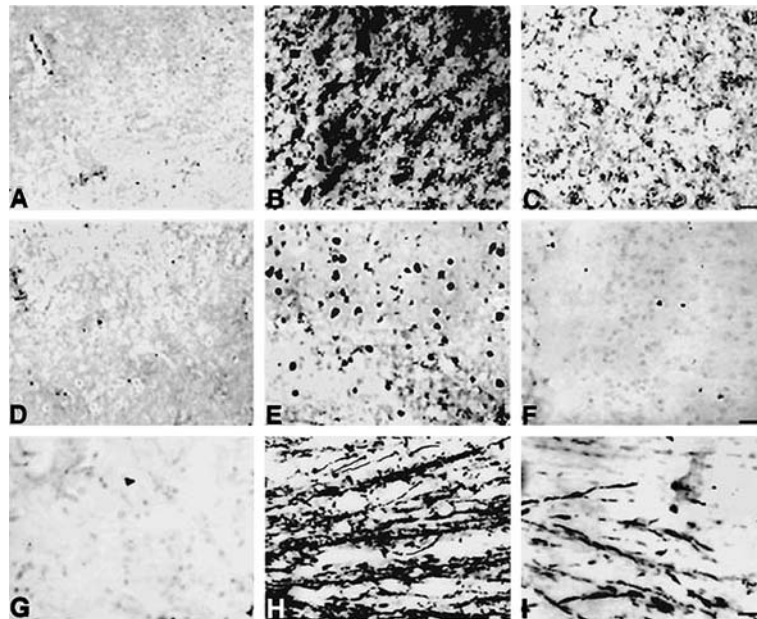


Figure 2. Oxidative stress marker NITT (A–C), TUNEL (D–F), and non-phosphorylated neurofilament (SMI-32) expression (G–I). Scale bars, A–C = 50 μ m; D–F = 66 μ m; G–I = 55 μ m. (A) In control sections, slight immunoreactivity for NITT was seen in a very few cells. (B) NITT immunoreactivity was significantly increased in active MS lesions. (C) In the inactive MS lesions, immunoreactivity for NITT was reduced in comparison with the active lesions. (D) Only very few cells were labeled by TUNEL in control sections. (E) The number of TUNEL+ cells was significantly increased in the active MS lesions. (F) In the inactive MS lesions, the number of TUNEL+ cells was clearly reduced when compared to active MS lesions. (G) In control sections, immunostaining for SMI-32 was hardly seen. (H) In the active MS lesions, SMI-32 immunoreactivity was significantly increased in comparison with controls. Thus, numerous neuronal processes and axon-terminal spheroids were stained positively for SMI-32 indicating demyelinating axons and axonal transection. (I) In inactive MS lesions, immunostaining for SMI-32 was reduced in comparison with that of the active MS lesions, indicating that demyelination and axonal transection were less pronounced.

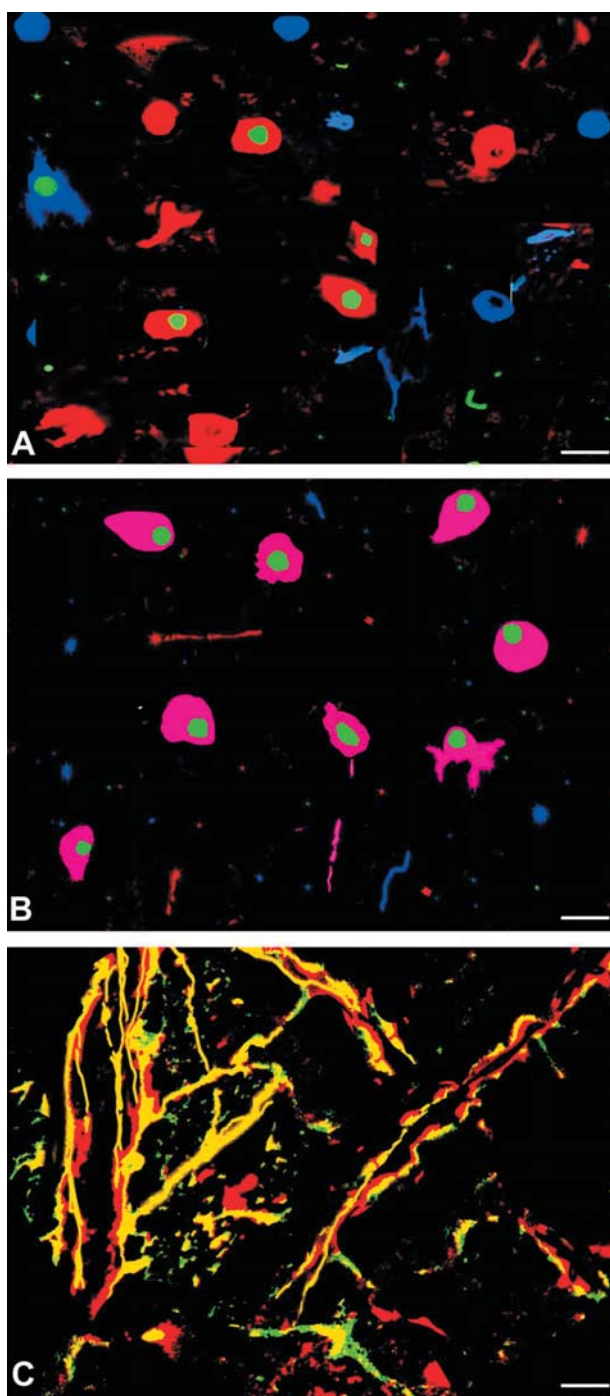


Figure 3. Apoptosis and oxidative stress in active MS lesions. Scale bars, A, B = 30 μ m; C = 50 μ m. (A) Triple staining for TUNEL (green), NSE+ neurons (red), and vimentin+ astrocytes and macrophages (blue). As shown, mainly neurons, though also a very few astrocytes, were suffering from apoptotic cell death in the active MS lesions. Macrophages were rarely stained positively for TUNEL. (B) Triple staining showing TUNEL (green), NITT (blue) and MDA (red). The TUNEL+ apoptotic cells were also suffering oxidative stress because they simultaneously expressed NITT and MDA (pink). (C) Double immunofluorescence for SMI-32 (red) and NITT (green). Several damaged axons (SMI-32+) were also suffering oxidative stress (yellow).

Moreover, immunoreactivity for non-phosphorylated neurofilaments, indicating axonal demyelination-related damage, was significantly increased in both the active (fig. 2 H) and in the inactive (fig. 2 I) MS lesions.

MT-I+II expression

In control sections, MT-I+II expression was detected in non-neuronal cells, mainly some astrocytes dispersed throughout the CNS as well as meningeal cells, ependymal cells and in the choroid plexus. Conversely, microglia, oligodendrocytes and neurons appeared roughly devoid of MT-I+II expression (fig. 1 D).

In all the MS lesions, MT-I+II were significantly increased (fig. 1 E, F). Accordingly, in the active MS lesions, MT-I+II expression was increased in several astrocytes and also in activated macrophages/microglia (fig. 4 A, B). In the inactive MS lesions, MT-I+II expression was significantly increased in most of the observed astrocytes, whereas it was hardly detected in macrophages (data not shown). In all the MS lesions, CD3+ T lymphocytes, CNPase+ oligodendrocytes and NF+ neurons were devoid of MT-I+II immunoreactivity (fig. 4 C–E). In addition, we observed that the MT-I+II-expressing cells of all the MS lesions never suffered oxidative stress or apoptosis as judged from using double staining for TUNEL and MT-I+II (fig. 4 F), or double immunostaining for MT-I+II and NITT (fig. 4 G), pointing to antioxidative and antiapoptotic actions of MT-I+II.

Interestingly, the levels of MT-I+II were increased in the inactive MS lesions in comparison with the active lesions (fig. 1, table 1).

Discussion

MT-I+II are cysteine-rich, heavy-metal-binding proteins that bind Zn and Cu and presumably function in metal ion regulation and detoxification in peripheral tissues and the CNS. Accumulating evidence suggests that MTs could be significant antioxidant proteins [29–31] that may protect against the myelin and neuronal damage occurring in MS. In this context, recent published work from our group has shown that MT-I+II are involved in the pathogenesis of EAE, playing a protective role, given that MT-I+II-deficient mice suffer from a more severe EAE than control animals [16] and treatment of EAE with Zn-MT-II has a beneficial effect, reducing the severity of the clinical symptoms and mortality in a dose-dependent manner [17, 18].

In contrast to the increasing data on the role of MTs in EAE, little is known about the actual role of these proteins in MS. To our knowledge, this is the first report showing the expression of MT-I+II proteins in MS plaques by immunohistochemistry. We observed that MT-I+II expression was significantly increased in MS lesions compared to

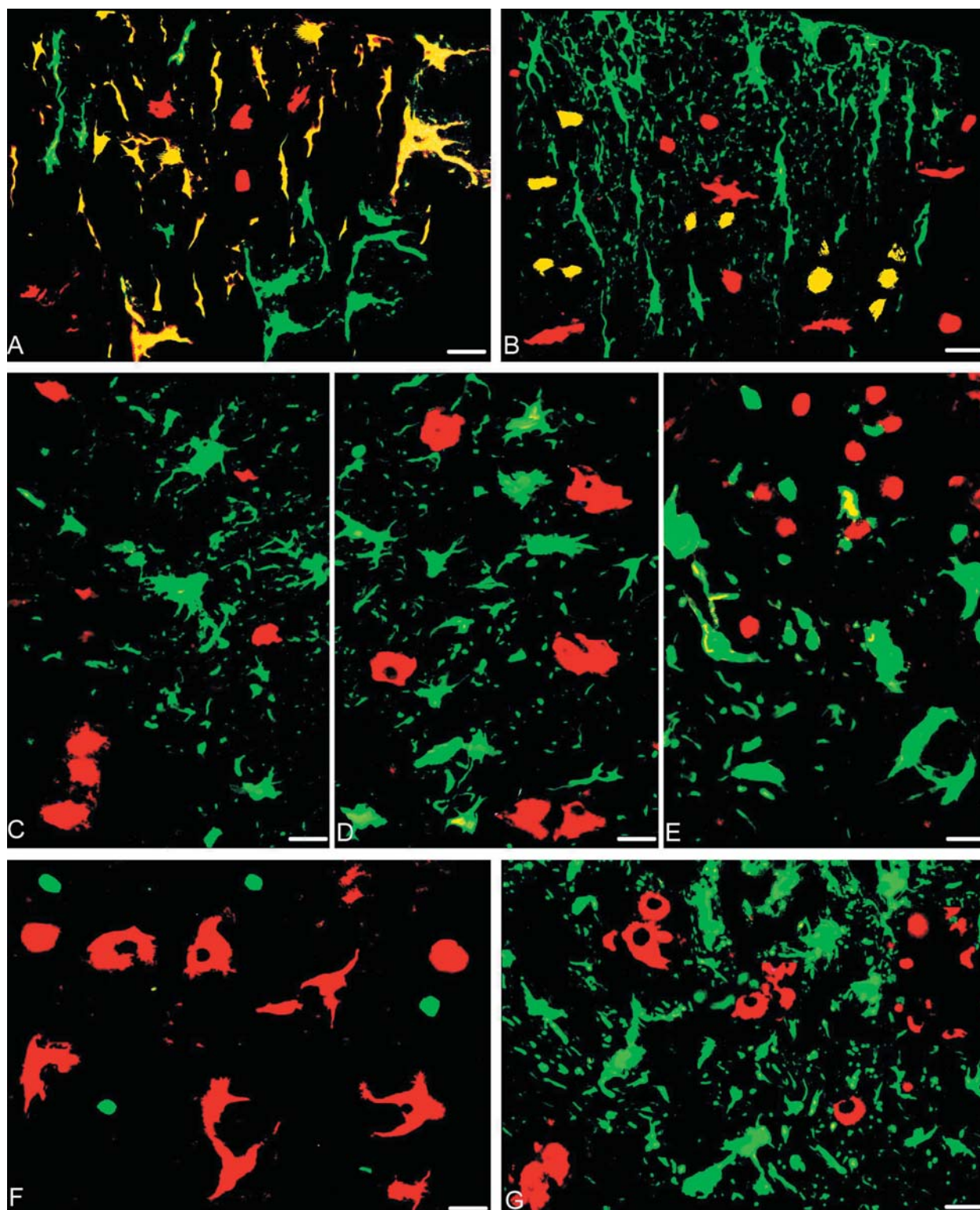


Figure 4. Double immunofluorescence stainings of active MS brain lesions showing cellular localization of MT-I+II. Scale bars, A = 21 μm ; B = 19 μm ; C–E, G = 20 μm ; F = 16 μm . (A) GFAP (green) and MT-I+II (red) expression were both seen in astrocytes (yellow). MT-I+II were additionally expressed in other round cells. (B) Lectin (red) and MT-I+II (green) staining were colocalized in some round or amoeboid macrophages (yellow). However, most MT-I+II⁺ cells were stellate astrocytic cells. (C) CNPase (red) and MT-I+II (green) immunoreactivity showed that oligodendrocytes were devoid of MT-I+II. (D) NF (red) and MT-I+II (green) stainings showed that neurons expressed little MT-I+II. (E) CD3 (red) and MT-I+II (green) immunoreactivity showed that lymphocytes were devoid of MT-I+II. (F) Double staining showing TUNEL (green) and MT-I+II immunoreactivity (red). The MT-I+II-expressing cells were protected from apoptosis. MT-I+II were observed in astrocytes and macrophages. (G) Immunoreactivity for NITT (red) and MT-I+II (green) showed that MT-I+II-expressing cells were protected from oxidative stress.

control sections. MT-I+II expression was found in astrocytes and activated macrophages/microglia, whereas T lymphocytes, oligodendrocytes and neurons were devoid of MT-I+II immunoreactivity. These results are in agreement with other reports on MT-I+II expression during EAE [16, 17]. Interestingly, the MT-I+II-expressing cells of all the MS brain sections never suffered oxidative stress or apoptosis, which supports the hypothesis that MTs have a protective role against oxidative stress and cell death, probably arising from their ability to act as scavengers of superoxide and hydroxyl radicals [32, 33].

MT expression was observed in all MS lesions analyzed. MT induction was most probably driven by inflammatory cytokines, such as IL-6 and TNF- α [34–36], and oxidative stress [37, 38] present in MS lesions. A number of reports in the literature have shown increases in proinflammatory cytokines and oxidative stress markers in MS lesions [39–42] and in the animal model of the disease, EAE, in which these events have been more extensively analyzed [43, 44], supporting their important pathogenic role in disease induction. In relation to MT expression, our results agree with those recently reported by Lock et al. [24] for mRNA. Looking at gene-microarray analysis of MS lesions of four individuals, these authors found an increase in MT gene expression in all samples analyzed (two acute and two chronic silent lesions). Interestingly, in the present work, we observed that the levels of MT-I+II were slightly increased in the inactive MS lesions in comparison with the active lesions, accompanying the increased number of GFAP+ cells (astrocytes). The number of astrocytes is likely increased in inactive MS lesions relative to active lesions, because astroglia are particularly important and activated during CNS recovery. Astrocytes are needed during CNS recovery and neuroregeneration as the main cell source in the brain of antioxidants, growth factors and trophic molecules. Moreover, the astroglia produce components of the extracellular matrix which may be necessary during CNS recovery. The high levels of MT-I+II expression also found in inactive MS lesions suggest that MT-I+II may have a role in the remission of the disease.

The exact mechanisms of action of MT-I+II in MS need to be elucidated. From the EAE studies one can hypothesize that MT-I+II (i) might act directly as antioxidants, or (ii) could indirectly decrease oxidative stress by reducing the reactive oxygen species produced by macrophages or (iii) by increasing the number of astrocytes, a main source of antioxidant factors [17]. Whatever the case may be, all these data point to a beneficial effect of these proteins in EAE/MS and hint at MT-I+II as potential candidates for MS treatment.

Acknowledgements. The authors wish to acknowledge Ms M. J. Trujillo and M. T. Moran from the Neuropathology Unit, Department of Pathology, Vall d'Hebron University Hospital (Barcelona, Spain), H. Hadberg and H. Nguyen for their technical help, G. Hahn

and K. Stub for photographic assistance, and Mr. J. Graells for language editing in the preparation of this manuscript. The study was supported by FIS 00/0846 and Fundació Esclerosi Multiple (Spain), Scleroseforeningen, Warwara Larsens Fond, Hestehandler Ole Jacobsens Mindelegat, Gerda og Aage Haensch's Fond, Dir. Jacob Madsens Fond, Ragnhild Ibsens Legat for Medicinsk Forskning, Lily Benthine Lunds Fond, Lægeforeningens forskningsfond: 23,500, Dir. Ib Henriksens Fond, ØJENFONDEN, Karen A Tolstrups Fond, Direcció General de Recerca 2001 SGR00203, SAF 2002-01268 (J. H.). C. E. was a predoctoral fellow of Fondo de Investigación Sanitaria FIS 00/0846 (Spain) during this study.

- 1 Lin R. F., Lin T. S., Tilton R. G. and Cross A. H. (1993) Nitric oxide localized to spinal cords of mice with experimental allergic encephalomyelitis: an electron paramagnetic resonance study. *J. Exp. Med.* **178**: 643–648
- 2 Koprowski H., Zheng Y. M., Heber-Katz E., Fraser N., Rorke L., Fu Z. F. et al. (1993) In vivo expression of inducible nitric oxide synthase in experimentally induced neurologic diseases. *Proc. Natl. Acad. Sci. USA* **90**: 3024–3027
- 3 Cross A. H., Misko T. P., Lin R. F., Hickey W. F., Trotter J. L. and Tilton R. G. (1994) Aminoguanidine, an inhibitor of inducible nitric oxide synthase, ameliorates experimental autoimmune encephalomyelitis in SJL mice. *J. Clin. Invest.* **93**: 2684–2690
- 4 Akaike T., Weihe E., Schaefer M., Fu Z. F., Zheng Y. M., Vogel W. et al. (1995) Effect of neurotropic virus infection on neuronal and inducible nitric oxide synthase activity in rat brain. *J. Neurovirol.* **1**: 118–125
- 5 Hooper D. C., Ohnishi S. T., Kean R., Numagami Y., Dietzschold B. and Koprowski H. (1995) Local nitric oxide production in viral and autoimmune diseases of the central nervous system. *Proc. Natl. Acad. Sci. USA* **92**: 5312–5316
- 6 Bagasra O., Michaels F. H., Zheng Y. M., Bobroski L. E., Spitsin S. V., Fu Z. F. et al. (1995) Activation of the inducible form of nitric oxide synthase in the brains of patients with multiple sclerosis. *Proc. Natl. Acad. Sci. USA* **92**: 12041–12045
- 7 Bo L., Dawson T. M., Wesselingh S., Mork S., Choi S., Kong P. A. et al. (1994) Induction of nitric oxide synthase in demyelinating regions of multiple sclerosis brains. *Ann. Neurol.* **36**: 778–786
- 8 Radi R., Beckman J. S., Bush K. M. and Freeman B. A. (1991) Peroxynitrite-induced membrane lipid peroxidation: the cytotoxic potential of superoxide and nitric oxide. *Arch. Biochem. Biophys.* **288**: 481–487
- 9 Beckman J. S. (1991) The double-edged role of nitric oxide in brain function and superoxide-mediated injury. *J. Dev. Physiol.* **15**: 53–59
- 10 Touil T., Deloire-Grassin M. S., Vital C., Petry K. G. and Brochet B. (2001) In vivo damage of CNS myelin and axons induced by peroxynitrite. *Neuroreport* **12**: 3637–3644
- 11 Hooper D. C., Bagasra O., Marini J. C., Zborek A., Ohnishi S. T., Kean R. et al. (1997) Prevention of experimental allergic encephalomyelitis by targeting nitric oxide and peroxynitrite: implications for the treatment of multiple sclerosis. *Proc. Natl. Acad. Sci. USA* **94**: 2528–2533
- 12 Hooper D. C., Spitsin S., Kean R. B., Champion J. M., Dickson G. M., Chaudhry I. et al. (1998) Uric acid, a natural scavenger of peroxynitrite, in experimental allergic encephalomyelitis and multiple sclerosis. *Proc. Natl. Acad. Sci. USA* **95**: 675–680
- 13 Spitsin S., Hooper D. C., Leist T., Streletz L. J., Mikheeva T. and Koprowski H. (2001) Inactivation of peroxynitrite in multiple sclerosis patients after oral administration of inosine may suggest possible approaches to therapy of the disease. *Mult. Scler.* **7**: 313–319
- 14 Drulovic J., Dujmovic I., Stojsavljevic N., Mesaros S., Andjelkovic S., Miljkovic D. et al. (2001) Uric acid levels in sera from patients with multiple sclerosis. *J. Neurol.* **248**: 121–126

- 15 Espejo C., Carrasco J., Hidalgo J., Penkowa M., Garcia A., Saez-Torres I. et al. (2001) Differential expression of metallothioneins in the CNS of mice with experimental autoimmune encephalomyelitis. *Neuroscience* **105**: 1055–1065
- 16 Penkowa M., Espejo C., Martinez-Caceres E. M., Poulsen C. B., Montalban X. and Hidalgo J. (2001) Altered inflammatory response and increased neurodegeneration in metallothionein I+II deficient mice during experimental autoimmune encephalomyelitis. *J. Neuroimmunol.* **119**: 248–260
- 17 Penkowa M. and Hidalgo J. (2000) Metallothionein I+II expression and their role in experimental autoimmune encephalomyelitis. *Glia* **32**: 247–263
- 18 Penkowa M. and Hidalgo J. (2001) Metallothionein treatment reduces proinflammatory cytokines IL-6 and TNF-alpha and apoptotic cell death during experimental autoimmune encephalomyelitis (EAE). *Exp. Neurol.* **170**: 1–14
- 19 Carrasco J., Giralto M., Molinero A., Penkowa M., Moos T. and Hidalgo J. (1999) Metallothionein (MT)-III: generation of polyclonal antibodies, comparison with MT-I+II in the freeze lesioned rat brain and in a bioassay with astrocytes, and analysis of Alzheimer's disease brains. *J. Neurotrauma* **16**: 1115–1129
- 20 Adlard P. A., West A. K. and Vickers J. C. (1998) Increased density of metallothionein I/II-immunopositive cortical glial cells in the early stages of Alzheimer's disease. *Neurobiol. Dis.* **5**: 349–356
- 21 Duguid J. R., Bohmont C. W., Liu N. G. and Tourtellotte W. W. (1989) Changes in brain gene expression shared by scrapie and Alzheimer disease. *Proc. Natl. Acad. Sci. USA* **86**: 7260–7264
- 22 Sillevs Smitt P. A., Blaauwgeers H. G., Troost D. and Jong J. M. de (1992) Metallothionein immunoreactivity is increased in the spinal cord of patients with amyotrophic lateral sclerosis. *Neurosci. Lett.* **144**: 107–110
- 23 Lookeren Campagne M. van, Thibodeaux H., Bruggen N. van, Cairns B., Gerlai R., Palmer J. T. et al. (1999) Evidence for a protective role of metallothionein-I in focal cerebral ischemia. *Proc. Natl. Acad. Sci. USA* **96**: 12870–12875
- 24 Lock C., Hermans G., Pedotti R., Brendolan A., Schadt E., Garren H. et al. (2002) Gene-microarray analysis of multiple sclerosis lesions yields new targets validated in autoimmune encephalomyelitis. *Nat. Med.* **8**: 500–508
- 25 Penkowa M., Carrasco J., Giralto M., Moos T. and Hidalgo J. (1999) CNS wound healing is severely depressed in metallothionein I- and II-deficient mice. *J. Neurosci.* **19**: 2535–2545
- 26 Gasull T., Rebollo D. V., Romero B. and Hidalgo J. (1993) Development of a competitive double antibody radioimmunoassay for rat metallothionein. *J. Immunoassay* **14**: 209–225
- 27 Penkowa M., Hidalgo J. and Moos T. (1997) Increased astrocytic expression of metallothioneins I + II in brainstem of adult rats treated with 6-aminonicotinamide. *Brain Res.* **774**: 256–259
- 28 Penkowa M., Giralto M., Moos T., Thomsen P. S., Hernandez J. and Hidalgo J. (1999) Impaired inflammatory response to glial cell death in genetically metallothionein-I- and -II-deficient mice. *Exp. Neurol.* **156**: 149–164
- 29 Aschner M. (1997) Astrocyte metallothioneins (MTs) and their neuroprotective role. *Ann. NY Acad. Sci.* **825**: 334–347
- 30 Aschner M., Cherian M. G., Klaassen C. D., Palmiter R. D., Erickson J. C. and Bush A. I. (1997) Metallothioneins in brain – the role in physiology and pathology. *Toxicol. Appl. Pharmacol.* **142**: 229–242
- 31 Hidalgo J., Aschner M., Zatta P. and Vasak M. (2001) Roles of the metallothionein family of proteins in the central nervous system. *Brain Res. Bull.* **55**: 133–145
- 32 Thornalley P. J. and Vasak M. (1985) Possible role for metallothionein in protection against radiation-induced oxidative stress: kinetics and mechanism of its reaction with superoxide and hydroxyl radicals. *Biochim. Biophys. Acta* **827**: 36–44
- 33 Lazo J. S. and Pitt B. R. (1995) Metallothioneins and cell death by anticancer drugs. *Annu. Rev. Pharmacol. Toxicol.* **35**: 635–653
- 34 Hernandez J., Molinero A., Campbell I. L. and Hidalgo J. (1997) Transgenic expression of interleukin 6 in the central nervous system regulates brain metallothionein-I and -III expression in mice. *Brain Res. Mol. Brain Res.* **48**: 125–131
- 35 Carrasco J., Hernandez J., Bluethmann H. and Hidalgo J. (1998) Interleukin-6 and tumor necrosis factor-alpha type 1 receptor deficient mice reveal a role of IL-6 and TNF-alpha on brain metallothionein-I and -III regulation. *Brain Res. Mol. Brain Res.* **57**: 221–234
- 36 Giralto M., Penkowa M., Hernandez J., Molinero A., Carrasco J., Lago N. et al. (2002) Metallothionein-1+2 deficiency increases brain pathology in transgenic mice with astrocyte-targeted expression of interleukin 6. *Neurobiol. Dis.* **9**: 319–338
- 37 Andrews G. K. (2000) Regulation of metallothionein gene expression by oxidative stress and metal ions. *Biochem. Pharmacol.* **59**: 95–104
- 38 Hidalgo J., Penkowa M., Giralto M., Carrasco J. and Molinero A. (2002) Metallothionein expression and oxidative stress in the brain. *Methods Enzymol.* **348**: 238–249
- 39 Maimone D., Guazzi G. C. and Annunziata P. (1997) IL-6 detection in multiple sclerosis brain. *J. Neurol. Sci.* **146**: 59–65
- 40 Vladimirova O., O'Connor J., Cahill A., Alder H., Butunoi C. and Kalman B. (1998) Oxidative damage to DNA in plaques of MS brains. *Mult. Scler.* **4**: 413–418
- 41 Windhagen A., Newcombe J., Dangond F., Strand C., Woodroffe M. N., Cuzner M. L. et al. (1995) Expression of costimulatory molecules B7-1 (CD80), B7-2 (CD86), and interleukin 12 cytokine in multiple sclerosis lesions. *J. Exp. Med.* **182**: 1985–1996
- 42 Ming X., Li W., Maeda Y., Blumberg B., Raval S., Cook S. D. et al. (2002) Caspase-1 expression in multiple sclerosis plaques and cultured glial cells. *J. Neurol. Sci.* **197**: 9–18
- 43 Espejo C., Penkowa M., Saez-Torres I., Hidalgo J., Garcia A., Montalban X. et al. (2002) Interferon-gamma regulates oxidative stress during experimental autoimmune encephalomyelitis. *Exp. Neurol.* **177**: 21–31
- 44 Segal B.M. (2003) Experimental autoimmune encephalomyelitis: cytokines, effector T cells, and antigen-presenting cells in a prototypical Th1-mediated autoimmune disease. *Curr. Allergy Asthma Rep.* **3**: 86–93

