

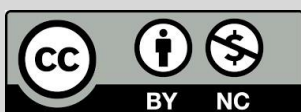## Alleviating Effects of Clove Essential Oil Dissolved in Dimethyl Sulfoxide (DmsO) Against Cadmium-Induced Testicular and Epididymal Damages in Male Wistar Rats

Uchewa, OO<sup>1\*</sup>, Chukwuemeli, CE<sup>1</sup>, Ovierson, AI<sup>2</sup>, Ibegbu, AO<sup>1</sup>

1. Department of Anatomy, Faculty of Basic Medical Sciences, Alex Ekwueme, Federal University, Ndufu-Alikekwo, Ebonyi State, Nigeria
2. Department of Anatomy, Faculty of Basic Medical Sciences, College of Medicine, Edo University, Uzaze, Edo State

**How to cite this article:** Uchewa OO, Chukwuemeli CE, Ovierson AI, Ibegbu AO. Alleviating Effects of Clove Essential Oil Dissolved in Dimethyl Sulfoxide (DmsO) Against Cadmium-Induced Testicular and Epididymal Damages in Male Wistar Rats. *Archives of Razi Institute*. 2023;78(6):1728-37.

DOI: 10.32592/ARI.2023.78.6.1728



Copyright © 2023 by



Razi Vaccine & Serum Research Institute

### Article Info:

Received: 26 December 2022

Accepted: 06 June 2023

Published: 30 December 2023

Corresponding Author's E-Mail:  
euchewa1@gmail.com

### ABSTRACT

Cloves possess antimicrobial and antioxidant activities, among other roles, they can play. This study investigated the effect of clove oil (CLO) on testicular and epididymal changes induced by cadmium chloride (CdCl). A total of 25 rats were randomly assigned to five groups of five rats. Group A was allowed feed and water *ad libitum*. Group B was given 20mg/kg of CdCl, group C was given 20mg/kg of CdCl and 10mg/kg of CLO, group D was given 20mg/kg of CdCl and 20mg/kg of CLO, and group E was given 20mg/kg of CdCl and 20mg/kg of Di Methyl Sulphur Oxide. After the experiment, the animals were sacrificed by cervical dislocation after 24 hours of fasting. The testes and epididymis were harvested, while the right epididymis was homogenized for sperm analysis. The results revealed a significant decrease in progressive motility in group B, while a significant increase was observed in CLO-treated groups ( $P < 0.05$ ). In addition, group B showed a significant reduction in percentage progressive, an increase in percentage non-motile, and a decrease in sperm count. The histological studies showed that the control group displayed normal testicular and epididymal histo-architecture, while the Cadmium group (B) showed a progressive degeneration of the cells and tissues, alleviated by the high dose of CLO in both the testes and epididymis. In conclusion, the current research demonstrated that testicular and epididymal damage induced by Cadmium could decrease fertility, and CLO may be used in alleviating the deleterious effects of CdCl.

**Keywords:** Cadmium, Clove oil, Epididymis, Motility, Sperm morphology, Testes, Wistar rats

## 1. Introduction

Chemical pollutants altering reproductive health have drawn significant attention in recent decades and are further compounded by the accumulation of endocrine-disruptive chemicals in the environment (1). Chemicals interrupting normal endocrine functions may interfere with the hormonal pathways responsible for controlling reproduction, thereby triggering morphological and functional abnormalities (2). Cadmium is a ubiquitous environmental contaminant from electroplating, plastics manufacturing, mining, alloy preparation, and batteries. Cadmium is also a known endocrine system disruptor and a reproductive toxicant, which affects male fertility through direct gonadotoxic and spermotoxic effects (3). This can also be through altered hypothalamic-pituitary-testicular axis function (4). Several researchers have confirmed that the testis is more sensitive to cadmium than other vital organs (5). Testicular toxicity is also a result of interactions between complex networks involving the inhibition of oxidative stress leading to a marked increase in germ cell apoptosis (6) and alteration of the blood-testis barrier.

The above issues lead to subsequent germ cell loss and testicular edema (7) due to fluid accumulation and hemorrhage (8). Damages from Cadmium are visible at interstitial and tubular levels after prolonged exposure (3). Controversy exists regarding changes in testicular weight after Cadmium exposure. Disruptions of cell junction and the blood-epididymis barrier are one of the main targets of Cadmium in the epididymis that causes deficiency in sperm maturation and motility (9). Subchronic exposure to Cadmium leads to epithelial thickening, distension of the tubule lumen, and inflammation (7). Apart from the epithelial disruption, Cadmium also induces edema, ischemia, and vasoconstriction as direct consequences of altered hemodynamics injury to the vascular endothelium (10). Epididymal weight increase generally indicates excessive interstitial fluid accumulation and is a sensitive indicator of decreased sperm production (2).

According to Ohtani *et al.* (11), Cadmium can significantly atrophy the epididymis, reduce the lumen diameter, and alkalize it. It is well established that testicular and epididymal oxidative stress is commonly induced under different normal and pathophysiological conditions, leading to male infertility. Oxidative stress has been a common factor in about half of the infertile men examined to date, illustrating the importance of Cadmium as an inducer of oxidative stress (1-6). Although the testis expresses several antioxidative enzymes, such as superoxide dismutase, catalase, and glutathione peroxidase, to counteract oxidative stress, their levels are significantly diminished upon Cadmium exposure (11). Therefore, both antioxidant and non-enzymatic agents may prevent or reduce Cadmium toxicity to the testis (8, 10). Much attention has been recently paid to the protective effects of natural antioxidants against chemical-induced toxicities, especially whenever free radical generations are involved (12). Among these natural antioxidants is Clove oil (CLO).

Eugenol, or CLO, is a volatile phenolic constituent of CLO from *Eugenia caryophyllata* buds mainly harvested from Indonesia and Madagascar (13). The name is supposedly derived from the scientific name for the clove *E. caryophyllata* tree, which has large leaves and flower buds that turn red when they are ready for collection (14). The most important properties of eugenol are antimicrobial, anti-inflammatory, analgesic, and antioxidant. Available experimental data show that eugenol has an antioxidant capacity and free radical scavenging activity by significantly suppressing lipid peroxidation and low-density lipoprotein oxidation caused by metallic ions (14). Several studies have shown that essential dietary supplements play an important role in protecting against Cadmium-induced toxicity by binding to Cadmium, causing its detoxification (14).

The study seeks to ascertain the endocrine effect of CLO on testicular and epididymal changes induced by Cadmium in male Wistar rats.

## 2. Materials and Methods

### 2.1. Ethical Clearance

Ethical clearance was obtained from Alex Ekwueme Federal University Ndufu Alike Ikwo (AE-FUNAI) Ethics and Animal Welfare Committee with reference Number AEFUNAI/2020/1501 and the Norwegian National Research Ethics Committee (15), principles and practices of research were strictly followed.

### 2.2. Experimental Animal Care and Management

A total of 25 male Wistar rats were purchased from the animal house of Alex Ekwueme Federal University Ndufu Alike, Ikwo (AE-FUNAI) and housed in netted cages under standardized conditions of 25-28°C and relative humidity between 35% and 70%. The rats were allowed free access to feeds and water *ad-libitum*. The rat pellets contained mostly glucose, maltose, fructose, sucrose, dextrin, and protein. The procedures for research animal care and handling according to AE-FUNAI guidelines were strictly followed throughout the study. After seven days of acclimatization, the animals were randomly assigned into five groups, with five rats in each group.

### 2.3. Experimental Design

The male Wistar rats (n=25) were randomly assigned into five groups of five rats after one week of acclimatization. Group A (control group) received normal saline and fed *ad libitum*. Group B received 20mg/kg of cadmium chloride (CdCl<sub>2</sub>). Group C received 10mg/kg of CLO dissolved in Di Methyl Sulphur Oxide (DMSO) and 20mg/kg of CdCl<sub>2</sub>. Group D received 20mg/kg of CLO and 20mg/kg of CdCl<sub>2</sub>, and Group E received 20 mg/kg of CdCl<sub>2</sub> and 20mg/kg of DMSO which served as the vehicle for dissolving the oil. These treatments were done orally using oral gavage, once daily during the mornings for 21 days, based on the weight of the rats in each group. The animals were observed for changes after each daily administration and sacrificed 24 hours after the last administration.

### 2.4. Animal Sacrifice

The animals were sacrificed using cervical dislocation after 24 hours of fasting, and blood

samples were collected from the apex of the heart and eyes for hormonal analyses. The animals were decapitated and skinned, and the epididymis and testes were fixed in Bouin's fluid after weighing the testes and the epididymis. After 48 hours, the testes and epididymis were re-fixed in 10% formol saline for histological studies.

### 2.5. Hormonal Assay

Blood samples were collected in 10 ml plastic syringes and kept at room temperature until the serum had separated. After centrifugation, the serum was transferred to a new tube and kept at room temperature until the serum had separated. After centrifugation, the serum was transferred to a new tube, kept at -20°C, and assayed within four weeks. The hormones, namely follicle-stimulating hormone (FSH) and luteinizing hormone (LH) levels, were measured by homologous specific double antibody radioimmunoassay using material kindly supplied by the National Hormone and Pituitary Program (NHPP, Rockville, MD) using r-LH-RP-3 and r-FSH-RP-2 reference preparations, respectively, as described by David and Sharon (16). The inter and intra-assay percentage coefficient variability values were less than 15 and 10, respectively. Plasma testosterone levels were measured using a commercial kit from Diagnostic Systems Laboratories Inc. (Webster, TX) validated in the laboratory.

### 2.6. Sperm morphology

The following techniques were used to identify the morphological appearance of the sperm count parameters: head shape (pin head [PH] and headless tail [HT]), tail shape (rudimentary tail, coiled tail [CT], and looped tail [LT]), and mid-piece (bent mid-piece [BMP], coiled mid-piece [CMP]). A smear of the sperm cells was made on a clean slide and was air-dried. The slides were labeled properly, rinsed, and allowed to dry before viewing them under the microscope using the 100× oil immersion objective lens. The preparation was then examined under the microscope for normal and abnormal spermatozoa using a 40× objective lens. The 100× objective lens

was used to confirm abnormalities.

### 2.7. Sperm Motility

The epidermal sperm content was obtained by the maceration of the tail of the epididymis in 1ml of Phosphate Buffered Saline (PBS). An aliquot of this solution was placed on the slide, and the percentage of motility was evaluated microscopically at a magnification of  $\times 400$ . Motility estimates were performed from the three different fields in each sample. The mean of the three estimations was used as the final motility score according to Ghasemzadeh *et al.* (17).

### 2.8. Sperm Count

The epididymis was minced in 1 ml of PBS (pH 7.2) to obtain a suspension. The suspension was filtered through a mesh (80  $\mu\text{m}$ ) (17). Sperm count was done in the filtrate using a standard method in Neubauer's chamber. Briefly, an aliquot from the suspension up to 0.5 was taken in a leukocyte hemocytometer and diluted with PBS up to the 11<sup>th</sup> mark. The suspension was well-mixed and charged in the Neubauer's counting chamber. The total sperm count in eight squares, except for the central erythrocyte area of 1mm<sup>2</sup> each, was determined and multiplied by  $5 \times 10^4$  to express the number of spermatozoa (17).

### 2.9. Histological Analysis

The testes and epididymis were immediately fixed in formol saline solution for 24 hours, processed using a graded alcohol series, and then embedded in paraffin. The paraffin sections were cut into 5 $\mu\text{m}$ -thick slices using a rotary microtome and stained using hematoxylin and eosin for microscopic examination. The sections were then viewed and

micro-graphed.

### 2.10. Data Analysis

Data generated were analyzed using the Statistical Package of Social Sciences (SPSS; version 23), and the results were expressed as mean $\pm$ S.E. The presence of a significant difference between the means of groups was determined by making use of one-way analysis of variance (ANOVA) at a P-value less than or equal to 0.05 that was considered statistically significant, whereas Tukey multiple comparison test was used to confirm the significant level.

## 3. Results

### 3.1. Animal weight

The result showed that the body weight change of the control group was lower, compared to the group with a high dose of CLO. There was a significant increase in the weight of rats in group B, compared to the control group. Animals in the groups of medium dose, high dose, and DMSO showed an increase in weight, compared to group B after treatment (Table 1).

### 3.2. Sperm Morphology

The result showed significant changes in morphological parameters, which are the PH, Round Head, HT, BMP, CMP, LT, and CT across the groups. Moreover, there was a significant increase in the parameters from the other groups, compared to group B. There was a significant increment in the medium dose, compared to groups D and E (P<0.05; Table 2).

### 3.3. Sperm Motility

The motility result showed a significant decrease in the percentage of active motility (AM) of sperm

**Table 1.** Effect of Clove oil on percentage weight change of cadmium-induced Wistar rats

Groups	Initial weight	Final weight	Weight change
Control	115.00 $\pm$ 5.52	137.80 $\pm$ 15.03	22.80 $\pm$ 9.48
CdCl	106.20 $\pm$ 8.95	143.40 $\pm$ 2.60	37.20 $\pm$ 6.35*
Medium dose	94.00 $\pm$ 7.70	115.40 $\pm$ 8.62	21.40 $\pm$ 0.92**
High dose	123.60 $\pm$ 1.21	146.80 $\pm$ 3.25	23.20 $\pm$ 2.04**
DMSO	109.20 $\pm$ 6.62	142.80 $\pm$ 4.41	33.60 $\pm$ 2.21**

\*Significant increase compared to A at P<0.05; \*\*Significant decrease compared to B at P<0.05

Note: Weight change was calculated subtracting the initial weight from Final weight.

**Table 2.** Table showing changes in the sperm morphology

Groups	PH	RH	HT	BMP	CMP	LT	CT
Control	1.50±0.50	1.50±0.50	2.50±0.50	2.50±0.50	0.50±0.50	1.50±0.50	1.00±0.00
CdCl	3.00±1.00*	2.00±0.00	3.00±1.00	4.50±0.50	1.50±0.50	1.50±0.50	1.50±0.50
Medium dose	3.50±0.50	2.00±0.00	3.50±0.50	3.00±0.00	1.00±1.00	0.50±0.50	1.00±0.00
High dose	2.50±0.50	1.50±0.50	4.00±1.00	3.50±0.50	2.50±0.50	1.50±0.50	1.50±0.50
DMSO	3.50±0.50	1.50±0.50	5.00±1.00	2.00±0.00	1.50±0.50	0.50±0.50	0.50±0.50

KEYS: PH = Pin Head; HT = Headless Tail; BMP = Bent Mid-Piece; CMP = Coiled Mid-Piece; LT = Looped Tail; CT = Coiled Tail. Mean ± SEM

**Table 3.** Table showing changes in various parameters involved in sperm motility

Groups	A.M	S.M	N.M	CNT
Control	52.50±2.50	22.50±2.50	25.00±5.00	46.00±3.00
CdCl	17.50±2.50*	22.50±2.50	60.00±5.00**	37.50±4.50*
Medium dose	21.50±1.50^	22.75±2.75	61.50±1.50	30.50±0.50 <sup>+</sup>
High dose	49.00±1.00^	20.00±0.00 <sup>+</sup>	40.00±10.00 <sup>+</sup>	48.00±2.00^
DMSO	7.50±2.50 <sup>+</sup>	17.50±5.00 <sup>+</sup>	75.00±5.00^	17.00±3.00 <sup>+</sup>

\*Significant decrease compared to A at P<0.05; \*\* Significant increase compared to A at P<0.05; <sup>+</sup>Significant decrease compared to B at P<0.05; ^Significant increase compared to B at P<0.05. A.M: Active Motility; S.M: Sluggish Motility; N.M: Non-Motility; CNT: Count

across the groups, compared to the control group; furthermore, there was an insignificant decrease in the percentage of Sluggish Motility (SM) across the group, compared to the control group, followed by a significant increase in the percentage of Non-Motility (NM) across the groups, compared to the control group. An increase was observed in NM with a high dose of CLO; however, a significant decrease was found in sperm count across the groups, except for the high-dose group in which it increased significantly (P<0.05; Table 3).

### 3.4. The Concentration of Sex Hormones

There was a significant increase in the control group, compared to the other groups, in FSH, LH, and testosterone. FSH works on the Sertoli cells to stimulate sperm production. The LH is vital in regulating the function of the testes in men (Table 4). Testosterone helps to regulate fertility muscle, fat

**Table 4.** Table showing hormone levels across each group

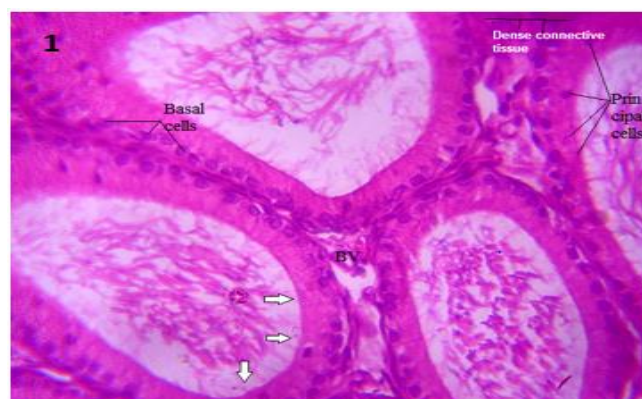Groups	FSH	LH	Testosterone
Control	13.57±0.07	1.76±0.01	3.64±0.03
CdCl	10.80±0.06*	1.64±0.01	2.96±0.01*
Medium dose	12.68±0.06^	1.69±0.01	3.04±0.01
High dose	11.50±0.06	1.71±0.01	3.13±0.01
DMSO	11.23±0.09	1.66±0.01	2.99±0.01

\* Significant decrease compared to A at P<0.05; ^ Significant increase compared to B at P<0.0

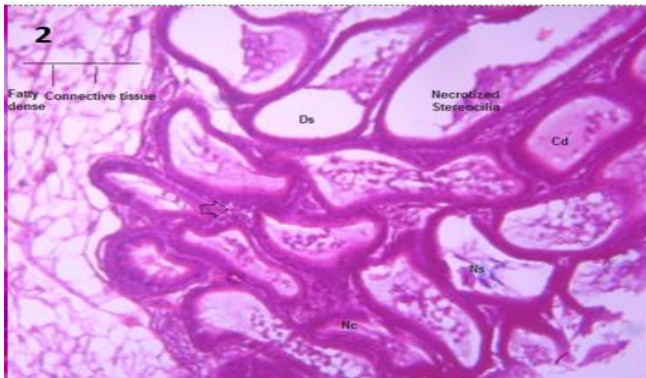
distribution, and red blood cell production.

### 3.5. Microscopic Study of the Testes and Epididymis

The result of histological analyses showed that the epididymis of the animals in the control group (A) displayed normal epididymal histoarchitecture, with dense connective tissue and well-accumulated blood vessels (Figure 1). In group B, there was a significant effect on the epididymal tissues, which resulted in the accumulation of fatty dense connective tissues and necrosis of the blood vessels

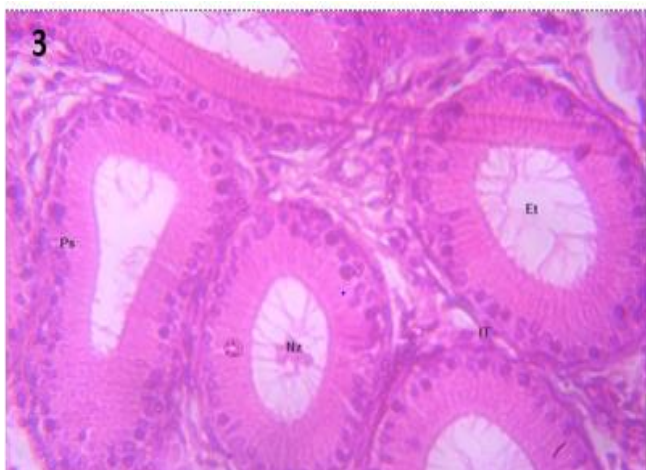


**Figure 1.** The photomicrograph of section of epididymis from the control group showing the normal two cell types (principal and basal cells), epithelium, blood vessel (BV), dense connective tissue and stereocilia (arrows) which extend from the surface of the principal cells. ×400.

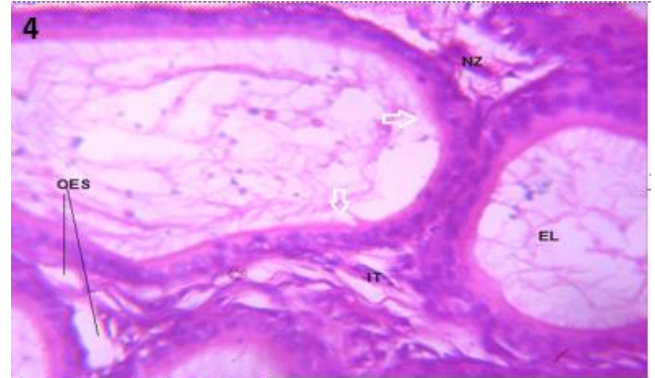


**Figure 2.** The photomicrograph of section of epididymis from the cadmium group showing several alterations such as fatty dense connective tissue, necrotized stereocilia, cellular debris (Cd), necrotized spermatozoa (Ns), necrotic blood vessel (arrow) and empty epididymal lumen. H&E, X400.

and stereocilia with the arrest of spermatozoa (Figure 2). Animals in the medium-dose group C displayed a moderate effect on the epididymal tissues, with necrosis of the spermatozoa (NZ), Pseudo stratified epithelial layer (Ps), and epididymal tubule (Et) (Figure 3). In the high dose of the extract, group D showed a moderate effect on the Epididymal tissues, with the moderate necrotic zone (NZ), interstitial tissues (IT), diffused stereocilia with an optical space (OES), and epididymal lumen (EL) (Figure 4). The result in

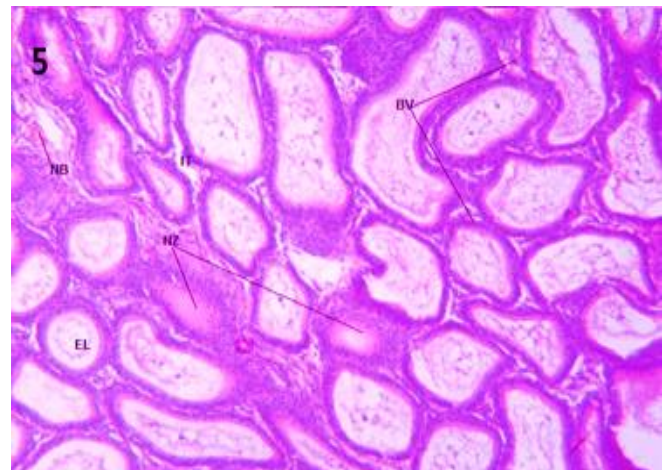


**Figure 3.** A section of the cadmium chloride + a medium dose of clove oil + DMSO group of the photomicrograph of epididymis showing interstitial tissue (It), Necrotic spermatozoa (Nz), Pseudostratified epithelial layer (Ps) and Epididymal tubule (Et), Hematoxylin and eosin, magnification  $\times 400$ .

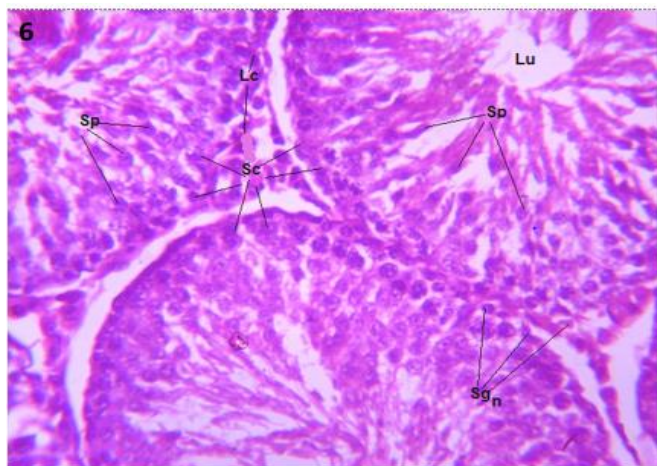


**Figure 4.** A section of the cadmium chloride + a high dose of clove oil + DMSO group of the photomicrograph of Epididymis showing Interstitial tissue (It), Necrotic zone (Nz), diffused stereocilia (arrow), Optical Empty Space (OES) and Epididymal lumen (EL). Hematoxylin and eosin  $\times 400$ .

group E showed testes with severe cellular debris (CD), inflamed tubules (IST), fatty changes, and empty optical spaces (Figure 5). The result of the histological examination of the testes of animals in the control group (A) showed normal testicular histo-architecture with seminiferous tubules that were lined with interstitial cells of Leydig cells (LC), Sertoli cells (SGN), with enhanced spermatogenesis (SG), spermatocytes (SC), and spermatids (SP) (Figure 6). The testes of animals in group B showed the distortion of the seminiferous

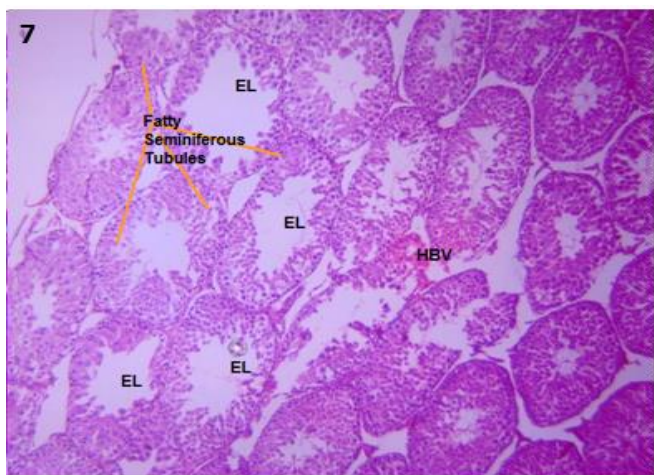


**Figure 5.** A section of the cadmium chloride + DMSO group of epididymis showing Interstitial tissue (It), Necrotic zone (Nz), Necrotized blood vessel (NB), Blood vessels (BV) and Epididymal lumen (EL), Hematoxylin and eosin magnification,  $\times 400$ .

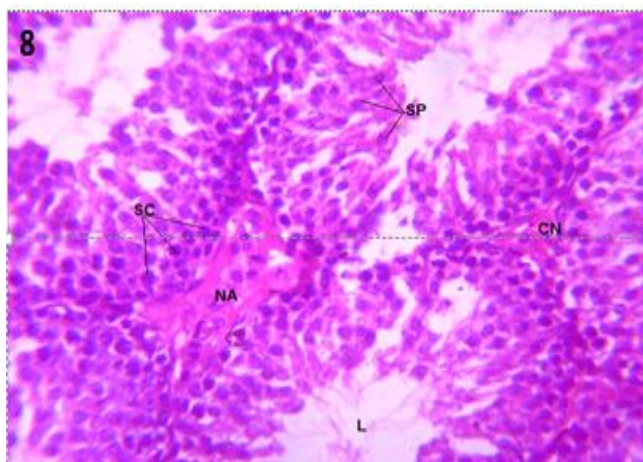


**Figure 6.** A photomicrographic section of the control group showing spermatocytes (Sc), sertoli cells (Sgn), spermatids (Sp), spermatogonia (Sg), Leydig cells (Lc), Lumen of the seminiferous tubules.  $\times 400$ .

tubules, hemorrhaged blood vessels (HBV), and empty lumen of the seminiferous tubules (Figure 7). Mild effect of the extract on the testicular tissues, revealing regenerating SC, SGN, and LC with a slight distortion of the lumen of the seminiferous tubules and moderate distortion of the SP as shown in the testes of group C animals (Figure 8). The result of the examination of the testicular tissues in group D with the high dose of the extract showed HBV, LC, IT, CD, and lumen of the seminiferous tubules (L) (Figure 9). The result from a section of

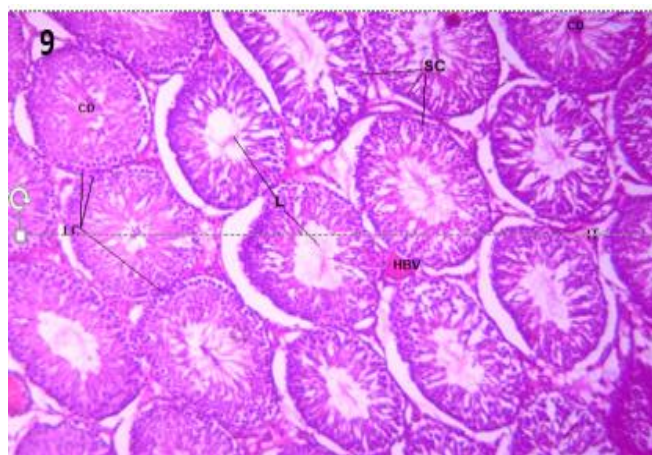


**Figure 7.** A photomicrographic plate section of the cadmium chloride showing various fatty seminiferous tubules caused by toxicity on the testes, hemorrhage blood vessel (HBV) and Empty lumen of the seminiferous tubules.  $\times 400$ .



**Figure 8.** The photomicrograph of a section of the CdCl + a medium dose of clove + DMSO group of testis revealing regenerating Spermatocytes (Sc), Sertoli cells (Sgn), Spermatids (Sp), Spermatogonia (Sg), Leydig cells (Lc) and the Lumen of the seminiferous tubules.  $\times 400$ .

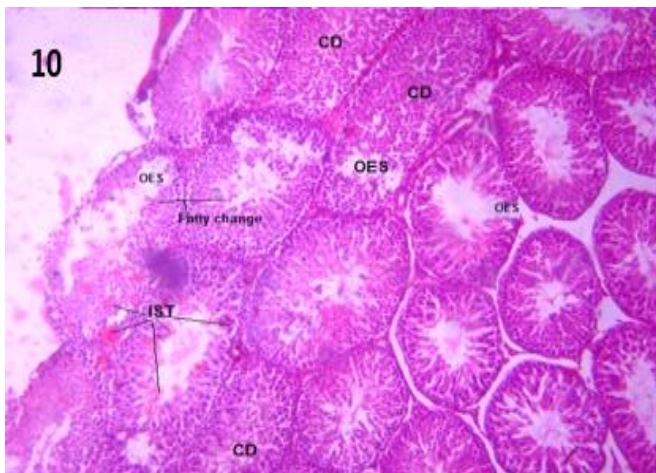group E showed a severe necrotic zone, necrotized blood vessels, and EL (Figure 10).



**Figure 9.** The photomicrograph of a section of the CdCl + a high dose of clove + DMSO group of testis revealing Sertoli cells (Sgn), Hemorrhaged blood vessel (HBV), Leydig cells (Lc), Interstitial tissue (IT), Cellular debris (CD) and the lumen of the seminiferous tubules (L).  $\times 200$ .

#### 4. Discussion

Based on reports from previous studies, CdCl showed significant oxidative properties, which caused a reduction in body weight and decreased associated sex organ weight (18-20). In the present study, animals in the Cadmium group showed a significant decrease in weight, compared to the control group. In



**Figure 10.** The photomicrograph of a section of the CdCl + DMSO group of testis revealing Cellular debris (CD) and Inflamed seminiferous tubules (IST), Fatty changes, and Optical Empty Spaces (OES),  $\times 200$ .

the control group, the sperm parameters were normal; meanwhile, there were morphological changes that were accompanied by a significant decrease in the percentage of AM of sperm in the Cadmium group, compared to the control group. Based on previous studies, due to its high toxicity and cumulative effect, CdCl could lead to multi-organ injury, especially to the genital organ by decreasing sperm motility leading to male infertility (21-22). The high dose of clove significantly increased sperm motility, suggesting that an increase in a high dose of CLO dissolved in dimethyl sulphoxide has an inverse correlation with the percentage of AM of sperm.

There was an insignificant decrease in the percentage of SM across the group, compared to the control group. In the Cadmium group, there was no decrease, suggesting an insignificant effect on the percentage of SM of sperm with the high dosage. The significant increase in the percentage of NM with the high dose of CLO, when compared to the control and Cadmium groups, suggests that a high dose of the extract (CLO) had a strong adverse effect on sperm motility, and thus, a significant increase in non-motile sperm (17). There was an increase in sperm count with the high dose of clove, compared to the Cadmium group, signifying that the high dose had an

adverse effect leading to a significant increase (17). According to Cheng *et al.* (3), a low Cadmium intake can last longer and accumulate in the body but accumulates in large amounts in the testes. Cadmium can cause male reproductive toxicity, including testicular injury leading to observable changes in sperm morphology.

Cadmium caused a decrease in FSH, LH, and testosterone concentration may be due to a decrease in LH concentration (24). Treatment with high doses of CLO elevated the concentration of this hormone, restoring it to levels related to the control group. The LH is crucial in regulating the function of the testes in men. Testosterone is the main hormone that regulates spermatogenesis in the testes and acts as a paracrine which diffuses into the testicular seminiferous tubules (5). FSH, a sex hormone, acts on Sertoli cells of the testes to stimulate sperm production, and a significant decrease in the FSH concentration in the Cadmium group could suggest impairment in spermatogenesis as a result of Sertoli cell dysfunction. Treatment with the high dose of CLO did not seem to restore the level of FSH to normal. The testes of the control group also displayed normal testicular histo-architecture with seminiferous tubules, as shown in Figure 6. The interstitial cells of Leydig function in the production of androgen and testosterone under the pulsatile control of pituitary luteinizing hormone were all affected by Cadmium (11).

Testosterone is the main hormone that regulates spermatogenesis in the testes and acts as a paracrine which diffuses into the testicular seminiferous tubules (11, 24). Figure 2, which depicts the photomicrographs of the Cadmium group, has a significant effect on the epididymal tissue, accumulation of fatty dense connective tissue, and necrosis of the blood vessel; moreover, stereocilia with the arrest of the spermatozoa can be seen, suggesting that the administration of CdCl led to this. The testicular photomicrographs with severe distortion of various parts in Figure 7, agree with Cheng *et al.* (3) that Cadmium directly affects male



fertility.

As observed in Figure 4, it showed a significant effect on the Epididymal tissue, with healing signs, while Figure 9 suggests that a high dose of the extract contributed significantly to the reduced necrosis seen in the sections. According to a previous study, the clove can elevate testosterone levels, motility of sperm, and secretory activities of the epididymis and seminal vesicle (23). It is well-known that testicular and epididymal oxidative stress induced under normal or different pathophysiological conditions leads to male infertility, illustrating the importance of Cadmium as an inducer of oxidative stress (4). DMSO, a known transport, exhibits anti-inflammatory and antioxidant properties by reducing the transcription factor NF-KB and controls the expression of immune response and apoptosis of cells, which can be seen in both sections. Hence, the arrest and necrosis of the spermatozoa, which disrupts spermatozoa production during the meiotic process, led to low testosterone levels in Figures 2 and 3 by CdCl. According to previous studies, inflammatory factors and cytokines can trigger the apoptosis of caspase cascade enzymes in germinal cells by reducing blood flow (25). Interestingly, the testosterone level was significantly justified in the group treated with the clove extract. Based on this evidence, this extract could notably improve the anti-spermatogenic effect and reduce oxidative stress induced by Cadmium through its scavenging properties.

In conclusion, a high dose of CLO increased the rate of spermatogenesis and sperm quality and restored damages inflicted by Cadmium on the histo-architecture of the testes and epididymis. It equally improved the sperm motility, count, and serum level of testosterone, as well as the histological and morphological parameters seen in regenerating qualities.

### Acknowledgment

The authors wish to appreciate Chief Nwajagu of

blessed memory, Dr. Ogugua A. Egwu, Mr. Joseph A. Nwafor, all of Anatomy Department, Alex Ekwueme Federal University Ndufu-Alike, Ebonyi state.

### Authors' Contribution

AOI, UOO, CEC, and OIA conceived the title; AOI, and UOO designed the experiments; UOO, OIA, and CEC performed experiments and collected data; UOO analyzed the data obtained; AOI, UOO, OIA, and CEC discussed the results and strategy; AOI and UOO Supervised, directed and managed the study; AOI, UOO, OIA, and CEC approved the final version to be published.

### Ethics

Ethical clearance was obtained from Alex Ekwueme Federal University Ndufu Alike Ikwo (AE-FUNAI) Ethics and Animal Welfare Committee with reference Number AEFUNAI/2020/1501 and the Norwegian National Research Ethics Committee (15), principles and practices of research were strictly followed.

### Conflict of Interest

The authors have no conflict of interest to declare.

### References

1. Yeung BH, Wan HT, Law AY, Wong CK. Endocrine disrupting chemicals: multiple effects on testicular signaling and spermatogenesis. *spermatogenesis*. 2011;1(3):231–239.
2. Diamanti-Kandarakis E, Bourguignon JP, Giudice LC. Endocrine-disrupting chemicals: an endocrine society scientific statement. *Endocrine Reviews*. 2009;30(4): 293–342.
3. Cheng CY, Wong EWP, Lie PPY. Environmental toxicants and male reproductive function. *spermatogenesis*. 2011;1(1):2–13.
4. De Souza PFM, Diamante AS, Dolder H. Testis response to low doses of cadmium in Wistar rats. *International Journal of Experimental Pathology*. 2010;91(2): 125–131.
5. Sui ER, Mruk DD, Porto CS, Cheng CY. Cadmium-induced testicular injury. *Toxicology and Applied*

- Pharmacology*. 2009;238(3):240–249.
6. Yan Cheng C, D. D. Mruk. The blood-testis barrier and its implications for male contraception. *Pharmacological Reviews*. 2011;64(1):16–64.
  7. EWP Wong, Cheng CY. Impacts of environmental toxicants on male reproductive dysfunction. *Trends in Pharmacological Sciences*. 2011;32(5):290–299.
  8. Blanco AR, Moyano JVivo. Quantitative changes in the testicular structure in mice exposed to low doses of cadmium. *Environmental Toxicology and Pharmacology*. 2007;23(1):96–101.
  9. Dubé E, Cyr DG. The blood-epididymis barrier and human male fertility. *Advances in Experimental Medicine and Biology*. 2013;763:218–236.
  10. Prozialeck WC, Edwards JR, Woods JM. The vascular endothelium is a target of cadmium toxicity. *Life Sciences*. 2006;79(16):1493–1506.
  11. Ohtani K, Yanagiba Y, Ashimori A. Influence of injection timing on the severity of cadmium-induced testicular toxicity in mice. *The Journal of Toxicological Sciences*. 2013; 38(1): 145–150.
  12. Eman T. Mohammed, Khalid S. Hashem. Ameliorative effect of lipoic acid on cadmium-induced hepatotoxicity and nephrotoxicity in rats. *Journal of Applied Science*. 2019; 19: 637-646.
  13. Raja RC, Srinivasan V, Selvaraj S, Mahapatra SK. A review of eugenol's versatile and synergistic potential. *Pharmaceutical Annals*. 2015;6(5):2153-2435.
  14. Mohammadi S, özgüneş H, Başaran N. Pharmacological and Toxicological Properties of Eugenol. *Turkish Journal of Pharmaceutical Science*. 2017;14(2):201–206.
  15. Norwegian National Research Ethics Committee. The National Committee for Research Ethics in Science and Technology, 2019.
  16. David Mortimer, Sharon T. Mortimer. Manual methods for sperm motility assessment. *Methods Mol. Biol.* 2013; 927:61-75.
  17. Ghasemzadeh A, Karkon-Shayan F, Yousefzadeh S, Naghavi-Behzad M, Hamdi K. Niger Study of pentoxifylline effects on motility and viability of spermatozoa from infertile asthenozoospermic males. *Niger Med J*. 2016;57(6):324-328.
  18. Bashandy SAEM. OE Role of zinc as an antioxidant and anti-inflammatory to relieve cadmium oxidative stress induced testicular damage in rats. *Asian Pacific Journal of Tropical Biomedicine*. 2016;6(12):1056-1064.
  19. Erboga MK. Anti-apoptotic and antioxidant effects of caffeic acid phenethyl ester on cadmium-induced testicular toxicity in rats. *Biological Trace Element Research*. 2016;171(1):176-184.
  20. Nna VU, Ujah GA, Mohammed M, Etim KB, Igba BO, Augustine ER, Osim EE. Cadmium chloride-induced testicular toxicity in male Wistar rats; prophylactic withdrawal. *Biomedicine & pharmacotherapy*. 2017;94,109-123.
  21. Loa N, Nordstrom Joensen U, Blomberg Jensen M, Jorgensen N. Regional differences and temporal trends in male reproductive health disorders. Semen quality may be a sensitive marker of environmental exposures. 2012;355(2):221-230.
  22. Zhang Y, Wang Y, Zhu X, Cao P, Wei S, Lu Y. Antibacterial and antibiofilm activities of eugenol from essential *Syzygium aromaticum* (L.) oil and clove leaf against periodontal pathogen *Porphyromonas gingivalis*. *Microbiology of Pathology*. 2017;113:396-402.
  23. Moghimian M, Abtahi-Evari SH, Shokoohi M, Amiri M, Soltani M. Effect of *Syzygium aromaticum* (clove) extracts on seminiferous tubules and oxidative stress after testicular torsion in adult rats. *Physiology and Pharmacology*. 2017;21(4):343-350.
  24. Ayo-Lawal BA, Yakubu TM. Aqueous Extract of *Aspilia Africana* CD Adams Leaves Ameliorates Cadmium Induced Testicular Perturbations in Male Wistar Rats, *Journal of Federation of American Societies for Experimental Biology*. 2018;32:658.12.
  25. Shaughnessy O, Peter J. Hormonal controls of germ cell development and spermatogenesis. *Seminars in cell and developmental Biology*. 2014;29:55-65.