



Aortic root anatomy: insights into annular and root enlargement techniques

Jama Jahanyar¹, Sameh M. Said², Laurent de Kerchove¹, Veronica Lorenz¹, Geoffroy de Beco¹, Gaby Aphram¹, Daniel E. Muñoz¹, Stefano Mastrobuoni¹, Matteo Pettinari¹, Bardia Arabkhani³, Gebrine El Khoury¹

¹Department of Cardiovascular & Thoracic Surgery, Cliniques Universitaires Saint-Luc, Université Catholique de Louvain (UCL), Brussels, Belgium; ²Division of Pediatric and Adult Congenital Cardiac Surgery, Maria Fareri Children's Hospital, Westchester Medical Center, Valhalla, NY, USA; ³Department of Cardiovascular & Thoracic Surgery, Erasmus Medical Center, Rotterdam, The Netherlands

Correspondence to: Jama Jahanyar, MD, PhD, FACS. Department of Cardiovascular & Thoracic Surgery, Cliniques Universitaires Saint-Luc, Avenue Hippocrate 10, 1200 Brussels, Belgium. Email: jjahanyar@gmail.com.

The introduction of the Y(ang)-technique for aortic root enlargement has sparked a renewed interest in annular and root enlargement procedures world-wide. In order to execute these procedures proficiently however, it's important to understand the complex three-dimensional structure of the aortic root and left ventricular outflow tract, and also be familiar with the different enlargement techniques. Herein, we are providing a description of the aortic root anatomy and the most commonly utilized root enlargement procedures. This should facilitate clinical decision making and guidance of patients towards the most appropriate procedure, which should not only treat the patients' acute symptoms, but should also set the patient up for potentially needed future procedures and respective life-time management of aortic valve disease.

Keywords: Aortic valve replacement; aortic root anatomy; aortic annular enlargement; aortic root enlargement



Submitted Mar 25, 2024. Accepted for publication Apr 24, 2024. Published online May 20, 2024.

doi: 10.21037/acs-2024-aae-25

View this article at: <https://dx.doi.org/10.21037/acs-2024-aae-25>

Introduction

Recently, a renewed interest in aortic annular and/or root enlargement has been sparked by the introduction of the Y(ang)-technique (1). This has led to the adoption of a more aggressive approach, by many surgeons throughout the world, in order to accommodate a larger prosthesis during aortic valve replacement.

The benefits of enlarging the aortic annulus and the left ventricular outflow tract (LVOT) translate into a lower risk of patient-prosthesis mismatch (PPM), lower postoperative transvalvular and LVOT gradients, and the ability to place a larger transcatheter valve (TAVR) during subsequent procedures in the future (life-time management of aortic valve disease).

The aortic root and aortic annulus are complex three-dimensional structures, that are not only difficult to understand, but there is also inconsistency in the

nomenclature, which further complicates generalization and comprehension of the anatomy. For instance, ventriculoaortic junction [(VAJ) also sometimes referred to as aorto-ventricular junction (AVJ)] is often used synonymously to aortic annulus (surgical or echocardiographic) or the virtual basal ring (VBR). These structures are not the same.

We have recently described the aortic root anatomy in detail, as it pertains to aortic valve repair and/or valve-sparing aortic root replacement (2). Thus, herein we will focus more on the aortic root anatomy, as it pertains to aortic valve replacement and annular and LVOT enlargements, where no further emphasis is placed on the function and anatomy of the aortic valve leaflets, as they are excised during the procedure.

Over the years, many annular and/or root enlargement techniques have been described (e.g., Manouguian, Nicks, Rittenhouse, Mavroudis, Konno-Rastan, Nunez, Yang, etc.)

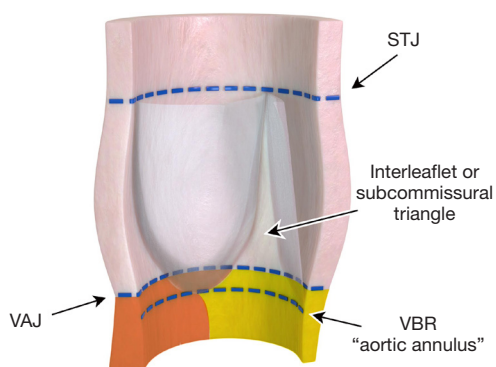


Figure 1 This figure depicts the main structures of interest in the aortic root in a simplistic form. It is important to note that there is a difference between the VAJ (often incorrectly referred to as the aortic annulus) and the VBR. The VBR is a line that connects the nadirs of all aortic valve leaflets. This line is correctly also referred to as aortic annulus, surgical annulus or echocardiographic annulus. The VAJ however, is not a consistent landmark but varies by valve phenotype and from patient to patient. The yellow area below the VBR represents the posterior LVOT (aorto-mitral fibrous body), and the red area represents the muscular portion of the LVOT (interventricular septum). STJ, sinotubular junction; VAJ, ventriculoaortic junction; VBR, virtual basal ring; LVOT, left ventricular outflow tract.

and are employed in congenital and adult contemporary surgical practices. It is important to understand, however, that these techniques target different areas of the LVOT and/or aortic root. For instance, not all techniques enlarge the LVOT and this concept is important to understand.

Aortic annulus and aortic root

Ventriculo-aortic transition

There is discrepancy between the anatomical and physiological VAJ. Specifically, the difference between the LVOT (ventricular tissue) and the beginning of the aorta (arterial tissue) (3). The anatomical junction is determined by the transition of the (I) ventricular myocardium anteriorly; and (II) fibrous tissue posteriorly (fibrous continuity of the aortic and mitral valve), to the arterial tissue of the aortic sinuses distally.

The physiological junction is determined by the attachment of the semilunar leaflets, or the semilunar hinge area of leaflet insertion. Hence, the entire area beneath valve insertion and in terms of hemodynamic pressures, is

part of the left ventricle. The area distal, is part of the aortic sinuses (3).

The VAJ, however, is not a consistent landmark. It varies by valve phenotype (e.g., bicuspid *vs.* tricuspid aortic valve) and area of the aortic root (anterior versus posterior) (2,4). Posteriorly, the VAJ is equal to the VBR (a virtual line drawn to connect the nadirs of semilunar leaflet insertions) as they overlap, but anteriorly, there is variation of the VAJ, which then leads to varying areas of the ventricular wall becoming part of the aortic sinuses of Valsalva. This is also now commonly referred to as myocardial crescents (5) or muscular inclusion (6), which we have also described in the other arterial valve, the pulmonary valve (7). We will elaborate on this topographic relationship in more detail later.

Three triangular areas of the arterial wall also are incorporated into the LVOT, due to the crown-shaped appearance of valve insertion and are commonly referred to as sub-commissural triangles. These are relatively thin areas of arterial wall that separate the inside of the left ventricle from the extracardiac space (3) (*Figure 1*).

As described above, the VAJ has only value as an anatomical landmark, but otherwise bears no clinical significance. It's simply the transition point where the left ventricular muscular and fibrous tissue is replaced by the fibroelastic walls of the aortic valve sinuses (8,9). Hence, in lieu of the VAJ we use the VBR as a surgical landmark, which is also commonly referred to as the aortic annulus (8,10), surgical annulus (2) or echocardiographic annulus (11). Therefore, this represents an important landmark during surgical procedures, surgical planning and diagnostic imaging (e.g., TAVR sizing). Moreover, this has to be distinguished from the functional aortic annulus (FAA).

The FAA

It is important to differentiate the aortic annulus from the FAA. As described above, the aortic annulus is synonymous with the VBR or the echocardiographic annulus (11). The VBR is also part of the FAA, as it forms its inferior or proximal border. As our understanding of the aortic valve improved, however, it became increasingly evident that the entire aortic root from VBR to sinotubular junction (STJ) represents the necessary support scaffold for the aortic valve (*Figure 2*). Thus, for proper aortic valve function, a healthy relationship between valve leaflets (free margin length and geometric height) and FAA dimensions (VBR, sinus of Valsalva and STJ) is crucial (2,12).

However, when describing surgical aortic annular

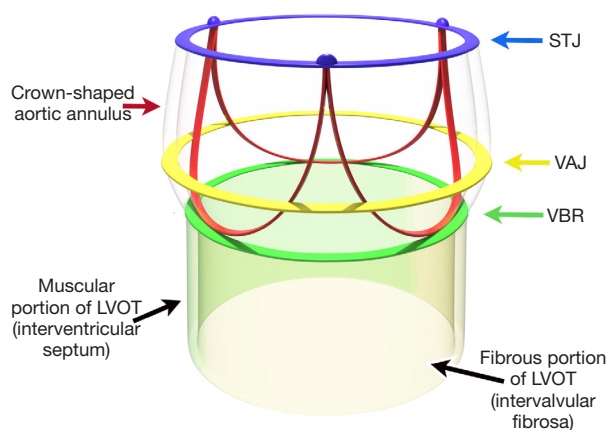


Figure 2 The FAA represents the necessary support scaffold for the aortic valve. It is the area of the aortic root between the proximal VBR and the distal STJ. The area below the VBR is the LVOT. The LVOT is made of the interventricular septum anterior and is hence muscular (green). The posterior portion is fibrous and consists of the intervalvular fibrosa (yellow). FAA, functional aortic annulus; VBR, virtual basal ring; STJ, sinotubular junction; VAJ, ventriculoaortic junction; LVOT, left ventricular outflow tract.

enlargement techniques, it's important to not mistake aortic annular enlargement with FAA enlargement. FAA enlargement can be considered synonymous with aortic root enlargement, and only when this passes the VBR as well, then we speak of an “aortic annular enlargement”, which then also enlarges the LVOT. Hence, a root enlargement in itself, does not enlarge the LVOT, but only enlarges the area above the VBR.

The crown-shaped surgical annulus

Robert Anderson has previously referred to the semilunar attachments of the valve leaflets as the “essence of the valvar complex” (9). This structure extends from the basal ring to the STJ, and thus forms a crown-shaped structure (Figure 2), which has historically been referred to as the actual surgical aortic annulus. When Sir Magdi Yacoub introduced the remodeling technique for valve-sparing aortic root replacement (Yacoub technique) (13), the three-pronged prosthetic graft was sewn to this annulus, and it was accordingly assumed that this also provided the necessary annuloplasty as the crown-shaped annulus was now supported by this prosthetic graft. This was not the case, because long-term results after root replacement with the

remodeling technique alone was suboptimal. The addition of an annuloplasty at the level of the VBR provided significantly improved long-term durability (14,15). This then raised the notion that the surgical aortic annulus is not just the crown-shaped structure in the aortic root but is actually much more complex. The concept of the crown-shaped surgical aortic annulus, however, remains perpetuated by many surgeons to this day.

We have now learned that for proper aortic valve function a healthy relationship between the aortic valve leaflets and the entirety of the FAA is critical (12,16), including the VBR. A surgical enlargement of the aortic root (and thus also of the crown-shaped annulus) cannot per se be considered an aortic annular enlargement, as it does not pass the VBR in a perpendicular fashion.

The VBR forms the proximal end of the FAA, and in his later work, Robert Anderson endorsed the VBR as the aortic annulus (8), which is the structure we measure echocardiographically for TAVR sizing for instance, or intraoperatively with a Hegar dilator. The dimension of this structure is also a critical component for the creation of a transvalvular gradient, as this structure can be an area where a bottle neck is created or remains after surgery. The VBR, however, is not a distinct anatomical structure but is rather a virtual ring formed by joining the nadirs of the aortic valve leaflet hinges, as opposed to the STJ, the superior aspect of the crown, which forms a true anatomical ring.

Nevertheless, for the purpose of this manuscript, we will only further discriminate between the FAA (aortic root from VBR to STJ), and the aortic annulus (the VBR alone) as the only two relevant structures for root or annular enlargements. The crown-shaped annulus bears no further significance in this context, as enlargement of the aortic root, by default, also entails an enlargement of the crown-shaped annulus.

The fibrous skeleton and trigones

In the aortic root, the fibrous skeleton of the heart forms the posterior wall of the LVOT. The leaflets of the aortic valve are here in direct fibrous continuity with the leaflets of the mitral valve (also called: aorto-mitral curtain, aorto-mitral continuity or aorto-mitral fibrous body). The two ends of the fibrous continuity are thickened to form the left (antero-lateral) and right (postero-medial) fibrous trigones. The right (postero-medial) fibrous trigone is continuous with the membranous part of the interventricular septum (3). The atrioventricular conduction tissue penetrates this area

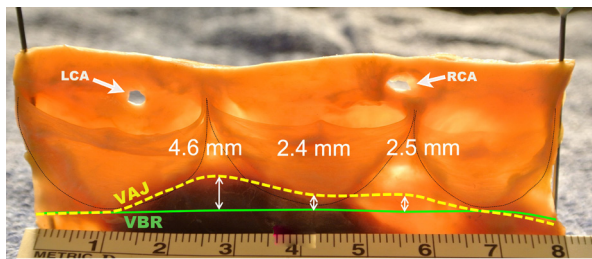


Figure 3 This anatomical representation demonstrates the difference between the VAJ and VBR. In the fibrous portion of the aortic annulus, both VAJ and VBR are superimposed. However, in the muscular portion of the LVOT there is variability of the VAJ as depicted by the white arrows between VAJ and VBR. The distance varies depending on valve phenotype and location. VAJ, ventriculoaortic junction; VBR, virtual basal ring; LVOT, left ventricular outflow tract; LCA, left coronary artery; RCA, right coronary artery.

to pass from the atrium to the ventricles and requires close attention during AVR to avoid a heart block.

The aortic root dimensions

The root dimensions are generally measured at three different levels, the VBR (proximal), the middle of the sinus of Valsalva (middle) and the STJ (distal) (*Figure 2*).

In an adult population, the average diameter of the VBR is 23.1 ± 2 mm in males, 21 ± 1.8 mm in females (17).

The average diameter of the sinus of Valsalva is 34 mm in males, 30 mm in females (upper normal limits 40 in males, 36 in females), and the average diameter at the STJ level is 29 mm in males, 26 mm in females (upper normal limits 36 in male, 32 in females). These measurements are taken with 2D-echocardiography in long axis view at end-diastole. The VBR and Sinus of Valsalva dimension correlates most closely with body surface area and the STJ (like the ascending aorta diameter) correlate most closely with age (2,18,19).

The VBR

The VBR, under normal circumstances, is oval-shaped with a short (latero-lateral) and a long (antero-posterior) diameter. In a study assessing preoperative aortic annulus dimensions the mean short diameter, measured by CT-scan, was 21 ± 2.2 mm and the long diameter was 28.2 ± 3.9 mm (20). Two-dimensional long axis view of the aortic root generally

shows the shorter VBR diameter. Three-dimensional echocardiography or CT scan are used to determine short and long diameter with better precision. The short diameter is delineated from mitro-aortic curtain on one side to the interventricular septum on the opposite side, while the long diameter extends from posterior trigone to anterior. The short/long diameter ratio is near 0.8 and increases to between 0.9 and 1 in cases of VBR dilatation (2,11).

Topographic relationship between VBR and VAJ

As briefly noted above, the VAJ is at the same level as the VBR along the fibrous portion of the circumference, corresponding to the mitro-aortic curtain (2). But along the muscular portion and the membranous septum, the VAJ stands up to half a centimeter above the VBR (*Figure 3*). The shape of the VAJ at the anterior part of the annulus is caused by the insertion of the ventricular myocardium into the basal portion of the left and the right coronary sinus. Thus, the muscular insertion at the base of these two sinuses form the so-called myocardial crescent, where the sinus tissues are thinner compared to the rest of the aortic root (3,5) (*Figure 4*). The ventricular myocardium also extends to the lower third, or even half, of the interleaflet triangle between the left and right sinus. In the area of the membranous septum, insertion of the right ventricle into the aortic wall delineates the VAJ at approximately the lower third of the right/non interleaflet triangle (21).

Moreover, the thickness of the tissues at the VAJ varies along the root circumference. Tissue thickness is relatively thin, and on average only a couple of millimeters thick along the fibrous portion and the membranous septum. However, along the interventricular septum it's thicker and reaches a maximum at the level of the right sinus. At this level, tissue thickness corresponds to the width of the myocardial crescent that is on average 6 mm (5,21) (*Figure 5*). In some patients with BAV, the myocardial crescent can reach up to 10 or 15 mm, and in rare circumstances even more (22).

Aortic annular & root enlargements

To summarize, we generally distinguish between aortic annular enlargements and aortic root enlargements. Every technique described to date enlarges the aortic root, but only techniques that cross the VBR, also enlarge the aortic annulus/LVOT.

The circumference of the aortic annulus is made of the fibrous body in-between the two trigones posteriorly, and

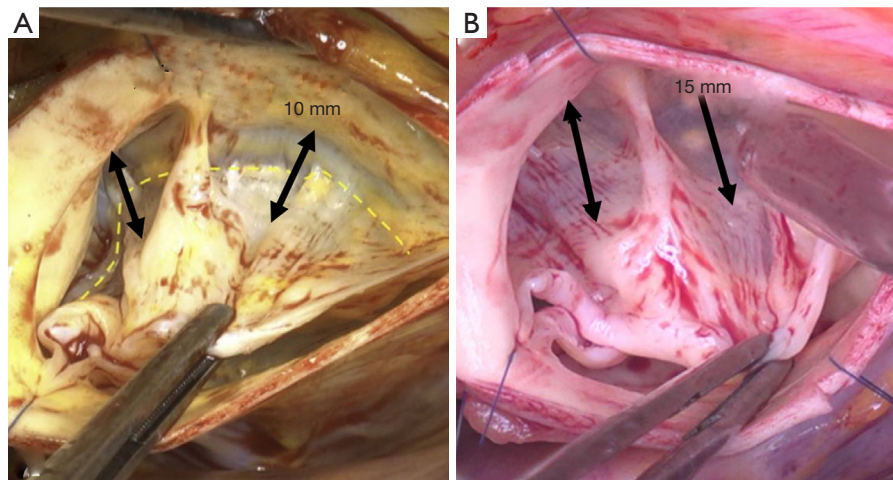


Figure 4 The intraoperative pictures of two bicuspid aortic valves (A,B), depict the myocardial crescents or muscular inclusion into the left and right coronary sinus. It represents incorporation of muscular myocardium into the sinuses of Valsalva and represent thinning of the sinuses. This can vary between valves and valve phenotypes.

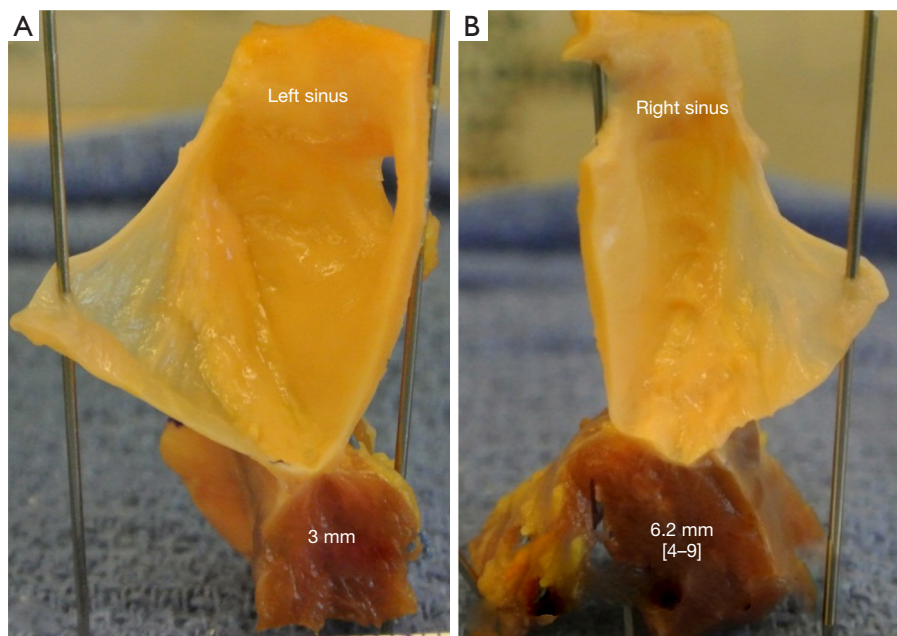


Figure 5 The thickness of the aortic annulus varies depending on the area of the LVOT. Posterior in the fibrous portion it is the thinnest, represented by the thickness of the mitro-aortic fibrous body, and is thicker in the left sinus (A) and thickest in the right sinus (B). LVOT, left ventricular outflow tract.

the interventricular muscular septum anteriorly. A small area anterior to the posteromedial trigone and in the area of the non/right commissure, the membranous septum, is generally spared during enlargement procedures. This certainly makes sense since, as noted above, the conduction

system typically runs through this area.

Thus, aortic root and annular enlargements can either incise the fibrous body or the interventricular septum; both with potential extension into adjacent structures and heart chambers (*Figure 6*). Sometimes, different techniques can

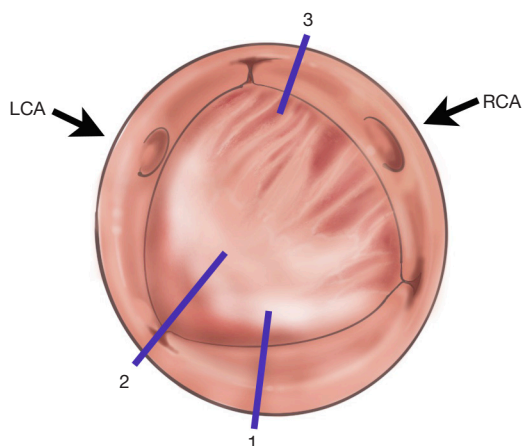


Figure 6 Depiction of the aortic annulus with areas of interest for annular and root enlargements. Incisions: 1, Nicks; 2, Manouguian; 3, Konno-Rastan. RCA, right coronary artery; LCA, left coronary artery.

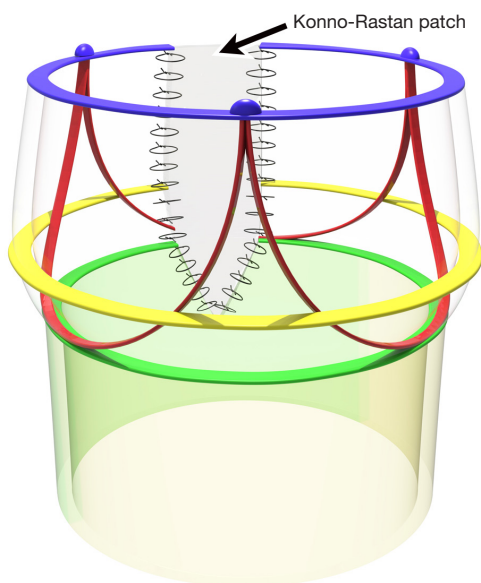


Figure 7 Konno-Rastan technique for enlargement of the anterior aortic annulus and root. This drawing does not depict the right ventricular outflow tract enlargement and patch, which is an important part of the procedure. However, the focus here is on the aortic root location in comparison to other aortic root enlargement procedures. This technique enlarges the right coronary sinus and crosses the virtual basal ring, and thus enlarges the aortic annulus through enlargement of the interventricular or muscular septum with a patch.

be combined to achieve an additive effect.

Technical aspects of aortic root enlargement procedures

Prior to performing any technique, it is critical to have adequate exposure of the LVOT. In some scenarios, this may even require complete transection of the ascending aorta. This is usually done about 1 cm above the STJ. Once the aortic valve is excised and the annulus is debrided and sized, a decision is made to tailor the required enlargement technique to the required needs of the patient. Thus, further incisions are determined accordingly.

The following are the most commonly used strategies to enlarge the aortic annulus and LVOT:

Anterior aortic annular enlargements

Konno-Rastan aortoventriculoplasty

In 1975, Konno (23) and Rastan (24) independently described an anterior annular enlargement technique, in which the aortic annulus is divided to the left of the right coronary artery ostium or at the commissure between the right and left coronary cusps (Figure 7).

This is followed by an incision in the right ventricular outflow tract and the interventricular septum, thus creating a ventricular septal defect which is further patched to enlarge the aortic annulus and LVOT.

The major advantage of this technique is the significant upsize that can be achieved for the aortic annulus and LVOT. It addresses all levels of LVOT obstruction; whether valvular, subvalvular, supravalvular or combined. However, it is more complex compared to other root enlargement techniques with slightly higher risks of heart block, and injury to the pulmonary or tricuspid valves, in addition to a risk of right ventricular outflow tract obstruction, if the prosthesis is upsized too much, or a residual ventricular level shunt can also remain.

Posterior aortic annular enlargements

Nicks

Nicks, in 1970, reported a technique for the enlargement of the hypoplastic aortic root in five patients (25) (Figure 8). He used a Dacron fabric gusset to allow for the root to accommodate a size 9A or larger Starr-Edwards prosthesis. He concluded that “no matter what type of valve is used for replacement of a diseased aortic valve, and no matter what improved designs of valvular prosthesis are ultimately developed,

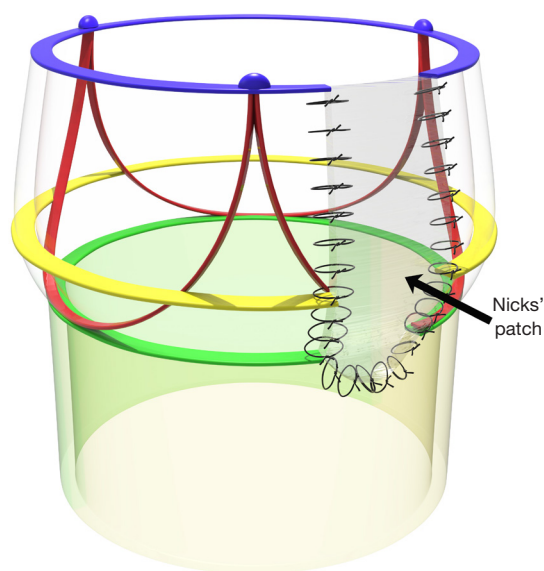


Figure 8 Nicks' technique. Incises the non-coronary sinus of the aortic root and crosses the virtual basal ring to enlarge the left ventricular outflow tract and aortic root.

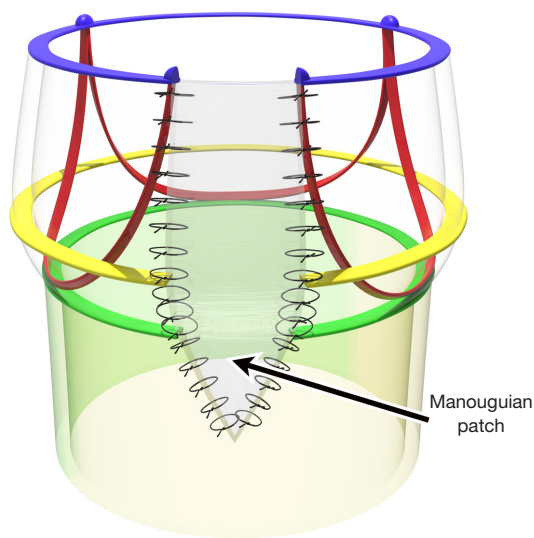


Figure 9 Manouguian technique. Incises the posterior commissure (non-left commissure) and passes the virtual basal ring to enlarge the left ventricular outflow tract and aortic root posteriorly.

it will be necessary to enlarge the aortic ring (aka aortic annulus) to accommodate a size which will function correctly without causing LVOT obstruction.” This, very likely, holds true to this day.

The principle of this technique is performing the

aortotomy in a hockey-stick fashion down to the middle of the non-coronary sinus of Valsalva of the aortic root. The incision has to cross the aortic annulus (VBR) but it doesn't extend onto the anterior leaflet of the mitral valve. Different patch materials can be used to augment the root. Originally, Nicks used a tongue of woven Dacron material, cut from a prosthetic tubular graft with its natural curvature facing the lumen. Currently, autologous, or more commonly, a bovine pericardial patch is being used.

The patch is secured to the fibrous origin of the mitral ring and then sutured to both margins of the aortotomy. The prosthesis is then secured to the aortic annulus as usual, but in the area of the patch, it is secured to the patch by interrupted sutures. It is commonly known that, with the Nicks technique, the aortic prosthesis can be upsized by one size. There can be variations of the Nicks technique, depending on the extent of the incision and the comfort level of the surgeon. If the incision isn't carried through the VBR, then this technique will only result in an aortic root enlargement without an LVOT enlargement.

Manouguian-Seybold-Epting

This is another posterior annular enlargement technique that is often confused with Nicks' and it was first described in 1979 by Manouguian and Seybold-Epting (26).

In this technique, the aortotomy incision is extended across the commissure between the left and non-coronary leaflets and onto the anterior mitral valve leaflet (Figure 9).

A diamond-shaped patch is then used to augment the aortic annulus posteriorly. The prosthesis is secured in a similar fashion as in the Nicks' procedure. It is important not to distort the mitral valve while suturing the patch. It may involve opening the roof of the left atrium as well.

It is commonly known that the valve prosthesis can be upsized by two sizes with the Manouguian technique.

Rittenhouse

Rittenhouse, in 1978, described a radical enlargement of the aortic root and outflow tract, in a fashion, similar to the Manouguian technique, which was described a year later (27).

The aortotomy is oblique and extends to the non-coronary sinus of Valsalva. Then, once the decision is made to proceed with the aortic root enlargement, the incision is extended across the aortic annulus (VBR) and downwards to the center of the mitral valve anterior leaflet, to within 5 mm of the leaflet free edge. This requires extending the incision to the roof of the left atrium for approximately 2 cm. It is important to avoid injury to the sinus nodal artery in situations where it arises from the circumflex coronary artery and courses along the superior aspect of

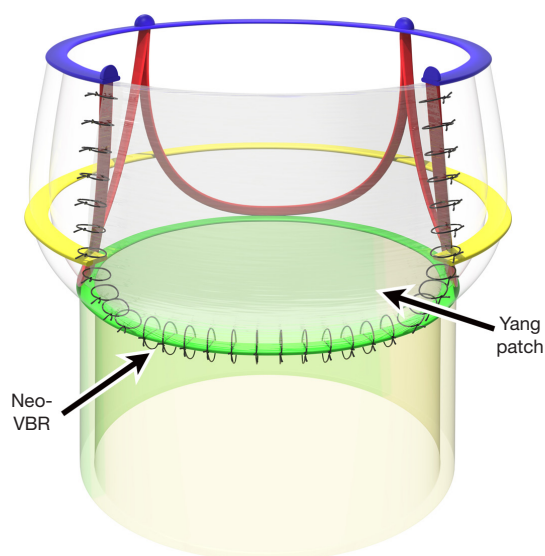


Figure 10 Yang technique. Incises the posterior commissure (non-left commissure), and at the level of the VBR it extends the incision laterally towards both trigones in an inverted Y-fashion. It does not cross the VBR and hence does not enlarge the left ventricular outflow tract but does a sizable enlargement of the aortic root or functional aortic annulus. VBR, virtual basal ring.

the left atrium to reach the sinus node. The LVOT is now wide open.

The size and configuration of the patch, are determined by measuring the width of the defect at the annulus level, and the distance from the annulus to the apex of the mitral valve incision and to the apex of the aortotomy. The apex of the patch is sutured to the apex of the mitral leaflet incision and to the annulus on both sides of the patch. At this point, it is important to determine the correct size of the patch needed to fill the defect remaining in the roof of the left atrium and suture it into place, since after the valve is replaced, exposure is severely limited.

Nuñez

Nuñez, in 1983, described a different technique in which the enlargement is done by resecting the commissure between the left and non-coronary cusps (28).

After resection of the aortic leaflets, and if the decision is made to enlarge the annulus, the adventitia of the aorta is separated from the middle layer by blunt dissection and is dissected distally beyond the posterior commissure. This easily performed maneuver separates the left atrial wall from the posterior aortic annulus, avoiding entrance into the left atrial roof. The posterior commissure is then resected. A

Dacron patch is used to close the defect, which is anchored to the fibrous base of the anterior mitral valve leaflet and the aortic wall and followed by placement of the aortic valve prosthesis.

Mavroudis

The Mavroudis technique, while not frequently used, involves incision of the aortic annulus to the left of the left/non-coronary commissure; or in other words, along the left sinus of Valsalva. It is important to note that this incision, while it enlarges the annulus posteriorly, it is very close to the left coronary ostium and care must be taken to avoid compromising the ostium during patch placement. It is a very posterior incision and hemostasis is very critical in this area to avoid issues when coming off cardiopulmonary bypass.

Combined (two-directional enlargement)

In those where the conventional posterior root enlargement technique is not sufficient to implant an adequately sized valve prosthesis, a combination of anterior and posterior enlargements can be performed (29).

The posterior enlargement is done first, followed by an additional aortotomy anteriorly, which extends to the interventricular septum. The aortic annulus could be enlarged by 68% with this technique. The aortotomy is made obliquely towards the noncoronary sinus, and the annulus is sized after removal of the aortic valve, and posterior enlargement is performed according to the Nicks or Manouguian technique. An additional anterior enlargement is then made just at the commissure, between the left and the right coronary cusps. Reconstruction of the annulus and repair of the aortotomy are carried out with a bifurcated Dacron patch.

Posterior aortic root enlargement

Yang (the Y-incision)

This technique was introduced in 2021 (1) by Yang, and it involves making an incision through the posterior commissure between the left and non-coronary cusps and into the aorto-mitral curtain. In its original description, the perpendicular incision into the posterior commissure ends at the level of the VBR, which corresponds with the level of the leaflet nadirs, and is then extended in an inverted Y-fashion along the VBR and towards both trigones, undermining the left and non-coronary cusps.

A rectangular patch is then used to repair the resultant defect (*Figure 10*). It is important to understand that this technique enlarges the fibrous part of the aortic root, however, it does not enlarge the LVOT. While this

allows for placement of a much larger valve prosthesis, it is nevertheless a supra-annular placement. With this technique, one can most likely achieve the greatest enlargement of the aortic root, not achieved by other techniques, even if a combined approach is utilized (posterior & anterior). And it allows for concomitant procedures, such a mitral valve repair or replacement as it does not cut below the level of the VBR or across the anterior mitral valve annulus, thus also minimizing the risk for mitral valve dysfunction.

Although Yang originally described the rectangular patch being sewn to the anterior mitral annulus, the initial perpendicular incision is not carried down to this level. It is therefore the author's understanding that the VBR remains unaltered, and that the lower edge of patch effectively becomes the new basal ring of the posterior aspect of the aortic annulus (*Figure 10*).

The technique was further modified later to avoid the issues created by enlargement of the aortic root and size discrepancy to the ascending aorta. The new "roof technique" is done by patch augmentation of the ascending aorta above the previously described rectangular patch. It allows for the straightening out of any kinks between the native ascending aorta and the newly enlarged root (30).

The Yang technique has the advantage of avoiding the mitral valve, with likely less mitral regurgitation risk compared to the Nicks and Manouguian technique. It is also advantageous during concomitant mitral valve surgery, as it stays above the level of the anterior mitral valve annulus. It also appears to be an easily reproducible technique. However, a thorough understanding of root anatomy is required. The width of the patch is equivalent to the length of the incision along the VBR and is hence limited by the distance between the two trigones. Although, it was suggested by Yang to slightly oversize the patch. Hence, the degree of root enlargement can never be more than the intertrigonal distance, which nevertheless should mostly be more than enough for an adequately-sized prosthetic valve.

Discussion

The aortic root is a complex three-dimensional structure, which is difficult to understand since it is made up of different components with further variations thereof; and to make things worse, with an inconsistency of the aortic root nomenclature. Nonetheless, proper aortic valve function heavily depends on proper function and relationship of all

of its components (2).

For aortic root enlargements in patients with small LVOTs and aortic roots however, it's important to have a detailed understanding of the aortic root anatomy and to be familiar with all the different root enlargement techniques. With this knowledge, an individualized surgical treatment plan can be tailored upon the patient's needs and individual anatomy.

Herein, we have provided an overview of the most commonly employed annular and root enlargement techniques and have attempted to reconcile the often-confusing aortic root anatomy.

Although there has been an increased interest in aortic root enlargements in recent years, which is likely also driven by the increased utilization of TAVR valves (larger prosthetic valves allow for TAVR placement later), not every surgeon approaches this problem equally. The Yang technique is a reproducible technique, which allows for placement of a much larger prosthesis. One has to be mindful that it does not enlarge the LVOT (31). Hence, in very small LVOTs, a bottle neck will still remain below the prosthetic valve ["lemon on a stick" (31)]. But it allows for placement of a larger valve, since a size 19 prosthetic valve in a 19 mm aortic annulus for instance, has a much smaller inner diameter and will further narrow an already small LVOT. The Yang technique allows for supra-annular placement of a larger valve, where the inner diameter of the prosthesis will match the true diameter of the LVOT ["crown on a head" (32)]. In the authors' opinion, implanting valves, where the inner diameter exceeds the true diameter of the LVOT, has little utility, however. It could even complicate future TAVR placement, since an artificial shelf can be created below the level of the prosthetic valve potentially rendering future TAVR deployment challenging. A recently published experience after the Yang technique demonstrated that redo-surgeries can be quite complex and require extensive root remodeling later on (33).

Alternatively, some aortic surgeons prefer to replace the aortic root in lieu of an annular or root enlargement technique, especially in younger patients. With this, a supra-annular replacement of the aortic root allows for placement of a larger valve, by means of a composite root and valve replacement with a homograft, freestyle graft, etc. or even the Ross/Ross-Konno operation. These techniques avoid manipulation of the LVOT with potential complications, related to its invasive nature. For instance, the Manouguian or Nicks technique can compromise the mitral valve, and anterior annular enlargements such as the Konno-Rastan technique carries other risks, mentioned earlier in the text.

We overall perform root enlargements very selectively. At our center, there has been a gradual shift towards a running suture technique for aortic valve replacements. This avoids obstructing pledgets in the LVOT and the purse-string effect of pledgetted horizontal mattress sutures. With this, we have achieved better hemodynamics with reduced transvalvular gradients, especially in smaller aortic annular sizes (34). Another helpful technique is to incise the non-coronary sinus down towards the aortic annulus, to better expose the aortic valve (this, in a sense, could be considered a modified Nicks procedure). We later close this with a pericardial patch since we generally employ a circumferential aortotomy rather than a hockey-stick incision. And this also enlarges the aortic root when needed.

Summary

There is an abundance of aortic root enlargement techniques. All techniques enlarge the aortic root, but not all techniques enlarge the LVOT. It is important to understand this concept, in order to tailor the surgical approach to the needs of the individual patient. We should therefore avoid a “one technique fits all patients” approach. Every cardiac surgeon should have a comprehensive understanding of the aortic root and be familiar with all enlargement options and guide the patient in decision-making and preparation for potentially required future interventions.

Acknowledgments

Funding: None.

Footnote

Conflicts of Interest: S.M.S. is a Consultant for Abbott, Artivion and JOMDD. The other authors have no conflicts of interest to declare.

Open Access Statement: This is an Open Access article distributed in accordance with the Creative Commons Attribution-NonCommercial-NoDerivs 4.0 International License (CC BY-NC-ND 4.0), which permits the non-commercial replication and distribution of the article with the strict proviso that no changes or edits are made and the original work is properly cited (including links to both the formal publication through the relevant DOI and the license). See: <https://creativecommons.org/licenses/by-nc-nd/4.0/>.

References

1. Yang B. A novel simple technique to enlarge the aortic annulus by two valve sizes. *JTCVS Tech* 2021;5:13-6.
2. Jahanyar J, Tsai PI, Arabkhani B, et al. Functional and pathomorphological anatomy of the aortic valve and root for aortic valve sparing surgery in tricuspid and bicuspid aortic valves. *Ann Cardiothorac Surg* 2023;12:179-93.
3. Anderson RH, Devine WA, Ho SY, et al. The myth of the aortic annulus: the anatomy of the subaortic outflow tract. *Ann Thorac Surg* 1991;52:640-6.
4. Jahanyar J, El Khoury G, de Kerchove L. Commissural geometry and cusp fusion insights to guide bicuspid aortic valve repair. *JTCVS Tech* 2021;7:83-92.
5. Toh H, Mori S, Tretter JT, et al. Living Anatomy of the Ventricular Myocardial Crescents Supporting the Coronary Aortic Sinuses. *Semin Thorac Cardiovasc Surg* 2020;32:230-41.
6. de Kerchove L, Jashari R, Boodhwani M, et al. Surgical anatomy of the aortic root: implication for valve-sparing reimplantation and aortic valve annuloplasty. *J Thorac Cardiovasc Surg* 2015;149:425-33.
7. Jahanyar J, Navarra E, de Kerchove L, et al. Pulmonary Autograft Sinus Muscular Inclusion: A Relative Contraindication for Ross Procedure. *Ann Thorac Surg* 2022;113:e161.
8. Anderson RH. Defining the enigmatic annulus of the aortic valve. *Eur J Cardiothorac Surg* 2016;49:101-2.
9. Anderson RH. The surgical anatomy of the aortic root. *Multimed Man Cardiothorac Surg* 2007;2007:mmcts.2006.002527.
10. Contino M, Mangini A, Lemma MG, et al. A geometric approach to aortic root surgical anatomy. *Eur J Cardiothorac Surg* 2016;49:93-100.
11. Lemaire G, Vancraeynest D. Echocardiography of the aortic root: a practical approach for aortic valve-sparing surgery. *Ann Cardiothorac Surg* 2023;12:194-212.
12. El Khoury G, Glineur D, Rubay J, et al. Functional classification of aortic root/valve abnormalities and their correlation with etiologies and surgical procedures. *Curr Opin Cardiol* 2005;20:115-21.
13. Sarsam MA, Yacoub M. Remodeling of the aortic valve annulus. *J Thorac Cardiovasc Surg* 1993;105:435-8.
14. Schneider U, Hofmann C, Aicher D, et al. Suture Annuloplasty Significantly Improves the Durability of Bicuspid Aortic Valve Repair. *Ann Thorac Surg* 2017;103:504-10.
15. Schneider U, Aicher D, Miura Y, et al. Suture

- Annuloplasty in Aortic Valve Repair. *Ann Thorac Surg* 2016;101:783-5.
16. Boodhwani M, de Kerchove L, Glineur D, et al. Repair-oriented classification of aortic insufficiency: impact on surgical techniques and clinical outcomes. *J Thorac Cardiovasc Surg* 2009;137:286-94.
 17. Capps SB, Elkins RC, Fronk DM. Body surface area as a predictor of aortic and pulmonary valve diameter. *J Thorac Cardiovasc Surg* 2000;119:975-82.
 18. Roman MJ, Devereux RB, Kramer-Fox R, et al. Two-dimensional echocardiographic aortic root dimensions in normal children and adults. *Am J Cardiol* 1989;64:507-12.
 19. Bierbach BO, Aicher D, Issa OA, et al. Aortic root and cusp configuration determine aortic valve function. *Eur J Cardiothorac Surg* 2010;38:400-6.
 20. Dashkevich A, Blanke P, Siepe M, et al. Preoperative assessment of aortic annulus dimensions: comparison of noninvasive and intraoperative measurement. *Ann Thorac Surg* 2011;91:709-14.
 21. de Kerchove L, Jashari R, Boodhwani M, et al. Surgical anatomy of the aortic root: implication for valve-sparing reimplantation and aortic valve annuloplasty. *J Thorac Cardiovasc Surg* 2015;149:425-33.
 22. de Kerchove L, Mastrobuoni S, Froede L, et al. Variability of repairable bicuspid aortic valve phenotypes: towards an anatomical and repair-oriented classification. *Eur J Cardiothorac Surg* 2019;ezz033.
 23. Konno S, Imai Y, Iida Y, et al. A new method for prosthetic valve replacement in congenital aortic stenosis associated with hypoplasia of the aortic valve ring. *J Thorac Cardiovasc Surg* 1975;70:909-17.
 24. Rastan H, Koncz J. Aortoventriculoplasty: a new technique for the treatment of left ventricular outflow tract obstruction. *J Thorac Cardiovasc Surg* 1976;71:920-7.
 25. Nicks R, Cartmill T, Bernstein L. Hypoplasia of the aortic root. The problem of aortic valve replacement. *Thorax* 1970;25:339-46.
 26. Manouguian S, Seybold-Epting W. Patch enlargement of the aortic valve ring by extending the aortic incision into the anterior mitral leaflet. New operative technique. *J Thorac Cardiovasc Surg* 1979;78:402-12.
 27. Rittenhouse EA, Sauvage LR, Stamm SJ, et al. Radical enlargement of the aortic root and outflow tract to allow valve replacement. *Ann Thorac Surg* 1979;27:367-73.
 28. Nuñez L, Aguado MG, Pinto AG, et al. Enlargement of the aortic annulus by resecting the commissure between the left and noncoronary cusps. *Tex Heart Inst J* 1983;10:301-3.
 29. Otaki M, Oku H, Nakamoto S, et al. Two-directional aortic annular enlargement for aortic valve replacement in the small aortic annulus. *Ann Thorac Surg* 1997;63:261-3.
 30. Yang B, Naeem A, Palmer S. "Roof" technique—a modified aortotomy closure in Y-incision aortic root enlargement upsizing 3-4 valve sizes. *JTCVS Tech* 2022;12:33-6.
 31. Said SM, Jahanyar J. Yang technique for aortic annular enlargement and the "lemon on a stick". *JTCVS Tech* 2022;16:21.
 32. Yang B, Burris NS, Prasch P. Reply from authors: Not lemon on a stick, but crown (valve) on a head (left ventricular outflow tract). *JTCVS Tech* 2022;16:22-4.
 33. Spindel SM, Du RE, Jiang KJ, et al. Reoperating on the Y-incision root enlargement: Deconstruction and reconstruction. *JTCVS Techniques* 2024;24:23-6.
 34. Arabkhani B, Gonthier S, Lorenz V, et al. Continuous or interrupted pledgeted suture technique in stented bioprosthetic aortic valve replacement: a comparison of in-hospital outcomes. *J Cardiothorac Surg* 2024;19:174.

Cite this article as: Jahanyar J, Said SM, de Kerchove L, Lorenz V, de Beco G, Aphram G, Muñoz DE, Mastrobuoni S, Pettinari M, Arabkhani B, El Khoury G. Aortic root anatomy: insights into annular and root enlargement techniques. *Ann Cardiothorac Surg* 2024;13(3):244-254. doi: 10.21037/acs-2024-aae-25