



RECURRENT INFECTIVE ENDOCARDITIS OF THE MITRAL VALVE AFTER ORTHOTOPIC HEART TRANSPLANTATION

Peter Snopek^{1,2}, Jozef Hasilla^{1,2}, Lukáš Patrovič³, Dominik Juskanič³, Jakub Benko^{1,4}, Martin Jozef Péc⁴, Matej Samoš^{4,5,6}

¹ Department of Cardiology, Faculty Hospital, Nitra, Slovakia

² Faculty of Social Sciences and Health, University of Constantin Philosopher, Nitra, Slovakia

³ Jessenius Diagnostic Centre, Nitra, Slovakia

⁴ Department of Internal Medicine I, Jessenius Faculty of Medicine at Comenius University, Martin, Slovakia

⁵ Department of Acute and Interventional Cardiology, Mid-Slovakian Institute of Heart and Vessel Diseases (SÚSCCH), Banská Bystrica, Slovakia

⁶ Department of Cardiology, Faculty Hospital, Trenčín, Slovakia

Corresponding author: Jakub Benko **e-mail:** benko36@uniba.sk

Received: 01/04/2024 **Accepted:** 02/04/2024 **Published:** 22/04/2024

Conflicts of Interests: The Authors declare that there are no competing interests.

Patient Consent: The patient gave written informed consent to process the healthcare data and publish a case report regarding his disease.

Acknowledgements: We kindly thank the microbiological and pharmacological teams of the Faculty Hospital in Nitra for their constant and passionate help with the treatment of severe infectious diseases, such as the one described.

This article is licensed under a Commons Attribution Non-Commercial 4.0 License

How to cite this article: Snopek P, Hasilla J, Patrovič L, Juskanič D, Benko J, Péc MJ, Samoš M. Recurrent infective endocarditis of the mitral valve after orthotopic heart transplantation. *EJCRIM* 2024;11:doi:10.12890/2024_004528

ABSTRACT

Introduction: Orthotopic heart transplantation is the gold standard for the treatment of advanced heart failure in the absence of contraindications. Infective endocarditis is a rare complication in patients after heart transplantation. The treatment of endocarditis after heart transplantation is challenging since there is a need for ongoing immunosuppression.

Case description: We present the case of a 51-year-old orthotopic heart transplant recipient enrolled in a chronic dialysis program, in whom we diagnosed and successfully treated recurrent infective endocarditis of the mitral valve caused by *Enterococcus* and *Enterobacter* species. Despite the complicated course of the disease, the treatment was successful.

Conclusions: Recurrent infective endocarditis after heart transplantation can be treated successfully with a multidisciplinary approach and robust antimicrobial therapy.

KEYWORDS

Immunosuppression, haemodialysis, antibiotics, bacteraemia, catheter sepsis

LEARNING POINTS

- There is a high risk of bacteraemia and subsequent endocarditis in patients with recurrent catheter-related sepsis.
- The spectrum of bacteria causing endocarditis in patients after heart transplantation differs from that in the general population.
- Scrupulous targeted antibiotic treatment is warranted for the treatment of immunosuppressed patients with endocarditis.



INTRODUCTION

Infective endocarditis after heart transplantation is a rare complication. In registries, the average time that endocarditis develops after transplantation is 8.4 months^[1]. The mitral valve is most frequently affected, and *Staphylococcus aureus* is the most common pathogen causing endocarditis. The second most common pathogen is *Aspergillus fumigatus*, followed by *Enterococcus faecalis*. The prevalence of viridans Streptococci is substantially lower^[2].

CASE DESCRIPTION

The patient was a 51-year-old male orthotopic heart transplant recipient enrolled in a chronic dialysis program, in whom we diagnosed and successfully treated a recurrent infective endocarditis of the mitral valve. The patient underwent orthotopic heart transplantation in 2012 for ischemic cardiomyopathy. The post-transplant period was complicated by repeated graft rejections which were treated successfully with preserved graft function. The patient was included in a chronic haemodialysis program five years later due to worsening chronic kidney disease caused by vascular nephropathy and calcineurin toxicity. Repeated attempts to establish a functional arteriovenous fistula were unsuccessful, and the patient had a permanent dialysis catheter inserted. He overcame repeated catheter-related infections and needed three catheter replacements over four years. Another episode prompted an echocardiographic examination, which revealed a 13 × 9 mm fluttering vegetation on the anterior leaflet of the mitral valve with severe mitral regurgitation (Fig. 1). We treated the patient with a combination of vancomycin and gentamycin. *Enterococcus faecalis* was detected in blood cultures. As it was resistant to gentamycin, we switched the patient to piperacillin-tazobactam. The course of the disease was complicated by an embolism to the splenic artery (Fig. 2), which presented itself with sharp pain in the left hypochondrium. After a four-week course of antibiotic therapy, the vegetation on the mitral valve was

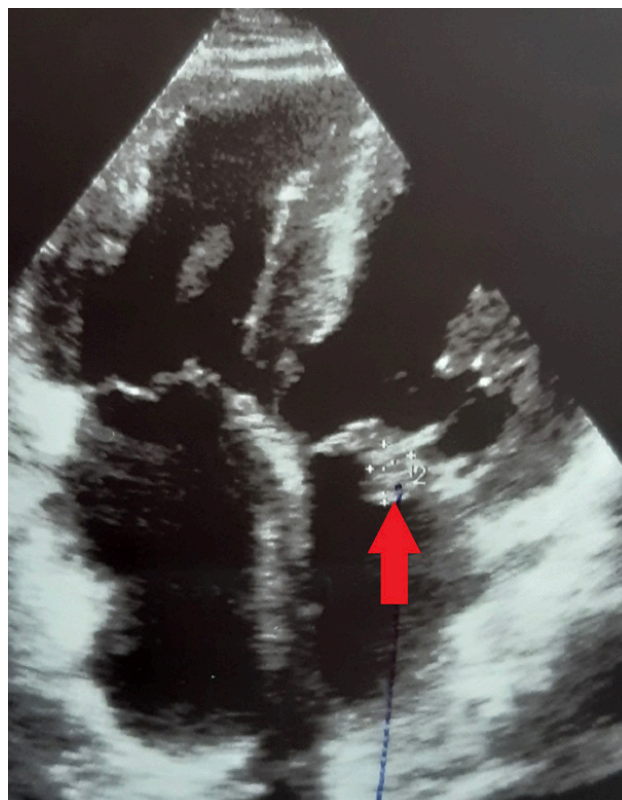


Figure 1. Apical four-chamber view showing a vegetation on the anterior leaflet of the mitral valve.

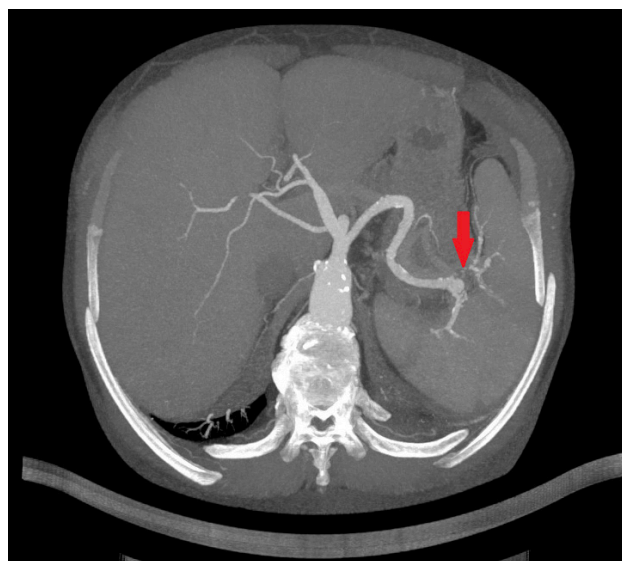


Figure 2. Transversal plane of a CT angiography of the aorta showing a septic embolization of the spleen.

April 2012	Orthotopic heart transplantation
2012-2013	Repeated transplant rejections
August 2017	Start of dialysis treatment
2018-2021	Repeated catheter-associated sepsis
May 2022	Endocarditis of the anterior leaflet of the mitral valve
June 2022	Embolization to the splenic artery
October 2022	Endocarditis of the posterior leaflet of the mitral valve
November 2022	Replacement of the dialysis catheter and AV fistula creation

Abbreviations: AV, arteriovenous

Table 1. The timeline of the case report.

not recognizable on echocardiography. The extraction of the dialysis catheter was carefully considered but the catheter was left in place as it did not show signs of inflammation. The patient had absolved more catheter exchanges before, and sparing of venous accesses was another reason. After four months, the patient was readmitted for fever and suspected endocarditis. A transthoracic echocardiography showed no signs of endocarditis. However, a transoesophageal examination found a vegetation on the posterior leaflet of the mitral valve (Fig. 3A and B). Again, we started an empirical treatment with vancomycin and gentamycin. Enterobacter

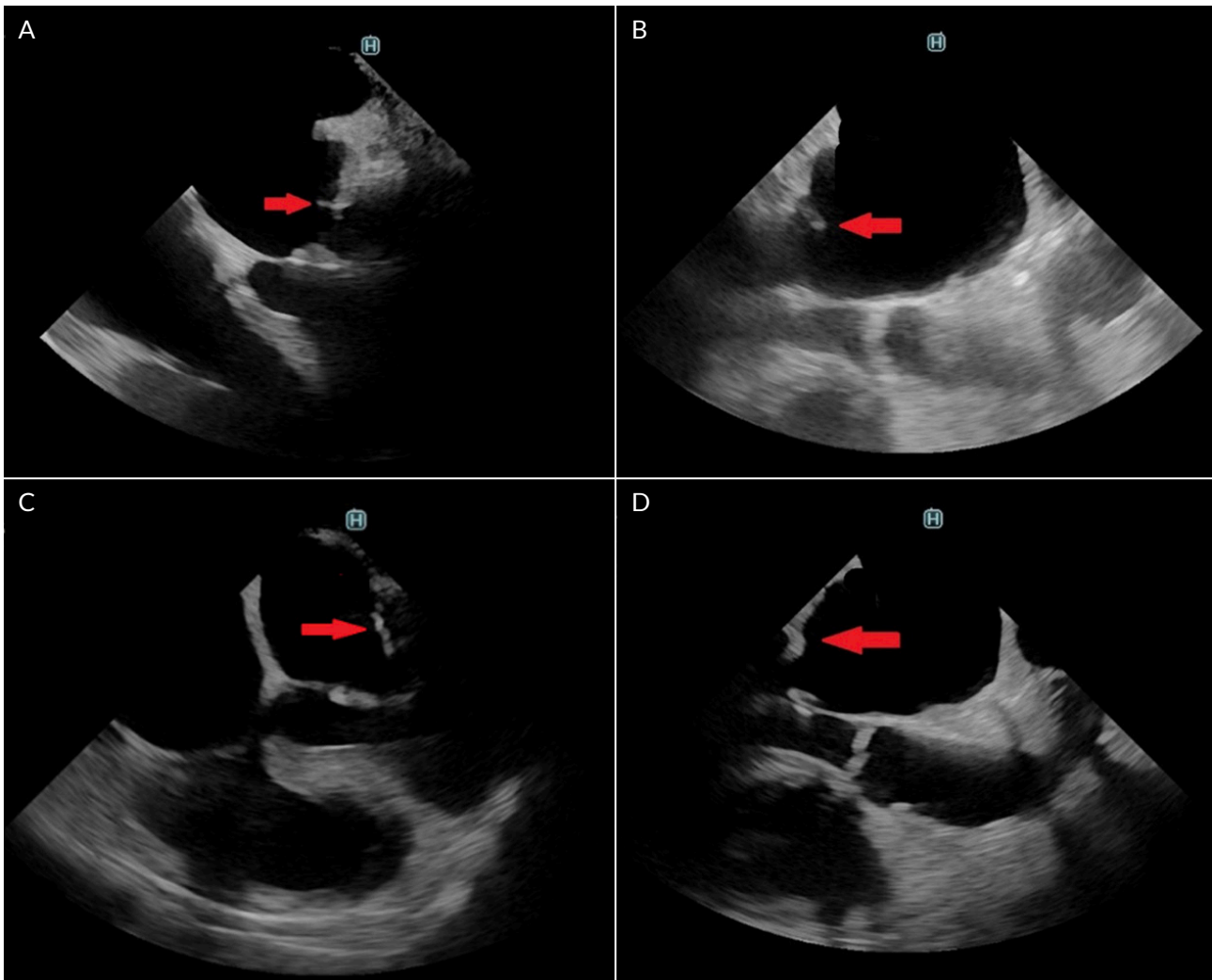


Figure 3. Transoesophageal echocardiography. A) a vegetation of the posterior leaflet of the mitral valve; B) long axis view of the left ventricle showing a vegetation of the posterior leaflet of the mitral valve; C) four-chamber view with no vegetation of posterior leaflet of the mitral valve after treatment; D) long-axis view of the left ventricle with no vegetation of posterior leaflet of the mitral valve after treatment.

cloacae was identified as the cause of infection. Antibiotic therapy was switched from vancomycin to ceftazidime with good results. The rest of the patient's hospital stay was uneventful. The dialysis catheter was replaced. Also, an arteriovenous fistula was successfully constructed. Transoesophageal echocardiography found no signs of valve vegetation (Fig. 3C and D), and the patient was discharged home. During the following months, the patient stayed in good health without any recurrence of endocarditis.

DISCUSSION

Chronic haemodialysis is recognized as a risk factor for developing infectious complications, including infective endocarditis. The incidence is 50 – 60 times higher in dialysis patients than non-dialysis patients and is higher in patients dialyzed through a catheter than through an arteriovenous fistula^[3]. The finding of *E. faecalis* in the first episode of the endocarditis is in concordance with the literature, as was mentioned in the introduction. *E. cloacae* is a very rare aetiology of endocarditis. A recent systematic review identified 20 cases of endocarditis caused by this agent. The mitral valve was the most frequently affected^[4]. A report of a

similar case described *Enterobacter* a patient with a chronic dialysis catheter left on site after an episode of previous bacteraemia who developed *Enterobacter* endocarditis^[5]. In our opinion, in our patient a combination of more risk factors, such as immunosuppression, repeated bacteraemia, and underlying heart disease, led to recurrent endocarditis caused by more sporadic microbial agents.

REFERENCES

- Martínez-Sellés M, Tattevin P, Valerio-Minero M, de Alarcón A, Fariñas MC, Mirabet-Pérez S, et al. Infective endocarditis in patients with heart transplantation. *Int J Cardiol* 2021;**328**:158-162.
- Jordan AM, Tatum R, Ahmad D, Patel SV, Maynes EJ, Weber MP, et al. Infective endocarditis following heart transplantation: A systematic review. *Transplant Rev* 2022;**36**:100672.
- Pericàs JM, Llopis J, Jiménez-Exposito MJ, Kourany WM, Almirante B, Carosi G, et al. Infective Endocarditis in Patients on Chronic Hemodialysis. *J Am Coll Cardiol* 2021;**77**:1629-1640.
- Ioannou P, Vamvoukaki R, Kofteridis DP. Infective endocarditis by *Enterobacter cloacae*: a systematic review and meta-analysis. *J Chemother* 2022;**34**:1-8.
- Karasaşin O, Yildiz Z, Unal O, Arslan U. A rare cause of healthcare-associated infective endocarditis: *Enterobacter cloacae*. *IDCases* 2018;**12**:18-20.