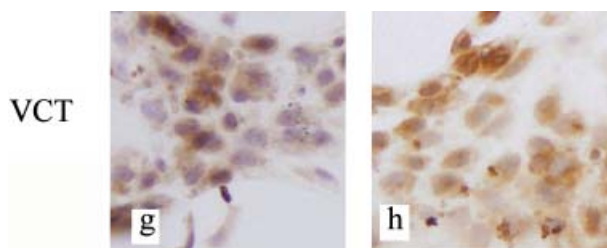


Corrections

The authors would like to draw the reader's attention to errors in the following articles:

1.
Hu W, Zhen X, Xiong B, *et al.* CXCR6 is expressed in human prostate cancer in vivo and is involved in the in vitro invasion of PC3 and LNCap cells. *Cancer Science* 2008; **99**: 1362–69.

On page 1365, Fig. 5g and 5h were incorrect. This is the correct figure:



2.
Bai Y, Kakudo K, Li Y, *et al.* Subclassification of non-solid-type papillary thyroid carcinoma identification of high-risk group in common type. *Cancer Science* 2008; **99**: 1908–15.

On page 1908, right column, line 14, the following sentence was published incorrectly:

Our low-grade malignant tumors were defined by pure histological characteristics of an invasive growth pattern and having two characteristic histological patterns, namely, loss of cellular cohesiveness and cellular polarity.

The sentence should read:

Our high-grade malignant tumors were defined by pure histological characteristics of non-invasive growth and lacking two characteristic histological patterns, namely, loss of cellular cohesiveness and cellular polarity.

The authors apologize for these errors and any confusion it may have caused.