

*ABC of oral health***Mouth ulcers and other causes of orofacial soreness and pain**

Crispian Scully, Rosemary Shotts

**Ulcerative conditions**

Mouth ulcers are common and are usually due to trauma such as from ill fitting dentures, fractured teeth, or fillings. However, patients with an ulcer of over three weeks' duration should be referred for biopsy or other investigations to exclude malignancy (see previous article) or other serious conditions such as chronic infections.

Ulcers related to trauma usually resolve in about a week after removal of the cause and use of benzydamine hydrochloride 0.15% mouthwash or spray (Difflam) to provide symptomatic relief and chlorhexidine 0.2% aqueous mouthwash to maintain good oral hygiene.

● **Patients with a mouth ulcer lasting over three weeks should be referred for biopsy or other investigations to exclude malignancy or other serious conditions**

**Recurrent aphthous stomatitis (aphthae, canker sores)**

Recurrent aphthous stomatitis typically starts in childhood or adolescence with recurrent small, round, or ovoid ulcers with circumscribed margins, erythematous haloes, and yellow or grey floors. It affects at least 20% of the population, and its natural course is one of eventual remission. There are three main clinical types:

- Minor aphthous ulcers (80% of all aphthae) are less than 5 mm in diameter and heal in 7-14 days
- Major aphthous ulcers are large ulcers that heal slowly over weeks or months with scarring
- Herpetiform ulcers are multiple pinpoint ulcers that heal within about a month.

Some cases have a familial and genetic basis, but most patients seem to be otherwise well. However, a minority have aetiological factors that can be identified, including stress, trauma, stopping smoking, menstruation, and food allergy.

Aphthae are also seen in haematinic deficiency (iron, folate, or vitamin B-12); coeliac disease; Crohn's disease; HIV infection, neutropenia, and other immunodeficiencies; Neumann's bipolar aphthosis, where genital ulcers may also be present; and Behcet's syndrome, where there may be genital, cutaneous, ocular, and other lesions. The mouth ulcers in Behcet's syndrome are often major aphthae with frequent episodes and long duration to healing.

In children aphthae also occur in periodic fever, aphthous stomatitis, pharyngitis, and cervical adenitis syndrome. This syndrome resolves spontaneously, and long term sequelae are rare. Corticosteroids are highly effective symptomatically; tonsillectomy and cimetidine treatment have been effective in some patients.

Diagnosis of aphthae is based on the patient's history and clinical features since specific tests are unavailable. A full blood picture (haemoglobin concentration, white cell count and differential, and red cell indices), iron studies, and possibly red cell folate and serum vitamin B-12 measurements and other investigations may help exclude systemic disorders, which should be suspected if there are features suggestive of a systemic background. Biopsy is rarely indicated.

**Main systemic and iatrogenic causes of oral ulcers****Microbial disease**

- Herpetic stomatitis
- Chickenpox
- Herpes zoster
- Hand, foot, and mouth disease
- Herpangina
- Infectious mononucleosis
- HIV infection
- Acute necrotising gingivitis
- Tuberculosis
- Syphilis
- Fungal infections

**Cutaneous disease**

- Lichen planus
- Pemphigus
- Pemphigoid
- Erythema multiforme
- Dermatitis herpetiformis
- Linear IgA disease
- Epidermolysis bullosa
- Chronic ulcerative stomatitis
- Other dermatoses

**Malignant neoplasms****Blood disorders**

- Anaemia
- Leukaemia
- Neutropenia
- Other white cell dyscrasias

**Gastrointestinal disease**

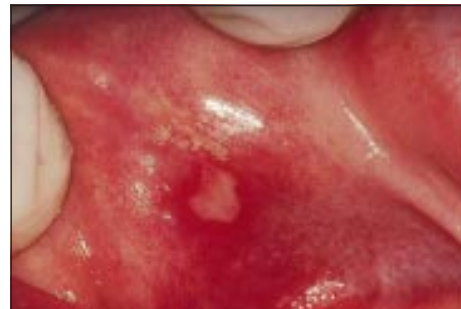- Coeliac disease
- Crohn's disease
- Ulcerative colitis

**Rheumatoid diseases**

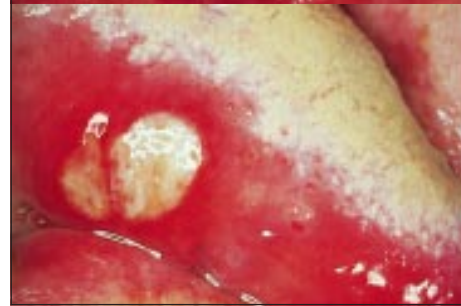
- Lupus erythematosus
- Behcet's syndrome
- Sweet's syndrome
- Reiter's disease

**Drugs**

- Cytotoxic agents
- Nicorandil
- Others

**Radiotherapy**

Minor aphthous ulceration (top) and major aphthous ulceration (bottom)



Major aphthous ulceration with severe scarring in patient with Behcet's syndrome

**Management**—Predisposing factors should be identified and corrected. Chlorhexidine mouthwashes may help. Symptoms can often be controlled with hydrocortisone hemisuccinate pellets or triamcinolone acetonide in carboxymethyl cellulose paste four times daily, but more potent topical corticosteroids may be required. Systemic corticosteroids are best given by a specialist. Thalidomide is also effective but is rarely indicated.

### Malignant ulcers

Oral carcinoma may present as a solitary chronic ulceration (see previous article).

### Mouth ulcers in systemic disease

Ulcers may be manifestations of disorders of skin, connective tissue, blood, or gastrointestinal tract.

The main skin disorders are lichen planus, pemphigus, pemphigoid, erythema multiforme, epidermolysis bullosa, and angina bullosa haemorrhagica (blood filled blisters that leave ulcerated areas after rupture). In view of the clinical consequences of pemphigus, accurate diagnosis of oral bullae is important, and referral for direct and indirect immunofluorescence of biopsy tissue is often indicated.

### Drug induced mouth ulcers

Among the drugs that may be responsible for mouth ulcers are cytotoxic agents, antithyroid drugs, and nicorandil.

## Non-ulcerative causes of oral soreness

### Erythema migrans (benign migratory glossitis, geographic tongue)

This common condition of unknown aetiology, which affects about 10% of children and adults, is characterised by map-like red areas of atrophy of filiform tongue papillae in patterns that change even within hours. The tongue is often fissured. Lesions can cause soreness or may be asymptomatic.

**Management**—There is no reliably effective treatment, although some have reported efficacy for zinc supplements. Similar lesions may be seen in Reiter's syndrome and psoriasis.

### Burning mouth syndrome (oral dysaesthesia, glossopyrosis, glossodynia)

This condition is common in people past middle age and is characterised by a persistent burning sensation in the tongue, usually bilaterally. The cause is unclear, but response to topical anaesthesia suggests it is a form of neuropathy. Discomfort is sometimes relieved by eating and drinking, in contrast to the pain from ulcerative lesions, which is typically aggravated by eating.

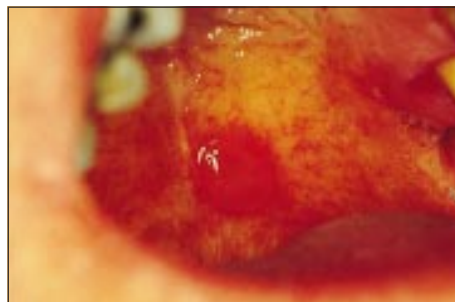
Organic causes of discomfort—such as erythema migrans, lichen planus, a deficiency glossitis (related to deficiency of iron, folate, or vitamin B-12), xerostomia, diabetes, and candidiasis—must be excluded, but these are only occasional causes. More often there is an underlying depression, monosymptomatic hypochondriasis, or anxiety about cancer or a sexually transmitted disease. Burning mouth syndrome is more common in Parkinson's disease.

**Management**—Reassurance and occasionally psychiatric consultation, vitamins, or antidepressants may be indicated, but they are not reliably effective.

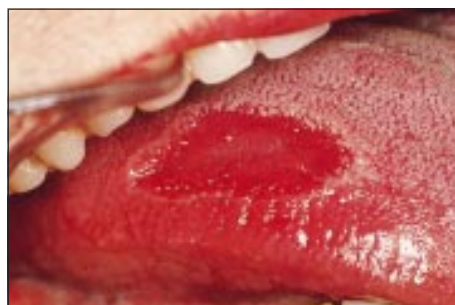### Desquamative gingivitis

Widespread erythema, particularly if associated with soreness, is usually caused by desquamative gingivitis. This is fairly common and is seen almost exclusively in women over middle age (see earlier article).

- Patients with aphthae are usually otherwise healthy
- Systemic diseases that should be excluded include Behcet's syndrome, gluten sensitive enteropathy, deficiencies of haematinics, and, occasionally, immunodeficiency
- Recurrent aphthous stomatitis is a clinical diagnosis
- Predisposing factors should be identified and corrected
- Topical corticosteroids aid resolution of ulcers
- In severe cases systemic immunomodulation may be needed



Bulla in oral pemphigoid



Erythema migrans

### Causes of a complaint of burning mouth syndrome

- |                  |                             |
|------------------|-----------------------------|
| ● Local          | ● Deficiency states         |
| Candidiasis      | Vitamin B                   |
| Erythema migrans | Folate                      |
| Lichen planus    | Iron                        |
| ● Psychogenic    | ● Diabetes mellitus         |
| Cancerophobia    | ● Dry mouth                 |
| Depression       | ● Drugs (such as captopril) |
| Anxiety          | ● Denture problems          |
| Hypochondriasis  | ● Parafunctional habits     |

- Erythema migrans commonly affects the tongue, there are usually no serious connotations, and there is no effective treatment
- Burning mouth syndrome is common, affects mainly the tongue, and antidepressants may be indicated, though organic disease must first be excluded

## Orofacial pain

Most orofacial pain is caused by

- Local disease, especially dental, mainly a consequence of caries (see earlier article)
- Psychogenic states
- Neurological disorders (such as trigeminal neuralgia). Similar features are seen in the rare SUNCT syndrome (short lasting, unilateral, neuralgiform headache attacks with conjunctival injection and tearing)
- Vascular disorders (such as migraine). Recent evidence suggests that chronic pain may occasionally be related to thrombosis or hypofibrinolysis causing small areas of jaw ischaemia and necrosis; this has been termed neuralgia-inducing cavitation necrosis
- Referred pain (such as angina).

### Psychogenic orofacial pain

This is an ill defined entity that includes burning mouth syndrome, atypical facial pain, atypical odontalgia, and the syndrome of oral complaints.

The pain is often of a dull, boring, or burning type of ill defined location. Most patients are women who are middle aged or older. They typically have constant chronic discomfort or pain, rarely use analgesics, sleep undisturbed by pain, have consulted several clinicians, have no objective signs and have negative investigations, and have recent adverse life events such as bereavement or family illness and also multiple psychogenic related complaints.

*Management*—Attempts at relieving pain by restorative treatment, endodontia, or exodontia are usually unsuccessful. Many patients lack insight and will persist in blaming organic diseases for their pain. Some patients are depressed or hypochondriacal and may respond to fluoxetine or dosulepin hydrochloride. However, many refuse drugs or psychiatric help. Those who will respond invariably do so early in treatment.

*Atypical odontalgia* presents with pain and hypersensitive teeth typically indistinguishable from pulpitis or periodontitis but without detectable pathology. It is probably a variant of atypical facial pain and should be treated similarly.

### Temporomandibular joint pain-dysfunction syndrome (myofascial pain-dysfunction syndrome, facial arthromyalgia)

This common disorder afflicts young women mainly. Symptoms are highly variable but characterised by

- Recurrent clicking in the temporomandibular joint at any point of jaw movement, and there may be crepitus especially with lateral movements
- Periods of limitation of jaw movement, with variable jaw deviation or locking but rarely severe trismus
- Pain in the joint and surrounding muscles, which may be tender to palpation.

Patients with a night time habit of clenching or grinding the teeth (bruxism) may awake with joint pain which abates during the day. In people who clench or grind during working hours the symptoms tend to worsen towards evening and sometimes have a psychogenic basis.

Different aetiological factors that have been implicated include muscle overactivity (such as bruxism and clenching), disruption of the temporomandibular joint, and psychological stress (such as anxiety and stressful life events). Precipitating factors may include wide mouth opening, local trauma, nail biting, and emotional upset. However, there is rarely one specific aetiology, and a combination of factors is often contributory. Occlusal factors do not in general seem to be important.

### Causes of orofacial pain

#### Local diseases

- Teeth and supporting tissues
- Jaws
- Maxillary antrum
- Salivary glands
- Eyes

#### Psychogenic pain

- Atypical facial pain and other oral symptoms associated with anxiety or depression (such as mandibular pain-dysfunction)
- Burning mouth syndrome

#### Referred pain

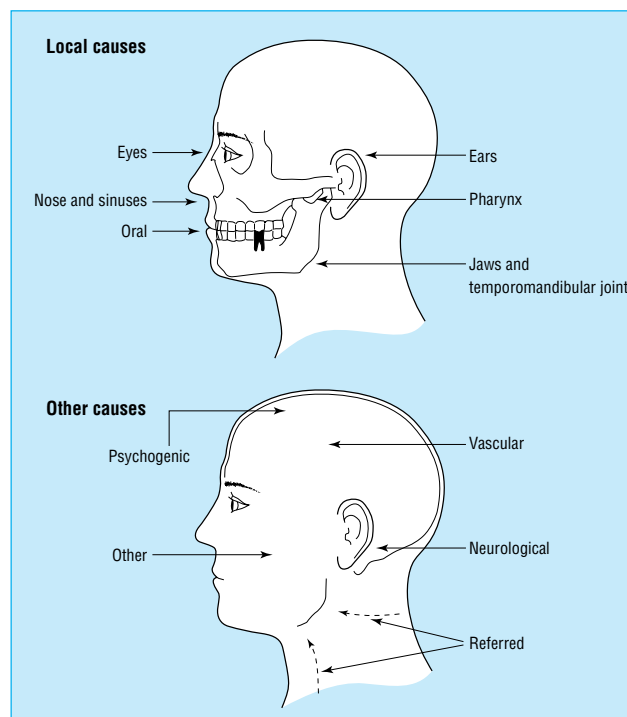
- Angina
- Lesions in neck or chest (including lung cancer)

#### Neurological disorders

- Trigeminal neuralgia
- Malignant neoplasms
- Multiple sclerosis
- Herpes zoster
- SUNCT syndrome

#### Vascular disorders

- Migraine
- Migrainous neuralgia
- Temporal arteritis (giant cell arteritis)
- Paroxysmal hemicrania
- Neuralgia-inducing cavitation osteonecrosis



Causes of orofacial pain

- Atypical facial pain and mandibular pain-dysfunction are common forms of orofacial pain
- There is typically a poorly localised dull ache
- Organic disease must be excluded
- Antidepressants may be indicated



**Diagnosis**—This is clinical. Radiographic changes are uncommon, and arthrography or magnetic resonance imaging is seldom indicated.

**Management**—Most patients recover spontaneously, and therefore reassurance and conservative measures are the main management. These include rest, jaw exercises (opening and closing), a soft diet, and analgesics. If these are insufficient, it can be helpful to use plastic splints on the occlusal surfaces (occlusal splints) to reduce joint loading, heat, ultrasound treatment, anxiolytic agents, or antidepressants. A very small minority of patients fail to respond to the above measures and require local corticosteroid or sclerosant therapy, local nerve destruction, or, often as a last resort, joint surgery.

Crispian Scully is dean and Rosemary Shotts is honorary lecturer at the Eastman Dental Institute for Oral Health Care Sciences, University College London, University of London ([www.eastman.ucl.ac.uk](http://www.eastman.ucl.ac.uk)).

The ABC of oral health is edited by Crispian Scully and will be published as a book in autumn 2000.

Crispian Scully is grateful for the advice of Rosemary Toy, general practitioner, Rickmansworth, Hertfordshire.

BMJ 2000;321:162-5

#### Further reading

- Krause I, Rosen Y, Kaplan I, Milo G, Guedj D, Molad Y, et al. Recurrent aphthous stomatitis in Behcet's disease: clinical features and correlation with systemic disease expression and severity. *J Oral Pathol Med* 1999;28:193-6
- Marbach JJ. Medically unexplained chronic orofacial pain. Temporomandibular pain and dysfunction syndrome, orofacial phantom pain, burning mouth syndrome, and trigeminal neuralgia. *Med Clin North Am* 1999;83:691-710, vi-vii
- Porter SR, Scully C, Pedersen A. Recurrent aphthous stomatitis. *Crit Rev Oral Biol Med* 1998;9:306-21
- Sakane T, Takeno M, Suzuki N, Inaba G. Behcet's disease. *N Engl J Med* 1999;341:1284-91
- Scully C. A review of common mucocutaneous disorders affecting the mouth and lips. *Ann Acad Med Singapore* 1999;28:704-7
- Scully C, Flint S, Porter SR. *Oral diseases*. London: Martin Dunitz, 1996
- Tammiala-Salonen T, Forssell H. Trazodone in burning mouth pain: a placebo-controlled, double-blind study. *J Orofac Pain* 1999;13:83-8
- Van der Waal I. *The burning mouth syndrome*. Copenhagen: Munksgaard, 1990

### *A patient who changed my practice*

#### The internet and a "small miracle"

I have just returned from a mother's day concert at my 6 year old's primary school. The first "welcome" statement was made by a friend of hers, A, in a loud clear voice—a remarkable achievement for this particular child.

I have known A since she was a baby, watching her and two younger siblings pass through the baby clinic and reach normal development milestones. A was always a quiet child in company, but I was surprised to hear my daughter, in A's class at nursery, remark one day, "You know Mummy, A never speaks at school." There was no hint of developmental delay, and at home A interacted quite normally with her family. The transition to primary school saw a persistence of A's determined silence—no verbal interaction at all with her class mates or her teachers, although her basic literacy and numeracy skills developed in line with those of her peers.

A's parents were worried but remained patient and expectant—they at least knew her much more normal behaviour at home. By the beginning of her second year at school A had still not uttered a single word at school. She also refused to remove her shoes and socks for physical education in front of others and would eat nothing all day, neither school dinners nor a packed lunch. A's parents asked for a specialist review, wondering if any form of therapy would lead to more normal childhood interaction. No specific help resulted from this psychiatric assessment, but at least A now had a label "selective mutism," and in today's world a label by itself can begin to unlock doors.

I have to say my heart sank a little at the sight of sheets of internet printouts in A's mother's hand when she came in to see me a couple of weeks after the psychiatric clinic appointment. This was not because I resent patients accessing health information but because I don't know how to judge the quality or validity of this information—I don't know how to use it to make clinical decisions. But I was impressed. A series of case reports and parents' stories of children seemingly similar to A who had responded dramatically to short courses of fluoxetine.

This drug is not licensed for children in the United Kingdom, but our local drug information pharmacist was able to locate a small trial describing its use in children with selective mutism.<sup>1</sup> A's parents and I talked about the concerns relating to the use of unlicensed medication, and I thought that I had to share my reservations explicitly, drawing up a clear contract acknowledging our shared responsibility in using this drug on their child.

Within two weeks of starting the drug, A was recording taped messages for her teacher and beginning to participate in physical education. After six weeks she is chattering happily with her friends at school and has been to her first party alone. She has been transformed into a totally "normal" 6 year old, and her parents are slowly withdrawing the fluoxetine.

I am convinced that the use of fluoxetine has played a central part in this huge change in A's behaviour, and I am equally sure that without the internet her parents could not have accessed this information. So if my heart sinks again at the sight of a patient's internet printout, I will simply remind myself of the small miracle of A and suspend my prejudice.

Di Jelley *general practitioner, North Shields*

1 Dummit RS, Klein RG, Tancer NK, Asche B, Martin J. Fluoxetine treatment of children with selective mutism: an open trial. *J Am Acad Child Adolesc Psychiatry* 1996;35:615-21.

We welcome articles of up to 600 words on topics such as *A memorable patient, A paper that changed my practice, My most unfortunate mistake*, or any other piece conveying instruction, pathos, or humour. If possible the article should be supplied on a disk. Permission is needed from the patient or a relative if an identifiable patient is referred to. We also welcome contributions for "Endpieces," consisting of quotations of up to 80 words (but most are considerably shorter) from any source, ancient or modern, which have appealed to the reader.