



# Feasibility, Safety, and Efficacy of Endovascular vs. Surgical Treatment of Unruptured Multi-Sac Intracranial Aneurysms in a Single-Center Retrospective Series

Lukas Goertz, MD<sup>1</sup>, Marco Timmer, MD<sup>2</sup>, David Zopfs, MD<sup>1</sup>, Kenan Kaya, MD<sup>1</sup>, Carsten Gietzen, MD<sup>1</sup>, Jonathan Kottlors, MD<sup>1</sup>, Lenhard Pennig, MD<sup>1</sup>, Marc Schlamann, MD<sup>1</sup>, Roland Goldbrunner, MD<sup>2</sup>, Gerrit Brinker, MD<sup>2</sup>, Christoph Kabbasch, MD<sup>1</sup>

<sup>1</sup>Department of Diagnostic and Interventional Radiology, Faculty of Medicine and University Hospital Cologne, University of Cologne, Köln, Germany

<sup>2</sup>Department of General Neurosurgery, Center of Neurosurgery, Faculty of Medicine and University Hospital Cologne, University of Cologne, Köln, Germany

**Purpose:** Multi-sac aneurysms (MSAs) are not uncommon, but studies on their management are scarce. This study aims to evaluate and compare the feasibility, safety, and efficacy of MSAs treated with either clipping or coiling after interdisciplinary case discussion at our center.

**Materials and Methods:** We retrospectively analyzed MSAs treated by microsurgical clipping, coiling, or stent-assisted coiling (SAC). Treatment modalities, complications, angiographic results, and clinical outcomes were evaluated. Major neurological events were defined as a safety endpoint and complete occlusion as an efficacy endpoint.

**Results:** Ninety patients (mean age, 53.2±11.0 years; 73 [81.1%] females) with MSAs met our inclusion criteria (clipping, 50; coiling, 19; SAC, 21). Most aneurysms were located in the middle cerebral artery (48.9%). All clipping procedures were technically successful, but endovascular treatment failed in 1 coiling case, and a switch from coiling to SAC was required in 2 cases. The major event rates were 4.0% after clipping (1 major stroke and 1 intracranial hemorrhage) and 0% after endovascular therapy ( $P=0.667$ ). At mid-term angiographic follow-up (mean 12.0±8.9 months), all 37 followed clipped aneurysms were completely occluded, compared to 8/17 (41.7%) after coiling and 11/15 (73.3%) after SAC ( $P<0.001$ ). Coiling was significantly associated with incomplete occlusion in the adjusted analysis (odds ratio, 11.7; 95% confidence interval, 2.7–52.6;  $P=0.001$ ).

**Conclusion:** Both endovascular and surgical treatment were feasible and safe for MSAs. As coiling was associated with comparatively high recanalization rates, endovascular treatment may be preferred with stent support.

**Key Words:** Aneurysm; Surgery; Catheter

## Correspondence to:

Lukas Goertz, MD

Department of Diagnostic and Interventional Radiology, Faculty of Medicine and University Hospital Cologne, University of Cologne, Kerpener Strasse 62, Köln 50937, Germany

Tel: +49-221-478-82735

Fax: +49-221-478-82736

E-mail: [lukas.goertz@uk-koeln.de](mailto:lukas.goertz@uk-koeln.de)

Received: February 22, 2024

Revised: May 29, 2024

Accepted: June 3, 2024

## Copyright © 2024 Korean Society of Interventional Neuroradiology

This is an Open Access article distributed under the terms of the Creative Commons Attribution Non-Commercial License (<http://creativecommons.org/licenses/by-nc/4.0>) which permits unrestricted non-commercial use, distribution, and reproduction in any medium, provided the original work is properly cited.

pISSN 2093-9043

eISSN 2233-6273

## INTRODUCTION

Lobulated aneurysms (Lobs) and aneurysms with daughter sacs (DSs) are morphologically complex aneurysms that account for approximately 30% of unruptured intracranial aneurysms (UIAs).<sup>1</sup> They can be grouped as multi-sac aneurysms (MSAs) because they consist of at least one additional aneurysmal sac arising from a common neck or from the main aneurysm body.<sup>2</sup> To distinguish DSs from Lobs, DSs have been defined to sit on the main aneurysm sac and cover a maximum of 25% of the main sac volume, while larger secondary sacs represent a lobulated morphology.<sup>1</sup>

Several previous studies have identified lobulated morphology as an independent risk factor for aneurysm rupture.<sup>1,3</sup> Since subarachnoid hemorrhage is a significant cause of morbidity and mortality, treatment of MSAs is considered essential.<sup>4</sup> The conventional approach to the treatment of complex aneurysms is microsurgical clipping. However, with the continuous advances in neurointerventional techniques, endovascular treatment is gaining importance in the management of simple and complex morphology MSAs.<sup>5,6</sup>

Although the safety and efficacy of various surgical and endovascular treatment options have been extensively studied for various types of UIAs, larger series that exclusively examine the treatment of MSAs are lacking.<sup>7-10</sup> Therefore, the best treatment options and clinical outcomes of MSAs remain unclear.

The purpose of this study was to evaluate whether coiling and stent-assisted coiling (SAC) are viable endovascular treatment alternatives to microsurgical clipping for unruptured anterior circulation MSAs, in terms of feasibility, safety, and efficacy, when selected for individual aneurysms after interdisciplinary case discussion at a neurovascular conference. We also used multivariate analysis to identify prognostic factors for neurological complications and incomplete occlusion at follow-up.

## MATERIALS AND METHODS

### Study Population

This is a retrospective, single-center analysis of consecutive patients who underwent surgical or endovascular treatment of UIAs between January 2013 and December 2020. Data collection was approved by the institutional review board and written informed consent was obtained from each patient

prior to the procedure.

All patients undergoing microsurgical clipping or endovascular coiling (with or without stenting) of MSAs were considered for inclusion in this study. Patients with multiple MSAs and incomplete preoperative angiographic imaging were excluded. Other exclusion criteria were pre-treated, partially thrombosed and giant (>25 mm) aneurysms and vertebrobasilar artery aneurysms.

### Procedure Details

All patients underwent preprocedure digital subtraction angiography (DSA) to confirm aneurysm location, size, and morphology. Thereafter, all cases were discussed on a case-by-case basis at a weekly neurovascular conference consisting of vascular neurosurgeons, vascular surgeons, interventional neuroradiologists, and neurologists. At these meetings, treatment decisions and allocation to either endovascular or surgical treatment were made by consensus, taking into account the specific aneurysm and patient characteristics. In cases of equipoise between surgical and endovascular treatment, the choice of modality was made by informed patient consent. If endovascular therapy was favored, the choice of endovascular modality (e.g., coil, stent) was at the discretion of the interventionalist, taking into account aneurysm and patient characteristics and patient preference.

Microsurgical clipping was the treatment of choice for middle cerebral artery (MCA) aneurysms, bifurcation aneurysms, and wide-necked anterior communicating artery (Acom) aneurysms. Clipping was performed under general anesthesia using an operating microscope under the guidance of intraoperative microdoppler ultrasound and/or indocyanine green videoangiography. The pterional approach was used for the majority of aneurysms. The interhemispheric approach was used in selected cases of anterior communicating aneurysms. Our institutional follow-up protocol after aneurysm clipping consisted of clinical evaluation and DSA 3–6 months after surgery, to allow the patient time for recovery after surgery. DSA was preferred over computed tomography angiography due to a higher sensitivity to detect aneurysm remnants.<sup>11</sup>

Endovascular procedures were performed under general anesthesia *via* the transfemoral access using a Philips biplane system (Philips). All patients received systemic heparinization during the procedure. Stand-alone coiling was the first-line treatment for internal carotid artery (ICA) aneurysms. If the coils could not be securely placed within the aneurysm cavi-

ty and tended to dislocate into the vessel lumen due to complex aneurysm geometry (i.e., neck width  $>4$  mm, dome-to-neck ratio  $<2$ ), additional stent implantation was considered. Patients were routinely treated with dual antiplatelet therapy (75 mg/d clopidogrel, 100 mg/d aspirin) started 5 days prior to the procedure, even when stand-alone coiling was planned in case additional stent implantation became necessary. After 4 months, treatment was continued with continuous single antiplatelet therapy, either clopidogrel or aspirin. Platelet inhibition was assessed in all endovascular patients with aspirin and P2Y12 assays (VerifyNow; Accumetrics). A platelet inhibition level between 30–60% for clopidogrel and 350–550 aspirin response units for aspirin was required. An inadequate response to either drug was counteracted by dose escalation (e.g., clopidogrel 150 mg/d) or substitution with prasugrel (40 mg bolus, 5 mg/d). Follow-up after endovascular aneurysm treatment consisted of clinical evaluation and control DSA at 6 and 24 months.

### Data Collection

Patient demographics, aneurysm characteristics, and treatment details were obtained from medical records. We reported all adverse events with new neurological symptoms. Major events were defined as lasting more than 7 days, whereas symptoms of minor events were defined as completely resolving within 7 days. Neurological complications included intracranial hemorrhage, ischemic stroke, symptomatic vasospasm, and seizure. Functional outcome was assessed using the modified Rankin scale (mRS) at discharge and at 1-year follow-up (favorable mRS score, 0–1; unfavorable mRS score, 2–6).

### Assessment of Aneurysm Morphology

Aneurysm morphology was evaluated using two-dimension-

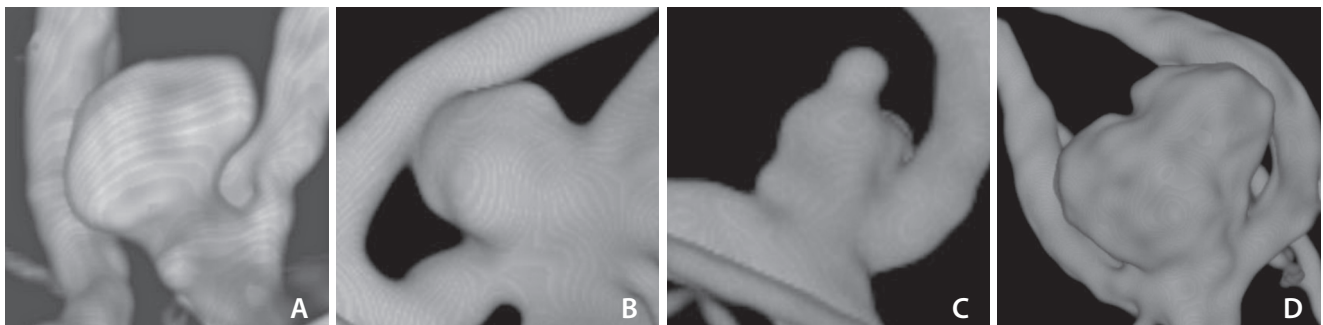
al (2D) DSA images and 3D volume-rendered images from rotational angiography data. The classification of aneurysm morphology proposed by the International Study of Unruptured Aneurysms (ISUIA) was used to classify aneurysms into single-sac aneurysms with regular or irregular margins, aneurysms with a DS, and Lobs.<sup>2</sup> The last 2 morphologic groups were considered MSAs and included in this study. Illustrative images of all 4 morphologic subtypes are shown in Fig. 1.

A DS was defined as a distinct protuberance arising from the primary aneurysm dome and accounting for a maximum of 25% of the main aneurysm sac. Lobs are composed of at least 1 additional aneurysm sac arising either directly from a combined neck or from the primary aneurysm dome and covering at least 25% of the main aneurysm sac.<sup>1</sup> Aneurysm size (i.e., the largest diameter of the aneurysm dome), aneurysm height, and neck width were also measured. The dome-to-neck ratio (aneurysm width/neck width) and the aspect ratio (aneurysm height/neck width) were calculated for all aneurysms. Aneurysms with a neck width  $>4$  mm or a dome-to-neck ratio  $<2$  were considered wide-necked.

The Raymond–Roy occlusion classification (RROC) was used to assess aneurysm obliteration at follow-up angiographic imaging: 1) complete aneurysm occlusion, 2) neck remnant, and 3) residual aneurysm. The RROC scale was originally developed for evaluation of coiled aneurysms; however, it is also used for clipped aneurysms.<sup>12</sup>

### Statistical Analysis

Categorical variables were expressed as numbers and percentages, and continuous variables were expressed as means  $\pm$  standard deviation. The 3 treatment groups were compared using chi-squared statistics with post-hoc Bonferroni pairwise comparison, and the Kruskal–Wallis test with post-hoc Dunn test, as appropriate. Age, sex, aneurysm mor-



**Fig. 1.** Three-dimensional reconstructions from rotational angiography showing illustrative aneurysms with regular margin (A), irregular margin (B), daughter sac (C), and lobulation (D).

phology, aneurysm location, aneurysm size, and treatment modality were tested for predicting neurological complications and incomplete occlusion at angiographic follow-up. Factors predictive in univariate analysis ( $P < 0.2$ ) were entered into a binary logistic regression model to identify independent prognostic factors for each outcome measure. All statistical tests were performed with SPSS version 25.0 (IBM Co.). A  $P$ -value  $< 0.05$  was considered statistically significant.

## RESULTS

### Patient and Aneurysm Characteristics

During the study period, a total of 529 patients were treated for unruptured aneurysms, whereof 125 (23.6%) patients had 133 MSAs. Thirty-five patients were excluded for the following reasons: treatment of multiple MSAs (8), flow diverter treatment (12), implantation of the Woven EndoBridge™ (MicroVention) (7), giant aneurysms (3), and vertebrobasilar artery aneurysms (5). The final study population consisted

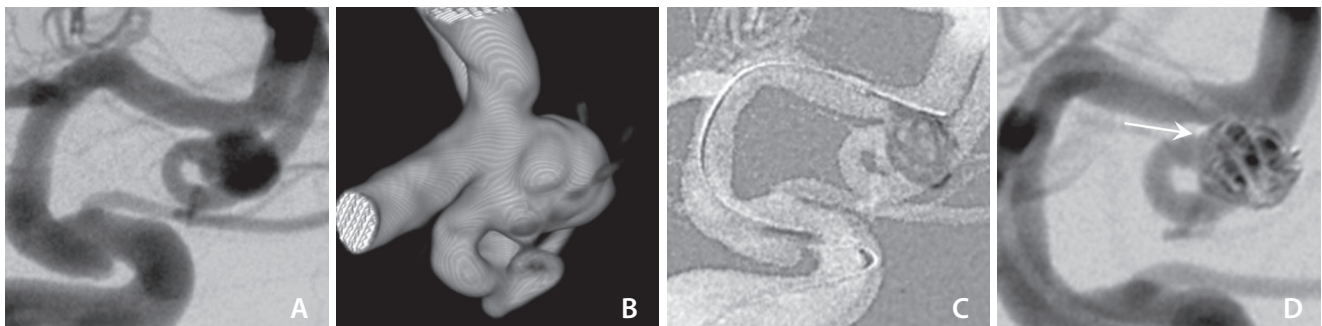
**Table 1. Baseline patient and aneurysm characteristics for the overall cohort and the 3 treatment groups**

	Overall (n=90)	Clipping (n=50)	Coiling (n=19)	Stent-assisted coiling (n=21)	P-value
Age (y)	53.2±11.0	50.3±9.5	54.8±14.5	58.4±8.8	0.019
Female sex	73 (81.1)	41 (82.0)	14 (73.7)	18 (85.7)	0.606
Morphology (Lob/DS)	57/33 (63.3/36.7)	29/21 (58.0/42.0)	14/5 (73.7/26.3)	14/7 (66.7/33.3)	0.452
Location					
ICA	12 (13.3)	2 (4.0)* <sup>†</sup>	4 (21.1)*	7 (33.3) <sup>†</sup>	0.001
ACA	24 (26.7)	7 (14.0) <sup>†</sup>	6 (31.6)	11 (52.4) <sup>†</sup>	0.003
MCA	44 (48.9)	40 (80.0)* <sup>†</sup>	2 (10.5)*	2 (9.5) <sup>†</sup>	<0.001
Pcom	10 (11.1)	2 (4.0)*	7 (36.8)*	1 (4.8)	<0.001
Aneurysm size (mm)	8.0±3.8	7.2±3.1	8.2±2.4	9.8±5.5	0.135
Neck width (mm)	4.0±1.5	3.9±1.3	3.7±1.2	4.6±2.0	0.327
Dome-to-neck ratio	1.7±0.7	1.5±0.6	1.7±0.5	2.0±1.0	0.503
Aspect ratio	2.0±1.0	1.8±1.0	2.2±0.7	2.0±1.1	0.084

Data are presented as means±standard deviation or number (%).

Lob, lobulated aneurysm; DS, daughter Sac; ICA, internal cerebral artery; ACA, anterior cerebral artery; MCA, middle cerebral artery; Pcom, posterior communicating artery.

\*Indicates a significant difference between clipping and coiling. <sup>†</sup>Indicates a significant difference between clipping and stent-assisted coiling.



**Fig. 2.** Digital subtraction angiography (A) and three-dimensional reconstruction from rotational angiography (B) show an unruptured aneurysm at the bifurcation of the middle cerebral artery with a daughter sac. The aneurysm neck is wide and covers the proximal part of the inferior M2 stem. Based on patient preference, the aneurysm was targeted for coiling. During insertion of the framing coil (C), the lower part of the coil protruded into the inferior M2 trunk (arrow) (D), resulting in flow reduction within the vessel. Therefore, the coil was removed. Although stent-assisted coiling was potentially an alternative endovascular option after antiplatelet loading, we assumed an increased risk of periprocedural complications with and the patient underwent microsurgical clipping.

of 90 patients with 33 aneurysms with DSs and 57 Lobs. The mean age of the patients was  $53.2 \pm 11.0$  years, and 73 (81.1%) patients were female.

The most common location of MSAs was the MCA in 44 (48.9%) cases, followed by the anterior cerebral artery (ACA) in 24 (26.7%). The mean aneurysm size was  $8.0 \pm 3.8$  mm and the mean neck width was  $4.0 \pm 1.5$  mm. Of 90 aneurysms, 50 (55.6%) were clipped, 19 (21.1%) were treated with stand-alone coiling, and 21 (23.3%) with SAC. Baseline patient and aneurysm characteristics for the entire cohort and for each treatment modality are shown in Table 1.

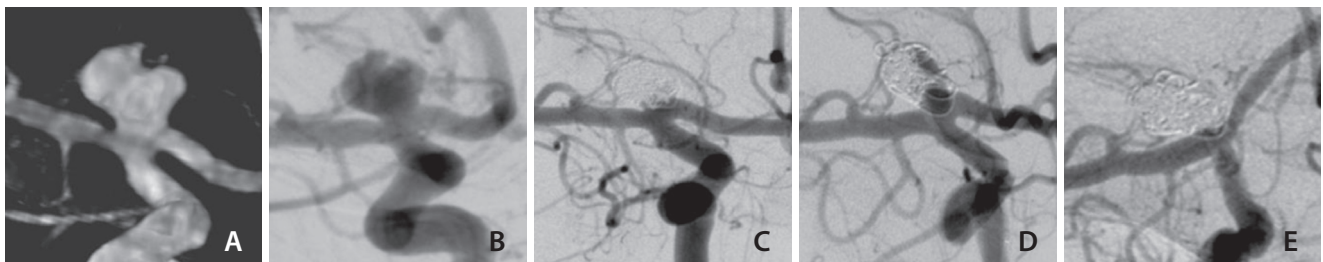
### Treatment

Clipping was most frequently used for MCA aneurysms ( $P < 0.001$ ), while older patients ( $P = 0.019$ ) and aneurysms located at the ICA ( $P = 0.001$ ), the ACA ( $P = 0.003$ ), and the posterior communicating artery (Pcom) ( $P < 0.001$ ) were more likely

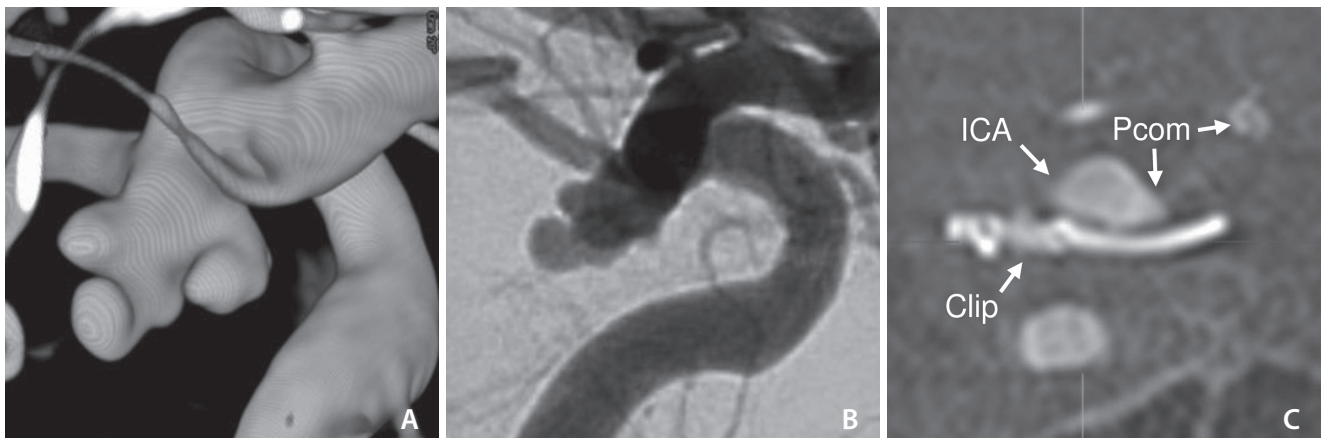
to be treated endovascularly.

All clipping procedures were technically successful. In the endovascular group, treatment with stand-alone coiling failed in 3 cases. Stand-alone coiling was not successful in a wide-necked aneurysm with a DS (6 mm) at the bifurcation of the MCA. In this case, the coils could not be securely placed in the aneurysm cavity and prolapsed into the parent artery. Although SAC was potentially an alternative endovascular option after antiplatelet loading, we assumed an increased risk of periprocedural complications with SAC and decided by interdisciplinary consensus to treat the aneurysm with microsurgical clipping. The case is presented in Fig. 2.

Furthermore, 2 aneurysms were initially planned to be treated with stand-alone coiling but eventually required stent support. In the first case, a coil was extended from the aneurysm into the Pcom. In the second case, an ICA aneurysm could not be adequately occluded by stand-alone coil-



**Fig. 3.** Stand-alone coiling. (A, B) A patient in thier 20s with a wide-necked bilobulated aneurysm at the terminal internal carotid artery. (C) The aneurysm sacs were embolized consecutively with 4 coils until complete occlusion was achieved. (D) After 3 months, the aneurysm showed recanalization due to coil compaction. (E) After retreatment with a combination of Woven EndoBridge™ (MicroVention) (not visible behind the coils) and recoiling (4 coils), the aneurysm showed stable occlusion at long-term follow-up.



**Fig. 4.** Microsurgical clipping. (A, B) A patient in thier 40s presented with acute third cranial nerve palsy. Three-dimensional DSA showed a trilobulated aneurysm at the posterior communicating artery (Pcom). The aneurysm was clipped *via* the pterional approach and punctured to release the mass effect. Stenosis of the parent artery was ruled out by intraoperative micro-doppler ultrasound and indocyanine green videoangiography. (C) At 3-month follow-up, the aneurysm was completely excluded from circulation and the Pcom was patent. The oculomotor nerve palsy was fully recovered. ICA, internal carotid artery.

ing, so a stent was added.

Successful cases of endovascular and surgical obliterations are shown in Figs. 3 and 4.

### Complications

Neurological events are shown in Table 2. There was a total of 13 (14.4%) neurological events, of which 2 (2.2%) were classified as major and 11 (12.2%) as minor. The major events consisted of 1 stroke and 1 hemorrhage after clipping. The major stroke was due to prolonged temporary occlusion of the parent artery during clipping of a complex lobulated MCA bifurcation aneurysm. The patient was severely disabled with an mRS of 5. The major subarachnoid hemorrhage was due to a procedural rupture during clipping of an Acom aneurysm; the patient was discharged to a rehabilitation center with an mRS 3. Minor neurological events in the clipping group included 2 minor strokes due to perforator infarction,

2 access-related subdural hematomas, and 4 seizures. All patients fully recovered from these minor complications during the hospital stay.

In the endovascular group, there were 3 minor strokes due to procedural thromboembolic events during coiling of an Acom aneurysm and stent-assisted coil embolization of an Acom and a Pcom aneurysm, respectively. All 3 patients had only mild symptoms and fully recovered during hospitalization.

There was no procedure-related mortality. The overall ( $P=0.228$ ) and major event rates ( $P=0.667$ ) were not significantly different across the treatment modalities. On univariate analysis, an increased aspect ratio ( $2.4\pm 1.6$  vs.  $1.8\pm 0.8$ ,  $P=0.031$ ) was associated with adverse events.

### Clinical Outcome

At discharge, 48/50 (96.0%) patients in the clipping group

**Table 2. Neurological adverse events for the overall cohort and the 3 treatment groups**

	Overall (n=90)	Clipping (n=50)	Coiling (n=19)	Stent-assisted coiling (n=21)	P-value
Overall	13 (14.4)	10 (20.0)	1 (5.3)	2 (9.5)	0.228
Major events	2 (2.2)	2 (4.0)	0 (0)	0 (0)	0.667
Ischemic stroke					
Major	1 (1.1)	1 (2.0)	0 (0)	0 (0)	
Minor	5 (5.6)	2 (4.0)	1 (5.3)	2 (9.5)	
Intracranial hemorrhage					
Major	1 (1.1)	1 (2.0)	0 (0)	0 (0)	
Minor	2 (2.2)	2 (4.0)	0 (0)	0 (0)	
Seizure (minor event)	4 (4.4)	4 (8.0)	0 (0)	0 (0)	
Symptomatic vasospasm	0 (0)	0 (0)	0 (0)	0 (0)	

Data are presented as number (%).

**Table 3. Angiographic outcome for the overall cohort and the 3 treatment groups**

	Overall (n=69)	Clipping (n=37)	Coiling (n=17)	Stent-assisted coiling (n=15)	P-value
Follow-up period (mo)	12.0±8.9	10.9±9.1	13.4±9.2	13.0±8.1	0.584
Occlusion classification					<0.001
RROC=1	56 (81.2)	37 (100)* <sup>†</sup>	8 (47.1)*	11 (73.3) <sup>†</sup>	
RROC=2	9 (13.0)	0 (0)*	7 (41.2)*	2 (13.3)	
RROC=3	4 (5.8)	0 (0)	2 (11.8)	2 (13.3)	
Retreatment	0 (0)	0 (0)	4 (23.6)	1 (6.6)	

Data are presented as means±standard deviation or number (%).

RROC, Raymond–Roy occlusion classification.

\*Indicates a significant difference between clipping and coiling. <sup>†</sup>Indicates a significant difference between clipping and stent-assisted coiling.

and all 40 patients in the endovascular group achieved a favorable outcome. At 1-year follow-up, a favorable outcome was achieved by 97.8% (44/45) in the clipping group and in 100% (34/34) in the endovascular group.

### Angiographic Outcome and Retreatment Rates

Angiographic follow-up was available for 37/50 (74.0%) patients in the clipping group (mean follow-up 10.9±9.1 months), 17/19 (89.5%) in the coiling group (mean follow-up 13.4±9.2 months), and 15/21 (71.4%) in the SAC group (mean follow-up 13.0±8.1 months) (Table 3).

The complete occlusion rate after clipping (37/37 [100%]) was significantly higher ( $P<0.001$ ) than that of coiling (8/17 [47.1%]) and that of SAC (11/15 [73.3%]). The complete occlusion rates of SAC were higher than that of coiling without reaching statistical significance ( $P=0.130$ ). For coiled aneurysms with recanalization were successfully retreated with coiling in 3 cases and SAC in 1. In the SAC group, 1 retreatment with a flow diverter implantation failed in an ICA aneurysm. This aneurysm was subsequently followed angiographically.

In univariate analysis, Pcom location (44.4% vs. 15.0%,  $P=0.037$ ) and coiling (52.9% vs. 7.7%,  $P<0.001$ ) were associated with incomplete occlusion at angiographic follow-up. In multivariate analysis, coiling was the only significant independent prognostic factor for incomplete occlusion (odds ratio, 11.7; 95% confidence interval, 2.7–52.6;  $P=0.001$ ).

## DISCUSSION

This study showed that both endovascular and surgical treatment of MSAs is reasonably safe. Clipping had slightly higher complication rates than endovascular treatment, but major events were low. Endovascular treatment failed only in a minority of cases, but comparatively high recanalization rates of 53% were seen after stand-alone coiling. This information is important for risk stratification and decision-making in these morphologically-challenging aneurysms. Although we attempted to compare endovascular and surgical treatment, a robust comparison is hampered by differences in baseline characteristics and a substantial selection bias because specific aneurysms were selected for endovascular treatment after interdisciplinary case discussion.

In addition, MSAs have a more complex aneurysm geometry than aneurysms with a regular morphology. In a

morphometric study, Goertz et al.<sup>13</sup> reported that compared to regular aneurysms, Lobs were associated with older patient age (57 years vs. 49 years), Acom location (26% vs. 2.5%), bifurcation location (70% vs. 27%), larger aneurysm size (8 mm vs. 5 mm), and steeper inflow angle (145° vs. 114°). These characteristics make MSAs more difficult to treat.

### Microsurgical Treatment

Despite the tremendous progress in neurointerventional techniques over the last 15 years,<sup>5,6</sup> there is still a fraction of aneurysms that cannot be safely treated by interventional means and for which clipping remains the first-line treatment option. For example, MCA aneurysms are still preferentially treated surgically in most neurovascular centers.<sup>14-16</sup> This treatment regimen was also true for MSAs in our cohort. Clipping of MSAs was associated with high technical success, resulting in complete occlusion of all aneurysms followed. Thus, the high occlusion rates reported for aneurysm clipping were also applicable to MSAs.<sup>17</sup>

Major complications with persistent neurological deficits occurred in only 4.0%, which seems reasonable for this complex subset of UIAs. Morbidity rates were 4.0% at discharge and 2.2% at 1-year, which is comparable to previous studies on clipping.<sup>17</sup> In fact, seizures were the most common complication in the clipping group. It can be speculated that clip placement in MSAs is more difficult than in single-sac aneurysms and may be associated with longer operative time and more manipulation of the aneurysm dome. These factors are known to increase the likelihood of complications.<sup>18</sup>

As in previous studies, the complication rate appears to be higher than with endovascular procedures, but the different aneurysm subsets of the 2 treatment groups do not allow a direct comparison. In fact, endovascular treatment of MCA aneurysms is challenging and associated with higher complication rates compared to typical endovascular sites such as the ICA and basilar artery. For example, Vendrell et al.<sup>19</sup> reported a complication rate of 19.4% and permanent morbidity of 5.7% for endovascular treatment of MCA aneurysms, which is not lower than the complication rates for clipping focused on complex morphology in the present series.

### Endovascular Treatment

Although microsurgical clipping is the standard of care for complex morphology anterior circulation aneurysms, an increasing number of complex aneurysms are being treated endovascularly. Therefore, we also evaluated the efficacy

of coiling and SAC for the treatment of MSAs. It should be noted that aneurysms were selected for coiling and SAC after interdisciplinary case discussion, whereas the majority of MSAs were considered unfavorable for endovascular treatment and were treated by clipping (50 clipping vs. 40 endovascular). Given this preselection, coiling failed in 3 cases. In our experience, severe lobulation and a wide neck are characteristics that make stand-alone coiling difficult, as the coil cannot unfold properly in the aneurysm sacs and therefore protrudes into the vessel lumen. Coil protrusion can be counteracted with an additional stent or switch to flow diversion if possible. Otherwise, clipping may be necessary, such as for bifurcation aneurysms that are difficult to treat with stents.

In our study, the complication rate was low and we did not observe any case of adverse outcome after coiling of MSAs. Thus, our study of MSAs confirms the excellent safety results of coiling reported in previous studies.<sup>20</sup>

A major disadvantage of endovascular treatment may be that it is associated with higher rates of aneurysm recanalization than clipping.<sup>14,21</sup> Similarly, the rate of aneurysm recurrence at the 6-month angiographic follow-up in our endovascular cohort was 53.0% after coiling and 26.7% after SAC. Based on these mid-term angiographic results, the rate of aneurysm recurrence is expected to increase significantly in the long-term. Due to the high rate of aneurysm recanalization, coiled MSAs are associated with an increased risk of aneurysmal subarachnoid hemorrhage in the long-term, which may have a serious impact on patient prognosis.<sup>22</sup> These considerations must be taken into account when developing a treatment strategy.

In the multivariate analysis, stand-alone coiling was an independent prognostic factor for incomplete occlusion of MSAs, whereas SAC carried a reasonable risk of aneurysm recurrence. In general, aneurysm recurrence after coiling of UIAs is reported to be approximately 25%.<sup>20</sup> Therefore, the recurrence rate after coiling was significantly higher than in most other studies that do not differentiate aneurysm morphology. It can be speculated that achieving dense coil packing in MSAs is complicated by their lobulated shape, making these aneurysms susceptible to coil compaction and aneurysm recurrence. To compensate for this risk, MSAs may require longer angiographic follow-up after stand-alone coiling and retreatment of aneurysm remnants, increasing the cumulative risk of procedure-related complications.

### Treatment Considerations

The results of our study indicate a high feasibility and safety of endovascular treatment of MSA when used in selected patients after prior interdisciplinary case discussion. However, recanalization rates were comparably high after stand-alone coiling, while SAC appeared to be more robust to coil compaction and may therefore be the preferred endovascular treatment option for the majority of patients with MSAs, even if it requires long-term antiplatelet therapy. However, coiling may be considered in older patients with limited life expectancy. Clipping had a 100% success or complete occlusion rate, but a slightly higher complication rate than endovascular treatment. However, the complication rates do not appear to exceed those of previous studies in unselected cohorts. Therefore, clipping may remain a viable option for MSA when endovascular treatment appears inappropriate or when antiplatelet therapy is not desired, such as in younger patients.

### Limitations

Due to the retrospective nature of this study, the treatment groups were not balanced with respect to patient characteristics and aneurysm location, making direct comparisons between groups difficult. Aneurysms were preselected for either endovascular or surgical treatment at a multidisciplinary neurovascular conference, introducing a clear selection bias. Because this was a single-center analysis, the number of patients enrolled is limited and our findings require validation by further studies. The follow-up was incomplete both in the clipping and the endovascular group. In addition, we did not analyze long-term follow-up results, but it can be expected that recanalization rates might increase further after coiling. Aware of the above limitations, this study provides novel insights into the management and risk profile of UIAs that may help guide treatment decisions.

### CONCLUSION

In conclusion, both surgical and endovascular approaches were reasonably safe treatment options for MSAs. A similar proportion of patients in both groups achieved a favorable outcome. Because stand-alone coiling of MSAs appears to have low rates of complete aneurysm occlusion, it may be preferred in combination with stenting techniques.



**Fund**

None.

**Ethics Statement**

Data collection was approved by the institutional review board and written informed consent was obtained from each patient prior to the procedure. This paper does not include any images or information that may identify the person.

**Conflicts of Interest**

DZ is on the speaker's bureau of Philips (Amsterdam, the Netherlands) and lecturer for Amboss GmbH (Cologne, Germany). CK serves as consultant for Acandis GmbH (Pforzheim, Germany) and as proctor for MicroVention Inc./Sequent Medical (Aliso Viejo, CA, USA). The other authors have no conflicts to disclose.

**Author Contributions**

Concept and design: LG and CK. Analysis and interpretation: LG and MS. Data collection: LP, MT, KK, CG, RG, and GB. Writing the article: LG. Critical revision of the article: LG, MT, DZ, KK, CG, JK, LP, MS, RG, GB, and CK. Final approval of the article: LG, MT, DZ, KK, CG, JK, LP, MS, RG, GB, and CK. Statistical analysis: JK. Overall responsibility: LG.

**ORCID**

Lukas Goertz: <https://orcid.org/0000-0002-2620-7611>

Marco Timmer: <https://orcid.org/0000-0002-8790-9617>

David Zopfs: <https://orcid.org/0000-0001-9978-7453>

Kenan Kaya: <https://orcid.org/0000-0003-3276-2571>

Carsten Gietzen: <https://orcid.org/0000-0002-2354-3847>

Jonathan Kottlors: <https://orcid.org/0000-0002-0475-1472>

Lenhard Pennig: <https://orcid.org/0000-0002-6606-9313>

Marc Schlamann: <https://orcid.org/0000-0002-9940-1503>

Roland Goldbrunner: <https://orcid.org/0000-0002-1927-0022>

Gerrit Brinker: <https://orcid.org/0000-0002-0184-0680>

Christoph Kabbasch: <https://orcid.org/0000-0003-3712-2258>

**REFERENCES**

1. Abboud T, Rustom J, Bester M, Czorlich P, Vittorazzi E, Pinn Schmidt HO, et al. Morphology of ruptured and unruptured intracranial aneurysms. *World Neurosurg* 2017;99:610-617
2. Forbes G, Fox AJ, Huston J 3rd, Wiebers DO, Torner J. Interobserver variability in angiographic measurement and morphologic characterization of intracranial aneurysms: a report from the International Study of Unruptured Intracranial Aneurysms. *AJNR Am J Neuroradiol* 1996;17:1407-1415
3. Dhar S, Tremmel M, Mocco J, Kim M, Yamamoto J, Siddiqui AH, et al. Morphology parameters for intracranial aneurysm rupture risk assessment. *Neurosurgery* 2008;63:185-196; discussion 196-197
4. Etminan N, Beseoglu K, Barrow DL, Bederson J, Brown RD Jr, Connolly ES Jr, et al. Multidisciplinary consensus on assessment of unruptured intracranial aneurysms: proposal of an international research group. *Stroke* 2014;45:1523-1530
5. Sorenson T, Brinjikji W, Lanzino G. Newer endovascular tools: a review of experimental and clinical aspects. *J Neurosurg Sci* 2016;60:116-125
6. Jiang B, Paff M, Colby GP, Coon AL, Lin LM. Cerebral aneurysm treatment: modern neurovascular techniques. *Stroke Vasc Neurol* 2016;1:93-100
7. Kwon OK, Han MH, Lee KJ, Oh CW, Ko YC. A technique of GDC embolization for deeply bilobulated aneurysms. *AJNR Am J Neuroradiol* 2002;23:693-696
8. Wang JT, Yang HC, Lin CF, Guo WY, Luo CB, Chen MH, et al. Bilobulated paraclinoid aneurysm mimics double aneurysms: a comparison of endovascular coiling and surgical clipping treatments. *J Chin Med Assoc* 2014;77:544-547
9. Mercado M, de Jesús O. Bilobulated aneurysms at the origin of the posterior communicating artery. *P R Health Sci J* 2003;22:405-408
10. Her Y, Jeon JP, Choi HJ, Cho YJ. Stent-assisted modified coil protection technique for bilobulated aneurysm: technical note. *Radiol Case Rep* 2016;12:146-149
11. Uricchio M, Gupta S, Jakowenko N, Levito M, Vu N, Doucette J, et al. Computed tomography angiography versus digital subtraction angiography for postclipping aneurysm obliteration detection. *Stroke* 2019;50:381-388
12. Kotowski M, Farzin B, Fahed R, Guilbert F, Chagnon M, Darsaut TE, et al. Residual cerebral aneurysms after microsurgical clipping: a new scale, an agreement study, and a systematic review of the literature. *World Neurosurg* 2019;121:e302-e321
13. Goertz L, Hamisch C, Pflaeging M, Kabbasch C, Borggreffe J, Timmer M, et al. Angiographic characteristics of lobulated intracranial aneurysms. *World Neurosurg* 2019;131:e353-e361
14. Smith TR, Cote DJ, Dasenbrock HH, Hamade YJ, Zammar SG, El Tecle NE, et al. Comparison of the efficacy and safety of endovascular coiling versus microsurgical clipping for unruptured middle cerebral artery aneurysms: a systematic review and me-

- ta-analysis. *World Neurosurg* 2015;84:942-953
15. Blackburn SL, Abdelazim AM, Cutler AB, Brookins KT, Fargen KM, Hoh BL, et al. Endovascular and surgical treatment of unruptured MCA aneurysms: meta-analysis and review of the literature. *Stroke Res Treat* 2014;2014:348147
  16. Nanda A, Patra DP, Bir SC, Maiti TK, Kalakoti P, Bollam P. Microsurgical clipping of unruptured intracranial aneurysms: a single surgeon's experience over 16 years. *World Neurosurg* 2017;100:85-99
  17. Kotowski M, Naggara O, Darsaut TE, Nolet S, Gevry G, Kouznetsov E, et al. Safety and occlusion rates of surgical treatment of unruptured intracranial aneurysms: a systematic review and meta-analysis of the literature from 1990 to 2011. *J Neurol Neurosurg Psychiatry* 2013;84:42-48
  18. Kerezoudis P, McCutcheon BA, Murphy M, Rayan T, Gilder H, Rinaldo L, et al. Predictors of 30-day perioperative morbidity and mortality of unruptured intracranial aneurysm surgery. *Clin Neurol Neurosurg* 2016;149:75-80
  19. Vendrell JF, Menjot N, Costalat V, Hoa D, Moritz J, Brunel H, et al. Endovascular treatment of 174 middle cerebral artery aneurysms: clinical outcome and radiologic results at long-term follow-up. *Radiology* 2009;253:191-198
  20. Naggara ON, White PM, Guilbert F, Roy D, Weill A, Raymond J. Endovascular treatment of intracranial unruptured aneurysms: systematic review and meta-analysis of the literature on safety and efficacy. *Radiology* 2010;256:887-897
  21. Birski M, Wałęsa C, Gaca W, Paczkowski D, Birska J, Harat A. Clipping versus coiling for intracranial aneurysms. *Neurol Neurochir Pol* 2014;48:122-129
  22. Molyneux AJ, Birks J, Clarke A, Sneade M, Kerr RS. The durability of endovascular coiling versus neurosurgical clipping of ruptured cerebral aneurysms: 18 year follow-up of the UK cohort of the International Subarachnoid Aneurysm Trial (ISAT). *Lancet* 2015;385:691-697