

An X across the Chest: A Rare Case of a Criss-crossed Sternalis Muscle

Swapna Ramakrishnan¹, Ishan Mahajan¹, Nikitha T¹, Robert Kevin Fernandez², Minnie Pillay¹

¹Amrita School of Medicine, Amrita Institute of Medical Sciences, Amrita Vishwa Vidyapeetham, Kochi - 682041, Kerala, India,

²Manipal Tata Medical College, Manipal Academy of Higher Education, Manipal, India.

Correspondence: *minniepillay@aims.amrita.edu; pillayminnieanat@gmail.com*; Tel.: + 91 989 5511577

Received: 26 September 2023; **Accepted:** 11 December 2023

Abstract

Objective. The present case study aims at drawing attention to a very rare presentation of the sternalis muscle noticed during routine dissection, and is intended to highlight the clinical significance and usefulness of this unique muscle in reconstructive surgeries, especially of the breast. **Case Report.** Though many morphological variants of the muscle have been reported, we came across a unique bilateral sternalis muscle during routine dissection for undergraduate medical teaching, in an 80-year-old male cadaver. The muscle originates on both sides from the external oblique aponeurosis from the fleshy belly, and after becoming tendinous, converges in the midline to form a common tendon at the level of the sternal angle, and then splits again into two tendons which become continuous with the ipsilateral sternocleidomastoid. **Conclusion.** Notwithstanding the fact that the presence of a sternalis can be misdiagnosed as a wide range of anterior chest wall lesions and tumors, especially with misdiagnosis of breast masses in routine mammograms, it has great use as a muscular flap for reconstructive surgeries of the anterior chest wall, head, neck and breast.

Key Words: Sternalis Muscle ▪ Mammogram ▪ Breast Augmentation ▪ Submuscular Pocket ▪ Muscular Flap.

Introduction

The sternalis muscle (SM) is a well-documented but uncommon muscular variant of the anterior chest wall (1). Since first reported in 1604 by Bartheloney Cabrol, numerous articles have been published on this peculiar muscle, which presents in several morphological forms as a thin or thick band, superficial to the pectoral fascia with longitudinal orientation, either unilaterally or bilaterally, but without any apparent physiological function (1-3).

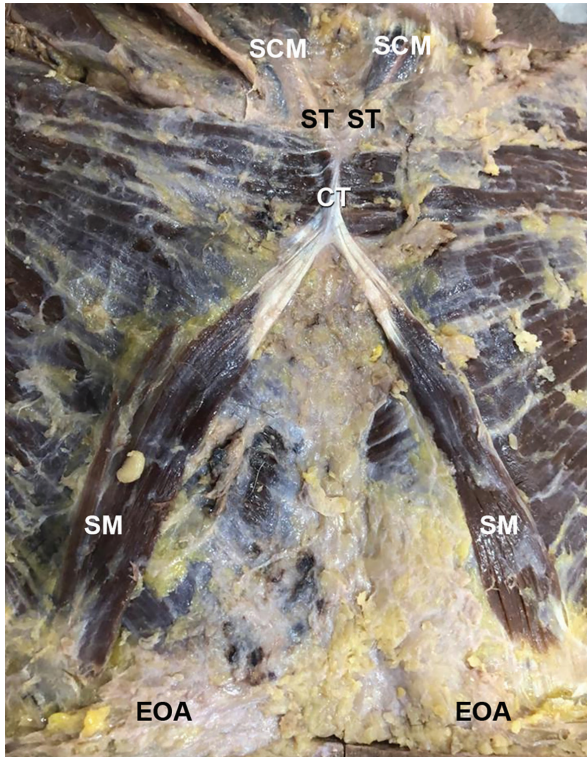
The sternalis muscle has come to the limelight in recent years because it has been implicated in the misdiagnosis of breast mammograms due to its parasternal location, thus causing confusion amongst radiologists (4), perhaps due to their lack of familiarity with it. However, when undetected before surgical procedures of the thorax, it can interfere with and prolong them (5, 6), but, when

detected preoperatively, it can be used as a flap in reconstructive surgeries of the anterior chest wall, breast, head and neck (6, 7), and prevent diagnostic errors and complications during surgical interventions.

Hence, the aim of the present study is to draw the attention of radiologists and surgeons to this very rare presentation of a criss-crossed sternalis muscle, and to discuss further the clinical implications and its usefulness in reconstructive surgeries, especially of the breast.

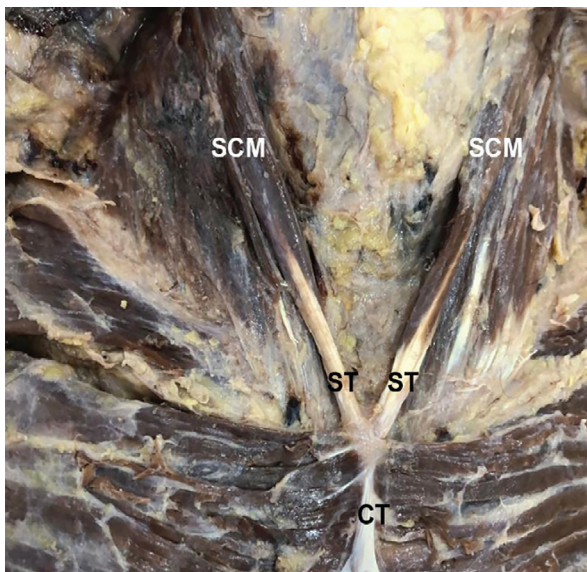
The Case

During routine dissection of the pectoral region for undergraduate medical teaching, an interesting bilateral variation of the sternalis muscle was observed in a 80-year-old male cadaver. The dissection was carried out according to the standard protocol mentioned in Cunningham's Manual of



SCM=Sternocleidomastoid; ST=Split tendons of the sternalis muscle; CT=Common tendon; SM=Sternalis muscle; EOA=External oblique aponeurosis.

Figure 1. Bilateral sternalis muscle with a common tendon in the midline, which splits into two to merge with the ipsilateral sternocleidomastoid.



SCM=Sternocleidomastoid; ST=Split tendons of sternalis muscle; CT=Common tendon.

Figure 2. Common tendon of the bilateral sternalis splitting to merge with ipsilateral sternocleidomastoid.

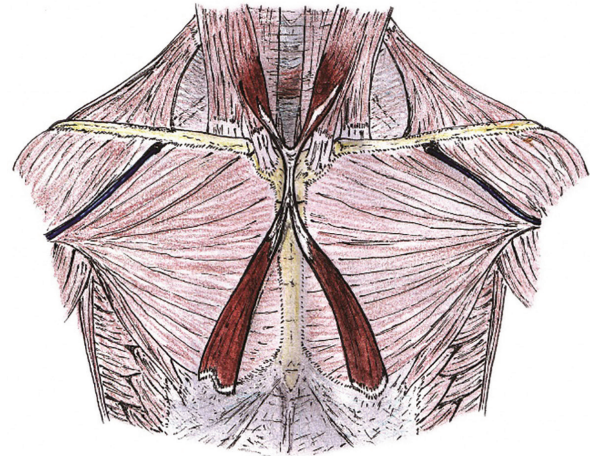


Figure 3. Schematic illustration of the variation.

Anatomy (8). The muscle originated on both sides from the fleshy belly, and was about 12 cm long on the right and 10.5 cm on the left from the aponeurosis of the external oblique muscle, after which it became tendinous, with a tendon about 6.5 cm long on the right and 6 cm on the left. The bilateral muscle converged medially to form a cord-like tendon, 2 cm in length, on the median plane at the level of the sternal angle, which again split into two tendons, to the right (3.5 cm) and left (2.5 cm), after which it became fleshy and blended with the ipsilateral sternocleidomastoid (Figures 1 and 2). The muscles were innervated by medial pectoral nerve on both sides. A schematic diagram of the variation is depicted in Figure 3.

Discussion

With technological advances in medical imaging techniques and the evolution of reconstructive procedures, the sternalis muscle has come into the limelight as a variant worth investigating.

Breast augmentation is one of the top five cosmetic surgical procedures in the world, and has continued to be so since 2006 (9). However, strangely, there were hardly any reports in the literature on the association of this muscle with these procedures until it was highlighted by Khan in 2008 (10), when he came across two cases of SM during breast augmentation procedures. According to him, the absence of reports on the role of this

muscle in augmentation mammoplasty could be due to inadequate anatomic understanding or the lack of visualization when the procedure is performed through a key hole as compared with mastectomies (10). He states that the presence of an SM could be challenging, but of great value during an inframammary approach for breast augmentation procedures, where the prosthesis is placed in the submuscular pocket, deeper than the pectoralis major (1, 10). Although the sternalis can make detection of the dissection plane difficult, as it interferes with dissection of the submuscular pocket (5), it can be used as an extra cover for the implant in the parasternal region, leading to better results, especially in thin individuals in whom the prosthesis may be visible in the lower parasternal region when placed in the submuscular pocket, and hence aesthetically unappealing (10). If a subglandular pocket is used, the implant lies superficially to the musculature, eliminating the concerns raised above (10). However, when a unilateral sternalis muscle is present and a subglandular pocket is used for the prosthesis, without proper dissection of the SM and the medial edge of the pectoralis major, the insertion, as well as the alignment of the implant, can be difficult, leading to asymmetry between the sides, and poor aesthetic outcome (7). According to Kabay et al. (11), inclusion of an SM in mastectomy could depend on its location, the extent of direct invasion by the tumor, and the presence of breast tissue under the muscle. He reported a case of modified radical mastectomy for invasive ductal carcinoma in the presence of an SM, where the sternalis muscle was removed despite not having macroscopic invasion, due to the apprehension that tumor nest cells may be lodged in its lymphatic channels due to the close proximity to the tumor.

In a meta-analysis of the published literature of the last 200 years on the prevalence, and distribution of the sternalis muscle, Asgar et al. (12), reported the worldwide prevalence of SMs to be 6% or 0.06 [0.05-0.7, 95% CI] in 27,470 adults and 0.29 [0.20-0.39, 95% CI] in 673 fetuses. The prevalence was three times higher in Asian mongoloids (9.1%) in comparison to Asian Caucasians

(3.33%). Cadaveric investigations revealed the overall prevalence of SMs to be 5.96% in adults on the basis of 76 studies, which was higher than in other modalities of investigation such as, multidetector computerized tomography (MDCT) 4.33%, surgical studies 0.47% and mammographic studies, 0.02%, respectively (12).

Although different hypothesis have been proposed regarding the homology of the sternalis, the most widely accepted view is that it is derived from the pectoralis major by virtue of its innervation by pectoral nerves (as in the present case), or from the rectus abdominis due to its innervation by intercostal nerves in many cases (1, 13, 14). It is also hypothesized that the sternalis is a downward extension of the sternocleidomastoid, due to the close association or continuity of their tendons at the clavicle or upper part of sternum, but after a prolonged study of the sternalis, Turner concluded that their relationship is incidental rather than true homology (3).

Many authors have attempted to classify the highly variable anatomy of the SM but the distribution of the sternalis based on classification has been abandoned due to the lack of consistency between the classifications, which failed to reveal any common attributes and characteristics of the SM (12). Although there are reports on the so-called crisscrossed sternalis, our present case is unique and very different from the commonly reported types, with a fleshy origin and insertion, and a crossed tendon in between on the median plane. We reported two cases of SMs earlier, one unilateral, with its origin in the lower part of the pectoral fascia and insertion into the contralateral sternocleidomastoid, and the other a bilateral case with its origin from the external oblique aponeurosis and insertion into the sternocleidomastoid, both origin and insertion being ipsilateral (15).

Conclusion

Although first reported four centuries ago, the SM has remained in relative obscurity due to its erratic occurrence and inconsequential presence. With the technological advancement in medical

imaging and evolution of surgical procedures, the sternalis is increasingly being viewed as a muscle worthy of attention. Awareness of its possible presence could avoid diagnostic errors by radiologists, help surgeons select the most appropriate surgical approach, and it can be made use of in reconstructive procedures, especially when a pocket dissection is made in the subpectoral plane for augmentation mammoplasty.

What Is Already Known on This Topic:

The sternalis muscle is well documented and is familiar to anatomists. Its presence may mislead clinicians and interfere with surgical procedures.

What This Study Adds:

The study highlights a very rare presentation of the sternalis muscle in order to make radiologists, as well as surgeons operating in the area, aware of such a possibility. The muscle has great value as it can be used as a flap in reconstructive surgeries, especially of the head, neck and breast.

Acknowledgements: The authors wish to acknowledge the help rendered by the gross anatomy technician Mr Mayilswamy T, for his help with dissection and Mr Varghese M, technician for medical illustration in preparing the images.

Authors' Contributions: Dissection and identification of the case: SR, IM, NT, RKF and MP; Analysis and interpretation of the case: SR, MP, IM and NT; Drafting the article: MP and SR; Revision of the article critically for important intellectual content: SR and MP; Approved final version of the manuscript: SR, IM, NT, RKF and MP; Schematic diagram of the variation: RKF.

Conflict of Interest: The authors declare that they have no conflict of interest.

References

- Snosek M, Tubbs RS, Loukas M. Sternalis muscle, what every anatomist and clinician should know. *Clin Anat.* 2014;27(6):866-84. doi: 10.1002/ca.22361. Epub 2014 Jan 16.
- Scott-Conner CE, Al-Jurf AS. The sternalis muscle. *Clin Anat.* 2002;15(1):67-9. doi: 10.1002/ca.1096.
- Turner W. On the Musculus Sternalis. *J Anat Physiol.* 1867;1(2):246-378.25.
- Bradley FM, Hoover HC Jr, Hulka CA, Whitman GJ, McCarthy KA, Hall DA, et al. The sternalis muscle: an unusual normal finding seen on mammography. *AJR Am J Roentgenol.* 1996;166(1):33-6. doi: 10.2214/ajr.166.1.8571900.
- Salval A, Scevola A, Baruffaldi Preis FW. Sternalis muscle: an uncommon finding during aesthetic breast surgery. *Aesthet Surg J.* 2012;32(7):903-5. doi: 10.1177/1090820X12455048.
- Raikos A, Paraskevas GK, Tzika M, Faustmann P, Triaridis S, Kordali P, et al. Sternalis muscle: an underestimated anterior chest wall anatomical variant. *J Cardiothorac Surg.* 2011;6:73. doi: 10.1186/1749-8090-6-73.
- Schulman MR, Chun JK. The conjoined sternalis-pectoralis muscle flap in immediate tissue expander reconstruction after mastectomy. *Ann Plast Surg.* 2005;55(6):672-5. doi: 10.1097/01.sap.0000183940.39898.32.
- Romanes GJ. *Cunningham's Manual of Practical Anatomy.* 15th ed. New York: Oxford University Press; 1986. p. 25-26.
- American Society of Plastic surgeons. 2020. 2020 plastic surgery procedural statistics. [cited 2023 May 9]. Available from: <https://www.plasticsurgery.org/documents/News/Statistics/2020/plastic-surgery-statistics-full-report-2020.pdf>.
- Khan UD. Use of the rectus sternalis in augmentation mammoplasty: case report and literature search. *Aesthetic Plast Surg.* 2008;32(1):21-4. doi: 10.1007/s00266-007-9046-1.
- Kabay B, Akdogan I, Ozdemir B, Adiguzel E. The left sternalis muscle variation detected during mastectomy. *Folia Morphol (Warsz).* 2005;64(4):338-40.
- Ashgar A, Naaz S, Narayan RK, Patra A. The prevalence and distribution of sternalis muscle: a meta-analysis of published literature of the last two hundred years. *Anat Sci Int.* 2022;97(1):110-23. doi: 10.1007/s12565-021-00632-9. Epub 2021 Sep 30.
- O'Neill MN, Folan-Curran J. Case report: bilateral sternalis muscles with a bilateral pectoralis major anomaly. *J Anat.* 1998;193 (Pt 2):289-92. doi: 10.1046/j.1469-7580.1998.19320289.x.
- Kida MY, Izumi A, Tanaka S. Sternalis muscle: topic for debate. *Clin Anat.* 2000;13(2):138-40. doi: 10.1002/(SICI)1098-2353(2000)13:2<138::AID-CA8>3.0.CO;2-4.
- Pillay M, Ramakrishnan S, Mayilswamy M. Two Cases of Rectus Sternalis Muscle. *J Clin Diagn Res.* 2016;10(1):AD01-3. doi: 10.7860/JCDR/2016/17196.7023. Epub 2016 Jan 1.