


Tuberculous Ulcerative Skin Lesion of the Penis: A Case Report

Meilan Xu¹, Fuxiang Fang², Krishna Hamal¹, Shenhui Tang³, Donghua Liu¹ 

¹Department of Dermatology and Venereology, the First Affiliated Hospital of Guangxi Medical University, Nanning, 530021, People's Republic of China; ²Department of Urology, the First Affiliated Hospital of Guangxi Medical University, Nanning, 530021, People's Republic of China; ³The First Affiliated Hospital of Guangxi University of Science and Technology, Liuzhou, 545001, People's Republic of China

Correspondence: Donghua Liu, Department of Dermatology and Venereology, the First Affiliated Hospital of Guangxi Medical University, No. 6, Shuang Yong Road, Nanning, Guangxi, People's Republic of China, Email ldhgxm@163.com

Abstract: Genitourinary tuberculosis (GUTB), especially penile tuberculosis (PTB), is a disease often overlooked by urological specialists, especially in Europe, where the pathology is less frequent. In this report, we described a case of penile tuberculosis (PTB) characterized by ulcers on the penis. After the patient was administered three months of anti-tuberculosis treatment (isoniazid 0.3 g/qd, rifampicin 0.6 g/qw, and ethambutol 0.75 g/qd), the ulcer disappeared. The patient was followed up for seven months and showed no recurrence.

Keywords: Mycobacterium tuberculosis, penile ulcers, dermatopathology, a case report

Introduction

Mycobacterium tuberculosis (*M. tuberculosis*) is responsible for causing infectious tuberculosis (TB). Pulmonary tuberculosis (PTB) is the most prevalent and contagious form of the disease.¹ Up to 45% of patients have extrapulmonary involvement (EPTB).² The urogenital tract is a common site of EPTB.² However, penile involvement (PTB) is extremely rare, constituting less than 1% of all cases of male genital tuberculosis.³ European urologists have limited knowledge of tropical urological diseases, such as GUTB.⁴ This report might allow these urologists to better understand GUTB.

Case

A 57-year-old uncircumcised man presented with painful ulcers on the coronal groove of the penis that persisted for eight months. The condition started as papular lesions and eventually developed into painful ulcers, covered with a yellowish discharge. The patient had no signs of fever, cough, hemoptysis, weakness, weight loss, or any other indicative systemic symptoms. He had no problem with voiding. He had no history of diabetes, oncological comorbidities, immune suppression, renal failure, or tuberculosis. He denied contact with tuberculosis patients. He had no history of preceding trauma, urological surgery, or high-risk sexual behavior; however, his partner was not available for evaluation. The patient initially received oral corticosteroid therapy at a local hospital, but the ulcer did not heal adequately. A physical examination showed multiple well-defined, non-indurated, tender, punched-out ulcers (0.5–1.0 cm in diameter) with ragged, regular margins. Additionally, a floor covered with yellowish discharge was found over the coronal groove of the penis (Figure 1A). No palpable superficial lymphadenopathy and no abnormalities were found after examining the genital system. Other mucocutaneous sites were unaffected, and systemic examination showed unremarkable results.

The results of Gram and Ziehl-Neelsen staining examinations and the culture of the swab taken from the ulcer surface were not significant. The interferon-gamma release assay provided positive results. The Tuberculin Skin Test, which was performed intradermally, demonstrated a 30 mm x 20 mm induration and erythema after 72 h (Figure 2). The results of syphilis and HIV serological tests were negative. Urine microscopy examination showed normal results. Ultrasound examination of the genitourinary system and superficial lymph nodes showed normal results. Chest computed tomography scans revealed linear, patchy, and nodular high-density lesions in the lungs (Figure 3), but *M. tuberculosis* was not

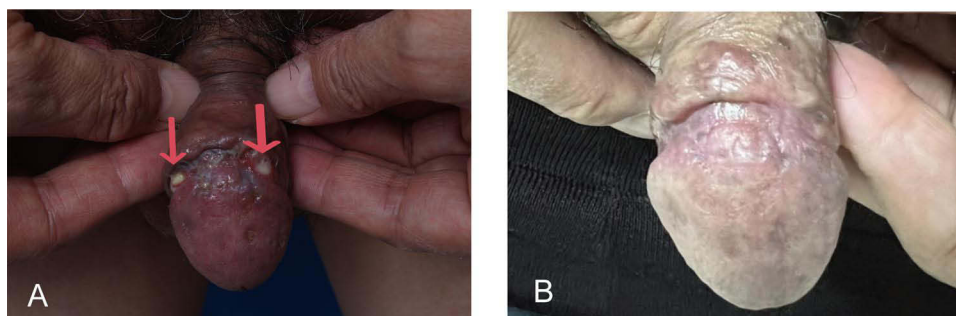


Figure 1 (A) Multiple well-defined, non-indurated, tender, punched-out ulcers (0.5–1.0 cm in diameter) with ragged, regular margins and yellow necrotic slough over the coronal groove of the penis (shown by the red arrows); (B) The ulcer on the penis disappeared, leaving behind irregular scarring after 2 months of anti-tuberculosis treatment.

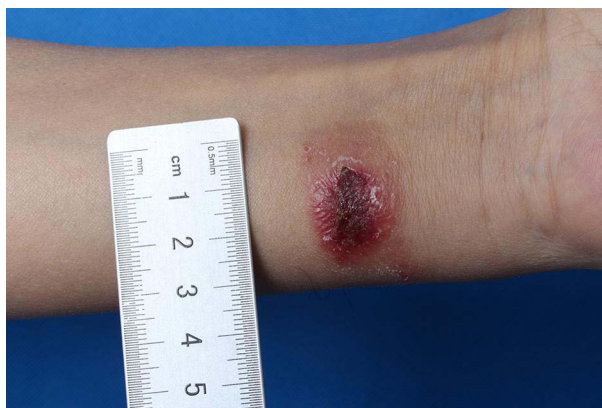

Figure 2 The Tuberculin Skin Test demonstrated a 30 mm x 20 mm induration and erythema after 72 h.

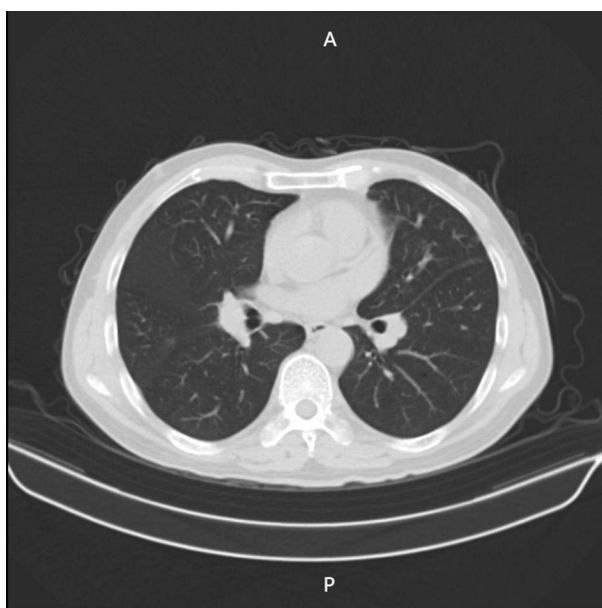


Figure 3 Chest computed tomography scans revealed linear, patchy, and nodular high-density lesions in the lungs.

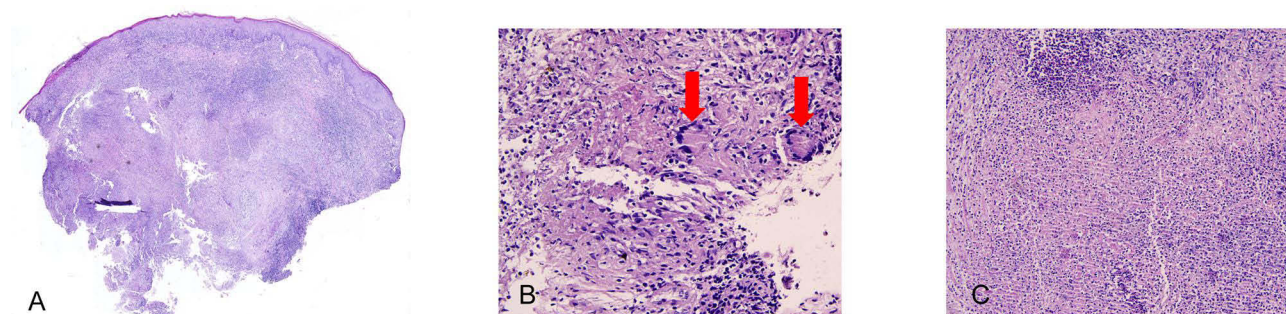


Figure 4 (A) Nodular infiltration of lymphocytes (H&E, ×10); (B) Langhans giant cells in the deep dermis (shown by the red arrows, H&E, ×40); (C) and small foci of caseous necrosis (H&E, ×40).

detected in the genome sequencing examination of bronchoalveolar lavage. The histopathology of lesion tissue biopsy showed nodular infiltration of lymphocytes, Langhans giant cells, and small foci of Caseous necrosis (Figure 4). We classified it as a tuberculous ulcerative skin lesion of the penis based on typical clinical characteristics and results of laboratory tests. The patient was administered three months of anti-tuberculosis treatment with isoniazid 0.3 g/qd, rifampicin 0.6 g/qw, and ethambutol 0.75 g/qd. The ulcer on the penis disappeared, leaving behind depressed and uneven scarring (Figure 1B). The chest CT scan was reviewed, and the results were similar to the previous CT results, ie, no significant changes in the chest CT scan were found after anti-tuberculosis treatment. Therefore, pulmonary tuberculosis was unlikely. No recurrence of the disease occurred after a follow-up of seven months. The patient was recommended regular follow-up.

Discussion

Extrapulmonary tuberculosis (EPTB) can develop in 16% of TB cases. GUTB accounts for 4.6% of EPTB.⁵ However, Tuberculosis of the penis accounting for less than 1% of all cases of GUTB in men.^{3,6} From 1971 to 2007, only 177 cases of primary penile cutaneous tuberculosis were reported,⁷ and just a few cases since then. GUTB is often overlooked by urological specialists, especially in Europe, where the disease is less frequent.² Guglielmo Mantica and Francesca Ambrosini reported that implementing exchange programs or internships in developing countries to increase knowledge regarding GUTB might help address this challenge.⁴

Genitourinary tuberculosis (GUTB) is almost secondary due to the hematogenous spread of chronic latent pulmonary TB (LTBI).² Primary TB and LTBI are its most important risk factors; geographical and social conditions are also important risk factors. Diabetes, old age, low body mass index, oncological comorbidities, immune suppression, and renal failure may increase the risk of reactivation of dormant bacilli.² PTB can manifest as either primary or secondary TB, but overall, most reported cases are associated with primary tuberculosis.⁸ Primary tuberculosis of the penis occurs due to sexual contact with infected partners, infected clothing, or ritual circumcision.⁹ In our patient, a biopsy of the lesion and histological examination of the specimen showed features consistent with tuberculosis, and the patient responded well to antitubercular therapy. Coexisting tuberculosis in any other part of the body was not detected, suggesting primary tuberculosis was possible. The patient in our case was probably caused due to contact with infected clothing.

The diagnosis of GUTB is challenging as it lacks specific symptoms or signs.² Patients frequently present only with nonspecific urological findings, including hematuria, sterile leukocyturia, a high frequency of urination, dysuria, abdominal, lumbar, and suprapubic pain, and, in female patients, menstrual irregularities and pelvic pain.⁵

Diagnosis of TB of the penis is difficult even in TB-endemic countries.⁹ The clinical presentation of penile tuberculosis can vary considerably and manifest as painless nodules, indurated swelling of the glans, single or multiple genital ulcers, fungating growth, and urethral discharge, with or without erectile dysfunction.⁷ In most cases, the lesion appears as a superficial ulcer on the glans or around the corona,³ making it as prone to misdiagnosis as any other disease involving external genital ulcers. Patients may suffer from neoplastic,

infectious, and non-infectious diseases. Neoplastic conditions include basal cell carcinoma, squamous cell carcinoma, lymphoma, Kaposi's sarcoma, Langerhans cell histiocytosis, and metastatic carcinoma. Infectious diseases include herpes simplex virus infection, syphilis, Epstein–Barr (EB) virus-related genital ulcers, sexually transmitted lymphogranuloma venereum, and disseminated histoplasmosis. Non-infectious diseases include lichen sclerosus, lichen planus, pemphigus vulgaris, necrotizing fasciitis, fixed drug eruption, Crohn's disease, and nodular polyarteritis.¹⁰

Several methods need to be used together to diagnose GUTB or PTB. The patient in this study was diagnosed with PTB; supporting evidence included an erythrocyte sedimentation rate (ESR) of 25 mm/h (raised), positive results for the tuberculin skin test and the interferon-gamma release assay, and biopsy of the lesion showed that the histological features matched the characteristics of tuberculosis. Preliminary investigation generally involves histopathological examination of the affected tissue, and in some cases, biopsy may be the only evidence for diagnosis.⁹ Epithelioid cell granulomas are the typical histopathological features. Additionally, caseous necrosis, neutrophilic abscesses, multinucleated giant cells, and dermal fibrosis are also commonly observed.¹¹ Skin biopsy tissue culture is the diagnostic gold standard; however, it is limited by a long duration of culture and the small number of *Mycobacterium tuberculosis* bacteria in the lesions, which results in lower sensitivity.¹² The tuberculin skin test using purified protein derivative has a specificity of 63% and a sensitivity between 33% and 96% for cutaneous tuberculosis. Interferon-gamma release assays showed that the sensitivity and specificity were 92% and 76%, respectively, among individuals with cutaneous TB.¹³ The ESR may or may not be raised in TB.⁹ In cases associated with TB of the kidney and genitourinary tract, sterile pyuria and positive tuberculosis culture related to TB of the genitourinary tract might be detected, but not penile TB.⁹ Histopathology, acid-fast staining, tuberculin skin testing, mycobacterial stains and cultures, and polymerase chain reaction (PCR) are used for the diagnosis of cutaneous TB.¹¹

The World Health Organization (WHO) recommends that anti-tuberculosis treatment should include a daily regimen for six months. The treatment should involve an intensive phase of two months in which isoniazid, rifampicin, pyrazinamide, and ethambutol should be administered, followed by a continuation phase of four months during which isoniazid and rifampicin should be administered.⁵ GUTB patients show relapse in 6.3% to 22% of cases, even after 12 months of medical therapy.² A high relapse rate might be related to a large number of renal TB foci, which are hard to completely sterilize even after treatment.² Recurrence may also occur if the sexual partners are not tested or treated, or if the individuals are affected by multidrug-resistant tuberculosis. The partner of the patient with TB of the penis should be assessed for genital tuberculosis. Additionally, the family and close contacts of the patients should be screened, and those found to have TB should be treated for TB.⁹ Patients with TB should not have intercourse until one month of therapy.⁹ To treat multidrug-resistant TB (resistant to rifampicin and isoniazid), an individualized treatment regimen should be implemented, with the least five effective TB medicines during the intensive phase, including pyrazinamide and four core second-line TB medicines.⁵ Then, a second biopsy and re-culture from the site of TB of the penis should be taken for consideration.⁹ Therefore, TB patients need to be followed up.

Conclusion

In Conclusion, clinicians should consider the possibility of PTB in cases of penile lesions. This report might help European urologists in the diagnosis and treatment of patients with suspected GUTB or PTB.

Abbreviations

GUTB, Genitourinary tuberculosis; PTB, penile tuberculosis; M. tuberculosis, *Mycobacterium tuberculosis*; TB, infectious tuberculosis; EPTB, extrapulmonary tuberculosis; PTB, penile tuberculosis; LTBI, latent pulmonary TB; ESR, erythrocyte sedimentation rate.

Data Sharing Statement

The original contributions presented in the study are included in the article, further inquiries can be directed to the corresponding author.

Ethical Statement and Informed Consent

The study was approved by the Ethics Committee at the First Affiliated Hospital of Guangxi Medical University. The patient provided written consent for the publication of this report.

Acknowledgments

We are extremely grateful to Dr. Donghua Liu (Department of Dermatology and Venereology, the First Affiliated Hospital of Guangxi Medical University) for his selfless assistance throughout the present study.

Author Contributions

All authors made a significant contribution to the work reported, whether that is in the conception, study design, execution, acquisition of data, analysis and interpretation, or in all these areas; took part in drafting, revising or critically reviewing the article; gave final approval of the version to be published; have agreed on the journal to which the article has been submitted; and agree to be accountable for all aspects of the work.

Funding

No funding was received for this study.

Disclosure

The authors declare that the research was conducted in the absence of any commercial or financial relationships that could be construed as a potential conflict of interest.

References

1. Muneer A, Macrae B, Krishnamoorthy S, Zumla A. Urogenital tuberculosis - epidemiology, pathogenesis and clinical features. *Nat Rev Urol*. 2019;16(10):573–598. doi:10.1038/s41585-019-0228-9
2. Mantica G, Ambrosini F, Riccardi N, et al. Genitourinary tuberculosis: a comprehensive review of a neglected manifestation in low-endemic countries. *Antibiotics*. 2021;10(11). doi:10.3390/antibiotics10111399
3. Khan D, Choudhary A, Dutta A, Khan I. Tuberculosis of the glans penis mimicking as carcinoma. *Int J Mycobacteriol*. 2016;5(3):341–342. doi:10.1016/j.ijmyco.2016.04.003
4. Mantica G, Van der Merwe A, Terrone C, et al. Awareness of European practitioners toward uncommon tropical diseases: are we prepared to deal with mass migration? Results of an international survey. *World J Urol*. 2020;38(7):1773–1786. doi:10.1007/s00345-019-02957-7
5. Bausch K, Mantica G, Smith EJ, et al. Genitourinary tuberculosis: a brief manual for urologists on diagnosis and treatment from the European Association of Urology Urological Infections Panel. *Eur Urol Focus*. 2024;10(1):77–79. doi:10.1016/j.euf.2023.07.006
6. Chhonkar A, Tambe S, Aswani Y, Nayak CS. Case series of genital tuberculosis. *Indian J Sex Transm Dis AIDS*. 2017;38(2):183–186. doi:10.4103/ijstd.IJSTD_3_17
7. Toledo-Pastrana T, Ferrándiz L, Pichardo AR, Muniain Ezcurrea MA, Camacho Martínez FM. Tuberculosis: an unusual cause of genital ulcer. *Sex Transm Dis*. 2012;39(8):643–644. doi:10.1097/OLQ.0b013e318251577b
8. Tapsoba AK, Bibi M, Traoré TM, Ayari A, Ben Rhouma S, Nouria Y. Primary tuberculosis of the glans penis: a rare presentation and review of literature. *Urol Case Rep*. 2021;39:101858. doi:10.1016/j.eucr.2021.101858
9. Venyo AK. Tuberculosis of the penis: a review of the literature. *Scientifica*. 2015;2015:601624. doi:10.1155/2015/601624
10. Roett MA, Mayor MT, Uduhiri KA. Diagnosis and management of genital ulcers. *Am Family Phys*. 2012;85(3):254–262.
11. Kaul S, Jakhar D, Mehta S, Singal A. Cutaneous tuberculosis. Part II: complications, diagnostic workup, histopathologic features, and treatment. *J Am Acad Dermatol*. 2023;89(6):1107–1119. doi:10.1016/j.jaad.2021.12.064
12. Barbagallo J, Tager P, Ingleton R, Hirsch RJ, Weinberg JM. Cutaneous tuberculosis: diagnosis and treatment. *Am J Clin Dermatol*. 2002;3(5):319–328. doi:10.2165/00128071-200203050-00004
13. Franco-Paredes C, Marcos LA, Henao-Martínez AF, et al. Cutaneous mycobacterial infections. *Clin Microbiol Rev*. 2018;32(1). doi:10.1128/cmr.00069-18

Infection and Drug Resistance

Dovepress

Publish your work in this journal

Infection and Drug Resistance is an international, peer-reviewed open-access journal that focuses on the optimal treatment of infection (bacterial, fungal and viral) and the development and institution of preventive strategies to minimize the development and spread of resistance. The journal is specifically concerned with the epidemiology of antibiotic resistance and the mechanisms of resistance development and diffusion in both hospitals and the community. The manuscript management system is completely online and includes a very quick and fair peer-review system, which is all easy to use. Visit <http://www.dovepress.com/testimonials.php> to read real quotes from published authors.

Submit your manuscript here: <https://www.dovepress.com/infection-and-drug-resistance-journal>