

Rare Case of *de Novo* 2p15 Microdeletion Syndrome with Deletion Covering *XPO1* and *USP34* Genes Diagnosed in a Child – A Case Report

Gabriela Ręka , Katarzyna Wojciechowska, Monika Lejman

Independent Laboratory of Genetic Diagnostics of the Second Chair of Pediatrics, Medical University of Lublin, Lublin, Poland

Correspondence: Gabriela Ręka, Independent Laboratory of Genetic Diagnostics of the Second Chair of Pediatrics, Medical University of Lublin, Poland, University Children's Hospital, Profesor Antoni Gębala Street 6, Lublin, 20-093, Poland, Tel +48 81 718 52 11, Email gabrysia.reka@gmail.com

Introduction: 2p15p16.1 microdeletion syndrome was described for the first time in 2007. The size of the microdeletion is variable and encompasses several genes, like *XPO1*, *USP34*, *BCL11A*, *REL*, *PAPOLG*, *PEX13*, *COMMD1*, *B3GNT2*, and *EHBPI*. Features of the syndrome include short stature, microcephaly, hypotonia, psychomotor developmental delay, anomalies of the fingers of the upper and lower limbs, dysmorphic features like receding forehead, broad nasal bridge, telecanthus, ptosis, flat philtrum, small mouth with a high, narrow palate and everted lower lip. The precise genotype–phenotype correlation in 2p15 deletion syndrome is not understood. The aim of the study is to present the patient's medical history and the diagnostic process.

Case Presentation: A boy aged 9 was admitted to the Genetic Outpatient Clinic due to dysmorphic features and mild mental retardation. Full lips, broad nasal root, very light hair, excessively developed subcutaneous tissue, joint laxity, postural defect, flat-valgus foot with sandal gap, brachydactyly, and problems with concentration, memory, and counting were found. Diagnosis was based on microarray testing, and copy-number variation analysis was performed using CytoScan 750K array. Genetic imbalance in the form of a deletion within the short arm of chromosome 2 in the 2p15 region (containing 50 kbp) was shown. The microdeletion covers 2 genes: *USP34* and *XPO1*. Parents were not carriers of that mutation.

Conclusion: The phenotypic features presented by the patient were reflected in the genetic test. 2p15 microdeletion syndrome is genetically heterogeneous with possible *de novo* occurrence, as in the presented case. The precise genotype–phenotype correlation in 2p15 deletion syndrome should be widely studied because in the literature there is mainly mentioned 2p15p16.1 syndrome. Even though 2p15 microdeletion syndrome is a rare discovery and its features are mainly mild, it is necessary to pay special attention to them to refer patients to genetic counseling to make an accurate diagnosis.

Keywords: 2p15 microdeletion syndrome, dysmorphism, mental retardation, microarrays, *XPO1*, *USP34*

Introduction

2p15p16.1 microdeletion syndrome (OMIM #612513) was described in 2007.^{1,2} The age of onset of the symptoms is infancy/neonatal.³ The prevalence is below 1/1000000 and it has been described in 30–40 patients so far.^{3,4} The size of the microdeletion is variable and ranges from 570 kB to 5.7 MB (base pairs of deoxyribonucleic acid).³ It encompasses several genes, like *XPO1*, *USP34*, *BCL11A*, *REL*, *PAPOLG*, *PEX13*, *COMMD1*, *B3GNT2*, *EHBPI*. Features and medical problems of the patients with 2p15p16.1 microdeletion syndrome include short stature, microcephaly, brachycephaly, hypotonia, abnormal head shape, variable brain malformations (cortical dysplasia, pachygyria, cerebral atrophy, enlarged ventricles, hypoplasia of the corpus callosum, cerebellum, and pons), bilateral optic nerve atrophy/hypoplasia, frequent upper respiratory infections, pectus excavatum, widely spaced nipples, hypogonadism, small testes, micropenis, cryptorchidism, hydronephrosis, anomalies of the fingers and toes like camptodactyly and arachnodactyly, metatarsus adductus, calcaneo-valgus, spasticity of the lower limbs, dysmorphic features, psychomotor developmental delay, speech and language delay,

nasal speech, feeding difficulties, mental retardation, features of autism spectrum disorder, and behavioral problems/attention deficit disorder.^{1,3,5-12} Asymptomatic elevated fetal hemoglobin (HbF) in 2p15p16.1 microdeletion syndrome is noted in patients with deletion of the *BCL11A* gene.^{1,11,12} Among dysmorphic features described in the literature the following could be enumerated: receding forehead, bitemporal narrowing, telecanthus – widened inner canthal distance, epicanthal fold, short and down-slanting palpebral fissures, ptosis, strabismus, long and straight eyelashes, large ears, low-set ears, posteriorly rotated ears, broad, high, depressed nasal root, prominent nasal tip, retrognathia, smooth long philtrum, small mouth with high, narrow palate, thin upper lip, and everted lower lip. Sensorineural hearing loss, valvular defects, laryngomalacia, and kyphoscoliosis were reported in single patients.^{1,3,5-12} Specific treatment for 2p15p16.1 microdeletion syndrome is not available. In the literature, there is mainly mentioned 2p15p16.1 syndrome, in which deletion covers a larger fragment of the genome than microdeletion of our patient – 2p15. Thus, in 2p15 deletion syndrome, the precise genotype and phenotype correlation is not fully understood.¹³

The aim of the study is to present the patient's medical history and the diagnostic process. Written informed consent for publication of this case report was obtained from the patient and patient's parents.

Case Report

Proband was a boy aged 9 who was referred to the Genetic Outpatient Clinic due to dysmorphic features and mild mental retardation. He came into the world at 39 weeks of the first pregnancy by caesarean section. He was born from the first delivery and had no siblings. The boy received 9 points in Apgar score and weighed 2600 g. Mother was 30 years old at the time of birth of the proband, and she had no health problems. She took vitamins and folic acid during pregnancy. During that time no health problems were noted, except lower length and weight of the fetus at the end of pregnancy. Father was 34 years old at the time of birth of the proband and suffered from hypertension. Parents were not consanguineous (Figure 1). In the neonatal period, the boy had suction problems. He was breastfed for 9 months.

Initially, psychomotor development was normal: sitting in the 6th month, standing in the 9th month, walking in the 12th month. The boy began to signal his needs at the age of 12 months. He had delayed speech development – he started speaking at the age of 4. Clinical features include the following: mild mental retardation, full lips, broad nasal root, very light hair, scar after right inguinal hernia operation, excessively developed subcutaneous tissue, joint laxity, postural defect, flat-valgus foot with sandal gap (Figures 2–5). At the age of 9, when he was first consulted by geneticist, his body weight was 40 kg (75–90th percentile), height 140 cm (75th percentile), BMI = 20.41 (75–90th percentile), and head circumference 53.5 cm (50th percentile).

The boy is under the care of a psychiatrist, neurologist, and psychologist due to mild mental retardation. He goes to integrational primary school to the class equally with age as his peers. The boy has problems with concentration, memory, and counting, but still he is doing quite well at school. Even though he is left-handed, he writes by right hand on computer. He is lively in his behavior and active in sports. Sometimes he has attacks of aggression. In the past, he underwent right inguinal

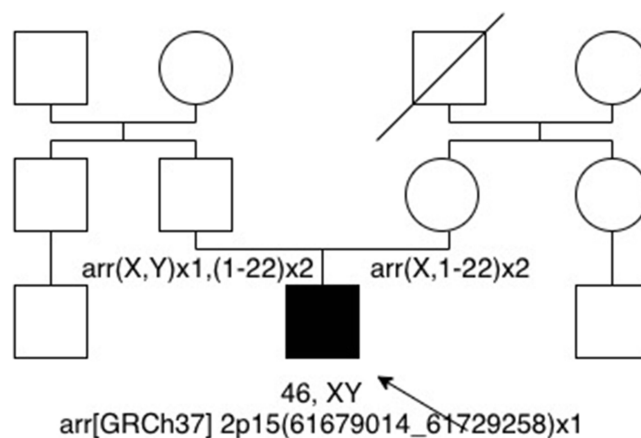


Figure 1 Genetic lineage of the proband's family.

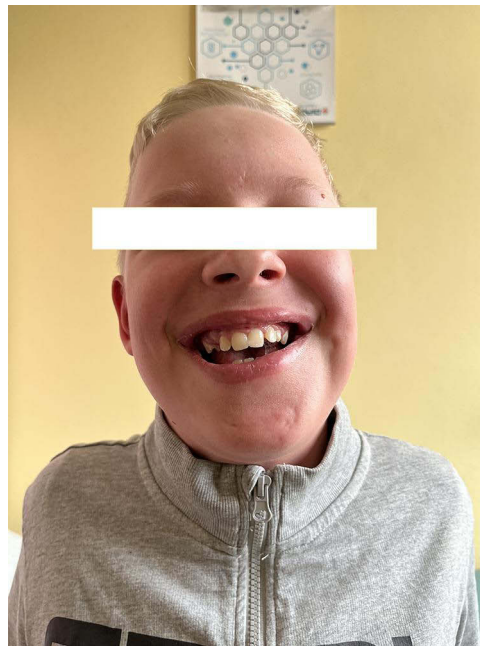

Figure 2 Photograph of the face of the patient with 2p15 microdeletion syndrome – front view. Note characteristic features: broad nasal bridge, smooth philtrum, large mouth, full lips.

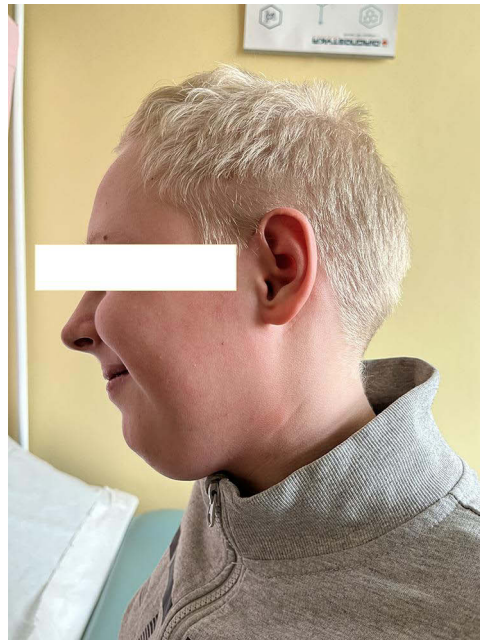

Figure 3 Photograph of the face of the patient with 2p15 microdeletion syndrome – side view. Note characteristic features: sloping forehead, full lips.

hernia surgery, adenectomy, and dilation of the tear ducts. The patient suffers from farsightedness. He had febrile seizures in the past. The boy took chlorprothixene, hydroxyzinum, and later – chlorprothixene and risperidone.

In the Genetic Outpatient Clinic, the diagnosis was confirmed. Cytogenetic studies were conducted, in which normal male karyotype (46, XY) was found. Subsequently, copy-number variation analysis was performed using CytoScan 750K array – microarray-based comparative genomic hybridization (aCGH). Genetic imbalance in the form of a deletion within the short arm of chromosome 2 in the 2p15 region (containing 50 kilobase pair) was found (arr[GRCh37] 2p15

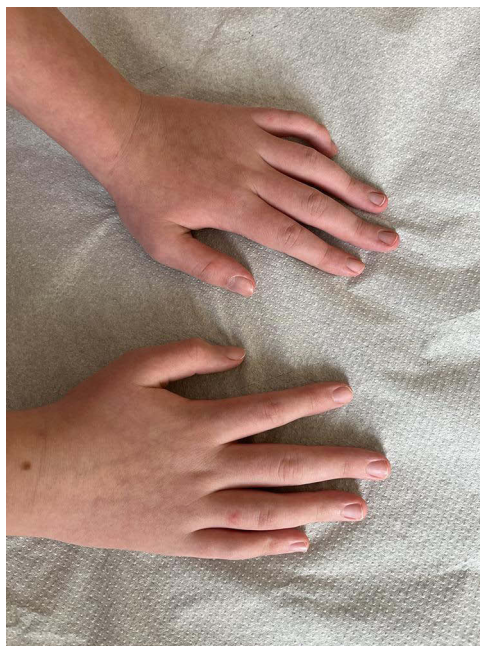

Figure 4 Photograph of hands of the patient with 2p15 microdeletion syndrome. Note characteristic features: long slender fingers.

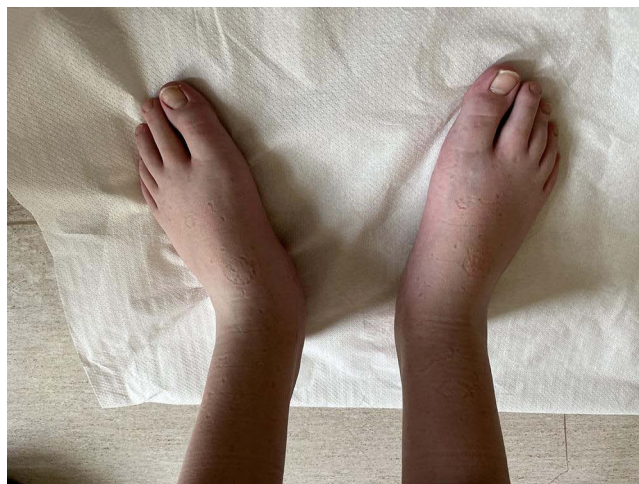


Figure 5 Photograph of the feet of the patient with 2p15 microdeletion syndrome. Note characteristic feature: long slender toes, sandal gap.

(61679014_61729258)x1) (Figures 6 and 7). The aberration covers two genes: *USP34* (OMIM #615295) and *XPO1* (OMIM #602559). Parents were not carriers of that deletion (*de novo* lesion) (Figures 8 and 9).

Discussion

Patients with 2p15p16.1 microdeletion syndrome, in which mutation covers a larger fragment of the genome, are supposed to present more medical problems and dysmorphic features than patients with microdeletion of 2p15. Since our described boy presents symptoms compatible with the phenotypic spectrum of 2p15p16.1 microdeletion syndrome and the deletion overlaps with the known region in genome, the 2p15 deletion could be stated as a reason of his clinical presentation. Peter et al draw attention to the variety of phenotypic features of patients with a microdeletion within 2p15p16.1, which result from the type of gene or genes that have been deleted.¹⁴

USP34 is a gene which encodes ubiquitin-specific peptidase 34 which enables cysteine-type endopeptidase activity and thiol-dependent deubiquitinase. It is involved in a positive regulation of the canonical Wingless-type signaling

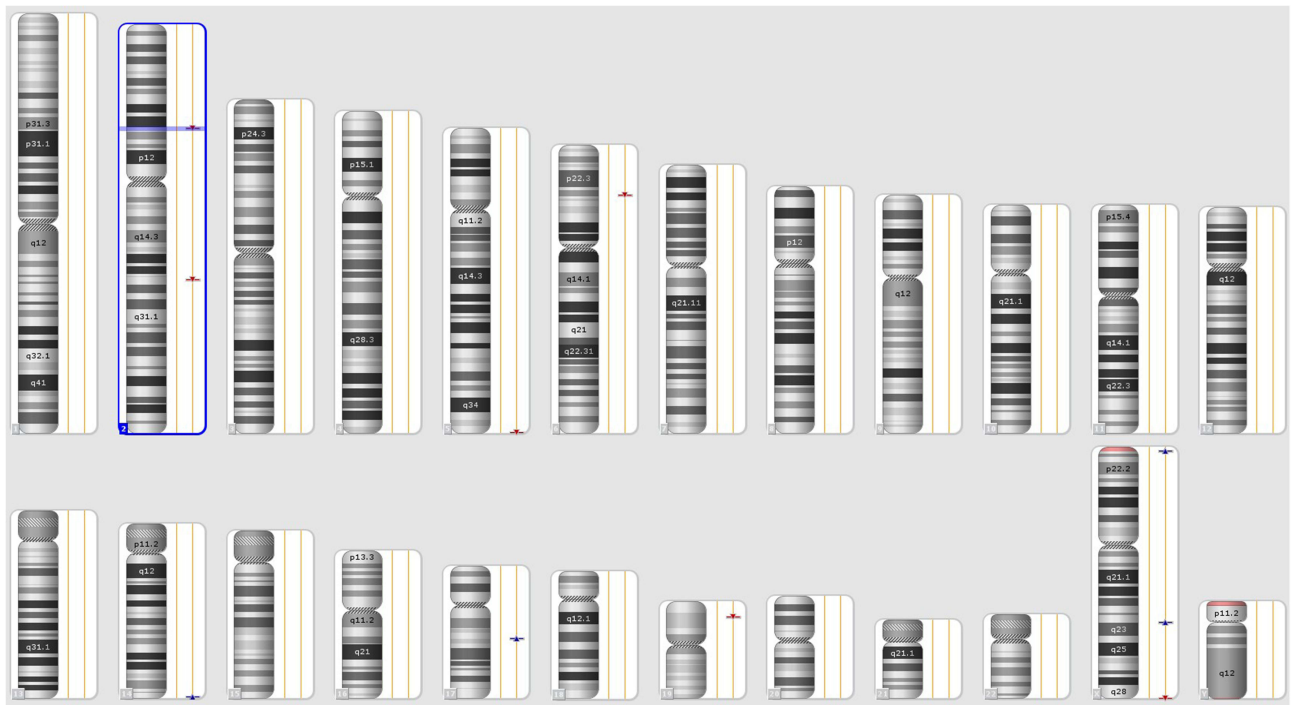

Figure 6 Karyoview of patient's chromosomal microarray results. Note a deletion within the short arm of chromosome 2 in the 2p15 region.

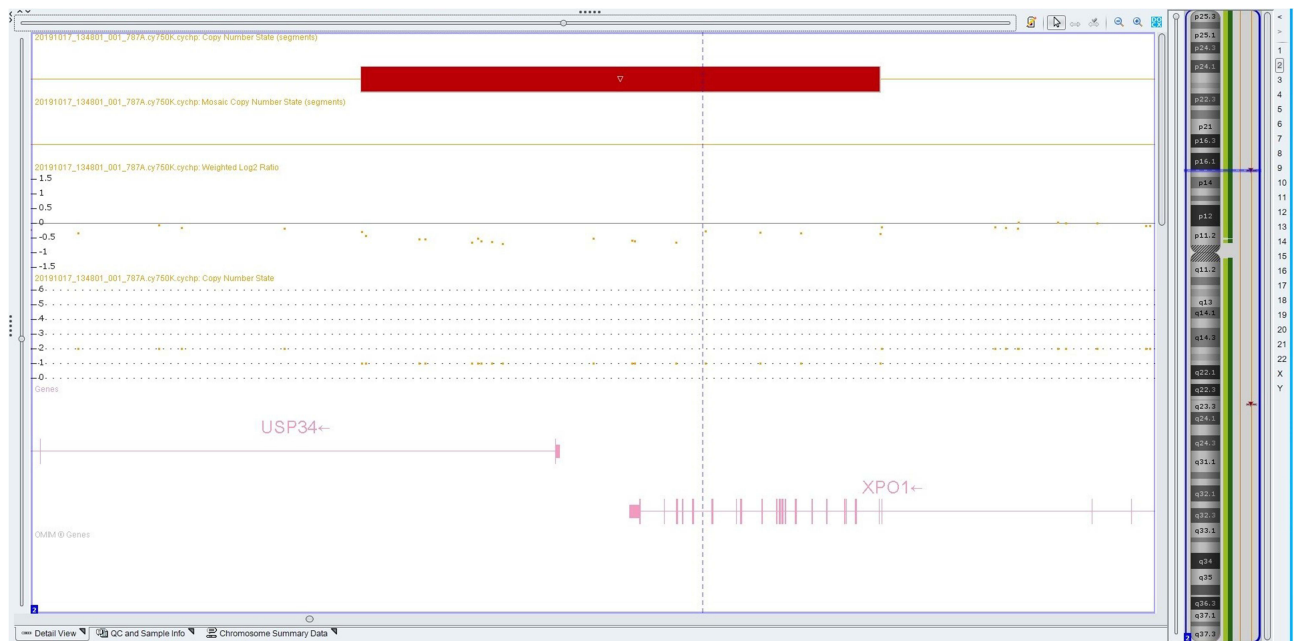


Figure 7 Patient's chromosomal microarray results showing a deletion covering *XPO1* and *USP34* genes (Chromosome Analysis Suite (Chas) Software).

pathway and protein K48-linked deubiquitination.¹⁵ The pathway plays an important role in several developmental processes, such as cell fate specification, cell migration, differentiation, and proliferation during embryonic development and in tissue homeostasis in adults.¹³ The peptidase is predicted to be active in cytosol and nucleus. *USP34* is expressed in brain at a low level and its disruptions might cause developmental defects or diseases, it may influence cell movement and polarity defects, and it may be involved in cancer.¹³

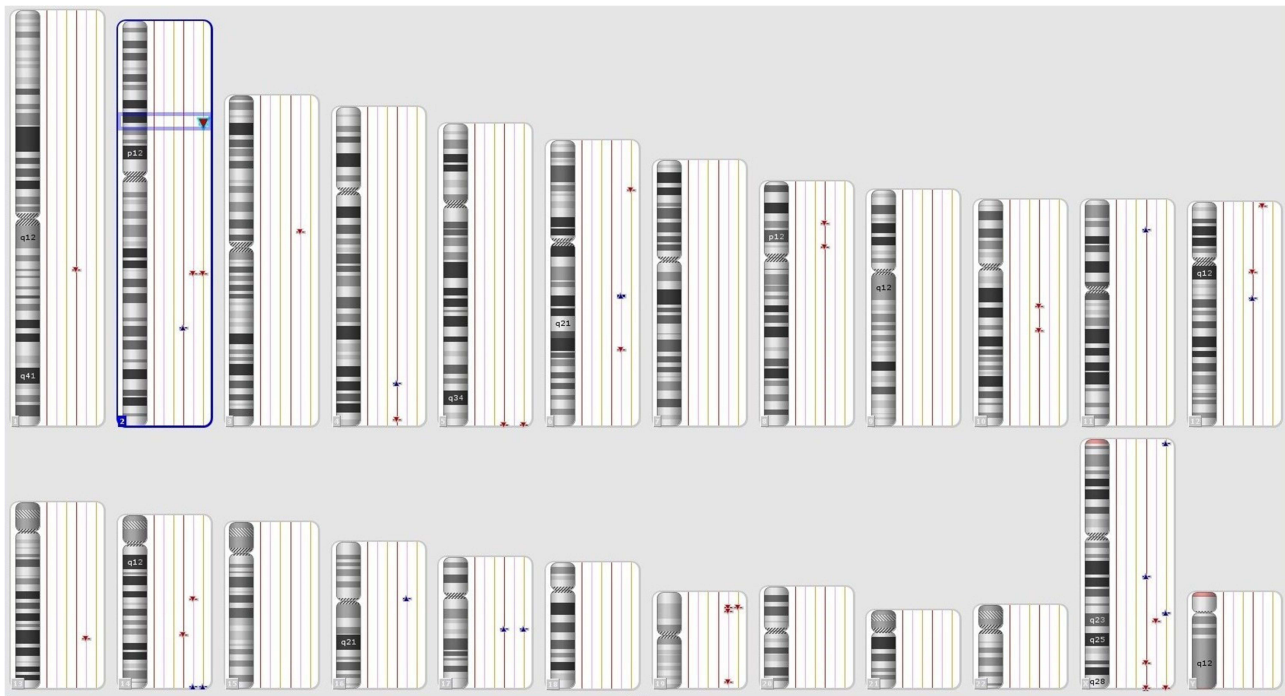


Figure 8 Karyoview of patient's and parents' chromosomal microarray results. Note a deletion within the 2p15 region in patient and no deletion in parents.

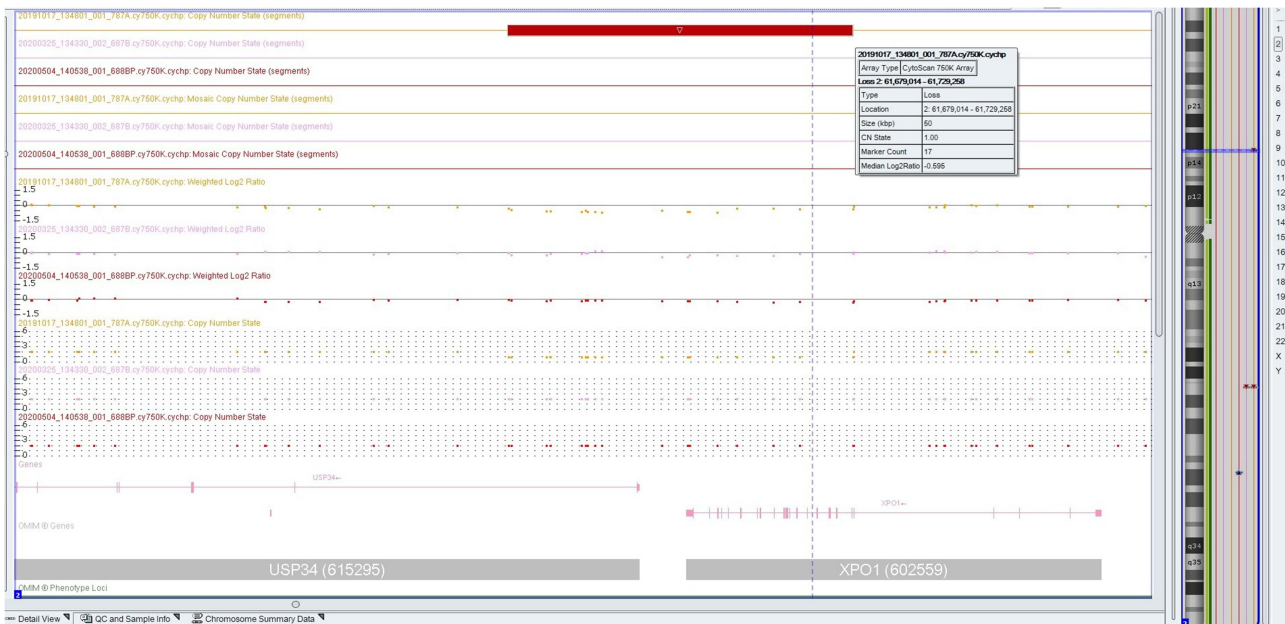


Figure 9 Patient's chromosomal microarray results showing a deletion covering *XPO1* and *USP34* genes and no deletion in parents (Chromosome Analysis Suite (Chas) Software).

XPO1 encodes exportin 1, which mediates leucine-rich nuclear export signal (NES)-dependent protein transport, and it is involved in the export of hundreds cellular molecules, like proteins involved in the proper development of neurons and synapses, ribosomal ribonucleic acid (rRNA), and small nuclear ribonucleic acid (snRNA).^{16,17} *XPO1* is also involved in coordinating mitosis, transcription activation, nuclear transport, and maintaining chromosome structure.¹⁶ It is suggested that

XPO1 might be a key regulator in early embryogenesis. Moreover, single-nucleotide polymorphism in *XPO1* was significantly associated with autism susceptibility. The deletion of *XPO1* might explain the multiple organ anomalies.¹³

The factor causing microdeletion of 2p15 is not known. Fannemel et al reported a case of male with mild intellectual disability and cranio-facial dysmorphisms with haploinsufficiency of *XPO1* and *USP34* by a *de novo* 230 kilobase pair deletion in 2p15. They suggest that haploinsufficiency of one or both genes is likely to be responsible for the phenotype in the disease. The presented patient had facial dysmorphic features like the boy described in our article, who is, to our best knowledge, the second known patient with 2p15 microdeletion syndrome, with deletion covering *XPO1* and *USP34* genes. Both boys had broad nasal bridge, full lower lip, large mouth, smooth philtrum, sloping forehead, long and slender fingers, and language developmental delay. The boy described by Fannemel et al presented also with scoliosis, pectus excavatum, extra nipple, polydipsia, anxiety, obsessive-compulsive disorders, hypermetric, bilateral non-progressive sensorineural hearing loss, and sensitivity to light and loud sounds.¹³

It is stated that interstitial 2p15p16.1 microdeletion is a contiguous gene syndrome with specific phenotypic features.^{10,16} Lévy et al proposed two critical regions at 2p15 and 2p16.1.¹⁶ It was found that the proximal part (2p15) includes *XPO1*, *SNORA70B*, and *USP34* genes, whereas the distal part (2p16.1) accounts among others for *BCL11A*, *PAPOLG*, and *REL* genes.¹⁸ Bagheri et al assessed that the most frequently deleted or disrupted coding genes were *XPO1* and *USP34*, which were noted in more than 70% of cases. They found also that the deletions occurred on maternal and paternal chromosomes, so the effect of imprinting is eliminated.¹⁹ According to Miceli et al, analysis of deletions reported in about 40 patients so far, has led to the identification of four candidate genes (*BCL11A*, *REL*, *USP34*, and *XPO1*) and two critical regions of 2p15p16.1 microdeletion syndrome.²⁰

There is no information in the literature about the potential therapy for 2p15p16.1 microdeletion syndrome. The patient requires multidisciplinary care according to his medical problems. The disease has no promise of improvement.

Conclusions

The genetic change is responsible for the boy's symptoms. Appropriately selected genetic tests confirmed the reason of the patient's phenotypic changes. 2p15 microdeletion syndrome is genetically heterogeneous with possible *de novo* occurrence, as in the described case. Even though 2p15 microdeletion syndrome is a rare discovery and its features are mainly mild, it is necessary to pay special attention to them, to refer patients to genetic counseling to make an accurate diagnosis. The precise genotype-phenotype correlation in 2p15 deletion syndrome should be widely studied because in the literature there is mainly mentioned 2p15p16.1 syndrome. There is a hope that our presented case will contribute to a better understanding of the disease due to clinical investigation of small size deletion.

Abbreviations

NES, nuclear export signal; rRNA, ribosomal ribonucleic acid; snRNA, small nuclear ribonucleic acid.

Ethics Approval and Consent for Publication

This study was approved by the ethics committee of the Medical University of Lublin, Poland (committee's reference number: KE-0254/228/11/2022). Consent of the Head of the University Children's Hospital in Lublin for access to patients' medical documentation was obtained (No. 13/BN/2023 of May 23, 2023). Patient and his parents gave informed consent to tests as well as to use data/material for further anonymous use according to local and national guidelines. Written, informed consent to have the case details and any accompanying images published was obtained from the patient's mother.

Acknowledgments

The authors would like to thank the patient and his parents for participating in this study.

Author Contributions

All authors made substantial contributions to conception and design, acquisition of data, or analysis and interpretation of data; took part in drafting the article or revising it critically for important intellectual content; agreed to submit to the current journal; gave final approval of the version to be published; and agreed to be accountable for all aspects of the work.

Disclosure

The authors report no conflicts of interest in this work.

References

- Mendelian Inheritance in Man, OMIM®. Johns Hopkins University, Baltimore, MD. MIM Number: 612513; 9 August 2016. World Wide Web URL. Available from: <https://omim.org/>. Accessed January 24, 2024.
- Rajcan-Separovic E, Harvard C, Liu X, et al. Clinical and molecular characterisation of a newly recognised microdeletion syndrome involving 2p15-16.1. *J Med Genet.* 2007;44(4):269–276. doi:10.1136/jmg.2006.045013
- Orphanet: an online database of rare diseases and orphan drugs. Copyright, INSERM 1997. Available from: https://www.orpha.net/consor/cgi-bin/OC_Exp.php?lng=en&Expert=261349. Accessed January 24, 2024.
- Shimbo H, Yokoi T, Aida N, et al. Haploinsufficiency of BCL11A associated with cerebellar abnormalities in 2p15p16.1 deletion syndrome. *Mol Genet Genomic Med.* 2017;5(4):429–437. doi:10.1002/mgg3.289
- De Leeuw N, Pfundt R, Koolen DA, et al. A newly recognised microdeletion syndrome involving 2p15p16.1: narrowing down the critical region by adding another patient detected by genome wide tiling path array comparative genomic hybridisation analysis. *J Med Genet.* 2008;45(2):122–124. doi:10.1136/jmg.2007.054049
- Chabchoub E, Vermeesch JR, de Ravel T, et al. The facial dysmorphism in the newly recognised microdeletion 2p15-p16.1 refined to a 570 kb region in 2p15. *J Med Genet.* 2008;45(3):189–192. doi:10.1136/jmg.2007.056176
- Liang JS, Shimojima K, Ohno K, et al. A newly recognised microdeletion syndrome of 2p15-16.1 manifesting moderate developmental delay, autistic behaviour, short stature, microcephaly, and dysmorphic features: a new patient with 3.2 Mb deletion. *J Med Genet.* 2009;46(9):645–647. doi:10.1136/jmg.2008.059220
- Félix TM, Petrin AL, Sanseverino MT, et al. Further characterization of microdeletion syndrome involving 2p15-p16.1. *Am J Med Genet A.* 2010;152A(10):2604–2608. doi:10.1002/ajmg.a.33612
- Prontera P, Bernardini L, Stangoni G, et al. Deletion 2p15-16.1 syndrome: case report and review. *Am J Med Genet A.* 2011;155A(10):2473–2478. doi:10.1002/ajmg.a.33875
- Piccione M, Piro E, Serraino F, et al. Interstitial deletion of chromosome 2p15-16.1: report of two patients and critical review of current genotype-phenotype correlation. *Eur J Med Genet.* 2012;55(4):238–244. doi:10.1016/j.ejmg.2012.01.014
- Basak A, Hancarova M, Ulirsch JC, et al. BCL11A deletions result in fetal hemoglobin persistence and neurodevelopmental alterations. *J Clin Invest.* 2015;125(6):2363–2368. doi:10.1172/JCI81163
- Funnell AP, Prontera P, Ottaviani V, et al. T. 2p15-p16.1 microdeletions encompassing and proximal to BCL11A are associated with elevated HbF in addition to neurologic impairment. *Blood.* 2015;126(1):89–93. doi:10.1182/blood-2015-04-638528
- Fannemel M, Baroy T, Holmgren A, et al. Haploinsufficiency of XPO1 and USP34 by a de novo 230 kb deletion in 2p15, in a patient with mild intellectual disability and cranio-facial dysmorphisms. *Eur J Med Genet.* 2014;57(9):513–519. doi:10.1016/j.ejmg.2014.05.008
- Peter B, Matsushita M, Oda K, et al. De novo microdeletion of BCL11A is associated with severe speech sound disorder. *Am J Med Genet A.* 2014;164A(8):2091–2096. doi:10.1002/ajmg.a.36599
- National Center for Biotechnology Information. Available from: <https://www.ncbi.nlm.nih.gov/gene/9736>. Accessed January 24, 2024.
- Lévy J, Coussement A, Dupont C, et al. Molecular and clinical delineation of 2p15p16.1 microdeletion syndrome. *Am J Med Genet A.* 2017;173(8):2081–2087. doi:10.1002/ajmg.a.38302
- National Center for Biotechnology Information. Available from: <https://www.ncbi.nlm.nih.gov/gene/7514>. Accessed January 24, 2024.
- Cho JY, Lee TK, Kim YM, et al. The first Korean case of 2p15p16.1 microdeletion syndrome, characterized by facial dysmorphism, developmental delay, and congenital hypothyroidism. *J Genet Med.* 2022;19(2):105–110. doi:10.5734/JGM.2022.19.2.105
- Bagheri H, Badduke C, Qiao Y, et al. Identifying candidate genes for 2p15p16.1 microdeletion syndrome using clinical, genomic, and functional analysis. *JCI Insight.* 2016;1(3):e85461. doi:10.1172/jci.insight.85461
- Miceli M, Failla P, Saccuzzo L, et al. Trait-driven analysis of the 2p15p16.1 microdeletion syndrome suggests a complex pattern of interactions between candidate genes. *Genes Genomics.* 2023;45(4):491–505. doi:10.1007/s13258-023-01369-7

The Application of Clinical Genetics

Dovepress

Publish your work in this journal

The Application of Clinical Genetics is an international, peer-reviewed open access journal that welcomes laboratory and clinical findings in the field of human genetics. Specific topics include: Population genetics; Functional genetics; Natural history of genetic disease; Management of genetic disease; Mechanisms of genetic disease; Counselling and ethical issues; Animal models; Pharmacogenetics; Prenatal diagnosis; Dysmorphology. The manuscript management system is completely online and includes a very quick and fair peer-review system, which is all easy to use. Visit <http://www.dovepress.com/testimonials.php> to read real quotes from published authors.

Submit your manuscript here: <https://www.dovepress.com/the-application-of-clinical-genetics-journal>