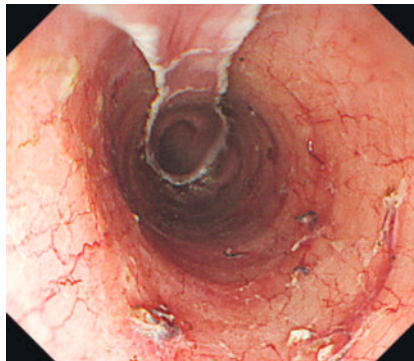


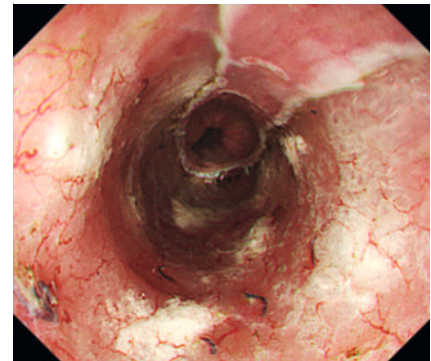
New drug-delivery balloon catheter for easy and fast injection of triamcinolone after esophageal endoscopic submucosal dissection



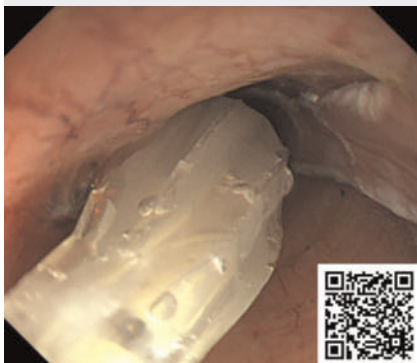► **Fig. 1** Semiperipheral superficial esophageal cancer in the upper thoracic esophagus.



► **Fig. 2** After endoscopic resection, the mucosal defect extended to 7/8 of the circumference.



► **Fig. 3** Post-procedure observation showed that triamcinolone was injected evenly and firmly into the ulcer.



► **Video 1** After resection, the mucosal defect extended to 7/8 of the circumference, and triamcinolone 40mg was injected into the post-treatment ulcer using the new drug-delivery balloon catheter.

Esophageal endoscopic submucosal dissection (ESD) is a very common and useful endoscopic treatment for superficial esophageal cancer [1]. The most common delayed adverse event of esophageal ESD for extensive lesions is stenosis [2]. Local injection of triamcinolone is the most common form of stenosis prevention [3], and the method using a needle is a rather complicated and time-con-

suming procedure. A new drug-delivery balloon catheter is a device with multiple micro holes on its surface that eject fluid from the balloon when the balloon pressure rises.

A man in his 60s underwent ESD for semiperipheral superficial esophageal cancer in the upper thoracic esophagus (► **Fig. 1**). The resected pathology was squamous cell carcinoma, and curative resection was obtained. After resection, the mucosal defect extended to 7/8 of the circumference (► **Fig. 2**), and triamcinolone 40 mg was injected into the post-treatment ulcer using the new drug-delivery balloon catheter (► **Video 1**). The procedure was completed in only a few minutes, and was very safe and simple. Post-procedure observation showed that triamcinolone was injected evenly and firmly into the ulcer (► **Fig. 3**).

A new drug-delivery balloon catheter allows for safe, simple, and quick triamcinolone injection after esophageal ESD.

Endoscopy_UCTN_Code_TTT_1AO_2AG_3AD

Acknowledgement

We would like to thank Kaoru Kamiya, Tatsumichi Fujiwara, Hiroaki Usukura, Katsumi Kanda, Takashi Kato, Tatsuya Okubo, and the rest of the Tokai Medical Products staff.

Conflict of Interest

The authors declare that they have no conflict of interest.

The authors

Takashi Hirose¹, **Hiroyuki Shibata**², **Kazuhiro Furukawa**², **Takeshi Yamamura**², **Takuya Ishikawa**², **Masanao Nakamura**¹, **Hiroki Kawashima**²

1 Department of Endoscopy, Nagoya University Hospital, Nagoya, Japan

2 Department of Gastroenterology and Hepatology, Nagoya University Graduate School of Medicine, Nagoya, Japan

Corresponding author

Takashi Hirose, MD, PhD

Department of Endoscopy, Nagoya University Hospital, 65 Tsurumai-cho, Showa-ku, Nagoya, 466-8550, Japan
taka-h@med.nagoya-u.ac.jp

References

- [1] Inoue H, Minami H, Kaga M et al. Endoscopic mucosal resection and endoscopic submucosal dissection for esophageal dysplasia and carcinoma. *Gastrointest Endosc Clin N Am* 2010; 20: 25–34, v-vi. doi:10.1016/j.giec.2009.08.005
- [2] Ishihara R. Prevention of esophageal stricture after endoscopic resection. *Dig Endosc* 2019; 31: 134–145. doi:10.1111/den.13296
- [3] Miyake M, Ishihara R, Matsuura N et al. Predictors of stricture after non-circumferential endoscopic submucosal dissection of the esophagus and single-dose triamcinolone injection immediately after the procedure. *Gastrointest Endosc* 2023; 98: 170–177. doi:10.1016/j.gie.2023.03.017

Bibliography

Endoscopy 2024; 56: E634–E635

DOI 10.1055/a-2353-5973

ISSN 0013-726X

© 2024. The Author(s).

This is an open access article published by Thieme under the terms of the Creative Commons Attribution License, permitting unrestricted use, distribution, and reproduction so long as the original work is properly cited.

(<https://creativecommons.org/licenses/by/4.0/>)

Georg Thieme Verlag KG, Rüdigerstraße 14,
70469 Stuttgart, Germany



ENDOSCOPY E-VIDEOS

<https://eref.thieme.de/e-videos>



E-Videos is an open access online section of the journal *Endoscopy*, reporting on interesting cases

and new techniques in gastroenterological endoscopy. All papers include a high-quality video and are published with a Creative Commons CC-BY license. Endoscopy E-Videos qualify for HINARI discounts and waivers and eligibility is automatically checked during the submission process. We grant 100% waivers to articles whose corresponding authors are based in Group A countries and 50% waivers to those who are based in Group B countries as classified by Research4Life (see: <https://www.research4life.org/access/eligibility/>).

This section has its own submission website at

<https://mc.manuscriptcentral.com/e-videos>