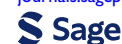

The value of Clinical signs in the diagnosis of Degenerative Cervical Myelopathy - A Systematic review and Meta-analysis

Global Spine Journal
2024, Vol. 14(4) 1369–1394
© The Author(s) 2023
Article reuse guidelines:
sagepub.com/journals-permissions
DOI: 10.1177/21925682231209869
journals.sagepub.com/home/gsj



Zhilin Jiang, BA, MBBS¹, Benjamin Davies, BSc, MPhil, MRCS² , Carl Zipser, MD, FEBN³, Konstantinos Margetis, MD, PhD⁴ , Allan Martin, MD, PhD⁵, Stavros Matsoukas, MD⁴, Freschta Zipser-Mohammadzada, PhD³, Najmeh Kheram, MSc^{3,6}, Andrea Boraschi, MSc⁶ , Elina Zakin, MD⁷, Oke Righteous Obadaseraye, MBBS, MCh, Ortho(UK), FMCOrtho⁸ , Michael G. Fehlings, MD, PhD, FRCSC⁹ , Jamie Wilson, MD¹⁰, Ratko Yurac, MD¹¹ , Chad E Cook, PT, PhD, MBA, FAPTA¹², Jamie Milligan, MD¹³, Julia Tabrah, BSc(Hons) MSc¹⁴, Shirley Widdop¹⁵, Lianne Wood, PhD¹⁶, Elizabeth A. Roberts, MA (Oxon), MSc (Edin)¹⁵ , Tanzil Rujeedawa, BA² , Lindsay Tetreault, MD, PhD⁷, on behalf of the AO Spine RECODE-DCM Diagnostic Criteria Incubator

Abstract

Study Design: Delayed diagnosis of degenerative cervical myelopathy (DCM) is likely due to a combination of its subtle symptoms, incomplete neurological assessments by clinicians and a lack of public and professional awareness. Diagnostic criteria for DCM will likely facilitate earlier referral for definitive management.

Objectives: This systematic review aims to determine (i) the diagnostic accuracy of various clinical signs and (ii) the association between clinical signs and disease severity in DCM?

Methods: A search was performed to identify studies on adult patients that evaluated the diagnostic accuracy of a clinical sign used for diagnosing DCM. Studies were also included if they assessed the association between the presence of a clinical sign and disease severity. The QUADAS-2 tool was used to evaluate the risk of bias of individual studies.

¹ King's College Hospital, NHS Foundation Trust, London, UK

² University of Cambridge, Cambridge, UK

³ Spinal Cord Injury Center, Balgrist University Hospital, Zurich, Switzerland

⁴ Department of Neurosurgery, Icahn School of Medicine at Mount Sinai, New York, NY

⁵ Department of Neurosurgery, University of California Davis, Sacramento, CA, USA

⁶ The Interface Group, Institute of Physiology, University of Zurich, Zurich, Switzerland

⁷ New York University Langone, Department of Neurology, New York, NY, USA

⁸ Department of Surgery, Asaba Specialist Hospital, Asaba, Nigeria

⁹ University of Toronto Division of Neurosurgery and Spinal Program, Toronto, ON, Canada

¹⁰ University of Nebraska Medical Center, Omaha, NE, USA

¹¹ University del Desarrollo, Clinica Alemana de Santiago, Chile

¹² Duke University Medical Center, Durham, NC

¹³ Department of Family Medicine, McMaster University, Hamilton, ON, USA

¹⁴ Hounslow and Richmond Community Healthcare, Teddington, UK

¹⁵ Myelopathy.org, Cambridge, UK

¹⁶ Nottingham University Hospital, Nottingham, UK

Corresponding Author:

Elizabeth A. Roberts, MA (Oxon), MSc (Edin), Myelopathy.org, Pioneer House, Vision Park, Histon, Cambridge CB24 9NL, UK.

Email: recode@myelopathy.org



Creative Commons Non Commercial No Derivs CC BY-NC-ND: This article is distributed under the terms of the Creative Commons Attribution-NonCommercial-NoDerivs 4.0 License (<https://creativecommons.org/licenses/by-nc-nd/4.0/>) which permits non-commercial use, reproduction and distribution of the work as published without adaptation or alteration, without further permission provided the original work is attributed as specified on the SAGE and Open Access pages (<https://us.sagepub.com/en-us/nam/open-access-at-sage>).

Results: This review identified eleven studies that used a control group to evaluate the diagnostic accuracy of various signs. An additional 61 articles reported on the frequency of clinical signs in a cohort of DCM patients. The most sensitive clinical tests for diagnosing DCM were the Tromner and hyperreflexia, whereas the most specific tests were the Babinski, Tromner, clonus and inverted supinator sign. Five studies evaluated the association between the presence of various clinical signs and disease severity. There was no definite association between Hoffmann sign, Babinski sign or hyperreflexia and disease severity.

Conclusion: The presence of clinical signs suggesting spinal cord compression should encourage health care professionals to pursue further investigation, such as neuroimaging to either confirm or refute a diagnosis of DCM.

Keywords

myelopathy, cervical, degenerative disc disease

Introduction

Degenerative cervical myelopathy (DCM) is a progressive spine condition and the most common cause of spinal cord dysfunction worldwide.^{1,2} Patients with DCM can present with subtle, non-specific symptoms in their upper and lower extremities, making it difficult to initially diagnose this condition.^{3,4} Behrbalk et al (2013) determined that the average time to diagnosis of DCM was 2.2 ± 2.3 years and that patients attended an average of 5.2 ± 3.6 physician visits before obtaining a correct diagnosis.⁵ The first line physician was a primary care practitioner in 69% of cases and an orthopedic surgeon in 21% of cases.⁵ DCM was most commonly mistaken for carpal tunnel syndrome or cervical disc radiculopathy without neurological deficit. Similarly, others have reported that the time between symptom onset and surgical evaluation was 17.7 ± 16.0 months.⁶ This delay in diagnosis and assessment by a spinal surgeon has detrimental consequences and can result in incomplete postoperative recovery, impaired quality of life and significant disability including inability to work.^{7,8} DCM is often managed surgically with response to treatment dependent on degree of preoperative functional impairment and duration of symptoms.^{9,10} As such, timely diagnosis and management is critical in order to optimize outcomes.

Patients with DCM complain of symptoms in their upper and lower extremities, including bilateral arm paresthesia, reduced manual dexterity, gait instability, and weakness. Other symptoms include neck pain or stiffness, Lhermitte's phenomena and urinary or fecal urgency or incontinence. On examination, patients with DCM typically present with bilateral motor and/or sensory deficits of the upper and lower extremities without facial involvement, although clinical variations can occur.¹¹ Furthermore, patients with DCM exhibit a combination of upper and lower motor neuron signs (manifestation of the disease that is identified during an examination) as well as abnormalities in the sensation of pain, temperature, proprioception and vibration. Upper motor neuron signs include hyperreflexia below the level of the lesion, Hoffmann sign, upgoing plantar responses, lower limb spasticity, and corticospinal distribution motor deficits.¹¹ Lower motor neuron signs result from compression of the nerve roots

as they exit the spinal canal and commonly include muscle atrophy especially in the hands, muscle fasciculations and weakness. However, patients do not always present with clear signs of DCM, but rather demonstrate nonspecific dissociated sensorimotor deficits and subtle gait disturbances. Furthermore, common comorbidities in patients of typical DCM age, such as carpal tunnel syndrome, radiculopathy and arthritis, may further impede the diagnosis. Therefore, clinical signs of cervical myelopathy (ie spinal cord involvement) are of greatest diagnostic value.

Misdiagnosis or delayed diagnosis of DCM is likely associated with its subtle, non-specific symptoms, incomplete neurological assessments by clinicians and a lack of public and professional awareness.^{12,13} Developing diagnostic criteria for DCM will likely improve diagnosis and was determined as a research priority as part of the AO Spine RECODE-DCM (Research Objectives and Common Data Elements for Degenerative Cervical Myelopathy) project.¹⁴⁻¹⁶ The first step in this process is to identify candidate variables for inclusion in diagnostic criteria. Signs that exhibit high sensitivity and specificity, and those that are correlated with disease severity are likely the most relevant.

A previous systematic review by Cook et al (2011) aimed to evaluate the diagnostic accuracy of various clinical tests by summarizing studies that reported on sensitivity, specificity, and other metrics.¹⁷ This review used the QUADAS (Quality Assessment of Diagnostic Accuracy Studies) tool to assess the external and internal validity of a diagnostic study and evaluate its risk of bias. Based on this scoring system, only a single study by Cook et al (2009) was rated as high quality.¹⁸ This review concluded that the test with the highest sensitivity was the inverted supinator sign (61%), followed by the suprapatellar tendon reflex (56%) and the Hoffmann sign (44%).¹⁷ Although the presence of clonus and the Babinski sign were not sensitive findings, they were the most specific tests (92% and 96%, respectively) for confirming a diagnosis of DCM. This review must be expanded on for the following reasons: (i) the term DCM has been introduced since its publication; (ii) several relevant studies have been conducted since 2011, including some that assess the diagnostic value of novel signs; and (iii) this

review did not assess the relationship between the presence of clinical signs and disease severity.

The objective of this study was to conduct a systematic review of the literature to address the following key questions (KQ):

- KQ1: What is the diagnostic accuracy (ie sensitivity, specificity, positive or negative predictive value, positive or negative likelihood ratio) of clinical signs in patients with DCM?
- KQ2: What is the association between clinical signs and disease severity in patients with DCM?

Materials and Methods

The systematic review was formatted using the Preferred Reporting Items for Systematic Reviews and Meta-Analyses checklist. Neither informed consent nor Institutional Review Board approval were required due to the nature of the study. The review was not registered in PROSPERO or any other similar site.

Eligibility Criteria

Table 1 outlines the eligibility criteria with respect to the population of interest, clinical signs, outcomes and study design.

Population. This review targeted adult patients (>18 years) with cervical myelopathy secondary to spondylosis, disc herniation, ossification of the posterior longitudinal ligament (OPLL), congenital stenosis or spondylosis. Eligible studies consisted of patients treated surgically or managed conservatively. Studies were excluded if they included patients with traumatic spinal cord injury, thoracic or lumbar myelopathy, asymptomatic spinal cord compression, tumor or infection or if they focused only on patients with DCM at a specific level.

Clinical Signs. Studies were included if they discussed a clinical sign used for diagnosing DCM. Clinical signs of interest included, but were not limited to, hyperreflexia, upgoing plantar responses, Hoffmann, clonus and gait abnormalities. Studies were excluded if they only assessed patient symptoms, patient- or clinician-reported outcome measures, or imaging characteristics. Table 2 summarizes definitions of clinical signs and highlights what constitutes a positive test.

Outcome. For KQ1, studies were included if they summarized the sensitivity, specificity, positive or negative predictive value

Table 1. Inclusion and Exclusion Criteria.

Characteristic	Inclusion	Exclusion
Population	Patients with cervical myelopathy secondary to spondylosis, disc herniation, ossification of the posterior longitudinal ligament, congenital stenosis or spondylosis Managed conservatively or surgically Age >18 years	Patient with traumatic spinal cord injury, thoracic or lumbar myelopathy, spondylosis without myelopathy, tumor or infection Patients with asymptomatic spinal cord compression Patients with DCM at a specific level
Clinical signs	Hoffmann Inverted supinator Finger escape Suprapatellar quadriceps Babinski Pectoralis reflex Hyperreflexia (biceps, triceps, quadriceps, ankle) Clonus Gait abnormalities Romberg Other	Patient reported symptoms Patient reported outcome measures (eg NDI, SF-36, VAS, subjective questionnaires) Clinician reported outcome measures (eg mJOA, nurick, walking test, grip dynamometer, GRASSP, GaitRite) Imaging characteristics
Outcome	KQ1: Sensitivity, specificity, positive predictive value, negative predictive value, positive likelihood ratio, negative likelihood ratio KQ2: Disease severity as measured by standardized outcome instruments (eg mJOA, nurick, 30-m walking test, NDI, SF-36)	KQ1: Reliability, responsiveness to change, internal consistency KQ2: Non-standardized outcome instruments (eg subjective rating of symptoms) or imaging findings
Study design	Case-control, cohort, cross-sectional, observational studies KQ1: Studies that report frequency of clinical signs in a cohort of DCM patients KQ1: Studies that include an acceptable control group for comparison (eg individuals with cervical radiculopathy or axial neck pain with no myelopathic symptoms) KQ2: Studies that statistically evaluate the association between the presence of a clinical sign and disease severity	Commentaries or opinions Systematic or narrative reviews Animal or biomechanical studies Studies with <15 patients

NDI, neck disability index; SF-36, short form-36; VAS, visual analog scale; mJOA, modified Japanese Orthopedic Association; GRASSP, graded redefined assessment of strength, sensation and prehension; KQ, key question; DCM, degenerative cervical myelopathy.

Table 2. Description of Clinical Tests.

Clinical Test	Description	Positive Finding
Hoffmann	The examiner stabilizes the middle finger of the patient by holding it just proximal to the distal interphalangeal joint and then flicks it	Abduction of the thumb and flexion of the other fingers
Babinski	The examiner applies stimulation with the blunt end of a tendon hammer to the plantar surface of the foot, moving from laterally to medially from the heel to the first metatarsal	Flexion of the great toe and fanning of the other toes
Tromner	The examiner stabilizes the patient's middle finger by holding it just proximal to the distal interphalangeal joint, in a flexed position. The examiner then taps or flicks the volar surface of the distal middle finger	Hyperreflexia of the index finger or thumb
Hyperreflexia at brachioradialis	The examiner positions the patient's arm with the lateral side upwards and tests the reflex by striking the lower end of the radius, just proximal to the wrist	Brisk and exaggerated contraction of the brachioradialis, causing supination of the forearm
Hyperreflexia at biceps	The examiner slightly supinates the patient's forearm and tests the reflex by striking the biceps tendon	Brisk and exaggerated contraction of the biceps, causing flexion of the elbow
Hyperreflexia at triceps	The examiner places the patient's hand on the contralateral shoulder, keeping it in a flexed position and tests the reflex by striking the triceps tendon	Brisk and exaggerated contraction of the triceps, causing extension of the elbow
Suprapatellar reflex	The examiner takes the weight of 1 of the patient's knee and strikes the suprapatellar tendon	Brisk and exaggerated contraction of the quadriceps tendon, causing extension of the knee
Hyperreflexia at patella	The examiner takes the weight of 1 of the patient's knee and strikes the patellar tendon	Brisk and exaggerated contraction of the quadriceps tendon, causing extension of the knee
Hyperreflexia at achilles	The examiner dorsiflexes 1 of the patient's foot and strikes the achilles tendon	Brisk and exaggerated contraction of the gastrocnemius, causing plantarflexion of the ankle
Hyperactive pectoralis reflex	The examiner strikes the patient's pectoralis tendon in the deltopectoral groove	Adduction and internal rotation of the shoulder
Scapulohumeral reflex	The examiner strikes the spine of the scapula and acromion of the patient in a caudal direction	Elevation of the scapula or abduction of the humerus
Inverted supinator sign	The examiner positions the patient's forearm in a slightly pronated position and strikes the forearm, just proximal to the radial styloid process. Also called the inverted radial reflex	Elbow extension and/or finger flexion
Cross adductor reflex	The examiner positions the patient's legs in abduction and strikes the surface of the adductor tendons which is located on the medial surface of the thigh, proximal to the knee	Hyperreflexia of ipsilateral leg with reflex adduction of contralateral leg
Clonus	The examiner takes the weight of the patient's ankle and quickly dorsiflexes it	Three or more involuntary and rhythmic muscle contractions
Absence of/Hypoactive deep tendon reflexes	The reflexes are tested as described above	Absent tendon reflex or reduced tendon reflex (despite the use of accentuation manoeuvres)
Hand withdrawal reflex	The examiner grasps the patient's palm and strikes the dorsum of the patient's hand with a tendon hammer	Abnormal flexor response
Gait deviation	The patient is asked to walk	Any abnormalities in gait such as spasticity, ataxia or changes in base
Abnormal great toe proprioception	The patient closes his or her eyes and the examiner asks whether the first toe is moved up or down	The patient is not able to tell whether the toe was moved up or down

(continued)

Table 2. (continued)

Clinical Test	Description	Positive Finding
Sensory impairment	The examiner tests 1 or more of the following modalities Light touch – the examiner assesses different areas of the skin using a cotton ball and confirms whether the patient is able to feel the touch and whether it is the same, reduced or increased compared to the sternum or the opposite limb Pain - a sharp object such as a pin is used to test the same areas of the patient's skin Temperature – a cold or warm object is used to test the same areas of the patient's skin Vibration - the examiner places a vibrating tuning fork on the patient's most distal joints and asks whether the patient is able to feel it and when it stops. The examiner moves the tuning fork more proximally if the patient cannot feel the vibration at the most distal joints	The patient has reduced sensation to touch, pain, temperature, vibration and/or proprioception
Motor impairment	The power of all myotomes is assessed	Reduced strength
Pyramidal signs/Upper motor neuron signs	Hyperreflexia or pathological reflexes, increased tone, motor weakness	NA
Myelopathic hand	The power of adduction and extension of the ulnar 2 or 3 fingers is tested by first asking the patient to perform active movements and then testing power against resistance. The examiner then tests the patient's grip by asking him or her to rapidly grip and release with these fingers	Loss of power of adduction and extension of the ulnar 2 or 3 fingers and an inability to rapidly grip and release with these fingers
Wazir	The patients' right wrist is rested in extension, supination and a relaxed position over the examiner's left distal forearm. The examiner then taps at the extended wrist around the palmaris longus tendon.	Exaggerated flexion of fingers, thumb and wrist
Romberg	A patient stands with feet together and eyes closed	The patient sways or fall
Walking romberg	A patient walks 5 meters with their eyes open and then walks 5 meters with their eyes closed	The patient sways or fall
Wasting or atrophy	The examiner observes a patient's muscles	Atrophy of the muscle
Spasticity	The examiner assesses the passive resistance of movement of each muscle	Velocity-dependent increased tone (ie hypertonia)
Finger escape sign	The examiner observes a patient's hand with fingers extended and adducted	Involuntary abduction of the fifth finger due weakness of intrinsic hand muscles
Fasciculations	The examiner observes for involuntary movement of muscles at rest	
Ataxia	Poor muscle control that causes clumsy voluntary movements and impaired coordination	NA
Grip release	The examiner counts the number of grip and release cycles a patient does in 10 seconds	Less than 20 grip and release cycles in 10 seconds
Hyperthesia	The sensation of all dermatomes is assessed	Increased sensitivity to tactile stimulation
Spurling's sign	The examiner extends and laterally flexes the patient's neck and applies axial compression	Pain that radiates down the ipsilateral arm in the direction of the corresponding dermatome
Posterior column dysfunction	Vibration and proprioception is assessed in the upper and lower extremities	Reduced sensation to vibration and proprioception
Spinal tenderness	The examiner palpates the vertebral column	Tenderness to palpation
Orthostatic hypotension	Blood pressure is measured when the patient is supine and standing	

or positive or negative likelihood ratio of a clinical sign. In some cases, sensitivity was calculated from the frequency of a clinical sign in a DCM population. [Table 3](#) provides definitions and equations for metrics of diagnostic accuracy.

For KQ2, studies were included if they evaluated the association between the presence of a clinical sign and disease severity, as measured using an appropriate outcome instrument.

Table 3. Definitions and Equations for Metrics of Diagnostic Accuracy.

Metric of Diagnostic Accuracy	Definition	Pearls	Relevant Equations
Sensitivity	How often a test is correctly positive in individuals with a particular disease	Important for ruling out individuals who do not have the disease	$Sensitivity = \frac{TP}{TP+FN}$
Specificity	How often a test is correctly negative in individuals who do not have a particular disease	Important for ruling in individuals who have the disease	$Specificity = \frac{TN}{TN+FP}$
Positive predictive value	The percentage of patients with a positive test who actually have the disease	The higher the disease prevalence, the higher the PPV of the test for the disease	$PPV = \frac{TP}{TP+FP}$
Negative predictive value	The percentage of patients with a negative test who do not have the disease	The lower the disease prevalence, the higher the NPV of the test for that disease	$NPV = \frac{TN}{TN+FN}$
Positive likelihood ratio	The probability that a positive test would be expected in a patient with the disease, divided by the probability that a positive test would be expected in an individual without the disease	How much the probability of the disease is increased if the test result is positive	$LR+ = \frac{Sensitivity}{1-Specificity}$
Negative likelihood ratio	The probability that a negative test would be expected in a patient with the disease, divided by the probability that a negative test would be expected in an individual without the disease	How much the probability of the disease is decreased if the test result is negative	$LR- = \frac{1-Sensitivity}{Specificity}$

TP, true positive; FN, false negative; FP, false positive; PPV, positive predictive value; NPV, negative predictive value; TN, true negative; LR+, positive likelihood ratio; LR-, negative likelihood ratio.

Study Design. For KQ1, this review targeted studies that (i) summarized the frequency of clinical signs in a cohort of DCM patients or (ii) compared the frequency of clinical signs between DCM patients and a control group. An example of an appropriate control group is a group of individuals with cervical radiculopathy or axial neck pain with no myelopathic symptoms. For KQ2, this review aimed to identify studies that statistically evaluated the association between a clinical sign and a measure of disease severity. Studies were excluded if they were commentaries, opinions, animal or biomechanical studies, review articles or surveys or if they consisted of less than 15 patients.

results on diagnostic accuracy; and results on the association between clinical signs and DCM severity. For each clinical sign, true and false positives and negatives were extracted, allowing for the calculation of sensitivity, specificity, positive and negative predictive values and likelihood ratios. In some cases, our calculations for these metrics of diagnostic accuracy differed from those reported in the primary study. Data were not extracted on potential clinical signs that could not be distinguished from symptoms based on full text analysis (eg “sensory abnormalities,” “gait difficulties,” “upper or lower extremity weakness.”)

Search, Study Selection and Data Collection Process

Studies were identified using 2 electronic databases: MEDLINE and Cumulative Index to Nursing and Allied Health Literature. The last search was performed on June 29, 2021. A detailed search strategy was developed. The strategy was first developed in MEDLINE and then appropriately modified for the other database. Only studies involving humans and written in English were considered for inclusion.

All titles and abstracts were evaluated in a standardized manner by 2 independent reviewers. The abstracts were sorted based on predefined inclusion criteria. Full text investigation was completed for potentially relevant studies. Disagreement between reviewers was resolved through discussion. The search strategy is illustrated in Appendix 1.

The following data were collected from each included article: inclusion and exclusion criteria; demographics of both patients and controls; clinical signs and relevant definitions;

Risk of Bias in Individual Studies

The upgraded QUADAS-2 tool is a 11-question instrument used to evaluate the quality of diagnostic accuracy studies.¹⁹ This tool was used in this review in order to assess the risk of bias of individual studies. To apply the QUADAS-2 tool, the evaluator must answer “yes,” “no” or unclear” to 11 questions within 4 domains. In this review, the studies were rated as having “low” risk of bias if less than 4 questions were answered “no” or “unclear,” “moderate” risk if 4 to 8 questions were answered “no” or “unclear” and “high” risk if more than 8 questions were answered “no” or “unclear.”

Data Analysis

Forest plots were created using RevMan. From each article, we extracted the number of patients who had the disease and tested positive (true positive), did not have the disease and

tested positive (false positive), had the disease and tested negative (false negative), and did not have the disease and tested negative (true negative). From these values, sensitivity and specificity were computed and plotted. In some studies, we estimated each value using prevalence data in combination with reported sensitivity and specificity. In other studies, only true positives were reported. The 95% confidence intervals for sensitivity and specificity were automatically generated by RevMan using standard error.

Results

Study Selection

The search yielded a total of 1709 citations. An additional 151 studies were identified from a scoping review and by searching reference lists. Eighteen duplicate studies were removed. After abstract and title review, 1589 records were excluded. Two hundred and fifty-three studies were retrieved for full text investigation. Of these, eleven satisfied inclusion and exclusion criteria and had an appropriate control group. An additional 61 studies reported on frequency of clinical signs in a cohort of DCM patients and were also included. Commonly, studies were excluded if they (i) discussed cervical spine pathology in asymptomatic individuals; (ii) were systematic or narrative reviews; (iii) evaluated the association

between clinical signs and specific levels of spinal cord compression; and (iv) assessed the diagnostic accuracy of patient- or clinician-reported outcome measures (Figure 1).

Study Characteristics. For KQ1, the search identified eleven studies that discussed the diagnostic accuracy of various clinical signs (Table 4, Figures 2, 3, 4).^{18,20-29} Sample sizes ranged from 45 to 7629. The most commonly reported clinical signs were Hoffmann (82%), Babinski (45%), hyperreflexia (36%) and inverted supinator sign (36%). All studies calculated sensitivity and specificity for at least 1 sign. Control groups included normal volunteers and patients with cervical spine complaints but no signs of myelopathy or evidence of cord compression. Of the included studies, 55% were prospective^{18,20-23,26} and 45% were retrospective.^{24,25,27-29} Sensitivity was calculated from 61 studies that reported on the frequency of clinical signs in a cohort of patients with DCM.^{10,30-89}

For KQ2, the search identified 5 studies that evaluated the association between various clinical signs and disease severity as measured by the JOA (n = 3),^{32,35,88} Nurick (n = 2),^{20,88} mJOA (n = 1),³⁶ European Myelopathy Score (EMS) (n = 1),⁸⁸ Prolo Score (n = 1)⁸⁸ and Cooper Myelopathy Scale (CMS) (n = 1).⁸⁸ The clinical signs that were discussed in these studies were Hoffmann (n = 4), Babinski (n = 4), hyperreflexia (n = 3), clonus (n = 2), inverted supinator sign (n = 1),

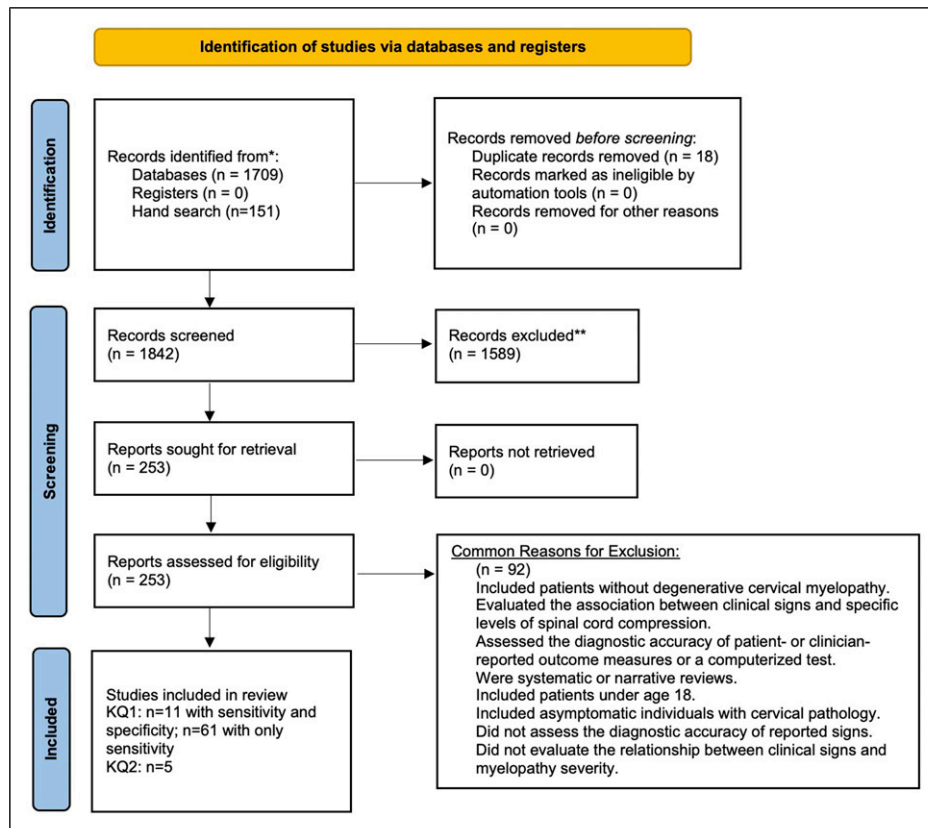


Figure 1. An overview of the search process.

Table 4. Summary of Studies That Included a Control Group and Assessed the Diagnostic Accuracy of Various Clinical Signs.

Author (Year), Study Design, QUADAS-2 (Risk of Bias) ¹⁰⁰	Objective	Cervical Myelopathy and Control Group	Demographic Information	Clinical Signs	Metrics of Diagnostic Accuracy Assessed
Rhee et al (2009), prospective, 4 (moderate)	To determine the prevalence and utility of commonly tested myelopathic signs in surgically treated patients with cervical myelopathy	<p>Cervical myelopathy group (n = 39)</p> <ul style="list-style-type: none"> - History of myelopathic symptoms (upper extremity clumsiness, gait instability, nondermatomal numbness or weakness) - Presence of correlative spinal cord compression on advanced imaging - Treated with surgical decompression - Postoperative improvement in the modified nurick score of at least 1 point <p>Control group (n = 37)</p> <ul style="list-style-type: none"> - Neck pain or radicular arm complaints - No myelopathic symptoms - No evidence of cervical cord compression on advanced imaging - No history of previous spine surgery 	<p>Cervical myelopathy group (n = 39)</p> <p>Age: 58 years Men: 56%</p> <p>Cord signal change: 51%</p> <p>Nurick preoperative: 2.6</p> <p>Control group (n = 37)</p> <p>Age: 48 Men: 49%</p> <p>Cord signal change: 0%</p> <p>Nurick preoperative: N/A</p>	<p>Hyperreflexia (biceps, triceps, brachioradialis, patella, achilles)</p> <p>Hoffmann</p> <p>Inverted brachioradialis</p> <p>Sustained clonus</p> <p>Babinski</p>	<p>Sensitivity</p> <p>Specificity</p> <p>Positive and negative predictive value^a</p> <p>Positive and negative likelihood ratio^a</p>
Cook et al (2010), prospective, 5 (moderate)	To produce a cluster of predictive clinical findings for a sample of patients with cervical myelopathy	<p>Cervical myelopathy group (n = 88)</p> <ul style="list-style-type: none"> - Diagnosis made by careful consideration of presenting symptoms, physical examination and imaging findings <p>Control group (n = 161)</p> <ul style="list-style-type: none"> - Cervical spine pain or dysfunction without image evidence of cervical myelopathy 	<p>Cervical myelopathy group (n = 88)</p> <p>Age: 56.9±12.5 Men: 54.5%</p> <p>NDI, % disability: 40.3±19.4%</p> <p>SF-12: 42.9±7</p> <p>Control group (n = 161)</p> <p>Age: 53.3±15.6 Men: 46.6%</p> <p>NDI, % disability: 40.4±18.5%</p> <p>SF-12: 45.4±6.7</p>	<p>Hoffmann</p> <p>Clonus</p> <p>Babinski</p> <p>Gait deviation</p> <p>Hyperreflexia (biceps, quadriceps, achilles)</p> <p>Inverted supinator sign</p>	<p>Sensitivity</p> <p>Specificity</p> <p>Positive and negative predictive value^a</p> <p>positive and negative likelihood ratio</p>
Cook et al (2009), prospective, 2 (low)	To assess reliability and diagnostic accuracy of neurological tests associated with cervical myelopathy	<p>Cervical myelopathy group (n = 18)</p> <ul style="list-style-type: none"> - Cervical spine pain with signal intensity changes on MRI confirming the presence of myelomalacia <p>Control group (n = 27)</p> <ul style="list-style-type: none"> - Cervical spine pain without MRI evidence of myelomalacia 	<p>Age: 52±13.4 Men: 41%</p>	<p>Hoffmann</p> <p>Hyperreflexia of biceps or triceps</p> <p>Inverted supinator sign</p> <p>Suprapatellar quadriceps</p> <p>Hand withdrawal reflex</p> <p>Babinski</p> <p>Clonus</p>	<p>Sensitivity</p> <p>Specificity</p> <p>Positive and negative predictive value^a</p> <p>positive and negative likelihood ratio</p>

(continued)

Table 4. (continued)

Author (Year), Study Design, QUADAS-2 (Risk of Bias) ¹⁰⁰	Objective	Cervical Myelopathy and Control Group	Demographic Information	Clinical Signs	Metrics of Diagnostic Accuracy Assessed
Chaiyamongkol et al (2017), prospective, 5 (moderate)	To investigate the significance of the trommer sign and how its presence correlates with the severity of cervical myelopathy	Cervical myelopathy group (n = 36) - Clinical symptoms and physical signs of cervical myelopathy, including loss of hand dexterity, gait dysfunction, motor/sensory dysfunction and long tract signs - Evidence of corresponding cervical cord compression Control group (n = 14) - Normal volunteers and patients seeking orthopedic care for non-spine related issues	Cervical myelopathy group (n = 36) Age: 59±9.9 Men: 77.8% Control group (n = 14) Age: 53.5±10.3 Men: 21.4%	Hoffmann Trommer Inverted radial reflex Babinski	Sensitivity Specificity ^a Positive and negative predictive value Positive and negative likelihood ratio ^a
Chang et al (2011), prospective, 3 (low)	To evaluate and quantify the trommer sign and compare its parameters to the severity of cord compression in patients with cervical myelopathy	Cervical myelopathy group (n = 46) - Sensory impairment, muscular weakness or associated hyperreflexia in upper and lower extremities - MRI evidence of cord compression Control group (n = 30) - Age matched healthy spouses of patients	Not reported	Trommer Hoffmann	Sensitivity Specificity ^a Positive and negative predictive value ^a Positive and negative likelihood ratio ^a
Harrop et al (2010), retrospective, 5 (moderate)	To correlate clinical findings of myelopathic signs to cervical MRI features of cord compression and parenchymal changes on T2-weighted images	Cervical myelopathy group (n = 54) - Presence of >1 long tract sign localized to the cervical spine, including hoffmann, babinski, clonus, hyperreflexia, crossed abductor and gait dysfunction Control group (n = 49) - Referred for symptomatic cervical spine disease but without myelopathic signs	Cervical myelopathy group (n = 54) Age: 56.9 Men: 44% Control group (n = 49) Age: 49.5 Men: 47%	Gait abnormality Hyperreflexia (LE or UE) LE hyperreflexia UE hyperreflexia Babinski Hoffmann Cross-abductor Sensory loss Hoffmann	Sensitivity Specificity ^b Positive and negative predictive value ^b
Cao et al (2019), retrospective, 3 (low)	To analyze the correlation between the hoffmann sign and cervical pathology in symptomatic patients; to calculate the sensitivity, specificity, and positive and negative predictive values of the hoffmann sign for cervical pathology	Cervical myelopathy group (n = 86) ⁸ - Referred for complaints related to the cervical spine - Image evidence of spinal cord compression Control group (n = 21) - Referred for complaints related to the cervical spine - No image evidence of spinal cord compression	Not reported	Hoffmann	Sensitivity Specificity Positive and negative predictive value Positive and negative likelihood ratio ^a
Glaser et al (2001), prospective, 2 (low)	To evaluate the hoffmann sign as a screening tool for radiographic evidence of cervical spinal cord compression	Cervical myelopathy group (n = 48) ⁸ - Referred for complaints related to the cervical spine - Image evidence of spinal cord compression Control group (n = 76) - Referred for complaints related to the cervical spine - No image evidence of spinal cord compression	Not reported	Hoffmann	Sensitivity Specificity Positive and negative predictive value Positive and negative likelihood ratio ^a

(continued)

Table 4. (continued)

Author (Year), Study Design, QUADAS-2 (Risk of Bias) [∞]	Objective	Cervical Myelopathy and Control Group	Demographic Information	Clinical Signs	Metrics of Diagnostic Accuracy Assessed
Grijalva et al (2015), retrospective, 6 (moderate)	To examine the relationship between hoffmann sign and cervical pathology in symptomatic patients	Cervical myelopathy group (n = 53) [∞] - Neck pain or radicular arm complaints - Image evidence of spinal cord compression Control group (n = 118) - Neck pain or radicular arm complaints - No image evidence of spinal cord compression	Not reported	Hoffmann	Sensitivity Specificity Positive and negative predictive value Positive and negative likelihood ratio ^a
Archer et al (2020), retrospective analysis of prospective data, 9 (high)	To develop and validate prediction models for patient-reported disability, pain and myelopathy outcomes at 12 months in patients undergoing cervical spine surgery	Cervical myelopathy group (n = 264) - No definition Control group (n = 4988) - Cervical radiculopathy	Cervical myelopathy group (n = 264) Age: 60.4±11.4 Men: 53% Current smoker: 21% Baseline mJOA 12.4±2.8 Control group (n = 4988) Age: 54.6±11.0 Men: 50% Current smoker: 20%	Motor deficit; undefined	Sensitivity Specificity ^a Positive and negative predictive value ^a Positive and negative likelihood ratio ^a
Phillips 1975, retrospective, 6 (moderate)	To assess clinical differences between patients with cervical spondylosis with brachial neuritis and those with cervical myelopathy	Cervical myelopathy group (n = 151) - Not defined Control group (n = 50) - Cervical spondylosis with brachial neuritis - No involvement of the lower limbs (ie no long tract compression in the spinal cord) - Symptoms and signs confined to the neck, shoulder girdle and upper limb - Predominant feature being pain in the upper limb or brachial neuralgia	Cervical myelopathy group (n = 151) Age: 57 Duration of symptoms: 2.15 years Control group (n = 50) Age: 47.5 Duration of symptoms: 2.7 years	Motor impairment Sensory impairment Absence of deep tendon reflexes Weakness and wasting of shoulder girdle and deltoid muscles	Sensitivity Specificity ^a

N/A, not applicable; NDI, neck disability index; SF-12, Short Form 12; MRI, magnetic resonance imaging; LE, lower extremity; UE, upper extremity; mJOA, modified Japanese Orthopedic.

[∞]QUADAS-2 is scored out of 11. Low risk of bias = zero to 3, moderate risk of bias = 4 to 8 and high risk of bias = 9 to 11.

^aAnterior-posterior width reduction, cross-sectional evidence of cord compression, obliteration of the subarachnoid space and signal intensity changes to the cord were considered the most important imaging parameters for confirmation of DCM.

^bNot reported in study but calculated using control group.

^conly reported for sensory loss. It was assumed that patients with a combination of cervical spine complaints and image evidence of spinal cord compression had cervical myelopathy

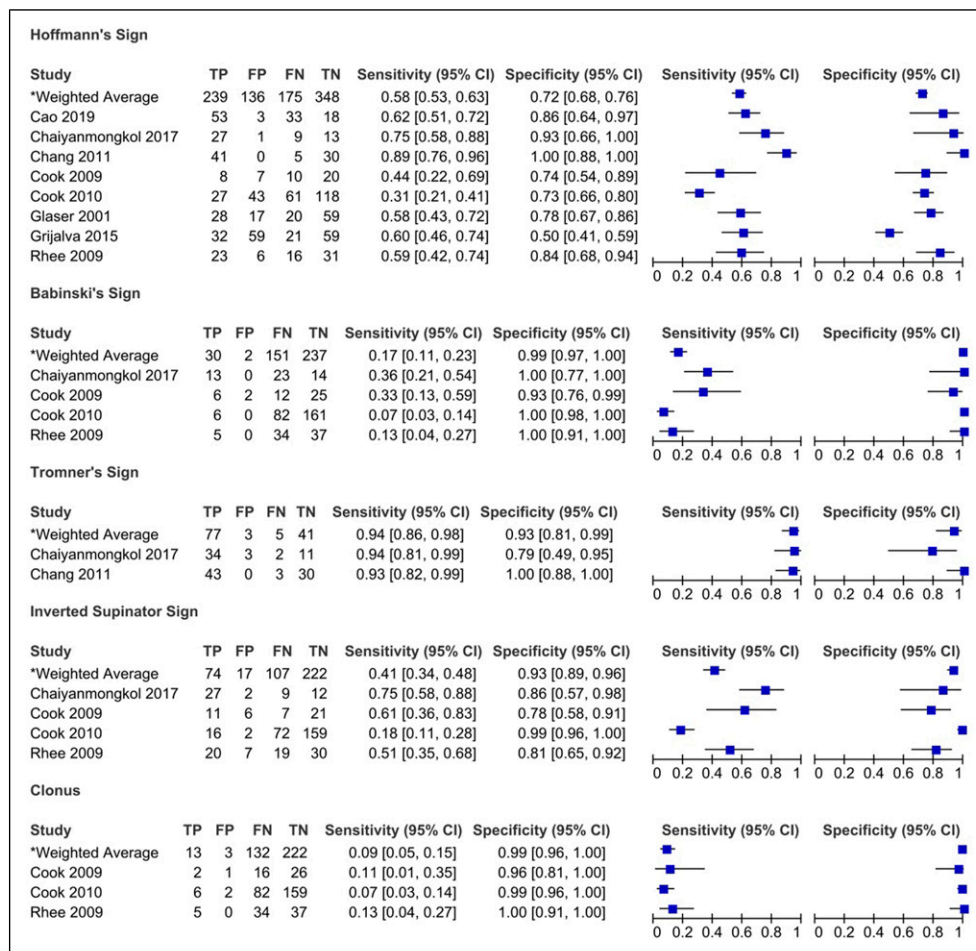


Figure 2. Sensitivity and specificity of pathological reflexes in degenerative cervical myelopathy: Results of eleven studies that included a control group.

dysdiadochokinesia (n = 1), pathological reflexes (n = 1), hypertonia (n = 1), paresis of the upper and lower extremity (n = 1) and great toe proprioception (n = 1).

Risk of Bias of Individual Studies. The QUADAS-2 scoring system was applied to the eleven studies that discussed diagnostic accuracy of various signs and included a control group. The risk of bias was deemed to be low in 4 studies,^{18,23,25,26} moderate in 6^{20-22,24,27,29} and high in 1.²⁸

Results of Individual Studies

KQ1. What is the diagnostic accuracy (i.e. sensitivity, specificity, positive or negative predictive value, positive or negative likelihood ratio) of clinical signs in patients with DCM?

Studies that included a control group. Rhee et al (2009) compared the prevalence of various myelopathic signs between a cervical myelopathy group and a control group (patients with

neck pain or radicular arm complaints with no image evidence of spinal cord compression or history of previous cervical surgeries).²⁰ Based on their results, patients with cervical myelopathy were more likely to exhibit any myelopathic (79% vs 57% in control group) or provocative sign (Hoffmann 59% vs 16%; inverted supinator sign 51% vs 19%; Babinski 13% vs 0%; and clonus 13% vs 0%) than individuals in the control group. In contrast, there were no significant differences in the frequency of hyperreflexia between the myelopathy and control groups.²⁰ Interestingly, 21% of patients diagnosed with cervical myelopathy, and ultimately treated surgically, demonstrated no myelopathic signs on examination. Biceps hyperreflexia had the highest sensitivity (62%), followed by Hoffmann sign (59%) and inverted brachioradialis (51%). In contrast, the sensitivities of Babinski (13%), clonus (13%) and hyperreflexia of the brachioradialis (21%) were low. The majority of myelopathic signs were specific, especially Babinski (100%) and clonus (100%).

Cook et al published 2 studies that evaluated the diagnostic accuracy of various clinical signs.^{18,21} In the 2009 study, patients were recruited if their primary complaint was cervical pain

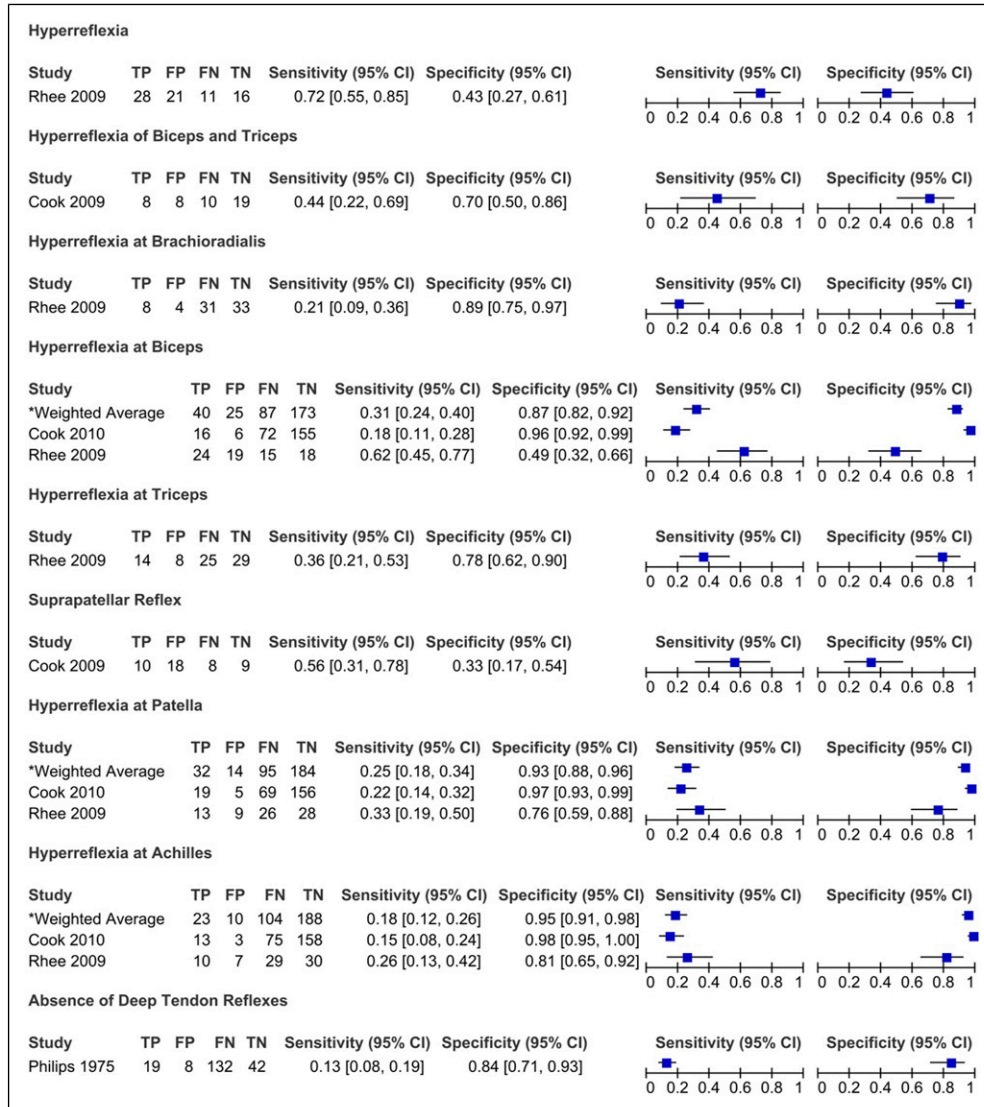


Figure 3. Sensitivity and specificity of hyperreflexia and hyporeflexia in degenerative cervical myelopathy: Results of eleven studies that included a control group.

and were included in the cervical myelopathy group if they had signal intensity changes on MRI.¹⁸ Based on their results, the inverted supinator sign had the highest sensitivity (61%), followed by the suprapatellar tendon reflex (56%), whereas Babinski (93%) and clonus (96%) demonstrated the highest specificity.¹⁸ Based on likelihood ratios, only Babinski and inverted supinator sign exhibited significant diagnostic accuracy. Specifically, the positive likelihood ratio for Babinski was 4.5 with a post-test probability of 73%. This indicates that the probability of the disease increases by 73% if this test is positive. The negative likelihood ratio for the inverted supinator sign was .5 with a post-test probability of 25%. Cook et al (2009) also evaluated whether combining clinical signs affected diagnostic accuracy.¹⁸ Unfortunately, the post-test probabilities of identifying DCM were not improved by combining clinical signs. In a second study, Cook et al (2010) aimed to develop a

prediction model for the diagnosis of DCM.²¹ Clinical signs that had a positive likelihood ratio greater than 2 or a negative likelihood ratio less than .5 were initially entered into a regression model and were retained if the *P*-value was less than .1.²¹ The 4 clinical signs that were deemed the most important for the diagnosis of DCM were gait deviation, Hoffmann, inverted supinator sign and Babinski. Age greater than 45 was also included in the model. It was found with a sensitivity of 94% that a patient was unlikely to have DCM if they exhibited none or only a single 1 of these 5 variables. In contrast, the presence of any 3 of the 5 variables being positive yielded a specificity of 99% and a positive likelihood ratio of 30.9, with a post-test probability of 94%; implying a high probability of the patient having DCM.²¹

Harrop et al (2010) evaluated the frequency of myelopathic signs in a cohort of patients with evidence of cervical

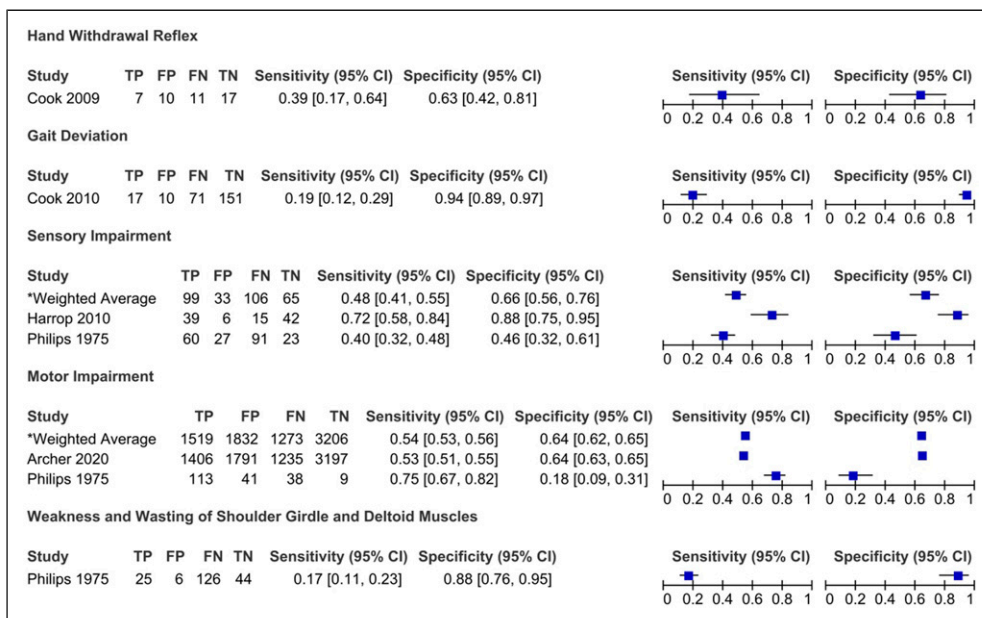


Figure 4. Sensitivity and specificity of sensory and motor impairment and gait dysfunction in degenerative cervical myelopathy: Results of eleven studies that included a control group.

spondylosis and symptoms of cervical stenosis.²⁴ Patients who exhibited greater than 1 long-tract sign localized to the cervical spinal cord comprised the myelopathy group, while those who did not were considered controls.²⁴ The sensitivity of signs ranged from 44% (Babinski) to 91% (gait abnormality), with hyperreflexia (85%), Hoffmann (83%) and lower extremity hyperreflexia (81%) demonstrating values above 80%. The presence of sensory loss was 72% sensitive and 88% specific for identifying cervical myelopathy and exhibited positive and negative predictive values of 87% and 74%, respectively.

Two studies evaluated the diagnostic accuracy of the Tromner sign.^{22,23} Based on their results, the sensitivity was 93% to 94% for identifying DCM and specificity ranged from 79% to 100%. The positive and negative predictive values were 92% to 100% and 85% to 91%, respectively. The study by Chang et al (2011) also assessed the sensitivity and specificity of the Tromner sign quantified by electrophysiological tests.²³ The sensitivity of this sign improved from 93% to 100% using this method. The diagnostic accuracy of the Hoffmann, inverted radial reflex and Babinski was also assessed in these 2 studies; results are summarized in Table 5.

Three studies evaluated the relationship between the presence of the Hoffmann sign and cervical pathology in symptomatic patients.²⁵⁻²⁷ In these studies, patients were considered to have cervical myelopathy if they were referred for complaints related to the cervical spine and had image evidence of cord compression. The control group consisted of individuals who were referred for similar symptoms but had no evidence of cord compression. Based on their results, the Hoffmann sign was 58% to 62% sensitive and 50% to 86% specific for identifying individuals with DCM.

Finally, 2 studies compared the rates of motor and sensory impairment between patient with cervical myelopathy and those with cervical radiculopathy or cervical spondylosis with brachial neuritis.^{28,29} The sensitivity of motor impairment ranged from 53% to 75% and specificity from 18% to 64%. Further results are provided in Table 5 for the diagnostic accuracy of sensory impairment, absence of deep tendon reflexes and weakness and wasting of shoulder girdle and deltoid muscles.

Studies that reported on frequency. Table 6 summarizes the results from the 61 studies that reported the frequency of clinical signs in a cohort of patients with DCM. Based on weighted averages, the most sensitive clinical signs for diagnosis DCM were hypertonia (.96, 95% CI 0.91 to .99) and pyramidal or upper motor neuron signs (.86, 95% CI 0.79 to .91) and hyperthesia (.81, 95% CI 0.70 to .89). The presence of hyperreflexia (.79, 95% CI 0.77 to .80) is also a sensitive sign that depends on location. Specifically, hyperreflexia of the lower extremities (.85, 95% CI 0.81 to .88) is more sensitive than hyperreflexia of the upper extremities (.78, 95% CI 0.74 to .82). The sensitivity of motor (.50, 95% CI 0.49 to .52) and sensory (.47, 95% CI 0.45 to .50) impairment increases when present in the upper extremities (motor: .73, 95% CI 0.69 to .77, sensory: .65, 95% CI 0.61 to .69) compared to the lower extremities (motor: .46, 95% CI 0.40 to .51, sensory: .62, 95% CI 0.52 to .72). Furthermore, while gait abnormalities have a sensitivity of only 47%, the presence of a spastic gait has a sensitivity of 69%. Based on single studies, the sensitivity of the following clinical signs was above 80%: myelopathic hand (.85, 95% CI 0.75 to .93) and patellar clonus (.80, 95% CI 0.61

Table 5. Diagnostic Accuracy of Clinical Signs Used to Diagnose Degenerative Cervical Myelopathy: Results of Twelve Studies That Included a Control Group.

	Sensitivity (%)	Specificity (%)	Positive Predictive Value (%)	Negative Predictive Value (%)	Positive Likelihood Ratio	Negative Likelihood Ratio
Hoffmann						
Cao et al (2019)	62	86	95	35	4.31	.45
Chaiyamongkol et al (2017)	75	93	96	59	10.50	.27
Chang et al (2011)	89	100	100	86	Infinite	.11
Cook et al (2009)	44	74	53	67	1.71	.75
Cook et al (2010)	31	73	39	66	1.15	.95
Glaser et al (2001)	58	78	62	75	2.61	.54
Grijalva et al (2015)	60	50	35	74	1.21	.79
Rhee et al (2009)	59	84	79	66	3.64	.49
Babinski						
Chaiyamongkol et al (2017)	36	100	100	38	Infinite	.64
Cook et al (2009)	33	93	75	68	4.50	.72
Cook et al (2010)	7	100	100	66	Infinite	.93
Rhee et al (2009)	13	100	100	52	Infinite	.87
Tromner						
Chaiyamongkol et al (2017)	94	79	92	85	4.41	.071
Chang et al (2011)	93	100	100	91	Infinite	.065
Hyperreflexia						
Rhee et al (2009)	72	43	57	59	1.26	.65
Hyperreflexia of the biceps and triceps						
Cook et al (2009)	44	70	50	66	1.50	.79
Hyperreflexia at brachioradialis						
Rhee et al (2009)	21	89	67	52	1.90	.89
Hyperreflexia at biceps						
Cook et al (2010)	18	96	73	68	4.88	.85
Rhee et al (2009)	62	49	56	54	1.20	.79
Hyperreflexia at triceps						
Rhee et al (2009)	36	78	64	54	1.66	.82
Hyperreflexia at patella						
Cook et al (2010)	22	97	79	69	6.95	.81
Rhee et al (2009)	33	76	59	52	1.37	.88
Hyperreflexia at achilles						
Cook et al (2010)	15	98	81	68	7.93	.87
Rhee et al (2009)	26	81	59	51	1.36	.92
Suprapatellar reflex						
Cook et al (2009)	56	33	36	53	.83	1.33
Inverted supinator sign						
Chaiyamongkol et al (2017)	75	86	93	57	5.25	.29
Cook et al (2009)	61	78	65	75	2.75	.50
Cook et al (2010)	18	99	89	69	14.64	.83
Rhee et al (2009)	51	81	74	61	2.71	.60
Clonus						
Cook et al (2009)	11	96	67	62	3.00	.92
Cook et al (2010)	7	99	75	66	5.49	.94
Rhee et al (2009)	13	100	100	52	Infinite	.87
Absence of deep tendon reflexes						

(continued)

Table 5. (continued)

	Sensitivity (%)	Specificity (%)	Positive Predictive Value (%)	Negative Predictive Value (%)	Positive Likelihood Ratio	Negative Likelihood Ratio
Philips (1975) Hand withdrawal reflex	13	84	70	24	.79	1.04
Cook et al (2009) Gait deviation	39	63	41	61	1.05	.97
Cook et al (2010) Sensory impairment	19	94	63	68	3.11	.86
Harrop et al (2010) Philips (1975), of the upper limbs	72	88	87	74	5.78	.32
Philips (1975), of the upper limbs	40	46	69	20	.74	1.31
Motor impairment Archer et al (2020)	53	64	44	72	1.48	.73
Philips (1975), of the upper limbs	75	18	73	19	.91	1.40
Weakness and wasting of shoulder girdle and deltoid muscles Philips (1975)	17	88	81	26	1.38	.95

to .92). Signs with poor sensitivity include motor deficit of individual muscle groups, clonus (.31, 95% CI 0.28 to .34), ataxia (.33, 95% CI 0.29 to .38), atrophy of intrinsic hand muscles (.38, 95% CI 0.35 to .41), Babinski (.42, 95% .41 to .44), and Romberg (.42, 95% .34 to .49).^{10,18,20-22,24,28-90} The supplemental material provides a complete summary of the average sensitivities of various clinical signs across included studies.

KQ2. What is the association between clinical signs and disease severity in patients with DCM?

Five studies evaluated the association between the presence of various clinical signs and disease severity as measured by the Nurick, JOA or mJOA, EMS, CMS and Prolo scores (Table 7).^{20,32,35,36,88}

Patients with a Hoffmann sign had more severe total JOA scores than those without this sign.³⁵ In single studies, a Hoffmann sign was also associated with worse upper and lower limb motor scores on the JOA.^{32,35} However, Funaba et al (2021) failed to detect a relationship between lower extremity JOA motor scores and the Hoffmann sign,³⁵ while Chikuda et al (2010) noted no correlation between a Hoffmann sign and upper extremity JOA motor scores.³² Of note, patients with a unilateral Hoffmann sign were less severe than those with bilateral Hoffmann sign.³⁶ Compared to patients with a Babinski, those with a Hoffmann sign had higher (less severe) mJOA scores.³⁶ Finally, there were no associations between the Nurick score and the presence of a Hoffmann sign.²⁰

Two studies identified that patients with a Babinski had more severe lower extremity JOA motor scores than those without this clinical finding.^{32,35} In contrast, there was no association between a Babinski and total JOA, upper extremity JOA motor or Nurick scores.^{20,32,35} Single studies

demonstrated that clonus was associated with more severe lower extremity JOA motor scores³² but not with upper extremity JOA motor or Nurick scores.^{20,32} Furthermore, Vitzthum and Dalitz (2007) identified an association between (i) the presence of dysdiadochokinesia and worse JOA, CMS upper extremity and EMS scores; (ii) upper extremity weakness and worse JOA, CMS upper extremity and EMS scores; and (iii) lower extremity weakness and worse Nurick scores. Finally, this review determined no association between (i) greater toe proprioception and total or subscores of the JOA,³⁵ (ii) hyperreflexia and JOA, Nurick, CMS, EMS or Prolo scores,³² and (iii) Nurick scores and hyperreflexia of the triceps, brachioradialis, patella and achilles or the inverted brachioradialis reflex.²⁰

Discussion

This systematic review aims to summarize the diagnostic accuracy of various clinical tests used to evaluate patients with DCM. Based on the results of the eleven studies, the most sensitive clinical tests were the Tromner sign and hyperreflexia, while the most specific tests were Babinski, the Tromner sign, clonus and the inverted supinator sign. Signs that may be eligible for inclusion in diagnostic criteria should demonstrate both moderate to high sensitivity and specificity. Of note, the majority of clinical signs identified in this review were either sensitive or specific, but not both. Furthermore, based on 1 series, examination findings may be absent entirely and a diagnosis of DCM can be made using a combination of patient-reported symptoms and imaging findings. As a result, it is important for clinicians to have a high index of suspicion for the diagnosis of DCM and to use a variety of clinical examination maneuvers to assess each patient. Furthermore, physicians should feel empowered to order imaging of the

Table 6. Sensitivity of Clinical Signs Used to Diagnose Degenerative Cervical Myelopathy.

Clinical Sign	Sensitivity	Clinical Sign	Sensitivity
Hoffmann	86%	Babinski	95%
Acharya et al (2010)	43%	Acharya et al (2010)	53%
Ahmed and galal (2020)	45%	Ahmed and galal (2020)	26%
Alaffi et al (2007)	52%	Alaffi et al (2007)	53%
Chatley et al (2009)	81%	Chikuda et al (2010)	41%
Chikuda et al (2010)	78%	Chiles et al (1999)	44%
Chiu et al (2017)	44%	Chiu et al (2017)	100% (U: 25%, B: 75%)
Du et al (2013)	49%	Di Iazzaro et al (1992)	22%
Du et al (2014)	25%	Du et al (2013)	30%
El-ghandour et al (2020)	79%	Du et al (2014)	72%
Findlay et al (2009)	76%	El-ghandour et al (2020)	31%
Funaba et al (2021)	83%	Findlay et al (2009)	61%
Harrop et al (2010)	43%	Funaba et al (2021)	44%
Holly et al (2009)	44%	Harrop et al (2010)	33%
Holly et al (2017)	97%	Holly et al (2009)	38%
Hossam et al (2013)	67%	Holly et al (2017)	57%
Hou et al (2020)	68% (U: 21%, B: 47%)	Hossam et al (2013)	33%
Houten et al (2008)	56%	Hou et al (2020)	33%
Kara et al (2011)	75%	Houten et al (2008)	63%
Kong et al (2019)	69%	Kara et al (2011)	11%
Lu et al (2017)	91%	Kim et al (2010)	55%
Paholpak et al (2013)	63%	Konya et al (2009)	57%
Tetreault et al (2015)	80%	Lo (2007)	52%
Thakar et al (2009)	42%	Lu et al (2017)	35%
Wang et al (2012)	100%	Paholpak et al (2013)	61%
Watson et al (1997)	63%	Pilato et al (2021)	100%
Wei et al (2019)	83%	Restuccia et al (1994)	36%
Wong et al (2004)		Tetreault et al (2015)	87%
		Thakar et al (2009)	46%
		Veilleux et al (1987)	16%
		Wang et al (2012)	93%
		Watson et al (1997)	26%
		Wei et al (2019)	79%
		Williams et al (2009)	55%
		Zhang et al (2010)	
Pathological reflexes	61%	Hypoactive reflexes	14%
Burkhardt et al (2017)	17%	Stetkarova et al (2009)	Biceps: 27%, triceps: 14%
Gerling et al (2017)	63%	Veilleux et al (1987)	
Kong et al (2019)	65%		
Vitzthum et al (2007)			
Hyperreflexia	83%	Clonus	48%
Ahmed and galal (2020)	82%	Acharya et al (2010)	27%
Alaffi et al (2007)	100%	Ahmed and galal (2020)	28%
Burkhardt et al (2017)	66%	Alaffi et al (2007)	35%
Chibbaro et al (2006)	100%	Chikuda et al (2010)	33%
Chibbaro et al (2009)	94%	Chiles et al (1999)	Ankle: 33%
Chikuda et al (2010)	76%	Chiu et al (2017)	17%
Chiles et al (1999)	66%	Du et al (2013)	19%
Du et al (2013)	77%	Du et al (2014)	60%
Du et al (2014)	83%	El-ghandour et al (2020)	19%
El-ghandour et al (2020)	85%	Holly et al (2009)	19%
Harrop et al (2010)	62%	Holly et al (2017)	Sustained patellar: 73%, unsustained patellar: 7%, sustained ankle: 73%, unsustained ankle: 3%
Holly et al (2009)	63%	Hossam et al (2013)	44%
Holly et al (2017)	97%	Kara et al (2011)	Ankle: 39%
Hossam et al (2013)	87%	Kim et al (2010)	31%
Hou et al (2020)	60%	Paholpak et al (2013)	31%
Houten et al (2008)	100%	Sinha and jagetia (2011)	UL: 65%, LL: 65%
Jain et al (2009)	100%	Thakar et al (2009)	Ankle: 34%
Kara et al (2011)	44%		
Kim et al (2010)	55%		
Konya et al (2009)	75%		
Lo et al (2004)	71%		
Lu et al (2017)	100%		
Misra et al (1998)	33%		
Raslan et al (2014)	86%		
Stetkarova et al (2009)	78%		
Tetreault et al (2015)	97%		
Thakar et al (2009)	79%		
Vitzthum et al (2007)	75%		
Wei et al (2019)			

(continued)

Table 6. (continued)

Clinical Sign	Sensitivity	Clinical Sign	Sensitivity
Hyperreflexia of upper limbs	90%	Hyperreflexia of lower limbs	76%
Chiu et al (2017)	72%	Chiu et al (2017)	62%
Findlay et al (2009)	67%	Findlay et al (2009)	81%
Harrop et al (2010)	85%	Harrop et al (2010)	96%
Lo (2007)	73%	Lo (2007)	96%
Lyu et al (2004)	100%	Lyu et al (2004)	100%
Sinha and jagetia (2011)	81%	Restuccia et al (1994)	100%
Stetkarova et al (2009)	60%	Sinha and jagetia (2011)	81%
Wang et al (2012)		Stetkarova et al (2009)	81%
		Veilleux et al (1987)	
Hyperreflexia at biceps	48%	Hyperreflexia at triceps	5%
Acharya et al (2010)	70%	Acharya et al (2010)	90%
Imajo et al (2011)		Imajo et al (2011)	
Hyperreflexia at patella	95%	Hyperreflexia at achilles	90%
Acharya et al (2010)	88%	Acharya et al (2010)	56%
Funaba et al (2021)	69%	Funaba et al (2021)	
Wang et al (2012)			
Hyperactive pectoralis reflex	32%	Inverted radial reflex	90%
Paholpak et al (2013)	60%	Acharya et al (2010)	83%
Watson et al (1997)		Hossam et al (2013)	89%
		Paholpak et al (2013)	53%
		Wong et al (2004)	
Scapulohumeral reflex	20%	Cross adductor	76%
Paholpak et al (2013)		Harrop et al (2010)	
Spasticity	LL: 20%	Romberg sign	37%
Alaffi et al (2007)	48%	Chacko et al (2012)	34%; with walking: 74%
Burkhardt et al (2017)	51%	Findlay et al (2009)	100%
El-ghandour et al (2020)	UL: 25%, LL: 6%	Kara et al (2011)	43%
Kara et al (2011)	58%	Turel et al (2013)	
Kim et al (2007)	90%		
Misra et al (1998)	LL: 100%		
Restuccia et al (1994)	LL: 48%		
Tetreault et al (2015)	LL: 33%		
Wei et al (2019)			
Hypertonia	92%	Gait abnormalities	41%
Chatley et al (2009)	100%	Audat et al (2018)	Spastic: 95%
Jain et al (2009)	UL: 100%, LL: 100%	Chacko et al (2014)	Spastic: 41%
Sinha and jagetia (2011)		Chibbaro et al (2006)	Spastic: 66%
		Chibbaro et al (2009)	Spastic: 68%
		Chiles et al (1999)	56%
		Du et al (2014)	91%
		Harrop et al (2010)	100%
		Hossam et al (2013)	53%
		Hou et al (2020)	25%
		Lo (2004)	Spastic: 50%
		Lo (2007)	Spastic: 59%
		Lyu et al (2004)	Ataxic: 67%
		Raslan et al (2014)	Broad-based: 60%
		Tetreault et al (2015)	Ataxic: 33%, spastic: 63%
		Veilleux et al (1987)	78%
		Wazir et al (2011)	Broad-based: 44%
		Wei et al (2019)	
Ataxia	32%	Pyramidal tetraparesis	28%
Gembruch et al (2019)	Spinal ataxia: 65%	Moussellard et al (2014)	
Scholler et al (2020)			

(continued)

Table 6. (continued)

Clinical Sign	Sensitivity	Clinical Sign	Sensitivity
Pyramidal signs/Upper motor neuron signs	Pyramidal syndrome: 84%	Motor deficit	74%
Moussellard et al (2014)	48%	Audat et al (2018)	84%
Stetkarova et al (2009)	100%	Chatley et al (2009)	9%
Wazir et al (2011)		Gembruch et al (2019)	22%
		Gerling et al (2017)	100%
		Hossam et al (2013)	57%
		Jain et al (2009)	60%
		Konya et al (2009)	75%
		Lo et al (2004)	61%
		Lu et al (2017)	55%
		Tetreault et al (2015)	48%
		Wei et al (2019)	
Motor deficit, upper limbs	87%	Motor deficit, lower limbs	63%
Ahmed and galal (2020)	90%	Ahmed and galal (2020)	47%
Chiu et al (2017)	72%	Chiu et al (2017)	53%
Du et al (2014)	52%	Du et al (2014)	29%
Holly et al (2009)	56%	Holly et al (2009)	38%
Holly et al (2017)	54%	Holly et al (2017)	26%
Lo (2007)	47%	Lo (2007)	22%
Lyu et al (2004)	100%	Lyu et al (2004)	91%
Sinha and jagetia (2011)	76%	Sinha and jagetia (2011)	
Veilleux et al (1987)			
Motor deficit, deltoids	11%	Motor deficit, biceps	12%
Chiles et al (1999)	57%	Chiles et al (1999)	
Imajo et al (2011)			
Motor deficit, triceps	29%	Motor deficit, hand intrinsics	57%
Chiles et al (1999)		Chiles et al (1999)	69%
		Thakar et al (2009)	
Motor deficit, iliopsoas	39%	Motor deficit, quadriceps	26%
Chiles et al (1999)		Chiles et al (1999)	
Motor deficit, plantarflexion	16%	Motor deficit, dorsiflexion	18%
Chiles et al (1999)		Chiles et al (1999)	
Atrophy of hand intrinsics	41%	Muscular atrophy/Wasting	14%
Aggarwal et al (2016)	24%	Chatley et al (2009)	27%
Alafifi et al (2007)	37%	Kim et al (2007)	
Chibbaro et al (2006)	40%		
Chibbaro et al (2009)	35%		
Misra et al (1998)	36%		
Tetreault et al (2015)	80%		
Thakar et al (2009)	26%		
Wei et al (2019)			
Fasciculations, lower limb	25%	Orthostatic hypotension	53%
Williams et al (2009)		Revannapa et al (2017)	
Myelopathic hand sign	85%	Wazir sign	79%
Wazir et al (2011)		Wazir et al (2011)	
Finger escape sign	48%	Grip and release	67%
Findlay et al (2009)	97%	Sugawara et al (2009)	
Paholpak et al (2013)	29%		
Sugawara et al (2009)	56%		
Wong et al (2004)			
Sensory impairment	80%	Impaired proprioception and touch	Proprioception: 31%
Ahmed and galal (2020)	88%	Chatley et al (2009)	50%
Audat et al (2018)	72%	Di Iazzaro et al (1992)	Proprioception at GT: 26%
Chatley et al (2009)	UL: 80%	Findlay et al (2009)	Proprioception at GT: 39%
Chibbaro et al (2009)	51%	Funaba et al (2021)	Proprioception: 47%
El-ghandour et al (2020)	19%	Hou et al (2020)	Touch: 57%
Gembruch et al (2019)	25%	Lo (2007)	Proprioception at LL: 70%
Gerling et al (2017)	UL: 38%, LL: 29%	Misra et al (1998)	Proprioception: 76%
Holly et al (2009)	UL: 50%, LL: 38%	Moussellard et al (2014)	Upper limbs: 45%
Holly et al (2017)	Hands: 87%	Restuccia et al (1994)	
Hou et al (2020)	100%		
Imajo (2011)	50%		
Konya et al (2009)	75%		
Lu et al (2017)	67%		
Stetkarova et al (2009)	UL: 73%, LL: 86%		
Veilleux et al (1987)	60%		
Wang et al (2012)	UL: 79%, LL: 71%		
Williams et al (2009)			

(continued)

Table 6. (continued)

Clinical Sign	Sensitivity	Clinical Sign	Sensitivity
Impaired vibration Lyu et al (2004) Findlay et al (2009)	Wrist: 47%, ankle: 65% Ankle: 60%	Impaired pain and temperature Di Iazzaro et al (1992) Kim et al (2007) Lo (2007) Lyu et al (2004) Misra et al (1998) Restuccia et al (1994)	Upper limbs: 21% 27% Reduced pain: 52% Reduced pain: UL: 61%, LL: 65%, trunk ^a : 18% Reduced pain: 45% Upper limbs: 34%
Hyperthesia Du et al (2014) Hossam et al (2013)	67% 100%	Spinal tenderness Chatley et al (2009)	20%
Spurling sign Hossam et al (2013)	13%	Posterior column dysfunction Chacko et al (2014) Moussellard et al (2014)	64% 42%

U, unilateral; B, bilateral; UL, upper limb; LL, lower limb; GT, great toe.

^aWith a level at the trunk.

cervical spine (or even advanced imaging) if a patient demonstrates any of these signs of DCM or symptoms referable to the neck (please see separate study on symptoms of DCM). Given the impact of early surgery on neurological recovery and other patient outcomes, we must get to the point where subtle signs and symptoms of myelopathy trigger early referral for neuroimaging and assessment by experts. Timely diagnosis of DCM is a top priority to ensure these individuals either get the surgical treatment they need, or are at the very least, monitored for disease progression by physicians with significant expertise in DCM. The results from this systematic review and a scoping review on important DCM symptoms will be used in combination with expert opinion to generate diagnostic criteria that can guide a variety of health care professionals towards a diagnosis of DCM.

Upper Motor Neuron Signs

The diagnostic value of the Hoffmann sign has been extensively studied in individuals with cervical spine complaints. Based on the results of this review, the clinical utility of this sign is controversial given the wide range of sensitivities (25% to 100%), specificities (50% to 100%) and positive (1.15 to infinite) and negative (.11 to .95) likelihood ratios. Similar to other pathological reflexes, the Hoffmann sign results from decreased inhibitory input from the descending fibers of the corticospinal tract; this decreased inhibition causes exaggerated activation of motor neurons from connections with both sensory neurons and interneurons.³⁶ It is postulated that patients with peripheral neuropathy or radiculopathy may have a falsely negative Hoffmann sign due to interference with the normal reflex arc.²⁶ However, in a study by Houten and Noce (2008), the Hoffmann sign was evident in patients with known diabetic neuropathy despite normal to diminished deep tendon reflexes.³⁶ The technique of eliciting this reflex is challenging to master and interrater variability may contribute to the range of results across studies. Cook et al (2009), however, demonstrated substantial agreement (89%) between

a neurosurgeon and a physical therapist in identifying a Hoffmann sign in a population of patients with cervical pain seeking a surgical consult.¹⁸ Inter-rater reliability is likely to differ across specialists and may be lower when assessed by physicians who encounter these patients less frequently. Finally, a positive Hoffmann sign may be present in .7% to 3% of the population as well as in patients with upper motor neuron dysfunction from an intracranial process.⁹¹ Although an asymmetric Hoffmann reflex may be more pathological, Houten and Noce (2008) demonstrated that a bilateral Hoffmann sign is associated with more definitive cord compression and more severe DCM.³⁶ This clinical sign should be used in combination with other signs and symptoms to support a diagnosis of myelopathy. Compared to the Hoffmann sign, the Tromner sign demonstrated superior sensitivity (94%) and specificity (93%) supporting its utility in both ruling in and out DCM.^{22,23}

An ongoing plantar response, known as the Babinski sign, is a primitive reflex that disappears at 1 to 2 years of age but can reappear in the setting of upper motor neuron dysfunction. In the studies included in this review, the Babinski sign was highly specific for diagnosing cervical myelopathy. The control groups, however, were either healthy individuals or patients with cervical spine complaints without image evidence of spinal cord compression or myelomalacia. As such, the values for specificity may be falsely elevated as a Babinski sign may also be present in patients with noncervical or nonspondylotic disorders that result in upper motor neuron dysfunction. The reliability of the Babinski sign also ranges from poor to moderate in cohorts of individuals with and without a variety of neurological diseases.^{18,92,93} This variability in assessment stems from differences in technique as well as in interpretation. Of note, the Babinski sign requires both extension of the great toe and fanning of the other toes; withdrawal of the foot or isolated toe extension are not consistent with a positive test. Finally, patients with a Babinski sign had worse mJOA scores than those with a Hoffmann sign, indicating that release of this primitive reflex is associated

Table 7. The Association Between Various Clinical Signs and Disease Severity.

	Clinical Sign	Measurement Tool to assess disease severity	Statistical Methods	Main results
Rhee et al (2009)	Hyperreflexia (biceps, triceps, brachioradialis, patella, achilles) Hoffmann Inverted brachioradialis Sustained clonus Babinski	Preoperative nurick score	Wilcoxon rank sum test to assess difference in nurick score in patients with ≥ 1 myelopathic signs vs patients without myelopathic signs	<ul style="list-style-type: none"> - No statistically significant correlation between preoperative nurick score and the presence of any myelopathic sign - Mean preoperative nurick score in patients with ≥ 1 myelopathic sign was 2.6 vs 2.4 in patients without any signs ($P = .4$)
Houten et al (2008)	Hoffmann Unilateral hoffmann Bilateral hoffmann Babinski	mJOA	Mann-whitney U-test to compare the mJOA scores in patients with a positive babinski sign and a positive hoffmann sign	<ul style="list-style-type: none"> - Mean mJOA score was higher in patients with a hoffmann sign (11.4) than patients with a babinski sign (9.6, $P < .0001$) - Mean mJOA score was higher in patients with unilateral hoffmann (12.8) than patients with bilateral hoffmann (10.8, $P < .0001$)
Chikuda et al (2010)	Hyperreflexia Hoffmann Babinski Clonus	JOA (motor function of upper and lower extremity)	Mann-whitney U-test to analyze the relationship between pyramidal signs and upper and lower motor JOA scores	<ul style="list-style-type: none"> - No association between upper motor JOA scores and the presence of hyperreflexia, hoffmann, babinski and clonus - More severe lower motor JOA scores were associated with the presence of hoffmann ($P = .031$), babinski ($P < .001$) and clonus ($P = .006$) but not hyperreflexia ($P = .445$)
Funaba et al (2021)	Hoffmann Babinski Great toe proprioception	Total, upper limb and lower limb JOA scores	Mann-whitney U-test to assess differences in JOA scores in patients with and without a particular clinical sign	<ul style="list-style-type: none"> - Hoffmann sign was associated with more severe total JOA (9.5 vs 10.4, $P = .04$) and upper limb JOA scores (2.92 vs 3.46, $P = .032$) - No association between hoffmann sign and lower limb JOA scores (2.79 vs 2.82, $P = .92$) - Babinski sign was associated with more severe lower limb JOA scores (2.64 vs 3.07, $P = .046$) - No association between babinski sign and total JOA (9.5 vs 10.1, $P = .18$) and upper limb JOA scores (3.05 vs 3.03, $P = .85$) - No association between great toe proprioception abnormalities and total JOA ($P = .93$), upper limb JOA ($P = .62$) or lower limb JOA scores ($P = .62$)
Vitzthum and dalitz (2007)	Dysdiadochokinesia Pathological reflexes Increased muscle tone Hyperreflexia of upper extremity Hyperreflexia of lower extremities Paresis of upper extremity Paresis of lower extremity	Nurick, JOA, CMS, prolo, EMS	Mann-whitney U test to assess the association between clinical signs and various scores	<ul style="list-style-type: none"> - Presence of paresis of the lower extremity was associated with worse nurick scores ($P < .05$). No association between paresis of the lower extremity and JOA, CMS, prolo or EMS scores - Presence of paresis of the upper extremity was associated with worse JOA ($P < .0001$), CMS upper extremity ($P < .0001$) and EMS ($P < .05$) scores. No association between paresis of the upper extremity and nurick or prolo scores - Dysdiadochokinesia was associated with worse JOA ($P < .05$), CMS upper extremity ($P < .0001$) and EMS ($P < .0001$) scores. No association between dysdiadochokinesia and nurick or prolo scores - Pathological reflexes, increased muscle tone, and hyperreflexia of the upper and lower extremities were not associated with nurick, JOA, CMS, prolo or EMS scores

mJOA, modified Japanese Orthopedic Association; JOA, Japanese Orthopedic Association; CMS, Cooper Myelopathy Scale; EMS, European Myelopathy Score.

with more severe corticospinal tract dysfunction.³⁶ The presence of clonus is also highly specific (99%) but demonstrates poor sensitivity.

Hyperreflexia at any deep tendon has moderate sensitivity for detecting cervical myelopathy (79%, with 47% of studies reporting a sensitivity over 80%). The sensitivity of this sign improves when assessing reflexes exclusively in the lower extremities (85%) compared with the upper extremities (78%).^{24,34,50} Evaluation of individual reflexes demonstrated a wide range of sensitivities: brachioradialis (21%), biceps (18% to 70%), triceps (5% to 90%), patella (22% to 95%) and achilles (15% to 90%). These results indicate that hyperreflexia, particularly in the lower extremities, may be an important screening tool for DCM. This finding is consistent with the underlying pathology of DCM as reflexes become exaggerated below the level of spinal cord compression due to reduced descending inhibition from the corticospinal tract. Furthermore, the reflexes in the upper extremities may be increased or decreased depending on the level of canal stenosis and the involvement of the nerve root as it exits the neural foramen. Presence of exaggerated reflexes in the upper extremities can further help to localize the level of spinal cord compression. For example, a hyperactive pectoralis reflex may indicate a myelopathic level above C4 whereas normal upper extremity reflexes are typically seen with a level at C6 to C7 or below.^{39,94} Notably, peripheral neuropathy may affect deep tendon reflexes; specifically, there was a significant difference in the frequency of achilles hyperreflexia in patients with diabetes (0%) compared to those without (35%, $P = .04$).²⁰ Caution should be taken in ruling out DCM in patients with peripheral neuropathy when reflexes are normal or diminished. Finally, the inverted supinator reflex has shown promising results with respect to specificity (93%) and therefore may be used to confirm a diagnosis of DCM in patients with cervical complaints.^{18,20-22,30}

Sensorimotor and Gait Dysfunction

Patients with DCM will often have motor and sensory dysfunction of their upper and lower extremities. The sensitivity, however, is variable for motor deficits (9 to 100%) and low for impaired pain, proprioception, temperature and vibration sensation. Weakness in patients with DCM often begins in the intrinsic hand muscles and is likely due to anterior horn cell damage as opposed to nerve root compression.³³ As a result, hand weakness is more sensitive (60%) than motor deficits in the iliopsoas (39%), triceps (29%), quadriceps (26%), dorsiflexors (18%), plantarflexors (16%), biceps (12%) and deltoids (18%).^{33,70,89}

Gait impairment may be 1 of the earliest manifestations of DCM. However, subtle changes in a patient's stance and stability when walking may be difficult to appreciate early in the disease course. A myelopathic gait is often described as unsteady, broad-based or spastic and is a result of impaired proprioception in addition to upper motor neuron dysfunction.

Furthermore, patients with DCM exhibit reduced gait velocity, a shortened stride length, increased double support time, a wide step width and slower cadence.⁹⁵⁻⁹⁹ DCM should be considered in patients with recurrent falls and gait deterioration. However, this clinical sign did not demonstrate high sensitivity given the wide variety of conditions that can impair gait, including osteoarthritis, peripheral neuropathy, obesity and vascular disease. Romberg sign can also be used to detect proprioception dysfunction but demonstrates poor sensitivity in DCM.^{30,34,37,51,84} When walking, however, the sensitivity of the Romberg sign increases from 34% to 74%.³⁴ This finding is clinically relevant as patients with DCM may sustain recurrent falls, especially in the dark. Overall, advanced gait assessments are essential to quantify subtle gait disturbances.

Based on the results of this systematic review, a combination of clinical signs is likely required to support a diagnosis of DCM. According to Cook et al (2010), the presence of 1 of the following has a high sensitivity (94%) for identifying individuals with DCM: gait deviation, Hoffmann sign, inverted supinator sign, Babinski sign and age over 45.²¹ Given these results, DCM could be safely excluded in patients who did not have any of these 5 criteria.²¹ Similarly, Rhee et al (2009) demonstrated that the presence of greater than or equal to 1 provocative sign (Hoffmann, inverted supinator sign, Babinski and clonus) was approximately 70% sensitive for diagnosing DCM.²⁰ However this study also identified cases of DCM with no positive examination findings. Furthermore, while the presence of an increasing number of clinical signs increases specificity and helps to confirm the diagnosis of DCM, it also appears to correlate to disease severity. Consequently, examination findings alone are not sufficient to make or exclude a diagnosis of DCM, especially early in the disease course.

Limitations

While this is the first review to summarize the sensitivity and specificity of clinical signs in DCM, there are limitations that should be mentioned. First, there were only eleven studies that included a control group in their analysis; as a result, there is limited information on the specificity of various DCM signs. Furthermore, of these eleven studies, 7 were rated as either moderate or high risk of bias on the QUADAS-2, questioning the validity of these results. In some of the studies, individuals were considered controls if they had neck, radicular or cervical spine pain or other symptoms but did not have myelomalacia or spinal cord compression on neuroimaging. It is increasingly recognized that patients can still be diagnosed with DCM in the absence of signal change or even spinal cord compression on static MRI. Moreover, several patients will have a combination of symptoms and signs of myelopathy and radiculopathy given that degenerative changes can simultaneously compress the spinal cord and nerve root. As such, these control groups may be suboptimal for assessing the accuracy of various symptoms. Other studies used patients referred to the

orthopedic clinic for other complaints or healthy controls such as the spouses of patients. These reflect better control groups for the question of interest. Second, values for sensitivity and specificity are extracted from studies that are screening a particular population and not just a random group of individuals. Nonetheless, this review provides invaluable information on some of the most common signs of DCM and will undoubtedly improve understanding of this condition.

Conclusion and Future Directions

Patients with DCM can present with subtle, non-specific signs in their upper and lower extremities, making it difficult to initially diagnose this condition. Based on the results, the most sensitive clinical tests for diagnosing DCM were the Tromner sign and hyperreflexia, while the most specific tests were the Babinski, Tromner sign, clonus and inverted supinator sign. Signs that may be eligible for inclusion in diagnostic criteria should demonstrate both moderate to high sensitivity and specificity. While the presence of these clinical signs is helpful, examination findings may be absent entirely and a diagnosis of DCM can still be made using a combination of patient-reported symptoms and imaging findings. Furthermore, the absence of upper motor neuron signs does not rule out a diagnosis of DCM. In patients with clear symptoms of myelopathy, standard or advanced imaging, formal gait assessment and neurophysiology may be required to confirm the diagnosis. The current systematic review provides a framework to create a diagnostic toolkit for specialists, primary care physicians, and allied health professionals.

- Patients with DCM can present with subtle, non-specific signs in their upper and lower extremities, making it difficult to initially diagnose this condition.
- The most sensitive clinical tests for diagnosing DCM are the Tromner sign and hyperreflexia
- The most specific tests are the Babinski, Tromner sign, clonus and inverted supinator sign.
- Examination findings may be absent entirely and a diagnosis of DCM can still be made using a combination of patient-reported symptoms and imaging findings.
- Absence of upper motor neuron signs does not rule out a diagnosis of DCM.

Acknowledgments

This research aligns with the AO Spine RECODE-DCM top research priority 'Diagnostic Criteria' selected by people living and working with DCM. For further information on how this process was conducted, why this question was prioritized, and global updates on currently aligned research, please visit aospine.org/recode/diagnostic-criteria. This article, including the broader efforts to establish diagnostic criteria for DCM, is led by the RECODE-DCM Diagnostic Criteria Incubator Group. This was initially launched,

with support from AO Spine through the AO Spine Knowledge Forum Spinal Cord Injury, a focused group of international Spinal Cord Injury experts. The oversight and support of the incubator has now transitioned to [Myelopathy.org](https://myelopathy.org), a global charity focused on DCM.

Declaration of conflicting interests

The author(s) declared no potential conflicts of interest with respect to the research, authorship, and/or publication of this article.

Funding


The author(s) received no financial support for the research, authorship, and/or publication of this article.

ORCID iDs

Benjamin Davies  <https://orcid.org/0000-0003-0591-5069>

Konstantinos Margetis  <https://orcid.org/0000-0002-3715-8093>

Andrea Boraschi  <https://orcid.org/0000-0002-2908-5234>

Oke Righteous ObadaserayeOrtho(UK) FMCOrtho  <https://orcid.org/0000-0001-8018-6076>

Michael G. Fehlings  <https://orcid.org/0000-0002-5722-6364>

Ratko Yurac  <https://orcid.org/0000-0003-3603-6294>

Elizabeth A. Roberts  <https://orcid.org/0000-0003-2738-4203>

Tanzil Rujeedawa  <https://orcid.org/0000-0002-7089-1684>

Supplemental Material

Supplemental material for this article is available online.

References

1. Nouri A, Tetreault L, Singh A, Karadimas SK, Fehlings MG. Degenerative cervical myelopathy: Epidemiology, genetics, and pathogenesis. *Spine (Phila Pa 1976)*. 2015;40(12):E675-E693. doi:[10.1097/BRS.0000000000000913](https://doi.org/10.1097/BRS.0000000000000913).
2. Badhiwala JH, Ahuja CS, Akbar MA, et al. Degenerative cervical myelopathy - update and future directions. *Nat Rev Neurol*. 2020;16(2):108-124. doi:[10.1038/s41582-019-0303-0](https://doi.org/10.1038/s41582-019-0303-0).
3. Davies BM, Mowforth OD, Smith EK, Kotter MR. Degenerative cervical myelopathy. *BMJ*. 2018;360:k186. doi:[10.1136/bmj.k186](https://doi.org/10.1136/bmj.k186).
4. Tetreault L, Kalsi-Ryan S, Benjamin D, et al. Degenerative cervical myelopathy: a practical approach to diagnosis. *Global Spine J*. 2022;21925682211072847. doi:[10.1177/21925682211072847](https://doi.org/10.1177/21925682211072847).
5. Behrbalk E, Salame K, Regev GJ, Keynan O, Boszczyk B, Lidar Z. Delayed diagnosis of cervical spondylotic myelopathy by primary care physicians. *Neurosurg Focus*. 2013;35(1):E1. doi:[10.3171/2013.3.FOCUS1374](https://doi.org/10.3171/2013.3.FOCUS1374).
6. Hilton B, Tempest-Mitchell J, Davies B, Kotter M. Route to diagnosis of degenerative cervical myelopathy in a UK healthcare system: a retrospective cohort study. *BMJ Open*. 2019;9(5):e027000. doi:[10.1136/bmjopen-2018-027000](https://doi.org/10.1136/bmjopen-2018-027000).
7. Pope DH, Mowforth OD, Davies BM, Kotter MRN. Diagnostic delays lead to greater disability in degenerative cervical myelopathy and represent a health inequality. *Spine (Phila Pa 1976)*. 2020;45(6):368-377. doi:[10.1097/BRS.0000000000003305](https://doi.org/10.1097/BRS.0000000000003305).

8. Davies BM, Phillips R, Clarke D, et al. Establishing the socio-economic impact of degenerative cervical myelopathy is fundamental to improving outcomes [AO spine RECODE-DCM research priority number 8]. *Global Spine J.* 2022;12(1_suppl):122S-129S. doi:10.1177/21925682211039835.
9. Tetreault L, Wilson JR, Kotter MRN, et al. Is preoperative duration of symptoms a significant predictor of functional outcomes in patients undergoing surgery for the treatment of degenerative cervical myelopathy? *Neurosurgery.* 2019;85(5):642-647. doi:10.1093/neuros/nyy474.
10. Tetreault L, Kopjar B, Cote P, Arnold P, Fehlings MG. A clinical prediction rule for functional outcomes in patients undergoing surgery for degenerative cervical myelopathy: Analysis of an international prospective multicenter data set of 757 subjects. *J Bone Joint Surg Am.* 2015;97(24):2038-2046. doi:10.2106/JBJS.O.00189.
11. Hilton B, Gardner EL, Jiang Z, et al. Establishing diagnostic criteria for degenerative cervical myelopathy [AO spine RECODE-DCM research priority number 3]. *Global Spine J.* 2022;12(1_suppl):55S-63S. doi:10.1177/21925682211030871.
12. Tetreault L, Lange SF, Chotai S, et al. A systematic review of definitions for neurological complications and disease progression in patients treated surgically for degenerative cervical myelopathy. *Spine (Phila Pa 1976).* 2019;44(18):1318-1331. doi:10.1097/BRS.0000000000003066.
13. Davies BM, Mowforth O, Wood H, et al. Improving awareness could transform outcomes in degenerative cervical myelopathy [AO spine RECODE-DCM research priority number 1]. *Global Spine J.* 2022;12(1_suppl):28S-38S. doi:10.1177/21925682211050927.
14. Davies BM, Kwon BK, Fehlings MG, Kotter MRN. AO spine RECODE-DCM: Why prioritize research in degenerative cervical myelopathy? *Global Spine J.* 2022;12(1_suppl):5S-7S. doi:10.1177/21925682211035379.
15. Tetreault L, Mowforth O, Khan DZ, et al. James lind alliance priority setting partnership for degenerative cervical myelopathy [AO spine RECODE-DCM]: An overview of the methodology used to process and short-list research uncertainties. *Global Spine J.* 2022;12(1_suppl):19S-27S. doi:10.1177/21925682211062501.
16. Davies BM, Khan DZ, Mowforth OD, et al. RE-CODE DCM (REsearch objectives and common data elements for degenerative cervical myelopathy): A consensus process to improve research efficiency in DCM, through establishment of a standardized dataset for clinical research and the definition of the research priorities. *Global Spine J.* 2019;9(1 Suppl):65S-76S. doi:10.1177/2192568219832855.
17. Cook CE, Wilhelm M, Cook AE, Petrosino C, Isaacs R. Clinical tests for screening and diagnosis of cervical spine myelopathy: A systematic review. *J Manip Physiol Ther.* 2011;34(8):539-546. doi:10.1016/j.jmpt.2011.08.008.
18. Cook C, Roman M, Stewart KM, Leithe LG, Isaacs R. Reliability and diagnostic accuracy of clinical special tests for myelopathy in patients seen for cervical dysfunction. *J Orthop Sports Phys Ther.* 2009;39(3):172-178. doi:10.2519/jospt.2009.2938.
19. Whiting PF, Rutjes AW, Westwood ME, et al. QUADAS-2: A revised tool for the quality assessment of diagnostic accuracy studies. *Ann Intern Med.* 2011;155(8):529-536. doi:10.7326/0003-4819-155-8-201110180-00009.
20. Rhee JM, Heflin JA, Hamasaki T, Freedman B. Prevalence of physical signs in cervical myelopathy: A prospective, controlled study. *Spine (Phila Pa 1976).* 2009;34(9):890-895. doi:10.1097/BRS.0b013e31819c944b.
21. Cook C, Brown C, Isaacs R, Roman M, Davis S, Richardson W. Clustered clinical findings for diagnosis of cervical spine myelopathy. *J Man Manip Ther.* 2010;18(4):175-180. doi:10.1179/106698110X12804993427045.
22. Chaiyamongkol W, Laohawiriyakamol T, Tangtrakulwanich B, Tanutit P, Bintachitt P, Siribumrungwong K. The significance of the tromner sign in cervical spondylotic myelopathy patient. *Clin Spine Surg.* 2017;30(9):E1315-E1320. doi:10.1097/BSD.0000000000000412.
23. Chang CW, Chang KY, Lin SM. Quantification of the Tromner signs: A sensitive marker for cervical spondylotic myelopathy. *Eur Spine J.* 2011;20(6):923-927. doi:10.1007/s00586-010-1681-6.
24. Harrop JS, Naroji S, Maltenfort M, et al. Cervical myelopathy: A clinical and radiographic evaluation and correlation to cervical spondylotic myelopathy. *Spine (Phila Pa 1976).* 2010;35(6):620-624. doi:10.1097/BRS.0b013e3181b723af.
25. Harrop JS, Naroji S, Maltenfort M, et al. A clinical correlation research of the Hoffmann sign and neurological imaging findings in cervical spinal cord compression. *World Neurosurg.* 2019;128:e782-e786. doi:10.1016/j.wneu.2019.04.254.
26. Glaser JA, Cure JK, Bailey KL, Morrow DL. Cervical spinal cord compression and the Hoffmann sign. *Iowa Orthop J.* 2001;21:49-52.
27. Grijalva RA, Hsu FP, Wycliffe ND, et al. Hoffmann sign: Clinical correlation of neurological imaging findings in the cervical spine and brain. *Spine (Phila Pa 1976).* 2015;40(7):475-479. doi:10.1097/BRS.0000000000000794.
28. Archer KR, Bydon M, Khan I, et al. Development and validation of cervical prediction models for patient-reported outcomes at 1 Year after cervical spine surgery for radiculopathy and myelopathy. *Spine (Phila Pa 1976).* 2020;45(22):1541-1552. doi:10.1097/BRS.0000000000003610.
29. Phillips DG. Upper limb involvement in cervical spondylosis. *J Neurol Neurosurg Psychiatry.* 1975;38(4):386-390. doi:10.1136/jnnp.38.4.386.
30. Acharya S, Srivastava A, Virmani S, Tandon R. Resolution of physical signs and recovery in severe cervical spondylotic myelopathy after cervical laminoplasty. *Spine (Phila Pa 1976).* 2010;35(21):E1083-E1087. doi:10.1097/BRS.0b013e3181df1a8e.
31. Alafifi T, Kern R, Fehlings M. Clinical and MRI predictors of outcome after surgical intervention for cervical spondylotic myelopathy. *J Neuroimaging.* 2007;17(4):315-322. doi:10.1111/j.1552-6569.2007.00119.x.
32. Chikuda H, Seichi A, Takeshita K, et al. Correlation between pyramidal signs and the severity of cervical myelopathy. *Eur*

- Spine J.* 2010;19(10):1684-1689. doi:10.1007/s00586-010-1364-3.
33. Chiles BW 3rd, Leonard MA, Choudhri HF, Cooper PR. Cervical spondylotic myelopathy: Patterns of neurological deficit and recovery after anterior cervical decompression. *Neurosurgery.* 1999;44(4):762-769. doi:10.1097/00006123-199904000-00041.
 34. Findlay GF, Balain B, Trivedi JM, Jaffray DC. Does walking change the Romberg sign? *Eur Spine J.* 2009;18(10):1528-1531. doi:10.1007/s00586-009-1008-7.
 35. Funaba M, Imajo Y, Suzuki H, et al. The associations between radiological and neurological findings of degenerative cervical myelopathy: Radiological analysis based on kinematic CT myelography and evoked potentials of the spinal cord. *J Neurosurg Spine.* 2021;1-12. doi:10.3171/2020.11.SPINE201626.
 36. Houten JK, Noce LA. Clinical correlations of cervical myelopathy and the Hoffmann sign. *J Neurosurg Spine.* 2008;9(3):237-242. doi:10.3171/SPI/2008/9/9/237.
 37. Kara B, Celik A, Karadereler S, et al. The role of DTI in early detection of cervical spondylotic myelopathy: A preliminary study with 3-T MRI. *Neuroradiology.* 2011;53(8):609-616. doi:10.1007/s00234-011-0844-4.
 38. Di Lazzaro V, Restuccia D, Colosimo C, Tonali P. The contribution of magnetic stimulation of the motor cortex to the diagnosis of cervical spondylotic myelopathy. Correlation of central motor conduction to distal and proximal upper limb muscles with clinical and MRI findings. *Electroencephalogr Clin Neurophysiol.* 1992;85(5):311-320. doi:10.1016/0168-5597(92)90107-m.
 39. Paholpak P, Jirattanaphochai K, Sae-Jung S, Wittayapairoj K. Clinical correlation of cervical myelopathy and the hyperactive pectoralis reflex. *J Spinal Disord Tech.* 2013;26(8):E314-E318. doi:10.1097/BSD.0b013e3182886edb.
 40. Pilato F, Calandrelli R, Distefano M, Tamburrelli FC. Multi-dimensional assessment of cervical spondylotic myelopathy patients. Usefulness of a comprehensive score system. *Neurol Sci.* 2021;42(4):1507-1514. doi:10.1007/s10072-020-04691-0.
 41. Restuccia D, Valeriani M, Di Lazzaro V, Tonali P, Manguiere F. Somatosensory evoked potentials after multisegmental upper limb stimulation in diagnosis of cervical spondylotic myelopathy. *J Neurol Neurosurg Psychiatry.* 1994;57(3):301-308. doi:10.1136/jnnp.57.3.301.
 42. Watson JC, Broaddus WC, Smith MM, Kubal WS. Hyperactive pectoralis reflex as an indicator of upper cervical spinal cord compression. Report of 15 cases. *J Neurosurg.* 1997;86(1):159-161. doi:10.3171/jns.1997.86.1.0159.
 43. Veilleux M, Daube JR. The value of ulnar somatosensory evoked potentials (SEPs) in cervical myelopathy. *Electroencephalogr Clin Neurophysiol.* 1987;68(6):415-423. doi:10.1016/0168-5597(87)90053-0.
 44. Zhang YZ, Shen Y, Wang LF, Ding WY, Xu JX, He J. Magnetic resonance T2 image signal intensity ratio and clinical manifestation predict prognosis after surgical intervention for cervical spondylotic myelopathy. *Spine (Phila Pa 1976).* 2010;35(10):E396-E399. doi:10.1097/BRS.0b013e3181c6dbc4.
 45. Wong TM, Leung HB, Wong WC. Correlation between magnetic resonance imaging and radiographic measurement of cervical spine in cervical myelopathic patients. *J Orthop Surg.* 2004;12(2):239-242. doi:10.1177/230949900401200220.
 46. Chibbaro S, Benvenuti L, Carnesecchi S, et al. Anterior cervical corpectomy for cervical spondylotic myelopathy: Experience and surgical results in a series of 70 consecutive patients. *J Clin Neurosci.* 2006;13(2):233-238. doi:10.1016/j.jocn.2005.04.011.
 47. Lo YL, Chan LL, Lim W, et al. Systematic correlation of transcranial magnetic stimulation and magnetic resonance imaging in cervical spondylotic myelopathy. *Spine (Phila Pa 1976).* 2004;29(10):1137-1145. doi:10.1097/00007632-200405150-00017.
 48. Misra UK, Kalita J. Motor evoked potential is useful for monitoring the effect of collar therapy in cervical spondylotic myelopathy. *J Neurol Sci.* 1998;154(2):222-228. doi:10.1016/S0022-510X(97)00275-X.
 49. Stetkarova I, Kofler M. Cutaneous silent periods in the assessment of mild cervical spondylotic myelopathy. *Spine (Phila Pa 1976).* 2009;34(1):34-42. doi:10.1097/BRS.0b013e31818f8be3.
 50. Lyu RK, Tang LM, Chen CJ, Chen CM, Chang HS, Wu YR. The use of evoked potentials for clinical correlation and surgical outcome in cervical spondylotic myelopathy with intramedullary high signal intensity on MRI. *J Neurol Neurosurg Psychiatry.* 2004;75(2):256-261.
 51. Chacko AG, Joseph M, Turel MK, Prabhu K, Daniel RT, Jacob KS. Multilevel oblique corpectomy for cervical spondylotic myelopathy preserves segmental motion. *Eur Spine J.* 2012;21(7):1360-1367. doi:10.1007/s00586-011-2137-3.
 52. Wazir NN, Kareem BA. New clinical sign of cervical myelopathy: Wazir hand myelopathy sign. *Singapore Med J.* 2011;52(1):47-49.
 53. Aggarwal RA, Srivastava SK, Bhosale SK, Nemade PS. Prediction of surgical outcome in compressive cervical myelopathy: A novel clinicoradiological prognostic score. *J Craniocervical Junction Spine.* 2016;7(2):82-86. doi:10.4103/0974-8237.181828.
 54. Ahmed OEF, Galal A. Multiple level anterior cervical discectomy and fusion versus posterior laminectomy for the management of multilevel cervical spondylotic myelopathy: clinical and radiological outcome. *Egyptian Journal of Neurology, Psychiatry and Neurosurgery.* 2020;56(32).
 55. Audat ZA, Fawareh MD, Radydeh AM, et al. *Anterior versus posterior approach to treat cervical spondylotic myelopathy, clinical and radiological results with long period of follow-up.* Sage Open Med; 2018. pp. 2050312118766199. doi:10.1177/2050312118766199.
 56. Burkhardt BW, Brielmaier M, Schwerdtfeger K, Sharif S, Oertel JM. Smith-Robinson procedure with and without Caspar plating as a treatment for cervical spondylotic myelopathy: A 26-year follow-up of 23 patients. *Eur Spine J.* 2017;26(4):1246-1253. doi:10.1007/s00586-017-4988-8.
 57. Chacko AG, Turel MK, Sarkar S, Prabhu K, Daniel RT. Clinical and radiological outcomes in 153 patients undergoing oblique corpectomy for cervical spondylotic myelopathy. *Br J*

- Neurosurg.* 2014;28(1):49-55. doi:10.3109/02688697.2013.815326.
58. Chatley A, Kumar R, Jain VK, Behari S, Sahu RN. Effect of spinal cord signal intensity changes on clinical outcome after surgery for cervical spondylotic myelopathy. *J Neurosurg Spine.* 2009;11(5):562-567. doi:10.3171/2009.6.SPINE091.
 59. Chibbaro S, Mirone G, Makiese O, George B. Multilevel oblique corpectomy without fusion in managing cervical myelopathy: Long-term outcome and stability evaluation in 268 patients. *J Neurosurg Spine.* 2009;10(5):458-465. doi:10.3171/2009.1.SPINE08186.
 60. Chiu AYY, Pang MYC. Assessment of psychometric properties of various balance assessment tools in persons with cervical spondylotic myelopathy. *J Orthop Sports Phys Ther.* 2017;47(9):673-682. doi:10.2519/jospt.2017.7283.
 61. Du W, Wang L, Shen Y, Zhang Y, Ding W, Ren L. Long-term impacts of different posterior operations on curvature, neurological recovery and axial symptoms for multilevel cervical degenerative myelopathy. *Eur Spine J.* 2013;22(7):1594-1602. doi:10.1007/s00586-013-2741-5.
 62. Du W, Zhang P, Shen Y, Zhang YZ, Ding WY, Ren LX. Enlarged laminectomy and lateral mass screw fixation for multilevel cervical degenerative myelopathy associated with kyphosis. *Spine J.* 2014;14(1):57-64. doi:10.1016/j.spinee.2013.06.017.
 63. El-Ghandour NMF, Soliman MAR, Ezzat AAM, Mohsen A, Zein-Elabedin M. The safety and efficacy of anterior versus posterior decompression surgery in degenerative cervical myelopathy: A prospective randomized trial. *J Neurosurg Spine.* 2020;1-9. doi:10.3171/2020.2.SPINE191272.
 64. Gembruch O, Jabbarli R, Rashidi A, et al. Degenerative cervical myelopathy in higher-aged patients: How do they benefit from surgery? *J Clin Med.* 2019;9(1). doi:10.3390/jcm9010062.
 65. Gerling MC, Radcliff K, Isaacs R, et al. Two-Year results of the prospective spine treatment outcomes study: An analysis of complication rates, predictors of their development, and effect on patient derived outcomes at 2 Years for surgical management of cervical spondylotic myelopathy. *World Neurosurg.* 2017;106:247-253. doi:10.1016/j.wneu.2017.06.147.
 66. Holly LT, Ellingson BM, Salamon N. Metabolic imaging using proton magnetic spectroscopy as a predictor of outcome after surgery for cervical spondylotic myelopathy. *Clin Spine Surg.* 2017;30(5):E615-E619. doi:10.1097/BSD.0000000000000248.
 67. Holly LT, Freitas B, McArthur DL, Salamon N. Proton magnetic resonance spectroscopy to evaluate spinal cord axonal injury in cervical spondylotic myelopathy. *J Neurosurg Spine.* 2009;10(3):194-200. doi:10.3171/2008.12.SPINE08367.
 68. Hossam M SM, Elsame M. Median cervical corpectomy for cervical myelopathy associated with ossified posterior longitudinal ligament. *Trends Med Res.* 2013;8:1-15.
 69. Hou X, Lu S, Wang B, Kong C, Hu H. Morphologic characteristics of the deep cervical paraspinal muscles in patients with single-level cervical spondylotic myelopathy. *World Neurosurg.* 2020;134:e166-e171. doi:10.1016/j.wneu.2019.09.162.
 70. Imajo Y, Kato Y, Yonemura H, Kanchiku T, Suzuki H, Taguchi T. Relative vulnerability of various spinal tracts in C3-4 cervical spondylotic myelopathy: Multi-modal spinal cord evoked potentials. *Spinal Cord.* 2011;49(11):1128-1133. doi:10.1038/sc.2011.68.
 71. Jain S SS, Kumar Joshi A, Pamecha C, Dave B, Patel P. Comparative study of anterior versus posterior decompression in elderly patients of cervical myelopathy with co-morbid conditions. *Eur J Orthop Surg Traumatol.* 2009;19:397-401.
 72. Kim CR, Yoo JY, Lee SH, Lee DH, Rhim SC. Gait analysis for evaluating the relationship between increased signal intensity on t2-weighted magnetic resonance imaging and gait function in cervical spondylotic myelopathy. *Arch Phys Med Rehabil.* 2010;91(10):1587-1592. doi:10.1016/j.apmr.2010.07.008.
 73. Kim YJ, Oh SH, Yi HJ, Kim YS, Ko Y, Oh SJ. Myelopathy caused by soft cervical disc herniation: Surgical results and prognostic factors. *J Korean Neurosurg Soc.* 2007;42(6):441-445. doi:10.3340/jkns.2007.42.6.441.
 74. Kong W, Xin Z, Du Q, Cao G, Liao W. Anterior percutaneous full-endoscopic transcorporeal decompression of the spinal cord for single-segment cervical spondylotic myelopathy: The technical interpretation and 2 years of clinical follow-up. *J Orthop Surg Res.* 2019;14(1):461. doi:10.1186/s13018-019-1474-5.
 75. Konya D, Ozgen S, Gercek A, Pamir MN. Outcomes for combined anterior and posterior surgical approaches for patients with multisegmental cervical spondylotic myelopathy. *J Clin Neurosci.* 2009;16(3):404-409. doi:10.1016/j.jocn.2008.07.070.
 76. Lo YL, Tan YE, Dan YF, et al. Cutaneous silent periods in the evaluation of cord compression in cervical spondylosis. *J Neurol.* 2007;254(1):14-19. doi:10.1007/s00415-007-0142-6.
 77. Lu K, Gao X, Tong T, Miao D, Ding W, Shen Y. Clinical predictors of surgical outcomes and imaging features in single segmental cervical spondylotic myelopathy with lower cervical instability. *Med Sci Monit.* 2017;23:3697-3705. doi:10.12659/msm.906046.
 78. Moussellard HP, Meyer A, Biot D, Khiami F, Sariali E. Early neurological recovery course after surgical treatment of cervical spondylotic myelopathy: A prospective study with 2-year follow-up using three different functional assessment tests. *Eur Spine J.* 2014;23(7):1508-1514. doi:10.1007/s00586-014-3315-x.
 79. Raslan F, Koehler S, Berg F, et al. Vertebral body replacement with PEEK-cages after anterior corpectomy in multilevel cervical spinal stenosis: A clinical and radiological evaluation. *Arch Orthop Trauma Surg.* 2014;134(5):611-618. doi:10.1007/s00402-014-1972-1.
 80. Revanappa KK, Moorthy RK, Alexander M, Rajsheshkar V. Recovery of sympathetic skin response after central corpectomy in patients with moderate and severe cervical spondylotic myelopathy. *Br J Neurosurg.* 2017;31(2):199-204. doi:10.1080/02688697.2016.1206178.
 81. Scholler K, Siller S, Brem C, Lutz J, Zausinger S. Diffusion tensor imaging for surgical planning in patients with cervical spondylotic myelopathy. *J Neurol Surg Cent Eur Neurosurg.* 2020;81(1):1-9. doi:10.1055/s-0039-1691822.

82. Sinha S, Jagetia A. Bilateral open-door expansive laminoplasty using unilateral posterior midline approach with preservation of posterior supporting elements for management of cervical myelopathy and radiculomyelopathy—analysis of clinical and radiological outcome and surgical technique. *Acta Neurochir.* 2011;153(5):975-984. doi:10.1007/s00701-010-0872-6.
83. Sugawara T, Hirano Y, Higashiyama N, Mizoi K. Limaprost alfadex improves myelopathy symptoms in patients with cervical spinal canal stenosis. *Spine (Phila Pa 1976).* 2009;34(6):551-555. doi:10.1097/BRS.0b013e31819a84ec.
84. Turel MK, Sarkar S, Prabhu K, Daniel RT, Jacob KS, Chacko AG. Reduction in range of cervical motion on serial long-term follow-up in patients undergoing oblique corpectomy for cervical spondylotic myelopathy. *Eur Spine J.* 2013;22(7):1509-1516. doi:10.1007/s00586-013-2724-6.
85. Wang L, Liu CY, Tian JW, Tian X, Dong SH, Zhao QH. Combined single-level subtotal corpectomy and decompression for cervical spondylotic myelopathy treatment. *ANZ J Surg.* 2012;82(5):342-347. doi:10.1111/j.1445-2197.2011.05996.x.
86. Wei L, Cao P, Xu C, et al. The relationship between preoperative factors and the presence of intramedullary increased signal intensity on T2-weighted magnetic resonance imaging in patients with cervical spondylotic myelopathy. *Clin Neurol Neurosurg.* 2019;178:1-6. doi:10.1016/j.clineuro.2019.01.006.
87. Williams KE, Paul R, Dewan Y. Functional outcome of corpectomy in cervical spondylotic myelopathy. *Indian J Orthop.* 2009;43(2):205-209. doi:10.4103/0019-5413.50855.
88. Vitzthum HE, Dalitz K.. Analysis of five specific scores for cervical spondylogenic myelopathy. *Eur Spine J.* 2007;16(12):2096-2103. doi:10.1007/s00586-007-0512-x.
89. Thakar S, Christopher S, Rajshekhar V. Quality of life assessment after central corpectomy for cervical spondylotic myelopathy: Comparative evaluation of the 36-item short form health survey and the world health organization quality of life-bref. *J Neurosurg Spine.* 2009;11(4):402-412. doi:10.3171/2009.4.SPINE08749.
90. !!! INVALID CITATION !!!.
91. Malanga GA, Landes P, Nadler SF. Provocative tests in cervical spine examination: Historical basis and scientific analyses. *Pain Physician.* 2003;6(2):199-205.
92. Dafkin C, Green A, Kerr S, Veliotis D, Olivier B, McKinon W. The interrater reliability of subjective assessments of the Babinski reflex. *J Mot Behav.* 2016;48(2):116-121. doi:10.1080/00222895.2015.1047486.
93. Miller TM, Johnston SC. Should the Babinski sign be part of the routine neurologic examination? *Neurology.* 2005;65(8):1165-1168. doi:10.1212/01.wnl.0000180608.76190.10.
94. Matsumoto M, Fujimura Y, Toyama Y. Usefulness and reliability of neurological signs for level diagnosis in cervical myelopathy caused by soft disc herniation. *J Spinal Disord.* 1996;9(4):317-321.
95. Kuhtz-Buschbeck JP, Johnk K, Mader S, Stolze H, Mehdorn M. Analysis of gait in cervical myelopathy. *Gait Posture.* 1999;9(3):184-189. doi:10.1016/s0966-6362(99)00015-6.
96. Haddas R, Patel S, Arakal R, Boah A, Belanger T, Ju KL. Spine and lower extremity kinematics during gait in patients with cervical spondylotic myelopathy. *Spine J.* 2018;18(9):1645-1652. doi:10.1016/j.spinee.2018.04.006.
97. Lee JH, Lee SH, Seo IS. The characteristics of gait disturbance and its relationship with posterior tibial somatosensory evoked potentials in patients with cervical myelopathy. *Spine (Phila Pa 1976).* 2011;36(8):E524-E530. doi:10.1097/BRS.0b013e3181f412d9.
98. Malone A, Meldrum D, Bolger C. Gait impairment in cervical spondylotic myelopathy: Comparison with age- and gender-matched healthy controls. *Eur Spine J.* 2012;21(12):2456-2466. doi:10.1007/s00586-012-2433-6.
99. Suzuki E, Nakamura H, Konishi S, Yamano Y. Analysis of the spastic gait caused by cervical compression myelopathy. *J Spinal Disord Tech.* 2002;15(6):519-522. doi:10.1097/00024720-200212000-00015.