

Protective Effects of Exogenous Secretin on Ceruletide-induced Acute Pancreatitis in the Rat

IAN G. RENNER AND JAMES R. WISNER, JR., *Section of Gastroenterology, Department of Medicine, University of Southern California School of Medicine, Los Angeles, California 90033*

HEINRICH RINDERKNECHT, *Veterans Administration Medical Center, Sepulveda, California 91343; Department of Medicine, University of California, Los Angeles School of Medicine, Los Angeles, California 90024*

ABSTRACT Unconscious rats given intravenous ceruletide (diethylamine salt of the decapeptide caerulein) in large pharmacologic doses consistently developed moderate acute pancreatitis by 3 h and florid pancreatitis by 6 h. Biochemical serum markers of acute pancreatitis tended to parallel the severity of the pancreatic damage. In 50% of the rats, mesenteric fat necrosis was present, free peritoneal fluid containing massive elevations of trypsinogen and amylase were noted in most animals. Intravenous secretion at a low dose given simultaneously with ceruletide exerted a variable protective effect on the pathological process. A high dose of secretin produced a striking macroscopic, microscopic, and biochemical protective effect on ceruletide-induced pancreatitis. High resolution light microscopy and electron microscopy showed a marked cellular disorganization in the acini of animals treated with ceruletide alone. By contrast, there was a striking apical redirection of zymogen granules in acini of the animals treated with secretin. The results of this study suggest that high dose intravenous secretion may exert a beneficial effect on acute pancreatitis.

INTRODUCTION

Although excellent work on early prognostic criteria in acute pancreatitis (AP)¹ has allowed increased recognition of those patients likely to experience significant morbidity and mortality (1-3), advances in treatment for this group have changed little in recent years.

Address correspondence to Dr. Renner.
Received for publication 27 October 1982 and in revised form 13 May 1983.

¹ Abbreviations used in this paper: CU, clinical unit; AP, acute pancreatitis.

The economic cost to the community in the care of patients with severe AP is enormous. Thus, there is a need for rapid improvement in therapy of AP and this need has led to an increased interest in development of suitable animal models for this purpose (4-7).

Clinical and biochemical changes consistent with acute pancreatitis have been observed by us in three patients given large intravenous doses of cholecystokinin without secretin, but not when both hormones were given concurrently. Ceruletide (the diethylamine salt of the decapeptide, caerulein, originally isolated from the skin of the Australian frog *Hyla caerulea*, and sharing seven of its eight C-terminal amino acids with the C-terminal octapeptide of cholecystokinin) given intravenously in 5 μ g/kg per h doses consistently produces acute pancreatitis in rats (4, 5). Therefore, we decided to investigate whether secretin might confer a protective effect on ceruletide-induced acute pancreatitis in rats.

METHODS

Adult male Wistar rats (180-220 g body wt) were purchased from Simonsen Laboratories, Gilroy, CA. All animals were deprived of food for 18 h before the experiment.

The rats were anesthetized by an intraperitoneal injection of urethane (750 mg/kg body wt), and were given an identical subcutaneous dose 10 min later (8). The left external jugular vein was catheterized with a PE-50 polyethylene tube and infusion of test substances was given for 6 h using a Sage syringe infusion pump (model 335; Sage Instruments Div., Orion Research Inc., Cambridge, MA) at a flow rate of 0.5 ml/h. Control animals received 0.9% NaCl, while experimental animals received infusions of either 5 μ g of ceruletide/kg per h (4, 5) (Adria Laboratories, Columbus, OH), 5 μ g of ceruletide plus 1 clinical unit (CU) of secretin/kg per h (Pharmacia, Piscataway, NJ), or 5 μ g of ceruletide plus 5 CU secretin/kg per h. Secretin used in these studies was a highly purified natural porcine hepatocosa-peptide (95% pure) with a potency of $\geq 3,000$ CU/mg peptide. All hor-

mones were redissolved in 0.9% NaCl immediately before use. No attempt was made to monitor or maintain constant animal body temperatures.

Tail-vein blood samples were obtained at time 0, 3 h, and 6 h; animals were laparotomized for examination of the pancreas and then killed by abdominal aorta exsanguination. For light microscopy, portions of pancreas were fixed overnight at room temperature in 10% formaldehyde solution buffered to pH 7.0 with 0.1 M phosphate buffer. Tissues were dehydrated in a graded ethanol series, embedded in paraffin, sectioned at 5- μ m slices, and stained with hematoxylin and eosin.

For electron microscopy, tissues were fixed with cold 2.5% glutaraldehyde in 0.1 M phosphate buffer, pH 7.4, and washed with several changes of 0.1 M phosphate buffer. Tissues were next postfixated with cold 1% OsO₄ in 0.1 M phosphate buffer, pH 7.4, dehydrated with a graded series of ethanols and propylene oxide, and embedded in an araldite/epon mixture. 1- μ m-thick sections were cut using an LKB microtome (LKB Instruments, Inc., Rockville, MD) and were stained with alkaline toluidine blue and examined by light microscopy to select areas for ultra-thin sectioning. Sections, 600–700 Å thick, were cut on the LKB microtome, stained with lead acetate, and examined with a Philips 301 transmission electron microscope.

Blood samples were centrifuged and serum stored at -20°C until analyzed.

Serum amylase was assayed by the Phadebas test (Pharmacia, Uppsala, Sweden). Lipase was estimated by the Sigma serum lipase (Sigma Chemical Co., St. Louis, MO) assay using an emulsion of olive oil as substrate. Serum trypsinogen content was evaluated according to the method of Rinderknecht and co-workers (9). Briefly, the procedure is based on activation of serum trypsinogen with porcine enterokinase and fluorometric determination of activated trypsin activity after incubation with a fluorogenic substrate (carbobenzoxy-[glycine]₂-arginine-2-naphthylamide). Statistical analysis of data was accomplished by analysis of variance (ANOVA) and by Duncan's new multiple range test (10) with $P < 0.05$ as the level of significance.

RESULTS

Macroscopic. Pancreatic tissue in all ceruletide-infused animals showed striking interstitial edema, which accentuated the natural lobulation of the gland. The spleen was displaced laterally by the grossly enlarged pancreas.

In six of the 14 rats with ceruletide-induced AP, fat necrosis was present in the mesenteries adjacent to the pancreas.

In rats treated for 6 h with 1 CU/kg per h of secretin in addition to ceruletide, considerable variability in pancreatic pathology was evident. Some animals exhibited minimal interstitial pancreatic edema and increased lobulation, while others showed more marked edema with accentuated glandular lobulation. A consistent finding in all rats given 5 CU/kg per h of secretin plus ceruletide was an almost complete absence of pancreatic edema and lobulation. The pancreatic tissue in these latter animals was virtually indistin-

guishable from that observed in saline-treated control animals. No mesenteric fat necrosis was present in rats treated with either combination doses of secretin plus ceruletide.

A consistent observation in rats receiving ceruletide alone was the presence of several milliliters of serosanguinous fluid in the peritoneal cavity. Peritoneal fluid was not present in saline-treated controls and was either absent or present in minimal amounts in rats treated with ceruletide plus either dose of secretin.

Light microscopic results. Histological appearance of a saline infused, control rat pancreas is shown in Fig. 1 A. The pancreas is composed of discrete lobes each composed of small lobules. A fine connective tissue capsule tightly adherent to peripheral portions of the lobules encloses the lobes. The capsular connective tissue projects between lobules and carries both arteries and veins. The lobules consist of closely apposed acini. High power views of the pancreatic acini (Fig. 1 B) in the saline-control animal show normal apposition of cells with large numbers of zymogen granules clustered in the supranuclear region and oriented toward the acinar lumen. The acinar lumen is small. These histological observations were representative of five animals selected at random from the control group for histological evaluation of the pancreas.

The pancreas of all animals treated with ceruletide exhibited gross interstitial edema, which resulted in thickening of the capsule and interstitial tissue and marked separation of lobules and acinar cells (Fig. 2 A). Marked change is apparent in acinar cells compared with those in control animals, with a high power view of the pancreatic acini (Fig. 2 B) showing clearly the intense vacuolization and acinar separation.

In marked contrast to the pattern of pancreatic disorganization observed in ceruletide-treated rats, little change from control animal pancreas was evident in all animals treated with 5 CU of secretin/kg per h plus ceruletide (Fig. 3 A). In these latter animals the capsule was closely applied to the pancreatic lobules and while the acini appeared slightly separated from one another, the most striking finding histologically was the virtual absence of interstitial edema (Fig. 3 A).

High power views of the pancreatic acini in all rats treated with 5 CU of secretin/kg per h plus ceruletide (Fig. 3 B) show a virtually normal acinar pattern with the basolateral membranes of the cells in close apposition to one another. There is evidence of minor intracellular vacuolization in marked contrast to the extensive vacuolization seen in animals treated with ceruletide alone (Fig. 2 B). The acinar lumen is clearly evident.

Electron microscopic results. Electron microscopy was performed on thin sections of pancreatic tissue

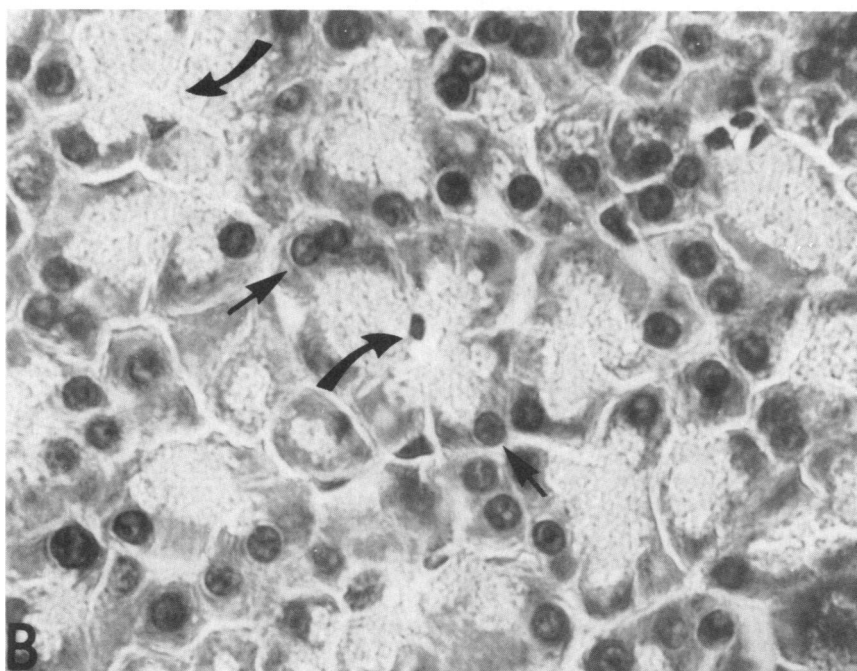
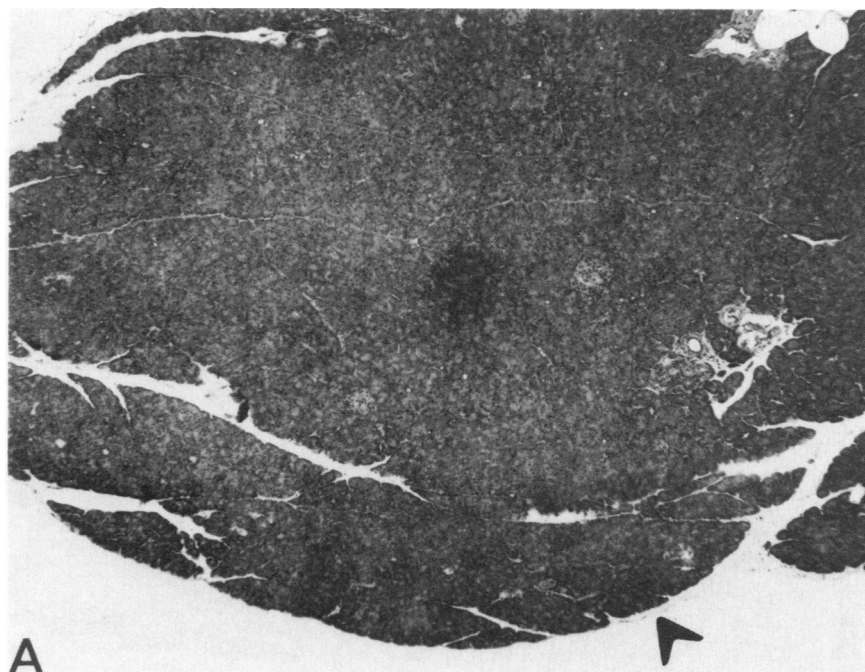


FIGURE 1 Rat pancreatic histology. (A) 6-h; saline-infused control. The pancreas exhibits a closely adherent capsule (large arrowhead) with preservation of normal lobular architecture. $\times 40$. (B) High power views of acini showing the normal orientation of cells with basal location of the nuclei (small arrows) and numerous zymogen granules (large arrows) oriented toward the apical zone. $\times 750$.

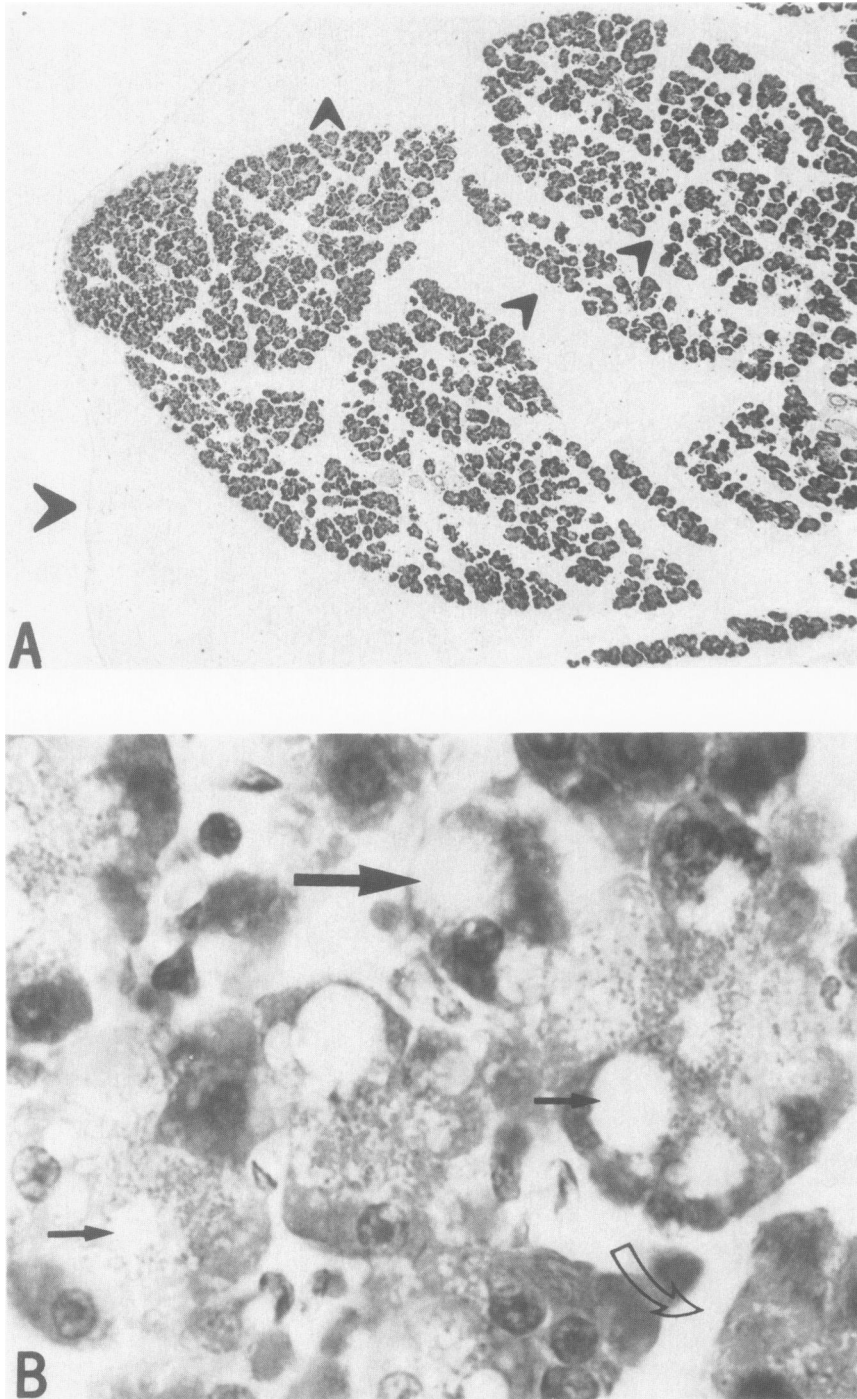


FIGURE 2 (A) 6-h ceruleide-infused animal showing features of severe edematous acute pancreatitis with marked interstitial edema (large arrowhead) and gross separation of capsule, lobes, and lobules from one another (small arrowheads) $\times 40$. (B) High power views of the acinar structure reveal marked disorganization of cells with numerous small and large vacuoles (small arrows) present. Many of these large vacuoles are situated close to the basolateral membranes of the cells (large arrow). Also evident is interacinar separation (clear arrow) $\times 750$.

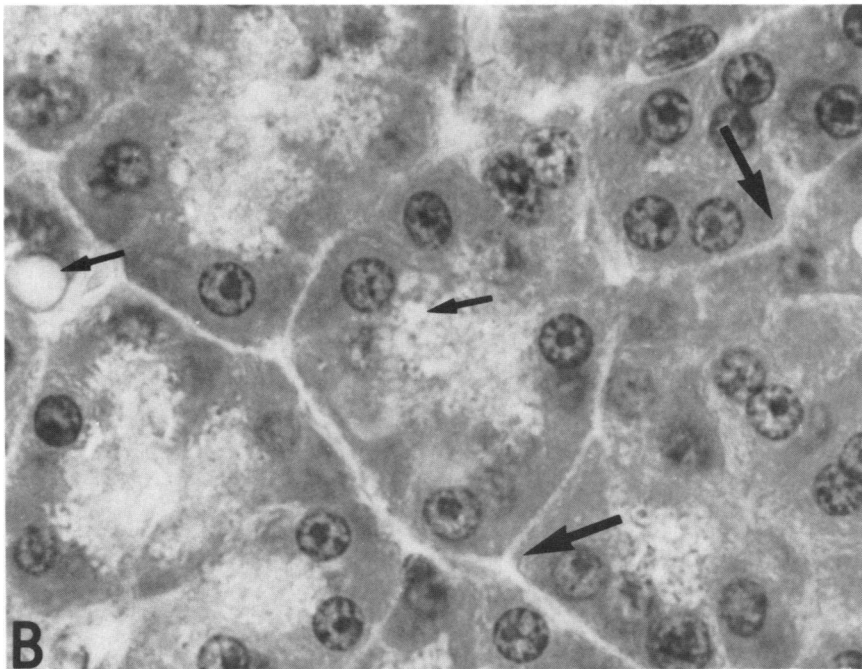
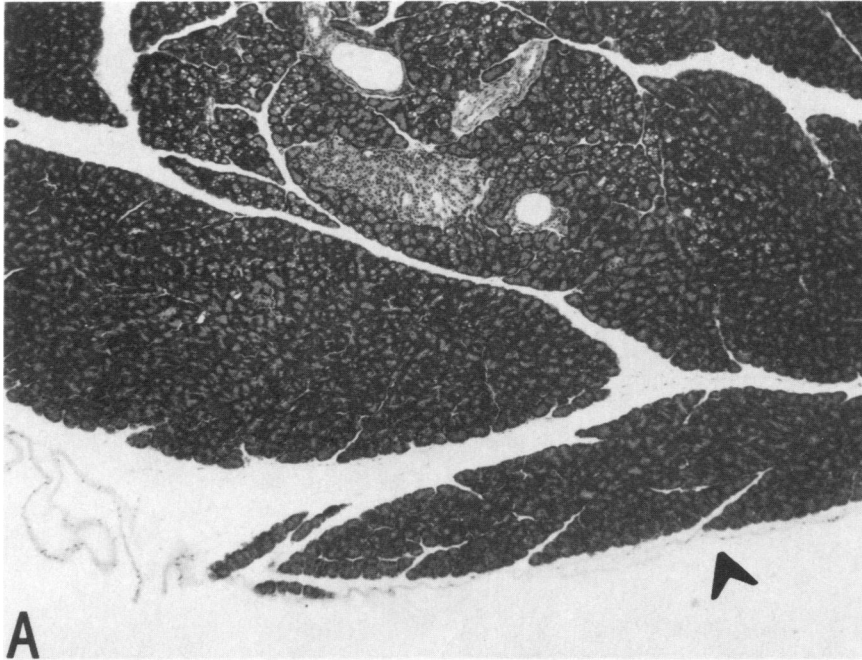
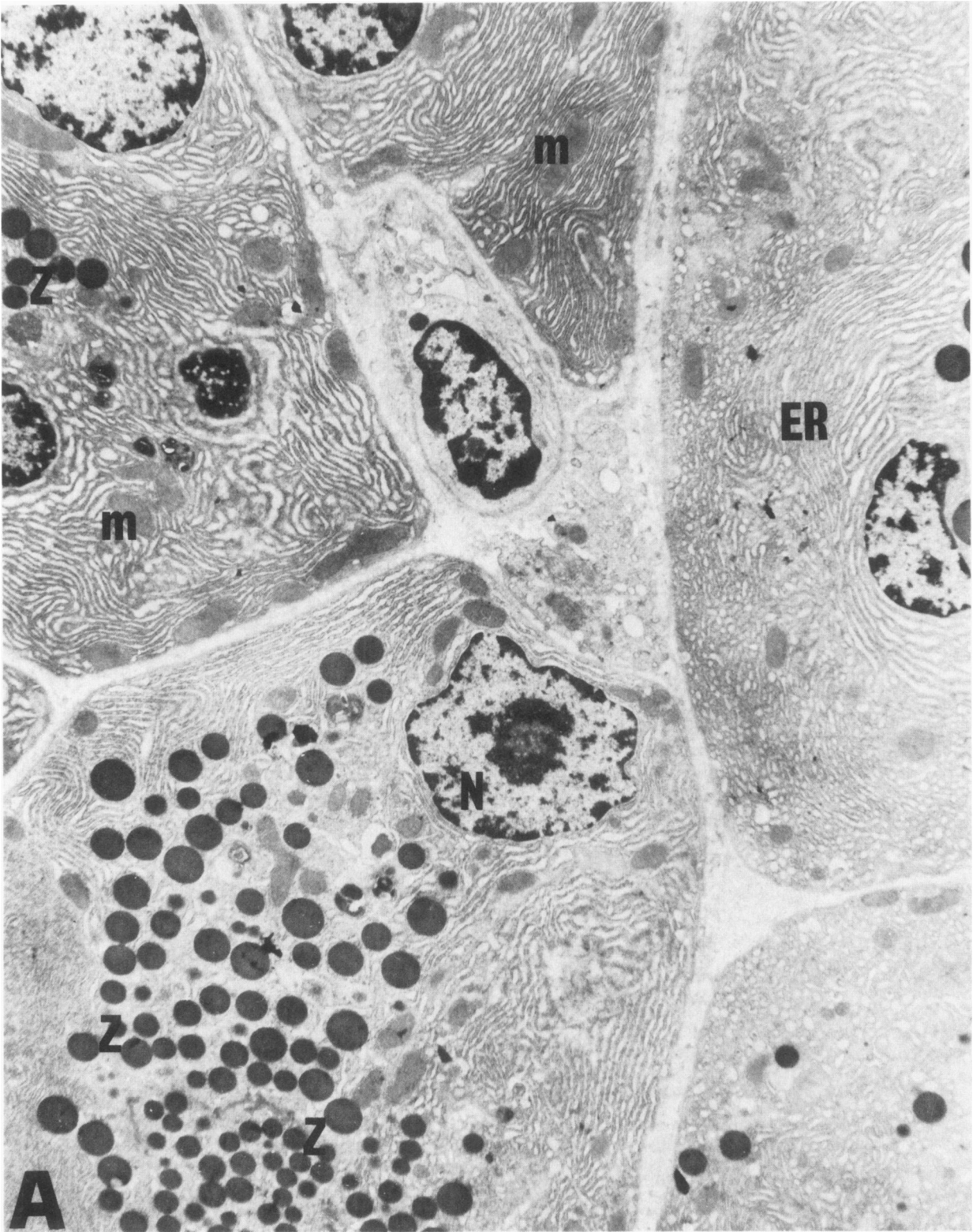
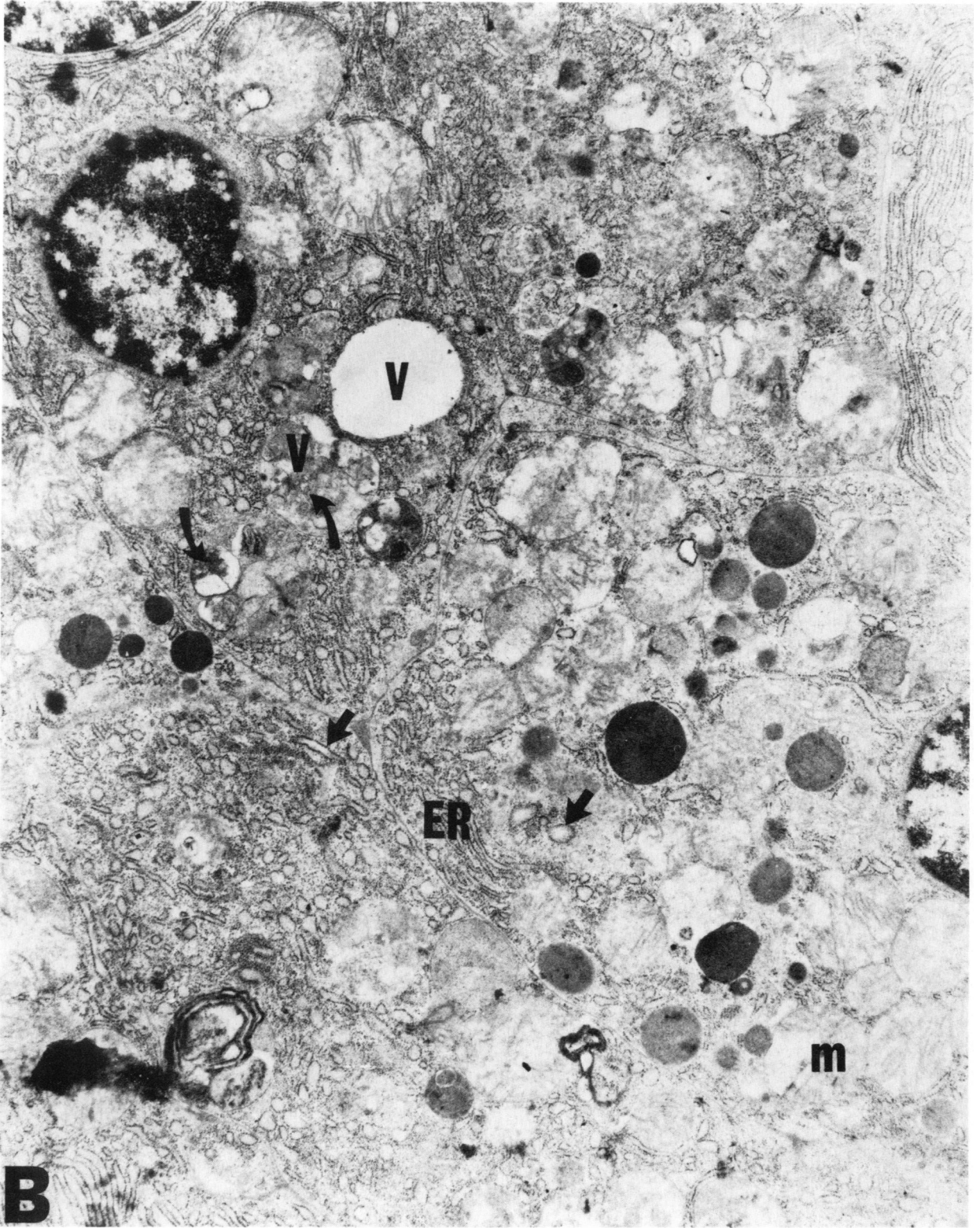
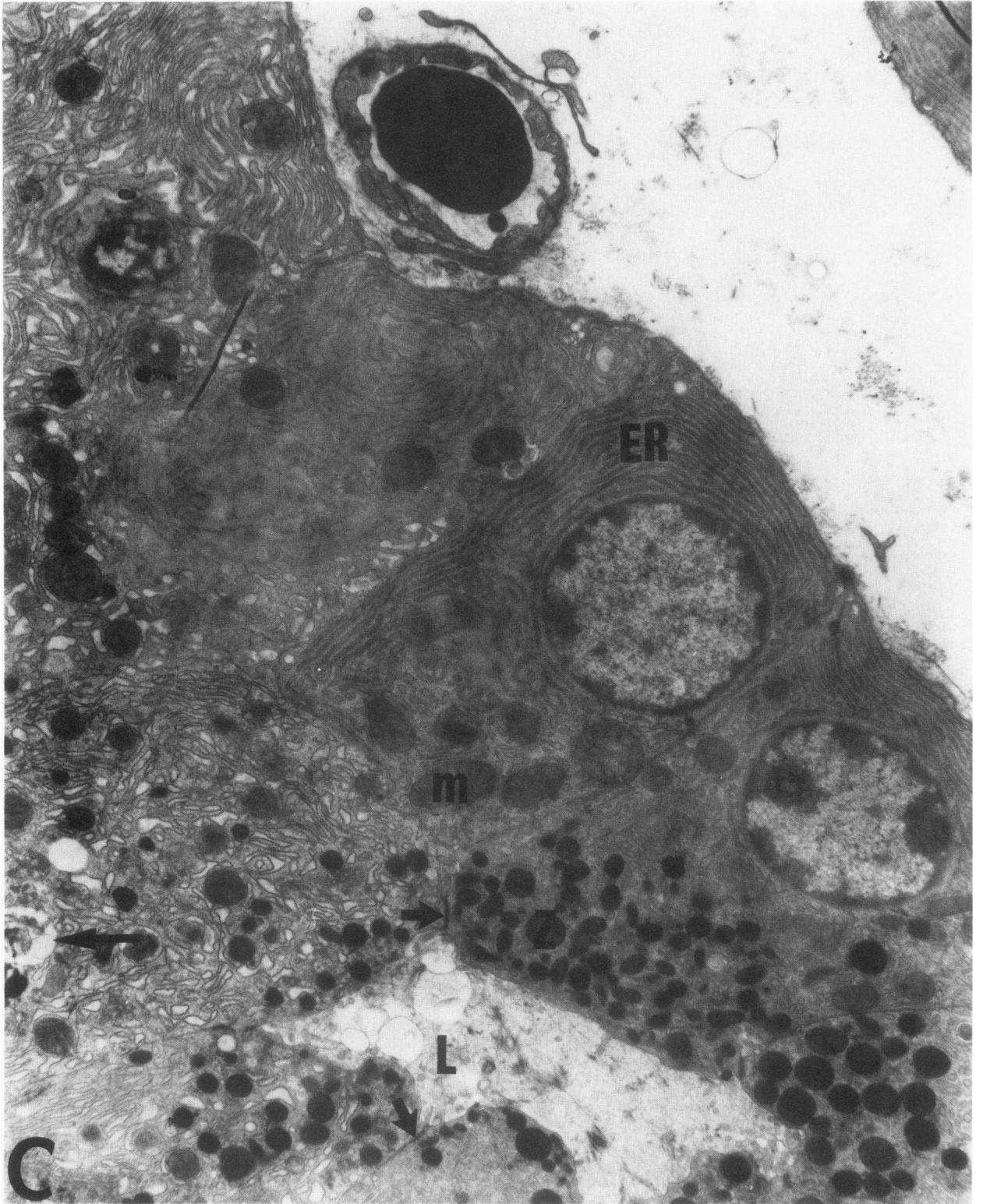


FIGURE 3 (A) 6-h animal infused with 5 CU of secretin/kg per h in addition to ceruletide. The capsule is tightly adherent to the lobules (arrowhead). There is minimal intralobular separation and a virtual absence of interstitial edema. $\times 40$. (B) High power views of the acinar structure revealing an almost normal cellular pattern. Although minor vacuolization (small arrows) is present in some cells, the basolateral areas (large arrows) of each cell appear undisturbed $\times 950$.







from three 6-h saline-treated controls, three ceruletide-treated animals, and one animal treated with 5 CU secretin/kg per h plus 5 μ g ceruletide/kg per h. Fig. 4 A shows the representative appearance of normal acinar cells in a saline-treated control rat with zymogen granules oriented toward the apical cell membrane. Fig. 4 B illustrates a representative characteristic feature of early AP in a ceruletide-treated rat with fusion of zymogen granules to form vacuoles and loss of normal architecture of the acinar cells. Fig. 4 C illustrates the protective effect of secretin on ceruletide-induced AP in one animal treated with 5 CU of secretin. There is normal migration of zymogen granules toward the apical zone of the acinar cells. The tight junctions are clearly seen and little cellular disorganization compared with the ceruletide-treated rat is evident. Clearly illustrated is the presence of a grossly dilated acinar lumen suggesting that active secretion of enzymes through the normal route is occurring (11).

Biochemical results. Basal serum amylase concentrations in all rat treatment groups did not differ significantly from one another, nor were significant differences apparent in serum amylase values at any time interval in saline-treated controls (Table I) or in rats treated with secretin alone (data not shown).

Infusion of ceruletide (5 μ g/kg per h) produced 2.3- and 3.4-fold elevations in serum amylase concentrations over basal values at 3 and 6 h, respectively (Table I). Serum amylase concentrations after 3 h infusion of 1 CU of secretin plus ceruletide were significantly lower than levels in animals infused for 3 h with ceruletide alone (Table I). However, at 6 h there was no significant difference between the two groups. By contrast, in rats treated with 5 CU of secretin plus 5 μ g of ceruletide/kg per h serum amylase levels were sig-

nificantly reduced to \sim 50% of the corresponding 3 and 6 h values of animals infused with ceruletide alone (Table I).

At 6 h after the beginning of treatment, serum lipase levels in ceruletide-treated animals were significantly greater than those obtained in control animals and those treated with either of the combination dosages of secretin plus ceruletide (Table II). Serum trypsinogen levels in animals infused for 6 h with 1 CU of secretin plus 5 μ g of ceruletide/kg per h were lower than values obtained for animals treated with ceruletide alone, but the difference was not statistically significant. However, increasing the dose of secretin to 5 CU/kg per h caused a significant reduction in serum trypsinogen to \sim 45% of values observed in ceruletide-treated animal. (Table II).

In ceruletide-infused rats, peritoneal fluid trypsinogen, lipase, and amylase concentrations at 6 h were elevated sevenfold, 2.5-fold, and eightfold, respectively, over values in animals infused with 5 CU/kg per h of secretin plus ceruletide. Peritoneal fluid was not present in control animals.

DISCUSSION

Intravenous administration of large pharmacological doses of ceruletide in rats has been shown by us (in this study), and by others (4, 5), to result in the development of AP.

In ceruletide-treated rats, macroscopic and microscopic evidence of AP was consistently present at 3 h and was striking by 6 h (Fig. 3, A and B) with presence of intense interstitial edema, lobulation, and intracellular disorganization of pancreatic tissue. In \sim 50% of these rats, mesenteric fat necrosis was present, a feature not previously reported in this animal model of

FIGURE 4 (A) Electron micrograph of pancreatic acinar cells from a 6-h, saline-treated control rat illustrating normal acinar cellular architecture with zymogen granules (Z) oriented toward the apical cell membrane. Mitochondria (m), nucleus (N) and endoplasmic reticulum (ER) are well demonstrated. \times 7,200. (B) Electron micrograph of acinar cells from a rat treated with 5 μ g of ceruletide/kg per h for 6 h showing generalized disorganization. Mitochondria (m) exhibit a swollen appearance with extensive disruption of cristae. The endoplasmic reticulum (ER) shows a loss of normal regular pattern (compared with A) with sequestration into either narrow or dilated irregular sacs (small arrows). Depletion of normal zymogen granules is evident and large autophagic vacuoles (V) are present containing electron dense material (large arrows). \times 8,500. (C) Electron micrographs of pancreatic acinar cells from a rat treated for 6 h with 5 CU of secretin/kg per h plus ceruletide. Cellular architecture closely resembles that of the saline-infused control rat acini (A). The mitochondria (m) do exhibit minor swelling although the cristae do not appear disrupted. The endoplasmic reticulum (ER), in contrast to the ceruletide-treated rat (B), does not exhibit extensive dilatation and fragmentation. The zymogen granules (Z) are plentiful and oriented toward the apical membrane and the centroacinar lumen (L). The centroacinar lumen is widely dilated and contains electron-dense and -light material. Tight junctions (small arrows) are clearly evident. Minor vacuolization (large arrow) is present, but minimal compared with changes observed in the ceruletide-treated animal (B). \times 7,200.

TABLE I
Serum Amylase Concentrations in Unconscious Rats after Constant Jugular Vein Infusions of Saline, Ceruletide, or Combinations of Secretin plus Ceruletide (Means±SEM)

Treatment group	Serum amylase (IU/ml) jugular vein infusion time			
	0	1.5	3	6
Saline controls (n = 5)	5.76±0.44	5.78±0.36	5.99±0.32	5.75±0.15
Ceruletide (n = 14) (5 µg/kg body wt per h)	5.75±0.43	7.28±0.41	13.0±0.69*	19.3±2.50*
Secretin + ceruletide (n = 11) (1 CU + 5 µg/kg body wt per h)	5.24±0.50	6.30±0.51	8.45±0.65‡	15.3±3.96
Secretin + ceruletide (n = 9) (5 CU + 5 µg/kg body wt per h)	5.46±0.35	6.70±0.48	8.30±0.54‡	10.4±1.10§

* $P < 0.001$ compared with appropriate saline-control value.

‡ $P < 0.001$ compared with appropriate ceruletide-treated value.

§ $P < 0.01$ compared with appropriate ceruletide-treated value.

AP (4, 5). Biochemical changes paralleled the severity of ceruletide-induced AP with significant elevations of serum amylase, trypsinogen, and lipase compared with saline-treated controls (Tables I and II). Of particular interest at 6 h in animals infused with ceruletide alone was the presence of several milliliters of free peritoneal fluid exhibiting massive increments in trypsinogen, lipase, and amylase levels (see Results).

Concomitant infusion of secretin (1 CU/kg per h) with ceruletide appeared to confer a variable protective effect on AP induction with a decrease in serum enzymes that, although reaching significance at 3 h, failed to achieve statistical significance at 6 h com-

pared with values in ceruletide-treated animals. Increasing the dose of secretin to 5 CU/kg per h consistently conferred striking protection with respect to macroscopic, microscopic (Fig. 3, A and B), and ultrastructural (Fig. 4 C) changes in the pancreas with significant decreases in serum amylase, trypsinogen, and lipase recorded (Tables I and II). We noted that serum enzymes in the secretin plus ceruletide-treated animals did exhibit gradual increases over saline-control values during the 6-h experiment and that a degree of pancreatic damage was apparent morphologically. These results suggest that concomitant infusion of secretin with ceruletide does not completely prevent the

TABLE II
Serum Lipase and Serum Trypsinogen Concentrations in Unconscious Rats after 6 h of Jugular Vein Infusions of Either Saline, Ceruletide, or Combinations of Secretin plus Ceruletide (Means±SEM)

Treatment group	Serum lipase	Serum trypsinogen
	<i>Sigma-Teltz Units/ml</i>	<i>ng/ml</i>
Saline controls	0.31±0.01 (n = 5)	90.4±22.2 (n = 5)
Ceruletide (5 µg/kg body wt per h)	4.89±0.42* (n = 13)	11,320±1,697* (n = 16)
Secretin + ceruletide (1 CU + 5 µg/kg body wt per h)	3.17±0.59‡§ (n = 10)	7,112±2,068‡ (n = 12)
Secretin + ceruletide (5 CU + 5 µg/kg body wt per h)	3.11±0.49*§ (n = 7)	5,041±948‡§ (n = 7)

* $P < 0.001$ vs. saline-control rats.

‡ $P < 0.01$ vs. saline-control rats.

§ $P < 0.05$ vs. ceruletide-treated rats.

onset of AP, but substantially reduces its severity. Alternatively, it is possible that secretin administration could be delaying the onset of ceruletide-induced AP. The answer to this latter question can only be addressed by future experiments involving long-term conscious animals.

The novel concept that secretin might exert a protective effect on AP came from studies in humans (unpublished data). When incremental intravenous bolus doses of cholecystokinin-pancreozymin without secretin were given to three healthy volunteers undergoing intraductal pancreatic cannulation (without pancreatograms), no flow of pure pancreatic juice was observed. Subsequently, each subject developed abdominal pain and elevated serum enzymes consistent with AP. By contrast, healthy volunteers (12), chronic alcoholics (13), and patients with known pancreatic disease (14, 15) given the same intravenous bolus doses of cholecystokinin-pancreozymin simultaneously with secretin (without pancreatograms) did not develop any adverse sequelae.

Secretin acts via cyclic AMP to stimulate a flow of bicarbonate- and electrolyte-rich ductular secretion (16). The process by which secretin confers protection in our model of AP is at present purely conjectural. In electron microscopic studies on acinar cells in scorpion venom-induced canine AP (6, 7), and in the present work using ceruletide in the rat (Fig. 2, B and C), we have observed in the absence of exogenous secretin a randomized dispersion of zymogen granules away from the apical membrane. These zymogen granules subsequently fuse to form progressively larger vacuoles, migrate to the basolateral membrane of the acinar cell, and finally rupture into the interstitial space (4-7, 17).

The present study demonstrates a protective effect of secretin on ceruletide-induced AP. High resolution light microscopy of acinar cells in all secretin-treated rats and electron microscopy of one randomly selected animal in this treatment group (Figs. 3, A and B and 4 C) provide evidence that secretin prevents the randomized dispersion of zymogen granules away from the acinar cell apical membranes and in some as yet unknown manner facilitates their discharge via the normal secretory pathway. This process appears to prevent intracellular disruption of zymogen granules and their fusion to the basolateral membranes with subsequent development of interstitial edema as observed in the ceruletide-treated rat (Figs. 2, B and C and 4, B and C).

Previous workers (18) have shown that adsorption of secretin on the surface of glass or plastic may result in a rapid decrease of its biological potency. Thus, it is possible that the results reported by us may reflect

the effect of much lower doses of secretin than indicated in this paper.

In the present study, we have shown that secretin given concomitantly with ceruletide significantly attenuates AP in rats. In recent preliminary experiments (unpublished data) we have also shown that secretin exerts an ameliorative effect on established AP in unconscious rats. It is conceivable that secretin might exert a beneficial effect on human AP.

ACKNOWLEDGMENTS

We thank Dr. Hugh Edmundson of the University of Southern California (USC) School of Medicine for his aid in light microscopic histological interpretations and Dr. Bernard Slavin for his help in interpretation of ultrastructural detail. We are indebted to Mr. John D. Hardy of the Cardiovascular Research Laboratory, USC School of Medicine for expert technical assistance in electron microscopy and to Mr. Andy Gero for photographic work.

This work was supported in part by a Biomedical Research Support Grant (2S07RR05356-21) from the USC School of Medicine, a Wright Foundation Grant (70), and by a donation from Pharmacia Laboratories.

REFERENCES

1. Jacobs, M. L., W. M. Daggett, J. M. Civetta, A. Vasu, D. W. Lawson, A. L. Warshaw, G. L. Nardi, and M. K. Bartlett. 1977. Acute pancreatitis: analysis of factors influencing survival. *Ann. Surg.* 185:43-51.
2. Ranson, J. H. C., K. M. Rifkind, and J. W. Turner. 1976. Prognostic signs and nonoperative peritoneal lavage in acute pancreatitis. *Surg. Gynecol. Obstet.* 143:209-219.
3. Imrie, C. W., and A. S. Whyte. 1975. A prospective study of acute pancreatitis. *Br. J. Surg.* 62:490-494.
4. Lampel, M., and H. F. Kern. 1977. Acute interstitial pancreatitis in the rat induced by excessive doses of pancreatic secretagogue. *Virchows Arch. A Pathol. Anat. Histol.* 373:97-117.
5. Adler, G., T. Hupp, and H. F. Kern. 1979. Course and spontaneous regression of acute pancreatitis in the rat. *Virchows Arch. A Pathol. Anat. Histol.* 382:32-47.
6. Renner, I. G., J. L. Pantoja, S. B. Abramson, A. P. Douglas, F. E. Russell, and M. Koch. 1983. Effects of scorpion and rattlesnake venoms on the canine pancreas following pancreaticoduodenal arterial injections. *Toxicol.* 21:405-420.
7. Pantoja, J. L., I. G. Renner, S. B. Abramson, and H. Edmundson. 1983. The production of acute hemorrhagic pancreatitis in the dog using venom of the scorpion, *Buthus quinquestriatus*. *Dig. Dis. Sci.* 28:429-439.
8. Petersen, H., and M. I. Grossman. 1977. Pancreatic exocrine secretion in anesthetized and conscious rats. *Am. J. Physiol.* 233:E530-E533.
9. Rinderknecht, H., N. F. Adham, I. G. Renner, and S. B. Abramson. 1982. Diagnosis of pancreatic disease by fluorometric determination of plasma trypsinogen. Progress in Clinical Enzymology. II: Masson Publishing USA, Inc., New York.
10. Steele, R. G. D., and J. H. Torie. 1960. Principles and Procedures of Statistics. McGraw-Hill Book Co., Inc., New York. 99-131.

11. Kim, S. K., P. A. Weinhold, D. W. Calkins, and V. W. Hartog. 1981. Comparative studies of the age-related changes in protein synthesis in the rat pancreas and parotid gland. *Exp. Gerontol.* 16:91-99.
12. Rinderknecht, H., I. G. Renner, A. P. Douglas, and N. F. Adham. 1978. Profiles of pure pancreatic secretions obtained by direct pancreatic duct cannulation in normal healthy human subjects. *Gastroenterology.* 75:1083-1089.
13. Renner, I. G., H. Rinderknecht, J. E. Valenzuela, and A. P. Douglas. 1980. Studies of pure pancreatic secretions in chronic alcoholic subjects without pancreatic insufficiency. *Scand. J. Gastroenterol.* 15:421-424.
14. Renner, I. G., H. Rinderknecht, and A. P. Douglas. 1978. Profiles of pure pancreatic secretions in patients with acute pancreatitis: the possible role of proteolytic enzymes in pathogenesis. *Gastroenterology.* 75:1090-1098.
15. Rinderknecht, H., I. G. Renner, and N. H. Stace. 1983. Abnormalities in pancreatic secretory profiles of patients with cancer of the pancreas. *Dig. Dis. Sci.* 28:103-110.
16. Jensen, R. T., and J. D. Gardner. 1981. Identification and characterization of receptors for secretagogues on pancreatic acinar cells. *Fed. Proc.* 40:2486-2496.
17. Renner, I. G., and M. Koch. 1981. Electron microscopic changes in scorpion venom induced acute hemorrhagic pancreatitis in the dog. *Gastroenterology.* 8:1260.
18. Beyerman, H. C., M. I. Grossman, T. Scratcherd, T. E. Solomon, and D. Voskamp. 1981. On the instability of secretin. *Life Sciences.* 29:885-94.