

# Argon Laser Management of Cutaneous Vascular Deformities

## A Preliminary Report

DAVID B. APFELBERG, MD, MORTON R. MASER, MD, and HARVEY LASH, DDS, MD  
*Palo Alto, California*

*Twenty-two patients with cutaneous vascular malformations were treated with an argon laser. Promising results were obtained in patients with port-wine stains, hemangiomas, telangiectasia and varicose veins. The argon laser shows promise as an effective clinical tool in the treatment of all such cutaneous vascular abnormalities. However, further study of clinical as well as laboratory data is necessary over a long period of time before this modality can be definitely recommended as the treatment of choice for vascular deformities of the skin.*

LASERS HAVE BEEN USED in medicine for a variety of surgical and nonsurgical problems for many years.<sup>1-7</sup> The Palo Alto Medical Clinic Department of Plastic and Reconstructive Surgery has been engaged in a pilot project investigating the use of argon lasers in the treatment of cutaneous vascular abnormalities. A study of 22 patients representing four major categories of lesions—port-wine hemangiomas, cavernous and capillary hemangiomas, telangiectasia and superficial varicose veins—has now been completed. Results in this group of patients were evaluated using clinical, photographic and biopsy studies. This new mode of treatment is as yet preliminary; however,

results thus far appear to be encouraging. A second study group of 100 patients has been approved and is now in the process of being assembled.

### Discussion of Clinical Data

Twenty-two patients were treated at the Palo Alto Medical Clinic with an argon laser in a five-year study (Table 1). The diagnosis by category was port-wine hemangiomas, seven patients; varicose veins, nine patients; hemangiomas of the capillary or cavernous variety, two patients, and telangiectasia, four patients. Follow-up intervals have averaged 18 months for those with port-wine hemangiomas, 15 months for those with varicose veins, 10 months for those with capillary or cavernous hemangiomas and 13 months for the telangiectasia group. The average age of the patients with port-wine stains was 26.7 years; with hemangiomas, 25 years; with varicose veins, 40.9

From the Department of Plastic and Reconstructive Surgery, Palo Alto Medical Clinic.

Presented in part at the California Society of Plastic Surgery meeting, Monterey, California, April 23, 1975.

Submitted May 12, 1975.

Reprint requests to: D. B. Apfelberg, MD, Dept. of Plastic and Reconstructive Surgery, Palo Alto Medical Clinic, 300 Homer Avenue, Palo Alto, CA 94301.

CUTANEOUS VASCULAR DEFORMITIES

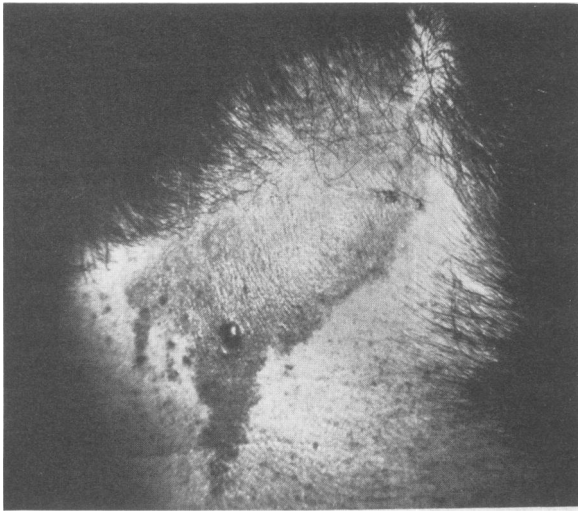


Figure 1.—Port-wine hemangioma of left upper forehead and hairline.

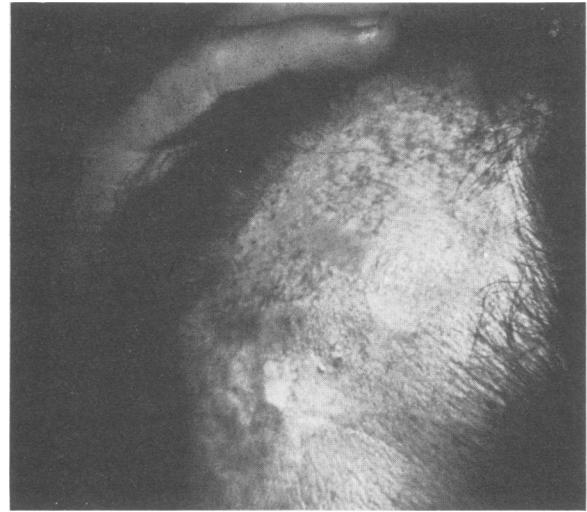

Figure 2.—Complete obliteration of majority of port-wine stain with no scarring.

years, and with telangiectasia, 35 years. There were very few associated diseases in any of the patients. Only the patients with varicose veins showed a family history correlated to the mother. It should be emphasized that the varicose vein group included those superficial varicosities that were found on the skin surface and were not the common greater and lesser saphenous varicose veins that are connected to the deep system. No patient had significant cardiorespiratory disease, was taking continuing medications or had significant allergies. The laser treatment power and dosage were correlated for each category and, remarkably, almost every category received ap-

proximately the same treatment regimen. Spot size averaged 1 mm, power averaged 1.5 watts (although later in the study, 1.8 watts was found to be the optimal dosage), time per exposure averaged 0.2 seconds. Only in the amount of exposures, that is the number of repetitive beams per time, were the categories notably different. The port-wine stain group received an average of 691 exposures per treatment correlating with the large size, mass and area of these lesions, and the desire of the patient and the physician to treat a greater percentage of the area during each laser treatment. The other categories received an average of 53 to 93 exposures per treatment.

TABLE 1.—Summary of Data for 22 Patients Treated

		Avg. Length Follow-up (months)	Avg. Age (years)	Spot Size	Time (sec.)	Exposures	Power (watts)
Port Wine	7	18	26.7	1 mm	.2	691	1.5
Varicose veins	9	15	40.9	1 mm	.2	93	1.5
Hemangioma	2	10	25	1 mm	.2	53	1.5
Telangiectasia	4	13	35	1 mm	.2	90	1.5

TABLE 2.—Results of Argon Laser Treatment in 22 Patients

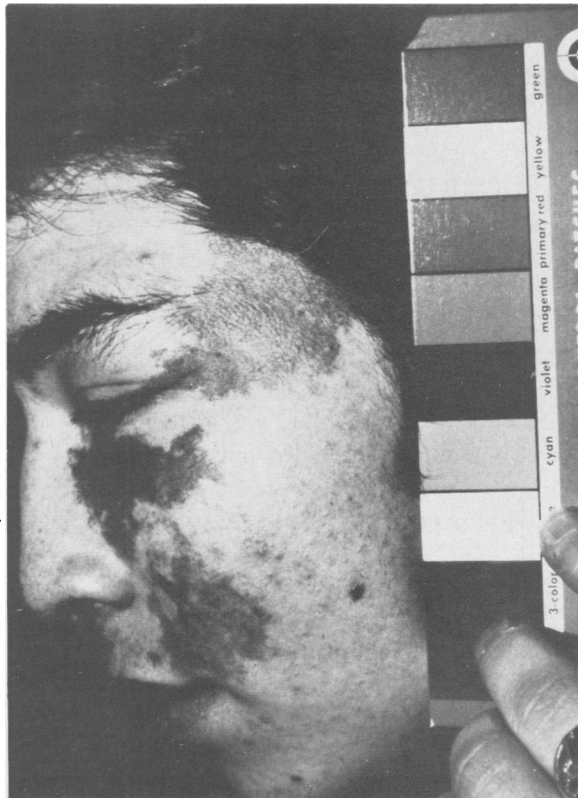	Excellent	Good	Fair	No Change	Complications
Port wine	7	4	3	..	.....
Varicose veins	9	..	..	1	8 minor scarring
Hemangioma	2	..	1	1	1 hypertrophic scar
Telangiectasia	4	..	2	2	.....

Biopsy Findings

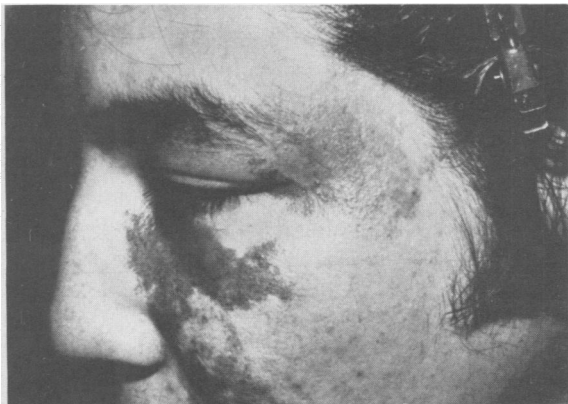1. Nonspecific dermal fibrosis
2. Obliteration of small vessels
3. Sparing secondary skin appendages
4. Atrophy epidermis

**Results**

Complications and results (Table 2) were carefully evaluated by photographic, clinical and biopsy studies. There were only three complications or side effects in the entire series, and these were minimal. Two patients with varicose veins reported some very minor scarring which was not disfiguring. One patient in the hemangioma group



**Figure 3.**—Typical port-wine stain of left forehead, eyelids, cheek, nose and upper lip.

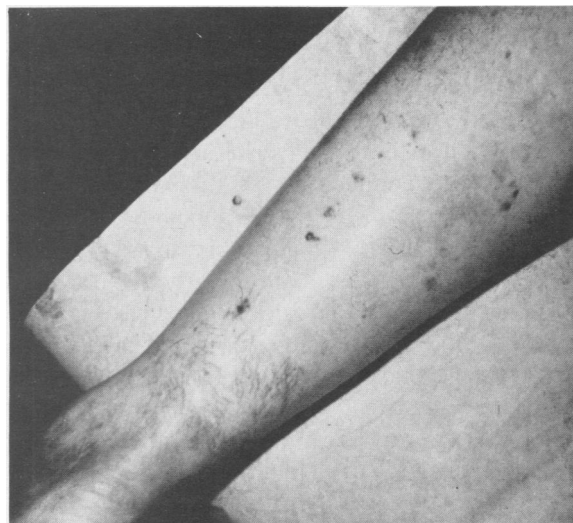


**Figure 4.**—Complete obliteration of forehead area of stain without scars. Remainder of face is under treatment at present.

underwent a hypertrophic change. Results have been evaluated and are divided into four categories: excellent, good, fair and no change. In the seven patients in the port-wine stain group, results were excellent in four and good in three (Figures 1 through 4). In the nine patients with varicose veins, there was a fair result in one, no significant change in six and no significant change but minor scarring in two. Later in the series as power was increased, satisfactory results were obtained in most of the varicose vein group (Figure 5). In the patients with telangiectasia there were two good results and two fair results. In the patients with hemangiomas, there was one good result and one fair result, the patient with the fair result having had the hypertrophic scar. Thus it appears that laser treatment is very promising for port-wine stains and of moderate-to-good effectiveness in treating telangiectasia, hemangiomas and varicose veins. Results of biopsy studies showed nonspecific subdermal fibrosis, obliteration of small vessels and sparing of secondary skin appendages, with mild atrophy of the epidermis.

**REFERENCES**

1. Little H: Lasers in medicine. *J Okla State Med Assoc* 64: 223-226, Jun 1971
2. Ketcham AS, Hoyer RC, Riggle GC: A surgeon's appraisal of the laser. *Surg Clin North Am* 47:1249-1263, 1967
3. Levine N, Ger R, Stellar S, et al: Use of a carbon dioxide laser for the debridement of third degree burns. *Ann Surg* 179: 246-252, Feb 1974
4. Stellar S, Meijer R, Sardar W, et al: Carbon dioxide laser debridement of decubitus ulcers. *Ann Surg* 179:230-237, Feb 1974
5. Zweng HC: Current status of laser ophthalmology. *Laser Focus Magazine Advanced Technology Publications*, Sep 1967
6. Kitzmiller KW: Laser treatment of tattoos and angiomas. *J Med Assoc Ga* 59:385-386, Oct 1970
7. Goldman L: Effects of new laser systems on the skin. *Arch Dermatol* 108:385-390, Sep 1973



**Figure 5.**—Ankle and Achilles tendon area is untreated and posterior calf has been treated with complete obliteration of superficial network of varicose veins similar to those present on ankle.