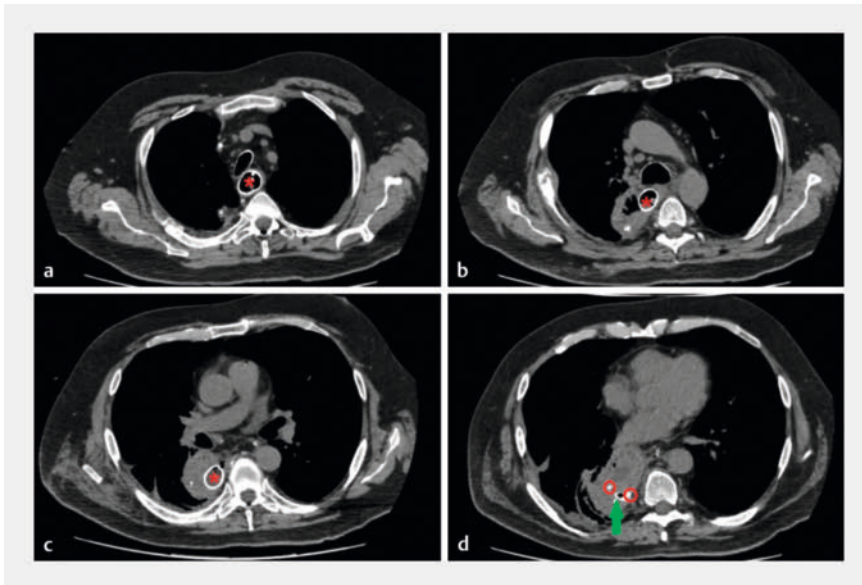
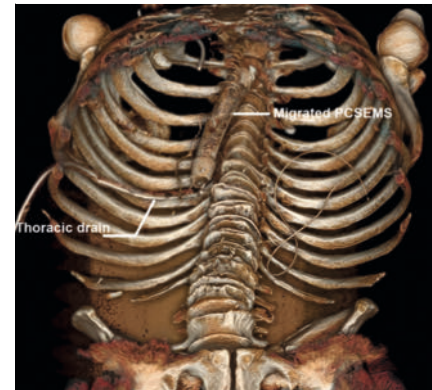


Rescue endoscopic treatment with completion by radical surgery following misplacement of a partially covered metal stent in an anastomotic fistula post-Lewis Santy esophagectomy


OPEN
ACCESS



► **Fig. 1** Computed tomography images from the initial scan showing: **a** the partially covered self-expandable metal stent (PCSEMS; red star) within the esophageal lumen; **b** the PCSEMS passing into the mediastinal cavity through the anastomotic fistula; **c** the PCSEMS within the mediastinal cavity, with a fluid and air-containing collection in this area; **d** the distal flange of the stent (red circles) in contact with the thoracic drain (green arrow).



► **Fig. 2** 3D reconstruction from the initial computed tomography scan showing that the stent has migrated into the mediastinal cavity through the anastomotic fistula orifice.



► **Video 1** Endoscopic procedures are performed firstly to re-establish digestive continuity for optimal nutrition and the anastomotic fistula is excluded by placing a fully covered self-expandable metal stent alongside the partially covered self-expandable metal stent (PCSEMS) that had migrated into the anastomotic fistula; the stent-in-stent technique is subsequently attempted for extraction of the PCSEMS.

Curative management of esophageal adenocarcinoma is based on esophagectomy. One of the main complications is anastomotic fistula (30%) [1], which is responsible for significant postoperative morbidity and mortality, as well as reduced survival [2]. In recent years, endoscopic treatment of anastomotic fistulas has become a valuable option, enabling closure of the fistula and a reduction in the mortality rate [3,4].

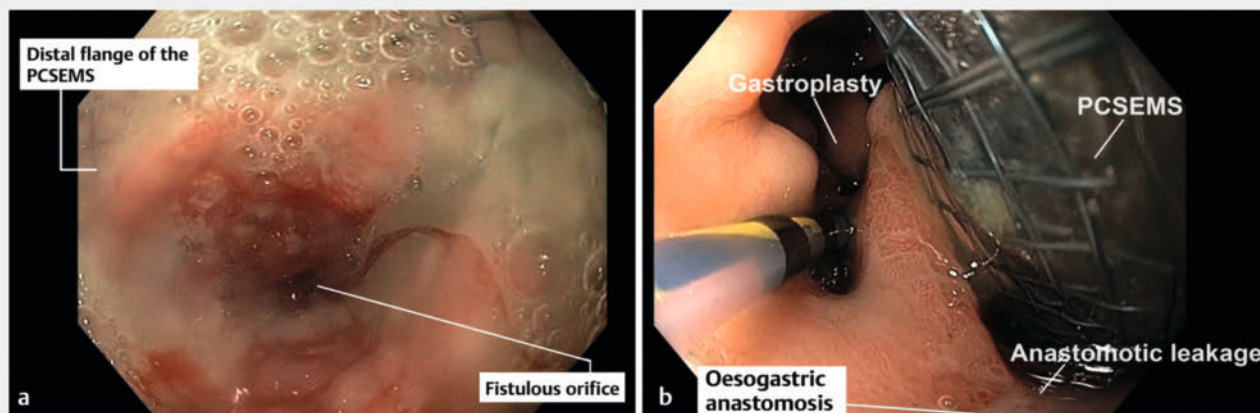
We report the case of a 55-year-old patient who underwent a Lewis Santy esophagectomy for esophageal adenocarcinoma. The patient developed an anastomotic fistula with a pleural abscess requiring antibiotics, thoracic drainage, and placement of a partially covered self-expandable metal stent (PCSEMS) to cover the fistula. However, the thoracic drainage remained highly productive and an endoscopy revealed migration of the stent's distal flange, with em-

bedment into the fistula (► **Fig. 1** and ► **Fig. 2**). After several unsuccessful attempts at endoscopic removal, the patient was transferred to our center.

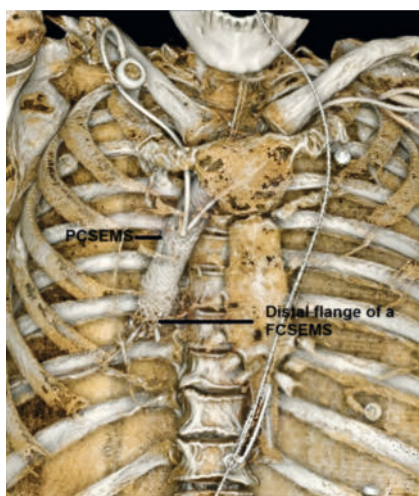
He presented to us with a chronic pleural infection and total dependence on parenteral nutrition. An endoscopic procedure to re-establish digestive continuity was planned. The lower pole of the fibrin-wrapped stent and a productive fistulous orifice were identified (► **Fig. 3**). We managed to pass the scope in parallel to the stent to gain access to the gastroplasty. After a guidewire had been positioned in the gastroplasty, a fully covered metal stent (FCSEMS) was placed in parallel and successfully re-established digestive continuity and excluded the fistula (► **Video 1**).

The FCSEMS was removed after 3 months, but the PCSEMS remained irremovable. After discussion with the surgical team, it was decided to try the stent-in-stent

technique [5], and a new FCSEMS was inserted inside the PCSEMS (► **Fig. 4**). A further endoscopy was performed 2 weeks later, at which the FCSEMS was



► **Fig. 3** Endoscopic images from the first procedure performed in our center showing: **a** the fistulous orifice and incarceration of the distal flange of the partially covered self-expandable metal stent (PCSEMS); **b** the gastroplasty and passage of the PCSEMS through the fistulous orifice.



► **Fig. 4** 3D reconstruction from the CT scan performed after placement of a fully covered self-expandable metal stent (FCSEMS) within the partially covered self-expandable metal stent (PCSEMS) for the stent-in-stent technique.

removed without difficulty, but the PCSEMS remained embedded. Given the impossibility of endoscopic PCSEMS removal, it was decided that surgical management would be required and the patient underwent surgical removal of the PCSEMS and coloplasty.

Endoscopy_UCTN_Code_TTT_1AO_2AI

Conflict of Interest

The authors declare that they have no conflict of interest.

The authors

Pierre Mayer^{1,2}, **Lucile Héroin**^{1,2}, **François Habersetzer**^{1,2,3}, **Pierre-Yves Christmann**^{1,2}, **Jérôme Huppertz**^{4,2}, **Leonardo Sosa-Valencia**⁵, **Abdenor Badaoui**⁶

- 1 Department of Gastroenterology and Hepatology, University Hospitals Strasbourg, Strasbourg, France
- 2 Digestive Endoscopy Unit, IHU Strasbourg, Strasbourg, France
- 3 Inserm U1110, Université de Strasbourg, Strasbourg, France
- 4 Department of Hepatogastroenterology, Clinique Sainte Barbe, Strasbourg, France
- 5 Research, IHU Strasbourg, Strasbourg, France
- 6 Department of Gastroenterology and Hepatology, CHU UCL Namur, Yvoir, Belgium

Corresponding author

Pierre Mayer, MD

Department of Gastroenterology and Hepatology, Pôle des Pathologies Hépatiques et Digestives, Nouvel Hôpital Civil, Hôpitaux Universitaires de Strasbourg (HUS), 1 place de l'Hôpital, 67000 Strasbourg, France
 pierre-emmanuel.mayer@chru-strasbourg.fr

References

- [1] Ubels S, Verstegen MHP, Klarenbeek BR et al. Treatment of anastomotic leak after oesophagectomy for oesophageal cancer: large, collaborative, observational TENTACLE cohort study. *Br J Surg* 2023; 110: 852–863. doi:10.1093/bjs/znad123

- [2] Hagens ERC, Reijntjes MA, Andereg MCJ et al. Risk factors and consequences of anastomotic leakage after esophagectomy for cancer. *Ann Thorac Surg* 2021; 112: 255–263. doi:10.1016/j.athoracsur.2020.08.022
- [3] Spaander MCW, Baron TH, Siersema PD et al. Esophageal stenting for benign and malignant disease: European Society of Gastrointestinal Endoscopy (ESGE) Clinical Guideline. *Endoscopy* 2016; 48: 939–948. doi:10.1055/s-0042-114210
- [4] Gonzalez J-M, Servajean C, Aider B et al. Efficacy of the endoscopic management of postoperative fistulas of leakages after esophageal surgery for cancer: a retrospective series. *Surg Endosc* 2016; 30: 4895–4903. doi:10.1007/s00464-016-4828-7
- [5] Hirdes MMC, Siersema PD, Houben MHMG et al. Stent-in-stent technique for removal of embedded esophageal self-expanding metal stents. *Am J Gastroenterol* 2011; 106: 286–293

Bibliography

Endoscopy 2024; 56: E716–E717
 DOI 10.1055/a-2371-0827
 ISSN 0013-726X
 © 2024. The Author(s).

This is an open access article published by Thieme under the terms of the Creative Commons Attribution License, permitting unrestricted use, distribution, and reproduction so long as the original work is properly cited.
 (https://creativecommons.org/licenses/by/4.0/)
 Georg Thieme Verlag KG, Rüdigerstraße 14, 70469 Stuttgart, Germany

