



# UTILITY OF AN ALPHA-1 ADRENERGIC AGONIST IN THE MANAGEMENT OF CHYLOTHORAX: A CASE SERIES AND MANAGEMENT ALGORITHM

Ruben Peralta<sup>1,2</sup>, Ahmed F. Ramzee<sup>1</sup>, Zeenat Khuda Bakhsh<sup>1</sup>, Ayman El-Menyar<sup>3,4</sup>, Ahmed Ajaj<sup>1</sup>, Hassan Al-Thani<sup>1</sup>

<sup>1</sup> Department of Surgery, Trauma Surgery, Hamad Medical Corporation (HMC), Doha, Qatar

<sup>2</sup> Department of Surgery, Universidad Nacional Pedro Henriquez Urena, Santo Domingo, Dominican Republic

<sup>3</sup> Department of Surgery, Clinical Research, Trauma & Vascular Surgery, HMC, Doha, Qatar

<sup>4</sup> Department of Clinical Medicine, Weill Cornell Medical College, Doha, Qatar

Corresponding author's e-mail: aymanco65@yahoo.com

Received: 13/06/2024

Accepted: 17/06/2024

Published: 29/07/2024

**Conflicts of Interests:** The Authors declare that there are no competing interests.

**Patient Consent:** Written informed consent from patients to secure permission for publishing their clinical history was not available for this case series. Our institution (Hamad Medical Corporation, Medical Research Center) exempted this case report and granted approval (MRC-04-24-151) for publication provided that no identifiable images or information of the patients were used. Data were collected retrospectively and anonymously with no direct contact with the patients.

This article is licensed under a [Commons Attribution Non-Commercial 4.0 License](#)

**How to cite this article:** Peralta R, Ramzee AF, Bakhsh ZK, El-Menyar A, Ajaj A, Al-Thani H. Utility of an alpha-1 adrenergic agonist in the management of chylothorax: a case series and management algorithm. *EJCRIM* 2024;11:doi:10.12890/2024\_004705

## ABSTRACT

Chylothorax is the accumulation of lymphatic fluid (chyle) within the pleural space. There are multiple causes, including traumatic and non-traumatic mechanisms. Trauma can cause disruption of the thoracic duct either by direct damage or indirect crushing or avulsion mechanisms. Non-traumatic causes include infections, inflammatory processes, malignancies, and iatrogenic injury (during surgery or central venous access). The traditional management of traumatic chylothorax has been either a conservative approach, including complete Nil Per Os (NPO), or a low-fat diet with medium-chain triglyceride supplementation with the administration of somatostatin or its analog, octreotide, versus a surgical approach consisting of thoracic duct ligation. Recently a less invasive approach via thoracic duct embolization has gained popularity. There have been a few reports of the successful use of an  $\alpha$  1-adrenergic agonist (midodrine) as an adjunct in the conservative approach. We describe the utility of midodrine in three cases of chylothorax and propose a management algorithm.

## KEYWORDS

Chylothorax,  $\alpha$ 1-adrenergic agonist, chest, octreotide, algorithm

## LEARNING POINTS

- The initial diagnosis of chylothorax is based on clinical suspicion and proper imaging.
- The clinical success of midodrine use as a first-line medical treatment for chylothorax will support the use of midodrine before considering invasive procedures.
- We propose a management algorithm for patients with chylothorax that will stimulate researchers to conduct prospective studies to assess its efficacy.



## INTRODUCTION

The confluence of all lymphatic channels from the body below the diaphragm forms the thoracic duct. The thoracic duct originates from the cisterna chyli and continues cranially through the aortic hiatus of the diaphragm to the right of the aorta and maintains its course until it turns left to drain into the left subclavian vein in the neck<sup>[1]</sup>. Close proximity to the aorta, esophagus, and vertebrae places the thoracic duct at an increased risk of injury following trauma to these structures.

Chylothorax is accumulation of chyle within the pleural space. It can be due to trauma, infections, inflammatory processes, or malignancies. Direct trauma to the thoracic duct or via iatrogenic injury during surgery or insertion of central venous lines can result in chylothorax<sup>[1]</sup>. Penetrating trauma results in direct injury to the duct, while blunt trauma can cause avulsion or crushing of the duct<sup>[2]</sup>.

Superior vena cava (SVC) obstruction is a rare cause of chylothorax. It is suggested that SVC occlusion leads to back pressure in the thoracic duct, which leads to the extravasation of the chyle<sup>[3]</sup>. We describe the utility of midodrine in three cases of chylothorax and propose a management algorithm.

## CASE DESCRIPTION

**Case 1:** A 33-year-old male was involved in a motorcycle crash and sustained multiple injuries including blunt chest trauma. A right-sided chest tube drained nearly 500 ml blood. He underwent a below-knee amputation. The postoperative course was remarkable for persistent discharge from the chest tube, which was white, ranging from 300-500 ml / day. Pleural fluid analysis revealed triglyceride levels of 13.7 mmol/l and cholesterol levels of 1.5 mmol/l. A methylene blue test was positive and raised the possibility of chylothorax. Midodrine 30 mg three times daily along with octreotide 0.5 ml three times daily and a fat-free diet were prescribed. The chest drain output cleared and nearly halved within two days of commencement of the regimen. He eventually switched to a nil per oral for a week and parenteral nutrition. Magnetic resonance lymphangiography (MRL) showed fluid leakage, probably lymph, around the supradiaphragmatic part of the inferior vena cava due to a tear of the thoracic duct at the same level (Fig. 1). The patient continued midodrine, octreotide, and a fat-free diet. After three weeks, the patient improved and complete resolution of his chylothorax was achieved. Six months of follow-up showed no evidence of a recurrent pleural effusion.

**Case 2:** A 35-year-old male was admitted, after a fall from a height, he had a sternal fracture with a right-sided minimal hemothorax, severely comminuted displaced pelvic fractures, a retroperitoneal hematoma with arterial blush, right renal and adrenal injuries. He was hypotensive, requiring vasopressor support and massive transfusion. He underwent successful bilateral internal iliac artery embolization using Gelfoam® and for the left ilio-lumbar artery using Gelfoam® and coil embolization. This was followed by a bilateral distal femur skeletal traction pin. One week later, the patient was

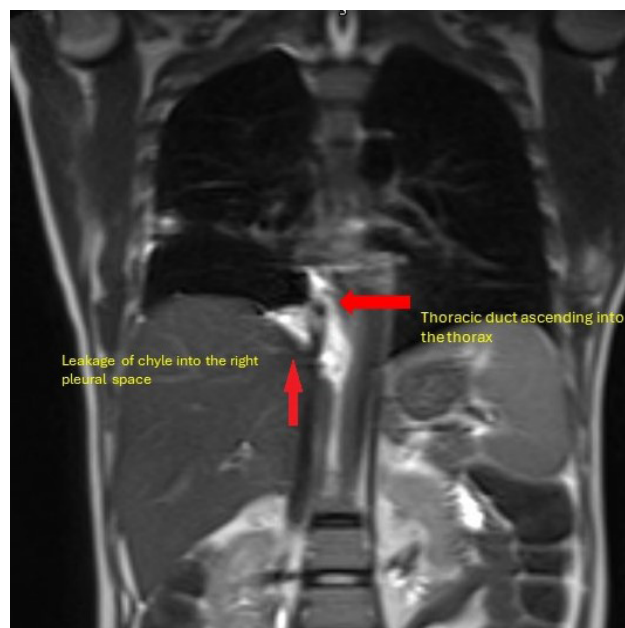


Figure 1. Magnetic resonance lymphangiography image showing chyle leak at the level of the right hemidiaphragm.



Figure 2. Chest drain with milky fluid.

taken to the operating room for pelvic fixation. However, after induction, he was desaturated, with high ventilatory pressures, and hypotensive. A central internal jugular central venous catheter was placed. A bedside ultrasound of the chest demonstrated a large right-sided effusion, and a right-sided chest tube was placed, which brought a whitish discharge of nearly 1 l (Fig. 2).

The high output of milky fluid suggested chylothorax and this was confirmed by laboratory tests (pleural fluid triglycerides - 17.9 mmol/l, cholesterol - mmol/l). Midodrine

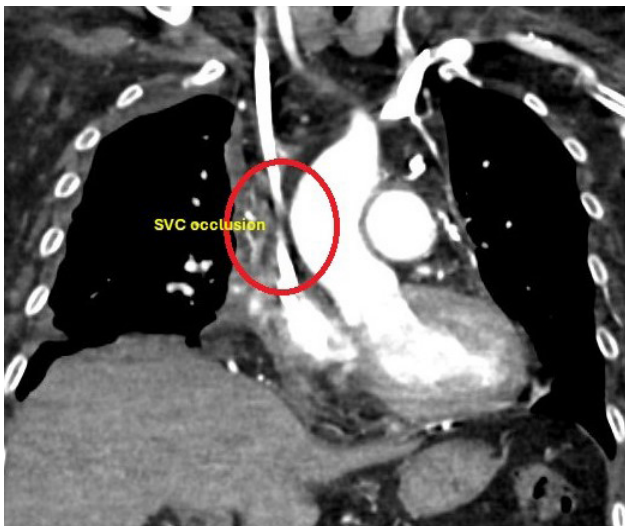

Figure 3. CT scan demonstrating SVC occlusion. Abbreviation: SVC, superior vena cava.

5 mg three times daily and octreotide 0.5 ml three times daily were initiated. The following day, after starting midodrine and octreotide, the patient's chest tube drainage was serosanguineous, and there was a significant reduction in chest drain output. The patient received a low fat and high protein diet. Over a week, the patient improved with no output from the drain, and the chest tube was removed. Follow-up X-ray showed no effusion.

Case 3: A 57-year-old female, known to have diabetes mellitus, hypertension and end-stage renal disease on hemodialysis, presented with shortness of breath. A week prior, she had been treated conservatively for a tibial plateau fracture with no significant history of trauma. Chest X-ray and computed tomography (CT) pulmonary angiogram revealed bilateral pleural effusions, more on the right side, with evidence of bilateral segmental and subsegmental pulmonary embolism. She was admitted to the intensive care unit, started on therapeutic anticoagulation, and underwent pleural tapping, which drained a large amount of milky fluid. She was started on 10 mg midodrine and octreotide and total parenteral nutrition, however the drainage persisted.

Her chest drain continued to discharge more than 1 l per day. An MRL was done. However, evidence of thoracic duct injury could not be elicited. CT imaging was performed to assess for occult malignancy and was negative except for chronic thrombosis of the proximal superior vena cava (Fig. 3). She also developed upper limb deep vein thrombosis related to a peripherally inserted central catheter. After 10 days, the midodrine dose was increased to 20 mg three times daily. Within 48 hours, the output decreased gradually, and the color and consistency cleared up (Fig. 4).

## DISCUSSION

This case series presents successful management of three chylothorax cases using midodrine as the first-line treatment. An algorithm for the management of chylothorax was proposed (Fig. 5). The initial diagnosis of chylothorax is based on clinical suspicion. Patients may present with dyspnea due to accumulation of fluid within the chest. In trauma, a patient with trauma producing copious amounts of output via a chest drain or persistent effusions should raise suspicion. The characteristic milky appearance may not always be present. Chyloptysis has been reported but is an infrequent symptom. Unlike non-traumatic causes, thoracic duct injury may lead to high output drainage (>500 ml/day) and usually present very early, usually within two days of the insult. Another non-specific finding can be reduced output during periods of fasting. Due to the predominance of lymphocytes, chyle rarely gets infected<sup>[4]</sup>.

These clinical findings would lead to the next step in the diagnostic pathway, which is the biochemical analysis of the pleural fluid. This is performed by retrieving fluid via thoracocentesis or via a previously placed chest tube. Routine imaging modalities (X-rays and CT scans) provide clues to the presence and volume of an effusion. On the contrary, dynamic contrast-enhanced MRL accurately identifies lymphatic anatomy and the source of chyle leak. The mainstay of therapy is conservative or surgical intervention. More recently, thoracic duct embolization via interventional radiology has gained popularity<sup>[1]</sup>.



Figure 4. Drainage fluid initially (on left) and after treatment (on right).

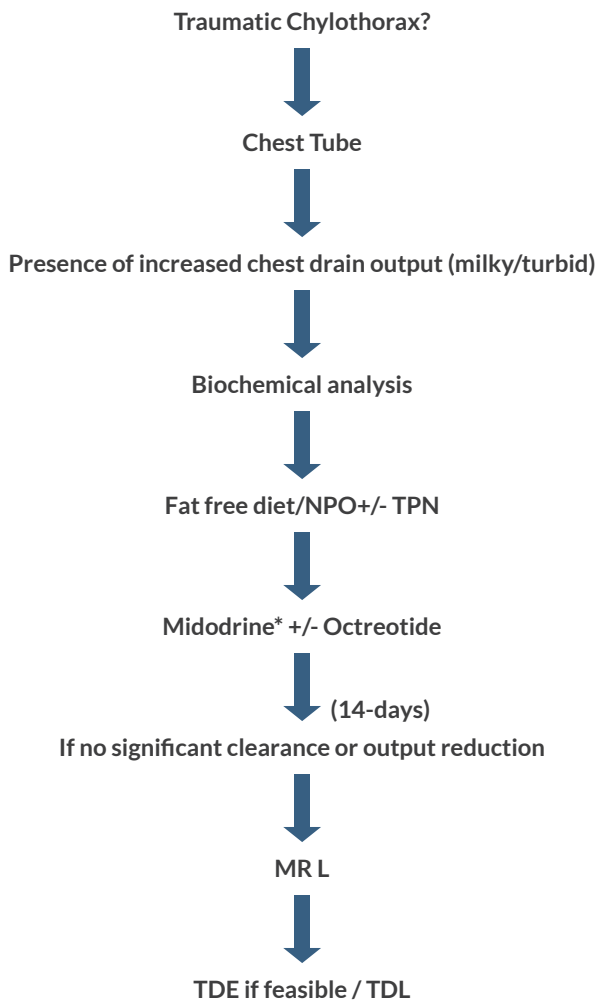


Figure 5. Algorithm for Stepwise Approach for Management of Traumatic Chylothorax.

Triglycerides - >110 mg/dL [ $>1.24$  mmol/L], Cholesterol - < 200 mg/dL (<5.18 mmol/L), Differential Counts - Lymphocyte predominant, Protein - Usually higher than serum, LDH - Lower than serum, Glucose level is similar to plasma. In a patient on TPN, if pleural/ serum glucose >1, consider central line erosion into pleural space. NPO - Nil Per Os. TPN - Total parenteral nutrition, TDE - Thoracic duct embolization. TDL - Thoracic duct ligation. MRL-magnetic resonance lymphangiography, LDH - Lactate dehydrogenase.

Medications Dosing:

- Midodrine - up to 20mg three times a day. Maximum duration unknown, has been used for more than 1 year.
- Octreotide - 50 to 200 micrograms every eight hours for up to 14 days.

The traditional approach in the initial medical management includes modification of diet (low-fat diet with medium chain triglyceride supplementation or total parenteral nutrition) and administration of either somatostatin or octreotide to reduce lymphatic output<sup>[1]</sup>. This, alone, has shown to be successful in less than 50% of patients and may be even lower in patients with high output chylothorax (>500 ml/day). Some patients may require aggressive nutritional support to counter ongoing protein losses, electrolyte imbalances, hypovolemia, and immunosuppression. The NPO status or low-fat diet helps reduce chyle production, from around 100

ml/hr in the fed state to around 14 ml/hr in the fasting state. This together with chyle being a potent irritant stimulating pleurodesis may result in spontaneous resolution of the problem<sup>[5]</sup>. However, this may be a slow process. Some researchers have advocated using somatostatin analogues such as octreotide and somatostatin, which have had favorable results in speeding up the process<sup>[6]</sup>. Octreotide is longer acting compared to somatostatin, and used following cardiothoracic surgery, as well as for chylothorax, has proven to be an effective adjunct with a significant reduction in output noted within days<sup>[6]</sup>. It acts by stimulating splanchnic vasoconstriction, decreasing gastrointestinal motility, and inhibition of gastric, pancreatic, and biliary secretions, resulting in reduced intestinal fat absorption and lymphatic flow within the thoracic duct<sup>[7]</sup>. The optimal dosing of octreotide is not known but reported doses ranges from continuous infusions to 50 to 200 micrograms every 8 hours for up to 14 days<sup>[6,7]</sup>. Success rates of octreotide as an adjunct to medical management range from 80-90%<sup>[6,7]</sup>. As noted above, high-output chylothorax may be more recalcitrant to medical measures, including octreotide. Predictors of failure include outputs of more than 1l/day or no reduction in output after 48 hours of commencement of octreotide<sup>[8]</sup>. Recently, the use of idodrine, an alpha-1 adrenergic agonist, has been proposed as a potential solution for the medical management of refractory chylothorax<sup>[8,9]</sup>. Midodrine stimulates the alpha-1 receptors in the lymphatics, resulting in constriction and decreased flow. Scarce numbers of case reports have demonstrated the successful management of refractory chylothorax, even post-surgical intervention, with results appearing within 24 hours of initiation and complete resolution occurring between 2 weeks to 1.5 years<sup>[8,9]</sup>. The oral formulation of midodrine makes it a convenient treatment option. The optimal dosage is not yet known; however, in the cited literature, doses of up to 10 mg to 20 mg four times a day have been used, leading to successful resolution. More invasive approaches are reserved for unsuccessful medical management after at least 2 weeks of therapy or high output chylothorax. Thoracic duct embolization was introduced 2 decades ago and has proven to be an effective modality of management with the benefits of avoiding the morbidity of surgery with clinical effective rates of more than 80-90% with complication rates of around 3% and usually minor<sup>[10]</sup>. Failure of these modalities would eventually require surgical intervention, which involves ligation of the thoracic duct, usually at the level of the diaphragm, either via an open approach or via thoracoscopic means.

**CONCLUSION**

The clinical success of midodrine use as a first-line medical treatment in our patients adds to the evidence in the literature supporting its use in the management of chylothorax before considering invasive procedures. Prospective studies are needed to assess the efficacy of the algorithm we have proposed.



---

## REFERENCES

1. Gilyard SN, Khaja MS, Goswami AK, Kokabi N, Saad WE, Majdalany BS. Traumatic Chylothorax: Approach and Outcomes. *Semin Intervent Radiol* 2020;**37**:263-268.
2. Bacon BT, Mashas W. Chylothorax caused by blunt trauma: Case review and management proposal. *Trauma Case Rep* 2020;**28**:100308.
3. de Villa AR, Obeidat O, Auyeung AB, Jaoude JA, Oyetoran A, Cannon K et al. Superior vena cava syndrome presenting as chylothorax. *Radiol Case Rep* 202;**18**:3824-3827.
4. Doerr CH, Miller DL, Ryu JH. Chylothorax. *Semin Respir Crit Care Med* 2001;**22**:617-626.
5. Seitelman E, Arellano JJ, Takabe K, Barrett L, Faust G, Angus LD. Chylothorax after blunt trauma. *J Thorac Dis* 2012;**4**:327-330.
6. Kalomenidis I. Octreotide and chylothorax. *Curr Opin Pulm Med* 2006;**12**:264-726.
7. ESME H. The use of octreotide in the treatment of chylothorax. *J Contemp Med December* 2019;**9**:432-435.
8. Sivakumar P, Ahmed L. Use of an Alpha-1 Adrenoreceptor Agonist in the Management of Recurrent Refractory Idiopathic Chylothorax. *Chest* 2018;**154**:e1-e4.
9. Liou DZ, Warren H, Maher DP, Soukiasian HJ, Melo N, Salim A, Ley EJ. *Chest* 2013;**144**:1055-1057.
10. Kim PH, Tsao J, Shin JH. Lymphatic Interventions for Chylothorax: A Systematic Review and Meta-Analysis. *J Vasc Interv Radiol* 2018;**29**:194-202.e4.