

Received: 2024.01.21

Accepted: 2024.04.29

Available online: 2024.06.02

Published: 2024.07.10

Fanconi Anemia in a 31-Year-Old Patient with Multiple Malignant Tumor Foci, Including Appendiceal Cancer, and Multiple Coexisting Pathologies

Authors' Contribution:

Study Design A

Data Collection B

Statistical Analysis C

Data Interpretation D

Manuscript Preparation E

Literature Search F

Funds Collection G

ABDEF 1 **Michał Dyaczyński**ABDEF 1 **Luiza Sannikova**AD 2 **Daniel Worek**

1 Department of General Surgery, The Silesian Hospital in Cieszyn, Cieszyn, Poland

2 Department of Surgery, Trinec Hospital, Trinec, Czech Republic

Corresponding Author:

Michał Dyaczyński, e-mail: michal.dyaczynski@gmail.com

Financial support:

Silesian Foundation for the Support and Development of Laparoscopic, Bariatric and Metabolic Surgery

Conflict of interest:

None declared

Patient: Male, 31-year-old
Final Diagnosis: Appendiceal cancer • mucinous type • grade G3
Symptoms: High levels of carcinoembryonic antigen (CEA)
Clinical Procedure: Laparoscopy • biopsy
Specialty: Oncology • Surgery

Objective: Rare disease



Background: Fanconi anemia (FA) is a genetic disorder that impairs the function of the bone marrow and predisposes individuals to aplastic anemia. The condition is caused by mutations in genes responsible for DNA repair. People with FA have an increased risk of developing tumors due to DNA damage. Flat-cell carcinomas of the head, neck, esophagus, and genital organs are often observed in individuals with FA.

Case Report: A 31-year-old man with Fanconi anemia and a history of bone marrow transplantation was admitted to the General Surgery Department due to elevated levels of the CEA marker. Before the transplantation, chromosomal anomalies, bone marrow hypoplasia, kidney agenesis, and bone defects were noted. After the transplantation, he developed a skin rash. He was also diagnosed with squamous cell carcinoma of the lip and chronic conditions, including cholestatic liver damage, hypertension, and hypothyroidism. During the diagnostic process, computed tomography showed signs of Barrett's esophagus, numerous polyps in the stomach and intestines, and a nodular formation measuring 4.5×5×5.5 cm in the right iliac region. Laparoscopy revealed a neoplasm of the appendix with numerous metastases on the inner abdominal wall and omentum. Histological analysis confirmed mucinous appendiceal cancer. The patient was discharged for palliative treatment at the Oncology Center with a final diagnosis of appendiceal cancer, mucinous type, grade G3. This case underscores the importance of early and comprehensive cancer screening in individuals with FA, particularly those with a history of bone marrow transplantation.

Conclusions: This clinical case underscores the critical importance of thorough and timely cancer diagnosis in individuals with this genetic pathology.

Keywords: Appendiceal Neoplasms • Rare Diseases • Genetics • Colorectal Surgery • Medical Oncology • Surgical Oncology

Full-text PDF: <https://www.amjcaserep.com/abstract/index/idArt/943880>

 1840 1 3 18

Publisher's note: All claims expressed in this article are solely those of the authors and do not necessarily represent those of their affiliated organizations, or those of the publisher, the editors and the reviewers. Any product that may be evaluated in this article, or claim that may be made by its manufacturer, is not guaranteed or endorsed by the publisher

Introduction

Fanconi anemia (FA) is a genetic disorder that leads to disruptions in bone marrow function and predisposes individuals to aplastic anemia. Fanconi anemia occurs in approximately 1 in 200 000 newborns worldwide [1]. In Europe, the disease is diagnosed in approximately 4-7 people per million live births [2].

FA is caused by mutations in genes responsible for DNA repair. Although FA itself is not a form of cancer, individuals with this condition have an increased risk of developing various neoplasms. DNA damage caused by genetic mutations makes normal cells more susceptible to tumorigenic transformation [3]. The most commonly observed cancers in FA patients are squamous cell carcinoma of the head and neck region or the upper part of the esophagus, as well as tumors in the genital organs and perineal tissues [4].

In the literature, cases of a rarer pathology have been previously described in patients with FA. These include Coats' disease reported in teenager with FA [5], a rare, Complex pathology of the wrist [6], medulloblastoma as the initial manifestation of FA [7], and FA with cataract [8]. Maxwell et al described a case of multiple malignant tumor foci without bone marrow failure [9].

Our literature review did not find any description of a case involving a patient with FA, malignant appendiceal tumor, and other concomitant pathologies. In general, primary appendiceal cancer is relatively rare and is often discovered incidentally during surgical removal of the appendix for acute appendicitis. The appendix can give rise to various subtypes of cancer, differing in both histology and biology. There is a classification that divides appendiceal cancer into 4 subgroups: neuroendocrine and mucinous tumors, adenocarcinoma, goblet cell carcinoid, and neuroendocrine neoplasia [10].

In the present article, we describe the case of a 31-year-old man with Fanconi anemia who underwent bone marrow transplantation at the age of 5 years and later underwent surgery for lower lip cancer. He was hospitalized due to elevated levels of the carcinoembryonic antigen (CEA). The case is notable for the atypical tumor localization and a series of other anomalies in the patient.

The case report may increase understanding of the variability in the manifestation of Fanconi syndrome and determining optimal diagnostic and treatment strategies in similar cases in the future.

Case Report

A 31-year-old man with previously confirmed Fanconi anemia was admitted to the General Surgery Department for diagnosis and treatment due to elevated levels of the CEA marker. At the age of 5 years, he underwent bone marrow transplantation as a treatment for Fanconi anemia. The blood type before transplantation was B Rh (+), CcDEe K(-). The donor for the transplant was the patient's younger brother. Testing of HLA I class phenotype and HLA II class genotype showed compatibility of both HLA haplotypes with the donor (allogeneic transplantation, HLA-matched family transplantation).

Before bone marrow transplantation, the patient exhibited the following abnormalities:

- Chromosomal abnormalities: Increased percentage of cells with chromosomal breaks and a significant increase in the number of chromosomal breaks per cell.
- Bone marrow: Bone marrow hypoplasia (requiring blood product transfusions every 4 weeks), with a total of 20 units of erythrocyte concentrate and 15 units of platelet concentrate transfused.
- Urinary system: Right kidney agenesis, duplication of the pelvicalyceal system in the left kidney.
- Skeletal system: Absence of the thumb (**Figure 1**) and first metacarpal bone in both hands, skeletal age delay.

In the post-transplantation period, the patient developed a skin rash typical of graft-versus-host disease (GVHD) (**Figure 2**), with diffuse erythematous micropapular lesions covering 80% of the skin, affecting the palms of the hands and soles of the feet, and pronounced facial erythema. No gastrointestinal tract abnormalities were observed.

The patient was an ethnic Pole, born from an uncomplicated first pregnancy. According to the patient's mother, there was no family history of cancer.

The patient had a healthy younger brother. The patient was under the guardianship of his parents, had no permanent employment, and struggled to answer questions without the assistance of his mother. The patient did not use nicotine or any psychoactive substances and did not suffer from alcoholism.

The patient was hospitalized due to high levels of carcinoembryonic antigen (40 ng/ml). Upon admission, he expressed no concerns about his well-being. No signs of intestinal obstruction or gastrointestinal bleeding were identified. There was no sudden weight loss or weight loss in general. He had normal appetite and regular bowel movements. Examination of the cardiovascular and respiratory systems revealed no abnormalities. Deep abdominal palpation also showed no significant deviations from the norm.

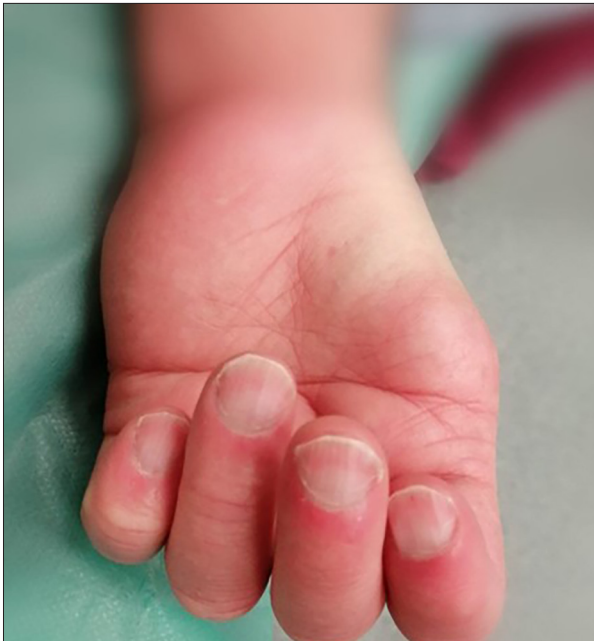

Figure 1. Absence of the thumb on the left hand.

In addition to the aforementioned changes in the musculoskeletal system (absence of the thumb and first metacarpal bone in both hands, skeletal age delay), manifestations of hypogonadism were observed, such as underdeveloped external genitalia, high-pitched voice, and chronic graft-versus-host disease affecting the skin and oral cavity, papular lesions on the face, and discoloration of the torso and limbs.

At the age of 30, the patient underwent surgery to remove a lip neoplasm. Histopathological examination revealed squamous cell carcinoma. A few days before hospitalization, a neoplasm on the right eyelid was also removed. In addition, he had been diagnosed with the following chronic conditions: cholestatic liver disease, hypertension, and hypothyroidism.

Upon hospitalization, basic laboratory and instrumental investigations were conducted to establish the diagnosis and initiate appropriate treatment. The complete blood count showed no significant deviations from the norm. The CEA level was 41.4 ng/ml. Gastroscopy, performed under general anesthesia, revealed signs of Barrett's esophagus (C2M5). Numerous sessile polyps resembling Elster's polyps were found in the cardia and body of the stomach. Tissue samples were taken from the esophageal polyps and the gastric fundus for histological evaluation. During colonoscopy, an opening of the appendix with reddened mucosa around its orifice was observed, so biopsy samples were taken and sent for histopathological examination. Additionally, a sessile polyp with a diameter of 6 mm was removed from the transverse colon by cold polypectomy. A computed tomography (CT) scan of the abdominal and pelvic organs revealed, among other things, a nodular formation



Figure 2. Manifestations of hypogonadism – underdeveloped external genitalia, as well as skin changes due to graft-versus-host disease (GVHD).

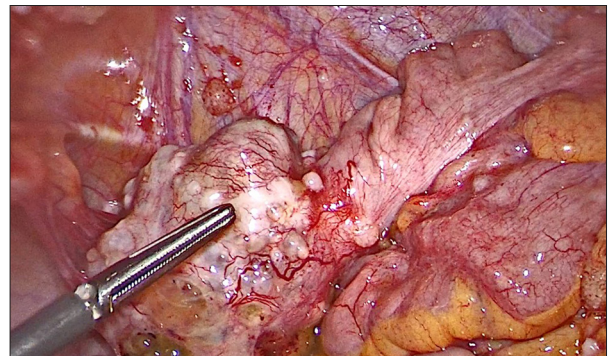


Figure 3. Tumor protruding from the appendix

measuring 4.5×5×5.5 cm in the right iliac region adjacent to the cecum, as well as right kidney agenesis. The left kidney was enlarged by 2-fold and had 2 ureters. A CT scan of the chest showed no significant pathological changes.

It was decided to perform laparoscopy. Trocars were placed in typical locations. Upon insertion of a camera, the abdominal cavity with metastases in the peritoneum and greater omentum was identified. A tumor measuring 5×6 cm protruding from the appendix was found (**Figure 3**). The base of the cecum with the tumor was resected using an endostapler. The tumor was placed in an endobag and removed from the abdominal cavity through an additional incision. Tissue samples for histopathological analysis were also taken from the greater omentum and peritoneum. No significant bleeding was observed during the intervention.

In the postoperative period, standard infusion therapy, pain management, and physiotherapy were employed. The histopathological examination yielded the following results:

Table 1. Summarized medical history of the patient.

Category	Information
Sex	Male
Age	31 years old
Height	1.5 meters
Family history	No family history
Bone marrow transplant	Yes
Blood group before transplant	B Rh (+), CcDEe K(-)
Chromosomal abnormalities	Increase in proportion of cells with chromosomal breaks, significant increase in breaks per cell
Bone marrow abnormalities	Bone marrow hypoplasia
Urinary system abnormalities	Right kidney agenesis, duplication of left kidney's renal pelvis and calyces
Bone system pathology	Absence of big toe and first metatarsal bone in both hands, skeletal age delay
Digestive system abnormalities	Barrett's esophagus, Elster's polyps, transverse colon polyp, cholestatic liver disease
Endocrine disorders	Hypothyroidism, hypogonadism
Neoplasms	Status post-radical surgery for lower lip cancer, tumor on skin of lower eyelid of left eye, Appendiceal carcinoma (Histological type: Mucinous, focal mucocellular malignancy, Grade G3)
Other	Arterial hypertension, skin rash typical of graft-versus-host disease (GVHD), diffuse erythematous micropapular lesions covering 80% of skin, affecting palms of hands, soles of feet, and pronounced facial erythema

- Fragments of peritoneal and omental tissue with several white formations up to 0.4 cm in diameter: mucinous carcinoma.
- Tissue specimen of the altered appendix: the tumor infiltrated the entire thickness of the appendix wall and extended into the subserosal tissue. The surface of the serosa of the appendix was uneven in some places, with areas of mucus containing cancer cells on the outer surface. Angioinvasion was present, but infiltration of nerve trunks was not detected. The tumor tissue was accompanied by sparse foci of lymphocytic inflammatory infiltrates.

Immunohistochemical testing of cancer cells showed: MSH-2 (+), MSH-6 (+), PMS-2 (+), MLH-1 (+).

Based on immunohistochemical findings, microsatellite instability was not detected. The final diagnosis was appendiceal carcinoma. The histological type was mucinous neoplasm, grade G3.

Additional diagnoses were Fanconi anemia status post-bone marrow transplantation in 1998, hypothyroidism, right kidney agenesis, Barrett's esophagus, Ester's polyps, transverse colon polyp, status post-radical surgery for lower lip cancer and tumor on the skin of the lower eyelid of the left eye, cholestatic

liver disease, hypertension, absence of the thumb and first metacarpal bone in both hands, and skeletal age delay. **Table 1** summarizes the medical history of the patient.

On the 14th day of hospitalization, the patient was discharged from the department with a referral for further palliative treatment at a specialized oncology center.

Discussion

In patients with FA, a correlation has been established between the expression levels of FA-associated genes (FANC genes) and the progression of colorectal cancer (CRC), as well as resistance to certain drugs. The FA pathway is considered a potential target for CRC treatment, and the characteristics of FANC genes may contribute to increased sensitivity of tumor cells to chemotherapy. FANC genes are also considered promising prognostic and predictive biomarkers for disease management and CRC treatment [11,12].

Earlier, an association was established between Fanconi anemia and a range of anomalies, including light-brown skin pigmentation, structural anomalies of the limbs such as absence

or deformities of fingers and bones, anomalies of the head and face, hypogonadism, and urinary system pathology. Overall, the presence of such disorders is explained by genetic defects in FA, affecting various aspects of embryonic development and organ function [13-15].

Petryk et al noted that 8 out of 10 patients with FA have endocrine disorders. Further investigation into this issue has allowed them to develop recommendations aimed at screening and treating hormonal disorders in patients with FA. For instance, these recommendations include annual thyroid function assessment for timely diagnosis of hypothyroidism [16]. A review by Dufour et al discussed key aspects of the contemporary management of patients with aplastic anemia, which can be categorized into several points:

- Long-term monitoring and early detection of cancer;
- Use of hematopoietic stem cell transplantation (HSCT) for bone marrow function restoration (considering the increased risk of malignant tumors);
- Gene therapy, which remains experimental but is already demonstrating effectiveness in the early stages of bone marrow involvement [17].

The Fanconi Anemia Research Fund (FARF) has compiled current knowledge on FA and published more detailed recommendations for managing patients with FA. Consequently, studies suggest regular screening for cancers of the digestive organs, skin, and oral cavity, endocrine pathology, and other anomalies mentioned in the present case report [18].

References:

1. Díaz de Heredia C, Bierings M, Dalle JH, et al. Fanconi's anemia and other hereditary bone marrow failure syndromes. In: Carreras E, Dufour C, Mohty M, Kröger N, eds. *The EBMT Handbook: Hematopoietic stem cell transplantation and cellular therapies*. 7th ed. Cham (CH): Springer; 2019;587-93
2. Gulbis B, Eleftheriou A, Angastiniotis M, et al. Epidemiology of rare anaemias in Europe. *Adv Exp Med Biol*. 2010;686:375-96
3. Che R, Zhang J, Nepal M, et al. Multifaceted fanconi anemia signaling. *Trends Genet*. 2018;34(3):171-83
4. Reina-Castillón J, Pujol R, López-Sánchez M, et al. Detectable clonal mosaicism in blood as a biomarker of cancer risk in Fanconi anemia [published correction appears in *Blood Adv*. 2017;1(18):1368]. *Blood Adv*. 2017;1(5):319-29
5. Martín-Sanz R, Peña D, López-Miguel A, et al. Coats disease in a patient with Fanconi anemia: A case report. *Eur J Ophthalmol*. 2015;25(2):182-83
6. Al-Qattan MM. Fanconi anemia with concurrent thumb polydactyly and dorsal dimelia: A case report with discussion of embryology. *Ann Plast Surg*. 2013;70(1):116-18
7. Tischkowitz MD, Chisholm J, Gaze M, et al. Medulloblastoma as a first presentation of fanconi anemia. *J Pediatr Hematol Oncol*. 2004;26(1):52-55
8. Merriman M, Mora J, McGaughan J. Fanconi anemia and primary cataracts: First case. *Ophthalmic Genet*. 2002;23(4):253-55
9. Maxwell KN, Patel V, Nead KT, et al. Fanconi anemia caused by biallelic inactivation of BRCA2 can present with an atypical cancer phenotype in adulthood. *Clin Genet*. 2023;103(1):119-24
10. Van de Moortele M, De Hertogh G, Sagaert X, Van Cutsem E. Appendiceal cancer: A review of the literature. *Acta Gastroenterol Belg*. 2020;83(3):441-48
11. Liu W, Palovcak A, Li F, et al. Fanconi anemia pathway as a prospective target for cancer intervention. *Cell Biosci*. 2020;10:39
12. Parsa FG, Nobili S, Karimpour M, et al. Fanconi anemia pathway in colorectal cancer: A novel opportunity for diagnosis, prognosis and therapy. *J Pers Med*. 2022;12(3):396
13. Moreno OM, Paredes AC, Suarez-Obando F, Rojas A. An update on Fanconi anemia: Clinical, cytogenetic and molecular approaches (review). *Biomed Rep*. 2021;15(3):74.
14. Bhandari J, Thada PK, Puckett Y. Fanconi anemia. In: *StatPearls*. Treasure Island (FL): StatPearls Publishing; August 10, 2022
15. Fiesco-Roa MO, Giri N, McReynolds LJ, et al. Genotype-phenotype associations in Fanconi anemia: A literature review. *Blood Rev*. 2019;37:100589
16. Petryk A, Kanakatti Shankar R, Giri N, et al. Endocrine disorders in Fanconi anemia: Recommendations for screening and treatment. *J Clin Endocrinol Metab*. 2015;100(3):803-11
17. Dufour C, Pierri F. Modern management of Fanconi anemia. *Hematology Am Soc Hematol Educ Program*. 2022;2022(1):649-57
18. Fanconi Anemia Research Fund. *Fanconi anemia clinical care guidelines*. 5th ed. Fanconi Anemia Research Fund; 2020; Eugene, OR

The prognosis for Fanconi anemia can vary significantly depending on various factors, including the severity of the disease, the presence of associated complications, the patient's age, and the availability of effective treatment. Aplastic anemia is a primary cause of death in children, while older patients are at risk of developing malignancies [14].

Conclusions

Our case represents the picture of a paraneoplastic process in a patient with FA, where radical removal of the tumor was not possible, emphasizing the importance of thorough and timely diagnosis of malignant neoplasms in FA patients. Effective case management requires a multidisciplinary approach involving oncologists, geneticists, and specialists from other medical fields.

Department and Institution in Which the Work Was Done

Department of General Surgery, The Silesian Hospital in Cieszyn, Cieszyn, Poland.

Declaration of Figures' Authenticity

All figures submitted have been created by the authors who confirm that the images are original with no duplication and have not been previously published in whole or in part.