



# Sternal fixation and autologous bone grafting for post sternotomy non-union: a case series

Hiral Jhala<sup>1^</sup>, Patricia McFarlane<sup>2</sup>, Sanjeet Singh Avtaar Singh<sup>3</sup>, Kamal Deep<sup>4</sup>, Zahid Mahmood<sup>5</sup>, Harikrishna Doshi<sup>5</sup>, Nawwar Al-Attar<sup>5</sup>

<sup>1</sup>Department of Cardiothoracic Surgery, Aberdeen Royal Infirmary, Aberdeen, UK; <sup>2</sup>University of Glasgow School of Medicine, Glasgow, UK; <sup>3</sup>Department of Cardiothoracic Surgery, Royal Infirmary of Edinburgh, Edinburgh, UK; <sup>4</sup>Department of Orthopaedic Surgery, Golden Jubilee National Hospital, Glasgow, UK; <sup>5</sup>Department of Cardiothoracic Surgery, Golden Jubilee National Hospital, Glasgow, UK

*Contributions:* (I) Conception and design: H Jhala, K Deep, N Al-Attar; (II) Administrative support: H Jhala, P McFarlane, SS Avtaar Singh, Z Mahmood, H Doshi; (III) Provision of study materials of patients: Z Mahmood, H Doshi, N Al-Attar; (IV) Collection and assembly of data: H Jhala, P McFarlane, SS Avtaar Singh; (V) Data analysis and interpretation: H Jhala, SS Avtaar Singh, K Deep, N Al-Attar; (VI) Manuscript writing: All authors; (VII) Final approval of manuscript: All authors.

*Correspondence to:* Hiral Jhala, MRCS, MBBS, BSc (Hons). Department of Cardiothoracic Surgery, Aberdeen Royal Infirmary, Foresterhill Road, Aberdeen AB25 2ZN, UK. Email: hiraljhala.hj@gmail.com.

**Background:** Sternal non-union is a rare but serious complication post cardiac surgery. It is defined as sternal pain with clicking, instability or both, lasting for more than 6 months in the absence of infection. It usually presents in an outpatient setting and is confirmed on computed tomography (CT) scanning. Despite many corrective methods described in the literature, there is a lack of consensus amongst cardiac surgeons as to the ideal surgical management of sternal non-union post cardiac surgery. We describe our experience of sternal plating combined with autologous iliac crest bone grafting (AICBG) for sternal fixation and explore its safety and feasibility in patients with non-union post cardiac surgery.

**Case Description:** Patients who underwent sternal non-union surgery between 2015 and 2020 were included. Their primary cardiac surgical interventions occurred between 2011–2018. Demographic, clinical and outcome data obtained from a local database was analyzed retrospectively. Surgical procedure: sternal edge debridement, plate fixation with screws, filling with AICBG. Due to variable pathoanatomy of non-union, residual wires and multiple fragments of poor bone quality were cut and the sternal halves were stabilised by titanium plates and screws. These were reinforced with AICBG applied in the residual sternal gap created after debridement. Seven patients were included in the study. Median age was 65 years (54–75 years). Four patients (57.1%) were male. Demographic risk factors for sternal non-union prior to their initial cardiac surgery included diabetes (N=6), smoking history (N=3), and a median body mass index (BMI) of 31.2 kg/m<sup>2</sup>. The median interval between primary surgery and sternal fixation was 2.2 years. There were no perioperative deaths. Complications post sternal plating such as iliac crest pain (n=3) and acute tubular necrosis (n=1) were managed conservatively with long-term resolution. None of the patients required further intervention post sternal fixation after a mean follow-up of 18.0 months.

**Conclusions:** The use of AICBG in addition to sternal plating is a viable and innovative method of treating sternal non-union post-cardiac surgery with lasting effects and without any serious long-term complications. However, further larger studies are required to validate our results.

**Keywords:** Sternal non-union; sternal fixation; autologous iliac crest bone grafting (AICBG); case series

Submitted Jan 23, 2024. Accepted for publication Apr 12, 2024. Published online Jul 26, 2024.

doi: 10.21037/jtd-24-126

View this article at: <https://dx.doi.org/10.21037/jtd-24-126>

<sup>^</sup> ORCID: 0000-0002-1267-5254.

## Introduction

### Background

Sternal wound complications occur in between 0.5–6% of cardiac surgical cases performed through a median sternotomy approach (1-3). If left undetected, sternal wound complications can lead to sternal instability, wire breakage or cutting through of wires through weak points in the sternum resulting in separation of the bone, and subsequent non-union. Sternal non-union is defined as sternal pain with clicking, instability or both, lasting for more than 6 months, in the absence of infection. It usually presents in the outpatient setting and is confirmed on computed tomography (CT) scanning. Sternal non-union can be transverse, following a fracture or longitudinal, most commonly following median sternotomy. One dangerous consequence of uncorrected sternal non-union is mediastinitis which can confer up to a 47% mortality rate if it ensues (4,5). Certain comorbidities such as obesity with a body mass index (BMI) >30 kg/m<sup>2</sup> (6), smoking (7), diabetes (7) and chronic obstructive pulmonary disease (COPD) (8), amongst others can predispose patients to sternal wound dehiscence, mediastinitis and non-union (9,10). Operative factors such as bilateral mammary arteries

harvesting have also been described as risk factors for suboptimal sternal wound healing (11,12). Post-operative factors including prolonged intensive therapy unit (ITU) stay, chest infection and re-intervention also increase the risk of sternal wound complications (13). In order to prevent such complications in particularly fragile sternums primary sternal closure methods other than the standard “figure of 8” horizontal stainless-steel wires, such as the modified Robiscek technique have been advocated to reinforce closure and prevent dehiscence or longitudinal non-union (14,15). However, reinforced closure with Robiscek wires or interlocking wires often poses risks of haemorrhage from injury to the residual internal mammary artery, or a compromised blood supply, and foreign body reactions to wires (16,17). Hence, stabilization techniques such as sternal plating with titanium or cannulated screws (18) have grown in popularity. Recently, techniques incorporating autologous iliac bone as flaps or cancellous application into sternal plate fixation have been described with good outcomes in large sternal defects (19,20).

### Rationale and knowledge gap

Despite many corrective methods described in the literature, there is a lack of consensus amongst cardiac surgeons as to the ideal surgical management of sternal non-union post cardiac surgery. Whereas plating alone fixes the sternal edges, the added use of autologous iliac crest bone grafting (AICBG) has the potential for osteogenic healing whilst conferring histocompatibility (21). This is particularly useful in fragile sternums with poor bone quality that cannot withstand the tensile forces of extensive synthetic materials. We describe the added value of AICBG to sternal plating for sternal fixation in patients with non-union.

### Objective

We describe our experience of sternal plating combined with AICBG for sternal fixation and explore its safety and feasibility in cardiac surgical patients with non-union post-sternotomy. We present this article in accordance with the AME Case Series reporting checklist (available at <https://jtd.amegroups.com/article/view/10.21037/jtd-24-126/rc>).

## Case presentation

### Patient recruitment

Patients who underwent sternal non-union surgery between

### Highlight box

#### Key findings

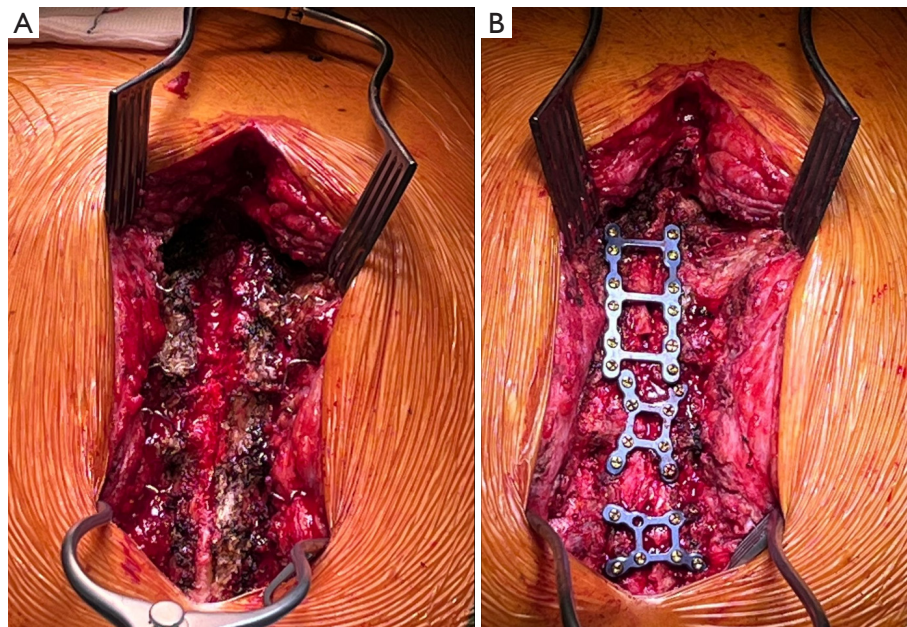
- Seven patients over 7 years successfully underwent sternal plating fixation with autologous iliac crest bone grafting (AICBG) for post sternotomy non-union.
- No perioperative deaths.
- Four patients had complications (iliac crest pain, and renal injury) which were successfully managed conservatively.
- None of the patients required further intervention post sternal fixation with AICBG.

#### What is known and what is new?

- Sternal non-union, which is a rare but serious complications post-cardiac surgery, can be treated with sternal plating.
- There is paucity of data regarding ideal surgical management of such patients to promote osteogenic healing after plate fixation. Our study demonstrates the safety and feasibility of using AICBG in addition to sternal plating.

#### What is the implication, and what should change now?

- Use of AICBG in addition to sternal plating is a viable and innovative method of treating sternal non-union successfully with lasting effects and without any serious long-term complications.
- AICBG can be used to achieve optimal outcomes in patients with non-union post sternotomy.



**Figure 1** Intraoperative photography of the procedure. (A) Before plating. Exposure sternum prior to fixation showing central gap of sternal non-union with irregular edges of sternal halves. (B) After plating. No gap between sternal halves with plates and screws.

2015–2020 following cardiac surgery at a single-centre were included. Demographic, surgical and outcome data were obtained from a local database and analysed retrospectively. All patients were followed up until December 2020. Clinical data are expressed as appropriate as counts and percentages or medians and ranges.

### *Criteria for sternal fixation surgery*

Sternal fixation surgery was offered to patients who experienced severe sternal pain or persistent instability and radiological evidence of sternal non-union on CT imaging.

### *Operative technique for sternal fixation*

Each procedure was performed as a joint-case by a consultant cardiac surgeon (N.A.A.) and consultant orthopaedic surgeon (K.D.). An anterior midline approach was used through the initial midline sternotomy scar and two superficial tissue flaps were made over the sternum on either side of the midline (*Figure 1A*). The two edges of the non-union of the sternum were freshened and the space cleared of fibrous tissue. The edges were then refreshed to the bleeding surface and washed out with aqueous solution. This debridement and washout of the non-union

area created a gap between the two sternal halves which was to be filled with autologous bone graft. This gap was reduced with tension on sternal wires (if present), manual compression and held by reduction forceps. The sternum was fixed, but not fully approximated, with locking plates (Depuy Synthes®, Massachusetts, USA) and screws with lengths varying from 12–14 mm (*Figure 1B*), depending on measurements taken from the patients' pre-operative CT scan. All previous wires were removed prior to plating to prevent reaction with the titanium plates. The residual gap in the midline of the fixed sternum created a bone bed to allow placement of AICBG. Cortical and cancellous bone was harvested from the iliac crest. The cortical bone was cut into small pieces and inserted in the residual gap between the sternal edges, underneath the blades of the sternal plates. The cancellous bone was then applied over the pieces of cortical bone in the residual sternal bone bed.

All procedures performed in this study were in accordance with the ethical standards of the institutional and/or national research committee(s) and with the Declaration of Helsinki (as revised in 2013). All authors have made the best efforts to gain written informed consent from the patients and to contact their relatives for the publication of this case series and accompanying images, but to no avail. Verbal consent for photography and publication

**Table 1** Demographic, clinical and operative data

Variables	Values
<b>Demographics</b>	
Age (years)	65 [54–75]
Male	4 (57.1)
<b>Smoking status</b>	
Current smoker	1 (14.3)
Ex-smoker	2 (28.6)
Never smoker	4 (57.1)
<b>Risk</b>	
EuroSCORE (%)	3.99 [0.88–8.55]
Charlson Comorbidity Index (%)	7 [4.5–9]
<b>CCS angina scale</b>	
1	1 (14.3)
2	2 (28.6)
3	2 (28.6)
4	2 (28.6)
<b>NYHA class</b>	
1	–
2	3 (42.9)
3	2 (28.6)
4	2 (28.6)
<b>Pre-operative comorbidities</b>	
BMI (kg/m <sup>2</sup> )	31.2 [29.1–31.5]
LVEF (%)	47 [39–57]
Pre-operative creatinine (µmol/L)	77 [69–110.5]
HbA1c (mmol/mol)	65.5 [53.8–79.5]
Diabetes mellitus	6 (85.7)
Liver disease	1 (14.3)
Congestive heart failure	1 (14.3)
Myocardial infarction	5 (71.4)
Cerebrovascular accident	3 (42.9)
Intra-aortic balloon pump	1 (14.3)
Inotropic support	1 (14.3)
<b>Primary surgical intervention</b>	
Isolated total arterial CABG	5 (71.4)
CABG (1 arterial, 2 vein grafts)	1 (14.3)
Bioprosthetic aortic valve replacement	1 (14.3)
<b>Primary sternal closure</b>	
Modified Robiscek technique	5 (71.4)
Figure of 8 closure	2 (28.6)

Data are expressed as median [range] or n (%). CCS, Canadian Cardiovascular Society; NYHA, New York Heart Association; BMI, body mass index; LVEF, left ventricular ejection fraction; HbA1c, glycosylated haemoglobin; CABG, coronary artery bypass grafts.

of intraoperative images was obtained for each patient prior to their operation. The authors have ensured the article has been sufficiently anonymized to cause no harm to the patients or their families.

### *Patient follow-up*

All patients were followed up in the outpatient clinic for symptoms, clinical examination of the wound and sternal stability and imaging assessment with chest X-rays (CXR). CT scan was not performed routinely unless clinically indicated.

### *Demographic data*

Out of a total of 1,836 patients under a single surgeon (N.A.A.) undergoing sternotomy for cardiac surgery over a 7-year period, five patients (0.3%) required sternal plating. In addition, two other patients under different surgeons (Z.M. and H.D.) also underwent sternal plating by the same surgeon (N.A.A.), hence a total of seven patients were included in this study. Four (57.1%) patients were male. The median age was 65 years (range, 54–75 years). Demographic, clinical and operative data prior to their initial cardiac surgical intervention can be shown in *Table 1*. Three patients had a smoking history. The median BMI was 31.2 kg/m<sup>2</sup> (range, 29.1–31.5 kg/m<sup>2</sup>). Six (85.7%) patients were diabetic, with a median pre-operative glycosylated haemoglobin (HbA1c) of 65.5 mmol/mol (range, 53.8–79.5 mmol/mol). The median left ventricular ejection fraction (LVEF) was 47%. The median pre-operative creatinine level was 77 µmol/L (range, 69–110.5 µmol/L). The median logistic EuroSCORE for all seven patients was 3.99% (range, 0.88–8.55%). The median Charlson Comorbidity Index was 7% (4.5–9%). Five patients had a history of previous myocardial infarction, one patient had previous liver disease, one patient had congestive heart failure, three patients had a previous cerebrovascular accident or transient ischaemic attack, one patient required an intra-aortic balloon pump (IABP) pre-operatively and one patient was on pre-operative inotropic support.

### *Operative data for the primary operation*

The primary cardiac surgical intervention for all patients occurred between 2011–2018. Five patients (71.4%) underwent isolated total arterial coronary artery bypass grafts (CABG) using bilateral internal mammary arteries (BIMA)

**Table 2** Post-operative and follow-up data

Patient, age (years)/sex	Time after index surgery (days)	Fixation procedure	Complications	Follow-up time after sternal fixation (months)	Symptoms	Non-union features on chest radiograph at follow-up
66/F	821	4 sternal plates, left iliac crest bone graft	Donor site pain	9.6	Mild pain, stable sternum, no wound infection	No
60/M	712	Sternal plates and screws, right iliac crest bone graft	Donor site pain	35.6	Minimal pain, stable sternum, wound healed	No
70/M	410	Sternal plates and screws, left iliac crest bone graft	None	7.8	No pain, stable sternum, wound healed	No
75/F	2,476	Sternal plates and screws, left iliac crest bone graft	None	7.3	Sternal brace for comfort, stable sternum, no wound infection	No
65/M	1,409	Sternal plates and screws, left iliac crest bone graft	Acute tubular necrosis—conservative management	15.5	No pain, stable sternum, wound healed	No
62/F	14	Sternal plates and screws, left iliac crest bone graft	None	48.3	Mild pain, stable sternum, wound healed	No
54/M	936	3 sternal plates and screws, right iliac crest bone graft	Donor site pain	3.5	Improved mobility, no pain, stable sternum, wound healed	No

F, female; M, male.

as their primary surgical intervention, one patient underwent a standard CABG procedure with left internal mammary artery (LIMA) and saphenous vein grafts (SVG). One patient underwent an isolated bioprosthetic aortic valve replacement. Five patients (71.4%) underwent a modified Robicsek technique of sternal closure whereas two patients had a standard “Figure-of-8” closure. There were no perioperative deaths in the study population. Four patients (57.1%) had post-operative complications: chest infection (n=2), acute kidney injury (n=1) and arrhythmias (n=1).

### Operative data for sternal stabilization

Sternal non-union presented in different ways as predominantly sternal pain (n=5), perceived wound infection due to discharge (n=2) and sternal click (n=5). One patient had undergone sternal wire removal after their primary operation. The overall median interval between primary surgical intervention and the sternal fixation was 2.2 years (range, 14 days–6.8 years). After a mean follow-up time of 18.0 months, none of the seven patients required further intervention after sternal fixation.

All seven patients underwent sternal plating using metal

plates and AICBG (left n=5, right n=2). Four patients (57.1%) had post-operative complications which included iliac crest pain (n=3) and acute tubular necrosis (n=1), all of which resolved with conservative management (*Table 2*).

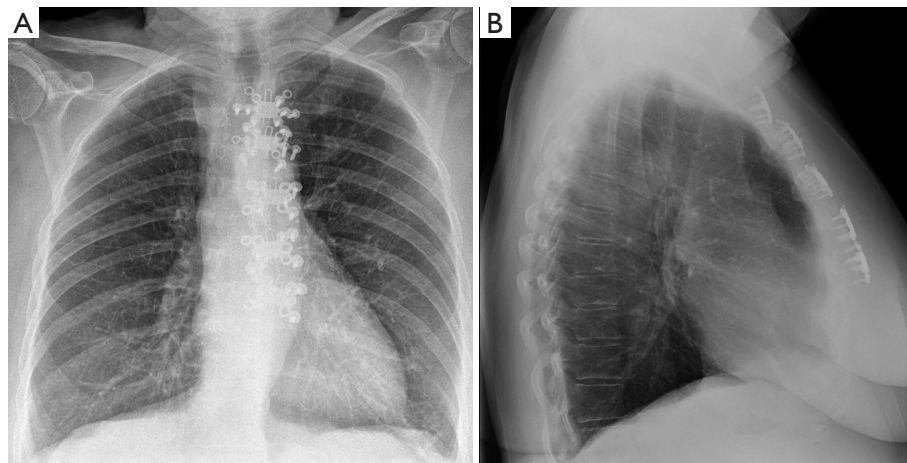
### Patient follow-up data

Details of follow-up is shown in *Table 2*. At 6 months post-sternal fixation, six patients reported no breathlessness, no sternal pain and no sternal clicking or instability. The remaining patient continued to use a sternal brace through choice due to difficulty with pain management. The mean resolution time was 6 months (1–18 months). At 18 months following fixation, all seven patients were asymptomatic, with stable sternums and had been discharged from surgical follow-up. CXRs of all patients revealed no evidence of residual sternal non-union (*Figure 2*). None of the patients required further CT scanning for follow-up.

## Discussion

### Surgical technique

Sternal plating with titanium has been described to treat



**Figure 2** Chest radiography in antero-posterior (A) and lateral (B) views post sternal non-union surgery demonstrating the end result of sternal fixation. The screw heads and titanium plates can be seen either side of the sternum.

post sternotomy non-union (22,23) and post trauma (24) with excellent results. In recent years, novel techniques such as sternal mesh repairs (25) and implanting cryopreserved cadaveric sternal allografts (26), have shown excellent results in major sternal defects. In our patients, none of the defects were large enough to warrant such techniques, once the sternal edges were debrided and the residual gap reduced. In the face of poor sternal bone quality, such as that encountered in our case series, the application of autologous cortical and cancellous bone grafts from the iliac crest, can provide extra osteogenic healing for optimum elasticity and tensile strength (27). Most of our patients were smokers, diabetic and obese, two of whom had BIMAs at their primary operation, which are all risk factors for poor wound healing and are more likely to have poor bone quality. A recent case report demonstrated symptomatic and functional benefit from using AICBG in addition to sternal and costal fixation techniques (28). They reported resolution of symptoms and no evidence of residual non-union after 3 months follow-up, which we replicated on average at 6 months follow-up, although the shortest resolution time was 1 month in one patient. The longest time a patient took for complete resolution was 18 months, with application of a sternal brace. Our median interval between procedures was 27.4 months, which was comparable to that of Gooseman *et al.* (28).

### ***Benefits and risks of AICBG***

A recent case series of seven patients described the

use of AICBG with sternal plating but in the context of post-traumatic sternal non-union (29). Our time to resolution (longest 18.0 months) was comparable to theirs (14.3 months), and like our patients, none of their patients had long-term serious complications or required further intervention (29). Whilst this study demonstrates successful treatment of transverse sternal non-union following fractures, a case series by Bardos *et al.* (30) shows applicability of AICBG in longitudinal fractures, with no long-term complications, and symptomatic and radiographic resolution of non-union. We believe this demonstrates the versatility and applicability of AICBG in promoting osteogenic healing in a range of anatomical variations of sternal non-union.

The iliac crest is recognised as the most common harvesting site for autologous bone grafting, owing to its ability for osteosynthesis (31).

However, iliac crest bone harvesting is not without risks, most commonly: infection, haematoma formation, fracture, chronic donor site pain, and local neuropathy (31). These complications have the potential to limit day-to-day functionality, however we saw that those of our patients who experienced donor site pain, recovered with conservative management, with no serious long-term consequences. None of our patients experienced neuropathy, haematoma formation or localised fractures. We believe that despite the potential chronicity of such complications, the benefits of using AICBG in sternal non-union outweigh the risks, due to the higher risk and adverse outcomes of needing a re-intervention if sternal fixation is inadequate. Adequate

sternal fixation can lead to an impaired cough effort, running the risk of a chest infection, which in the context of cardiac surgery, confers a higher mortality due to impaired chest ventilation mechanics.

### *Limitations and future directions*

The literature surrounding sternal non-union surgery post sternotomy is largely limited to case reports and series, due to its rarity post cardiac surgery. Our study has a small number of patients, in whom the analysis was performed retrospectively. However, our study is a preliminary study to demonstrate the safety and feasibility of AICBG with sternal plating to facilitate further larger studies which could validate our results in future. We endeavour, that future studies will include a control group for direct comparison of sternal fixation with and without AICBG, conducted in a prospective manner to allow for more rigorous analysis of our hypothesis.

### **Conclusions**

The use of AICBG in addition to sternal plating is a viable and innovative method of treating sternal non-union post cardiac surgery with lasting effects and without any serious long-term complications. However, further larger studies are required to validate our results.

### **Acknowledgments**

*Funding:* None.

### **Footnote**

*Reporting Checklist:* The authors have completed the AME Case Series reporting checklist. Available at <https://jtd.amegroups.com/article/view/10.21037/jtd-24-126/rc>

*Peer Review File:* Available at <https://jtd.amegroups.com/article/view/10.21037/jtd-24-126/prf>

*Conflicts of Interest:* All authors have completed the ICMJE uniform disclosure form (available at <https://jtd.amegroups.com/article/view/10.21037/jtd-24-126/coif>). The authors have no conflicts of interest to declare.

*Ethical Statement:* The authors are accountable for all aspects of the work in ensuring that questions related

to the accuracy or integrity of any part of the work are appropriately investigated and resolved. All procedures performed in this study were in accordance with the ethical standards of the institutional and/or national research committee(s) and with the Declaration of Helsinki (as revised in 2013). All authors have made the best efforts to gain written informed consent from the patients and to contact their relatives for the publication of this case series and accompanying images, but to no avail. Verbal consent for photography and publication of intraoperative images was obtained for each patient prior to their operation. The authors have ensured the article has been sufficiently anonymized to cause no harm to the patients or their families.

*Open Access Statement:* This is an Open Access article distributed in accordance with the Creative Commons Attribution-NonCommercial-NoDerivs 4.0 International License (CC BY-NC-ND 4.0), which permits the non-commercial replication and distribution of the article with the strict proviso that no changes or edits are made and the original work is properly cited (including links to both the formal publication through the relevant DOI and the license). See: <https://creativecommons.org/licenses/by-nc-nd/4.0/>.

### **References**

1. Salehi Omran A, Karimi A, Ahmadi SH, et al. Superficial and deep sternal wound infection after more than 9000 coronary artery bypass graft (CABG): incidence, risk factors and mortality. *BMC Infect Dis* 2007;7:112.
2. Eklund AM, Lyytikäinen O, Klemets P, et al. Mediastinitis after more than 10,000 cardiac surgical procedures. *Ann Thorac Surg* 2006;82:1784-9.
3. Kubota H, Miyata H, Motomura N, et al. Deep sternal wound infection after cardiac surgery. *J Cardiothorac Surg* 2013;8:132.
4. Satta J, Lahtinen J, Räisänen L, et al. Options for the management of poststernotomy mediastinitis. *Scand Cardiovasc J* 1998;32:29-32.
5. El Oakley RM, Wright JE. Postoperative mediastinitis: classification and management. *Ann Thorac Surg* 1996;61:1030-6.
6. Molina JE, Lew RS, Hyland KJ. Postoperative sternal dehiscence in obese patients: incidence and prevention. *Ann Thorac Surg* 2004;78:912-7; discussion 912-7.
7. Tang GH, Maganti M, Weisel RD, et al. Prevention and management of deep sternal wound infection. *Semin*

- Thorac Cardiovasc Surg 2004;16:62-9.
8. Hosseinrezaei H, Rafiei H, Amiri M. Incidence and risk factors of sternal wound infection at site of incision after open-heart surgery. *J Wound Care* 2012;21:408-11.
  9. Ariyaratnam P, Bland M, Loubani M. Risk factors and mortality associated with deep sternal wound infections following coronary bypass surgery with or without concomitant procedures in a UK population: a basis for a new risk model? *Interact Cardiovasc Thorac Surg* 2010;11:543-6.
  10. Sá MPBO, Ferraz PE, Soares AF, et al. Development and Validation of a Stratification Tool for Predicting Risk of Deep Sternal Wound Infection after Coronary Artery Bypass Grafting at a Brazilian Hospital. *Braz J Cardiovasc Surg* 2017;32:1-7.
  11. Taggart DP, Altman DG, Gray AM, et al. Randomized trial to compare bilateral vs. single internal mammary coronary artery bypass grafting: 1-year results of the Arterial Revascularisation Trial (ART). *Eur Heart J* 2010;31:2470-81.
  12. Crabtree TD, Codd JE, Fraser VJ, et al. Multivariate analysis of risk factors for deep and superficial sternal infection after coronary artery bypass grafting at a tertiary care medical center. *Semin Thorac Cardiovasc Surg* 2004;16:53-61.
  13. Centofanti P, Savia F, La Torre M, et al. A prospective study of prevalence of 60-days postoperative wound infections after cardiac surgery. An updated risk factor analysis. *J Cardiovasc Surg (Torino)* 2007;48:641-6.
  14. Tavilla G, van Son JA, Verhagen AF, et al. Modified Robicsek technique for complicated sternal closure. *Ann Thorac Surg* 1991;52:1179-80.
  15. Ata EC, Beyaz MO. Sternum Dehiscence: A Preventable Complication of Median Sternotomy. *Heart Surg Forum* 2020;23:E599-605.
  16. Konstantinov IE, Saxena P. Sternal stabilization by interlocking wires: an alternative simple technique for high-risk patients. *J Card Surg* 2009;24:510-1.
  17. Schimmer C, Reents W, Berneder S, et al. Prevention of sternal dehiscence and infection in high-risk patients: a prospective randomized multicenter trial. *Ann Thorac Surg* 2008;86:1897-904.
  18. De Cicco G, Tosi D, Crisci R, et al. Use of new cannulated screws for primary sternal closure in high risk patients for sternal dehiscence. *J Thorac Dis* 2019;11:4538-43.
  19. Xu S, Dou Y, Zhao G, et al. Autologous ilium graft combination with Y-shaped titanium plate fixation for chest wall reconstruction after resection of primary sternal tumors—a clinical study from three institutions. *Transl Cancer Res* 2020;9:930-6.
  20. Drinnon KD, Sherali S, Cox CT, et al. Sternal Tumor Resection and Reconstruction Using Iliac Crest Autograft. *Plast Reconstr Surg Glob Open* 2020;8:e3002.
  21. Khan SN, Cammisa FP Jr, Sandhu HS, et al. The biology of bone grafting. *J Am Acad Orthop Surg* 2005;13:77-86.
  22. Hendrickson SC, Koger KE, Morea CJ, et al. Sternal plating for the treatment of sternal nonunion. *Ann Thorac Surg* 1996;62:512-8.
  23. Malovrh T, Stupnik T, Podobnik B, et al. Postoperative transverse sternal nonunion with a chest wall defect managed by a tibial locking plate and a Gore-Tex dual mesh membrane: a case report. *J Cardiothorac Surg* 2021;16:345.
  24. Bertin KC, Rice RS, Doty DB, et al. Repair of transverse sternal nonunions using metal plates and autogenous bone graft. *Ann Thorac Surg* 2002;73:1661-2.
  25. Dell'Amore A, Campisi A, Giunta D, et al. Surgical options to treat massive sternal defect after failed Robicsek procedure. *J Thorac Dis* 2018;10: E410-5.
  26. Ciarrocchi AP, Dell'Amore A, Campisi A, et al. Long-Term Metabolic Assessment of Cryopreserved Sternal Allograft: A Case Series. *Ann Thorac Surg* 2021;111:1059-63.
  27. Elliott DS, Newman KJ, Forward DP, et al. A unified theory of bone healing and nonunion: BHN theory. *Bone Joint J* 2016;98-B:884-91.
  28. Gooseman MR, Cooper GJ, Edwards JG. Elastic-Stable Chest Repair: Costal Plate Fixation for Sternotomy Nonunion. *Ann Thorac Surg* 2018;105:e175-6.
  29. LaRoque MC, Brahme IS, Cole PA. Surgical management of traumatic sternal body nonunions: Technical tricks and clinical experience. *J Trauma Acute Care Surg* 2023;95:861-7.
  30. Bardos A, Sabhrawal S, Tytherleigh-Strong G. Management of Vertical Sternal Fracture Nonunion in Elite-Level Athletes. *Orthop J Sports Med* 2021;9:23259671211010804.
  31. Dimitriou R, Mataliotakis GI, Angoules AG, et al. Complications following autologous bone graft harvesting from the iliac crest and using the RIA: a systematic review. *Injury* 2011;42 Suppl 2:S3-15.

**Cite this article as:** Jhala H, McFarlane P, Avtaar Singh SS, Deep K, Mahmood Z, Doshi H, Al-Attar N. Sternal fixation and autologous bone grafting for post sternotomy non-union: a case series. *J Thorac Dis* 2024;16(7):4685-4692. doi: 10.21037/jtd-24-126