

CASE REPORT

Open Access



Prenatal diagnosis of recurrent Kagami–Ogata syndrome inherited from a mother affected by Temple syndrome: a case report and literature review

Xueting Yang^{1†}, Mengmeng Li^{1†}, Qingwei Qi¹, Xiya Zhou¹, Na Hao¹, Yan Lü^{1*} and Yulin Jiang^{1*}

Abstract

Background Kagami–Ogata syndrome (KOS) and Temple syndrome (TS) are two imprinting disorders characterized by the absence or reduced expression of maternal or paternal genes in the chromosome 14q32 region, respectively. We present a rare prenatally diagnosed case of recurrent KOS inherited from a mother affected by TS.

Case presentation The woman's two affected pregnancies exhibited recurrent manifestations of prenatal overgrowth, polyhydramnios, and omphalocele, as well as a small bell-shaped thorax with coat-hanger ribs postnatally. Prenatal genetic testing using a single-nucleotide polymorphism array detected a 268.2-kb deletion in the chromosome 14q32 imprinted region inherited from the mother, leading to the diagnosis of KOS. Additionally, the woman carried a de novo deletion in the paternal chromosome 14q32 imprinted region and presented with short stature and small hands and feet, indicating a diagnosis of TS.

Conclusions Given the rarity of KOS as an imprinting disorder, accurate prenatal diagnosis of this rare imprinting disorder depends on two factors: (1) increasing clinician recognition of the clinical phenotype and related genetic mechanism, and (2) emphasizing the importance of imprinted regions in the CMA workflow for laboratory analysis.

Keywords Prenatal diagnosis, Kagami–Ogata syndrome, Imprinting disorder, Single-nucleotide polymorphism array

Background

Genomic imprinting is an epigenetic mechanism in which the expression pattern of a parental allele influences phenotypic expression [1]. Imprinted genes are

generally found in clusters and are regulated by imprinting control regions (ICRs), which exhibit parent-specific DNA methylation during germline development. Gamete-specific DNA methylation at ICRs can be retained despite extensive postfertilization epigenetic reprogramming [2, 3].

Kagami–Ogata syndrome (KOS, OMIM #608149) and Temple syndrome (TS, OMIM #616222) are rare imprinting disorders caused by genetic or epigenetic alterations of an imprinted gene cluster in the chromosome 14q32 region. This locus encompasses paternally expressed protein-coding genes (*DLK1*, *RTL1* and *DIO3*), maternally expressed long noncoding RNAs (*MEG3/GTL2*, *RTL1as* and *MEG8*) and short noncoding RNAs. The absence or

[†]Xueting Yang and Mengmeng Li contributed equally to this work.

*Correspondence:

Yan Lü

lyan@pumch.cn

Yulin Jiang

yulinj@gmail.com

¹ Department of Obstetrics and Gynecology, National Clinical Research Center for Obstetric & Gynecologic Diseases, Peking Union Medical College Hospital, Chinese Academy of Medical Science & Peking Union Medical College, Beijing, China



reduced expression of maternal or paternal genes results in KOS or TS, respectively [4–6].

More than 60% of KOS cases are caused by paternal uniparental disomy 14, approximately 25% are caused by microdeletions, and nearly 10% are caused by epimutations of the chromosome 14q32 imprinted region [7]. The major clinical features of KOS include polyhydramnios, omphalocele, placentomegaly and macrosomia during the prenatal period [4]. KOS, which has a mortality rate of approximately 30%, is also characterized by a small bell-shaped thorax, coat-hanger ribs and a narrow chest wall postnatally, leading to significant respiratory distress upon delivery [8–10]. Therefore, prenatal diagnosis is crucial not only for prenatal counseling but also for the management of KOS newborns. However, prenatal identification of KOS is challenging, possibly due to insufficient recognition of this rare disease and its associated imprinted regions.

Here, we present a prenatally diagnosed case of recurrent KOS caused by a deletion in the chromosome 14q32 imprinted region inherited from a mother who was affected by TS. We provide a review of previous cases involving maternal allele deletions associated

with KOS, with the objective of improving awareness of rare imprinted disorders within the realm of prenatal diagnosis.

Case presentation

We present the case of a healthy 33-year-old pregnant woman, gravida 3, para 0. She had an ectopic pregnancy, and her second pregnancy ended in stillbirth at 27 weeks gestation, with fetal omphalocele and polyhydramnios indicated by prenatal ultrasound. The miscarried tissues obtained during the second pregnancy were analyzed by single-nucleotide polymorphism (SNP) array (Affymetrix GeneChip 3000Dx, 25 kb 25 marker loss & 25 kb 25 marker gain), and no abnormalities were found. In the third pregnancy, prenatal ultrasound at 23⁺⁵ weeks of gestation revealed polyhydramnios and clenched hands with overlapping fingers. Additionally, head circumference (226 mm, 92nd percentile for gestational age according to reference data of the Asian population provided by the National Institute of Child Health and Development), abdominal circumference (232.1 mm, 100th percentile for gestational age) and weight (820 g, 99th percentile for gestational age) were above the normal range for a fetus at

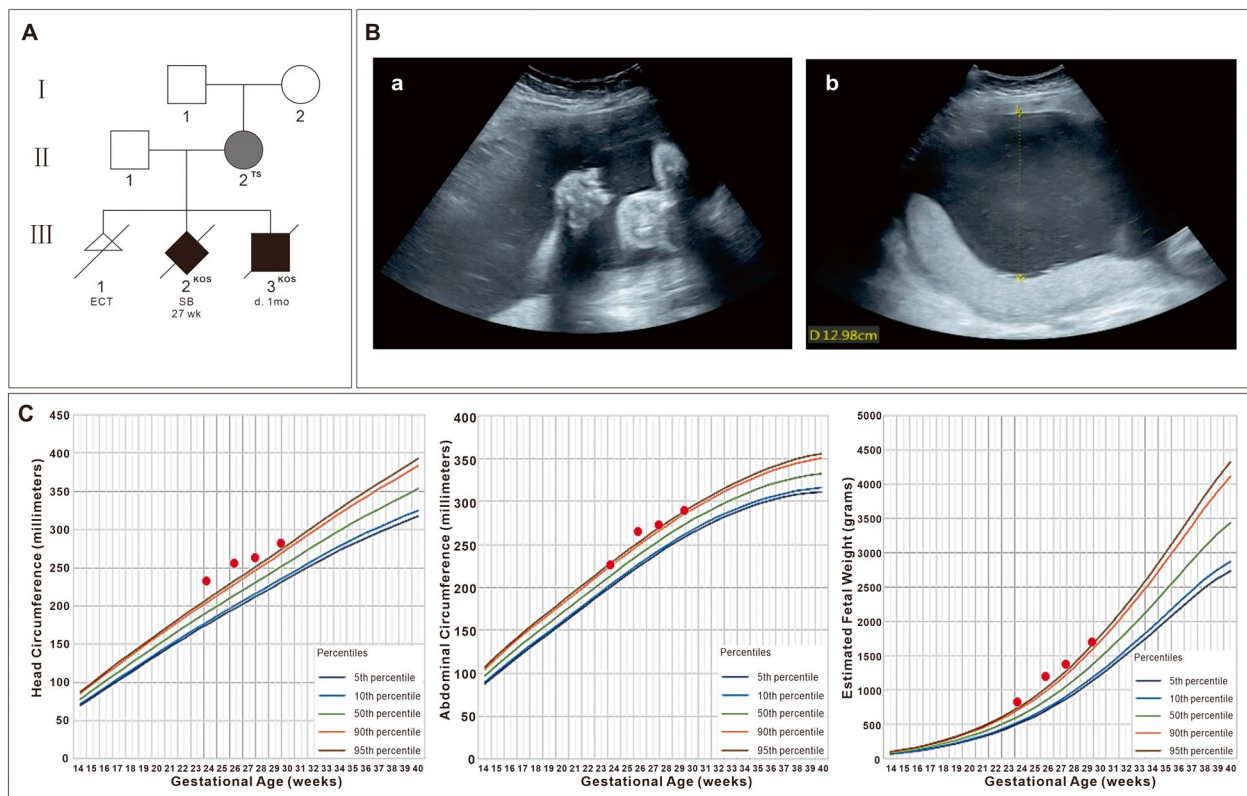


Fig. 1 Pedigree of the family and abnormalities of the fetus detected by prenatal ultrasound. **A** Pedigree of the family: members affected by KOS are colored in black and the member affected by TS is colored in dark gray. ECT, ectopic pregnancy; SB, still birth. **B** Ultrasound image showing clenched hands with overlapping fingers and polyhydramnios with a deepest vertical pocket of 12.98 cm. **C** Fetal growth trajectories of head circumference, abdominal circumference and estimated fetal weight, NICHD Fetal Growth Studies—Singletons

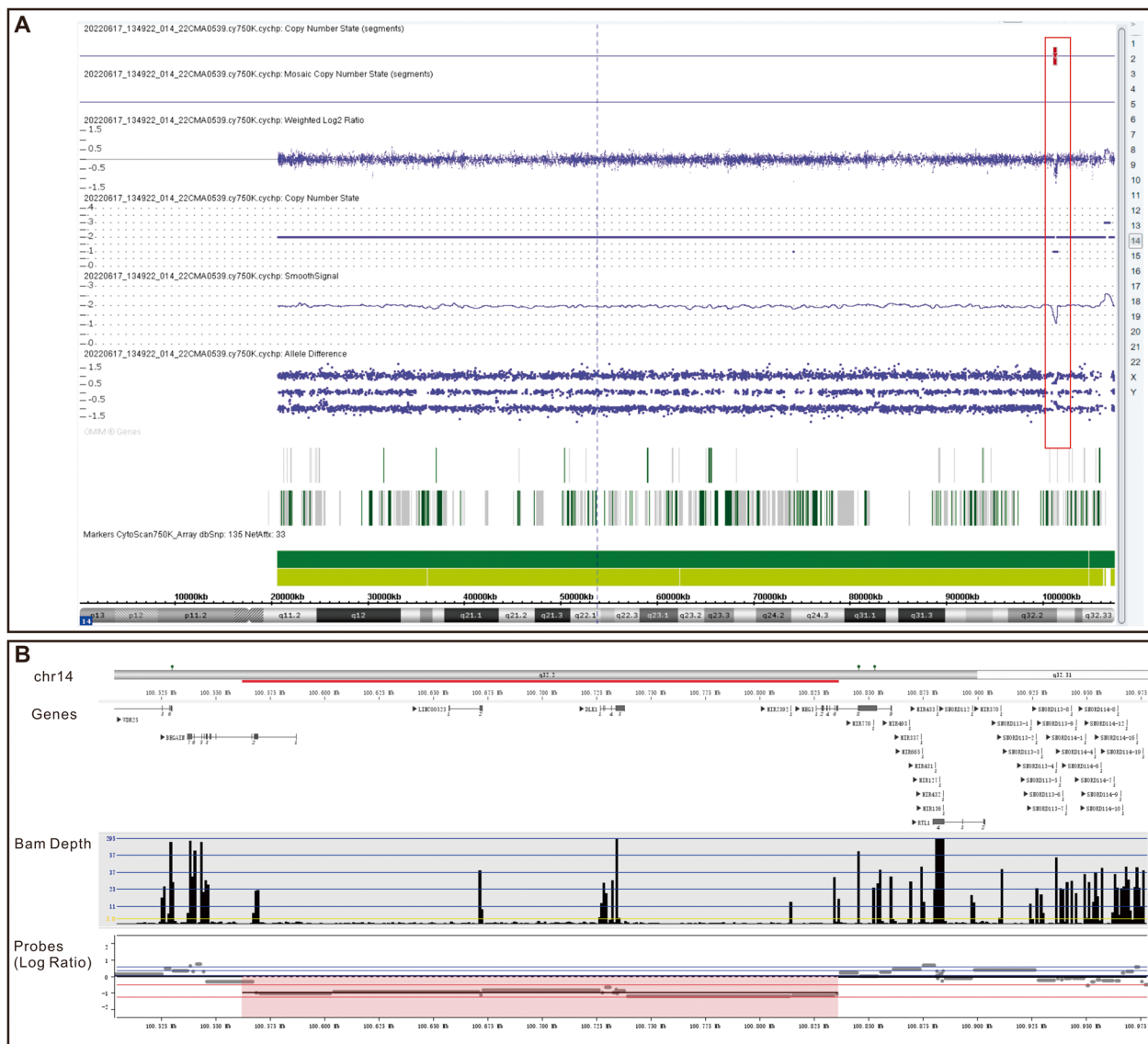


Fig. 2 SNP array and WES results for the fetus. **A** A deletion of 268.2 kb at 14q32.2 was detected by SNP array (highlighted in the red frame). **B** A deletion including *DLK1*, exons 1–7 of *MEG3*, IG-DMR and *MEG3*-DMR was detected by WES (highlighted in a red shadow)

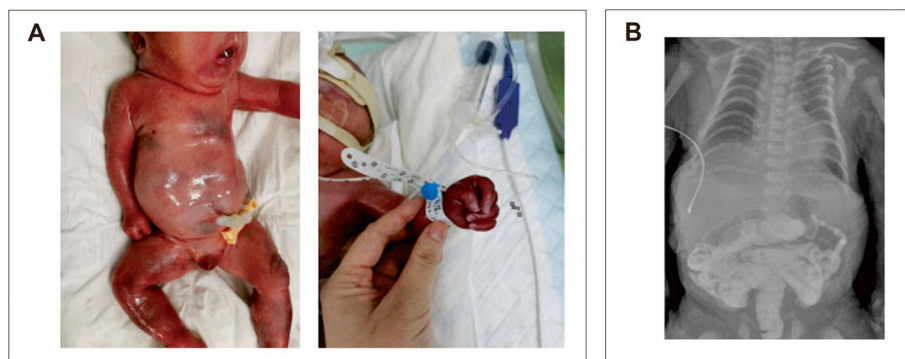


Fig. 3 Postnatal features of the neonate. **A** Thin and soft abdominal wall, clenched hands, full cheeks, tented upper lip and micrognathia. **B** Chest X-ray image showing a typical bell-shaped thorax with coat-hanger ribs

Table 1 Kagami–Ogata syndrome cases with maternal allele deletions on chromosome 14q32

Reference (year)	Patient (n)	Sex (M:F)	Inheritance mode	Sizes of deletion	Affected ICRs of maternal origin		Prenatal features				Postnatal features							
					IG-DMR	MEG3-DMR	Polyhydramnios	Omphalocele	Placentomegaly	Preterm labor	Respiratory distress	Feeding difficulties	Developmental delay	Hypotonia	Depressed nasal bridge	Prominent philtrum	Short webbed neck	Small bell-shaped thorax with coat-hanger ribs
Kagami et al. [16] (2008)	2	1:1	Inherited	108.8 kb	Deleted	Deleted	+	-	-	+	NA	+	+	+	NA	+	+	+
	1	0:1	NA	474.6 kb	Deleted	Deleted	+	-	-	+	NA	+	+	+	NA	+	+	+
	1	1:0	NA	6.5 Mb	Deleted	Deleted	+	-	-	+	NA	+	+	+	NA	+	+	+
Kagami et al. [5] (2010)	1	0:1	Inherited	411.4 kb	Deleted	Deleted	+	-	-	+	NA	+	+	+	NA	+	+	+
	1	0:1	Inherited	8.6 kb	Deleted	No deletion	+	+	+	+	+	+	+	+	+	+	+	+
Classen et al. [22] (2013)	1	0:1	NA	4.3 kb	No deletion	Deleted	+	+	+	+	+	+	+	NA	+	-	+	+
	1	1:0	de novo	1.143 Mb	Deleted	Deleted	NA	NA	NA	-	+	+	+	+	NA	NA	NA	+
Beygo et al. [23] (2015)	1	1:0	de novo	165 kb	No deletion	Deleted	+	NA	-	+	+	+	+	+	NA	NA	NA	+
	2	2:0	Inherited	5.8 kb	No deletion	Deleted	+	NA	NA	+	+	+	+	NA	+	+	+	+
Rosenthal et al. [17] (2015)	1	0:1	Inherited	122 kb	No deletion	No deletion	+	-	-	+	NA	NA	NA	NA	NA	NA	NA	+
	1	0:1	Inherited	154 kb	No deletion	No deletion	+	-	-	+	NA	NA	NA	NA	NA	NA	NA	+
Consello et al. [24] (2015)	1	0:1	de novo	160 kb	No deletion	No deletion	+	-	-	+	+	+	+	NA	+	+	+	+
	2	1:1	Inherited	65.9 kb	No deletion	No deletion	+	+/NA (1:1)	-	+	±(1:1)	±(1:1)	-	+	NA	NA	NA	+
Van Der Werf et al. [25] (2016)	2	2:0	Inherited	130 kb	Deleted	Deleted	+	-	-	+	±(1:1)	±(1:1)	+	NA	NA	NA	NA	+
	2	1:1	Inherited	1.2 Mb	Deleted	Deleted	+	-	-	+	+	+	+	NA	+	+	+	+
Jung et al. [14] (2018)	1	0:1	Inherited	133 kb	No deletion	Deleted	+	-	-	-	+	+	+	+	NA	NA	NA	+

Table 1 (continued)

Reference (year)	Patient (n)	Sex (M/F)	Inheritance mode	Sizes of deletion	Affected ICRs of maternal origin		Prenatal features			Postnatal features									
					IG-DMR	MEG3-DMR	Polyhydramnios	Omphalocele	Placentomegaly	Preterm labor	Respiratory distress	Feeding difficulties	Developmental delay	Hypotonia	Depressed nasal bridge	Prominent philtrum	Short webbed neck	Small bell-shaped thorax with coat-hanger ribs	
Huang et al. [9] (2019)	1	1:0	de novo	NA	NA	NA	+	+	NA	+	+	+	+	+	+	+	+	+	+
Altmann et al. [26] (2020)	1	0:1	NA	336 kb	Deleted	Deleted	+	+	NA	+	+	-	+	+	+	+	+	+	+
Sabria-Back et al. [19] (2022)	1	NA	Inherited	108 kb	Deleted	Deleted	+	+	NA	+	+	NA	NA	NA	+	+	+	+	+
Hu et al. [15] (2022)	1	NA	Inherited	732.3 kb	Deleted	Deleted	+	NA	NA	NA	NA	NA	NA	NA	NA	NA	NA	NA	NA
Sirera et al. [27] (2023)	1	0:1	Inherited	117 kb	No deletion	No deletion	+	NA	-	-	-	+	+	NA	-	-	-	-	+
Kilich et al. [21] (2024)	1	0:1	de novo	203 bp	No deletion	Partially deleted	+	-	NA	+	+	+	+	+	+	+	+	+	+
This case	2	2:0	Inherited	2682 kb	Deleted	Deleted	+	+	-	+	+	+	+	NA	+	+	+	+	+

M Male, F Female, NA not available

the corresponding gestational week [11]. The ultrasound abnormalities of the fetus are presented in Fig. 1. Given the woman's multiple fetal ultrasound abnormalities, gestational age, and adverse pregnancy history, amniocentesis was performed at 27 weeks after the she was provided informed consent. Standard chromosome analyses, SNP array (Affymetrix GeneChip 3000Dx, 25 kb 25 marker loss and 25 kb 25 marker gain) analysis and trio whole exome sequencing (WES) were carried out.

Neither aneuploidy nor structural rearrangements of the chromosomes were detected by karyotype analysis. Both SNP array and trio WES revealed a maternal allele deletion of 268.2 kb in the chromosome 14q32 imprinted region, as illustrated in Fig. 2. In light of the abnormalities detected by ultrasound and the results of the genetic tests, KOS was diagnosed prenatally. The diagnosis prompted a review of the SNP array analysis of the previously affected pregnancy, and the same deletion was detected.

The woman experienced preterm labor at 30 weeks of gestation and delivered a male fetus weighing 2045 g (99th percentile for gestational age) with a head circumference of 30 cm (97th percentile for gestational age), a length of 40 cm (62nd percentile for gestational age), a placental volume of 18 cm × 14 cm × 3 cm and a weight of 500 g [12]. The fetus had facial dysmorphism (small dysplastic ears, small palpebral fissures, full cheeks, tented upper lip, depressed nasal bridge and micrognathia), short neck, thin and slack abdominal wall with abdominal distension, and clenched fist. Chest X-ray revealed a small bell-shaped thorax with distinctive coat-hanger ribs, which are representative features of KOS, as illustrated in Fig. 3 [4]. In addition to feeding difficulties, infections and calcium deficiency, the most prominent symptom of the newborn was respiratory deficiency. The newborn continued to depend on high-frequency oscillatory ventilation with high-quality respiratory support even at one month of age.

Further clinical evaluations of the mother revealed features of a short stature with a height of 158 cm and small hands and feet. Genetic analysis indicated that the woman carried a de novo deletion in the paternal chromosome 14q32 imprinted region, leading to the diagnosis of TS [13].

Discussion

Herein, we described a case with a prenatal diagnosis of recurrent KOS caused by a 268.2-kb deletion in the chromosome 14q32 imprinted region inherited from the mother who was affected by TS due to a de novo deletion in the paternal chromosome.

Among the three differentially methylated regions (DMRs) in the chromosome 14q32 imprinted region, IG-DMR and MEG3-DMR are hypomethylated, and

MEG8-DMR is regulated to be methylated in the maternal chromosome, resulting in the maternal expression of *MEG3*, *RTL1as* and *MEG8*. In contrast, the paternal IG-DMR and the MEG3-DMR are methylated, and the MEG8-DMR is demethylated, regulating the paternal expression of *DLK1* and *RTL1* [4–6]. In our case, the woman carried a de novo deletion in the paternal chromosome. The deleted locus contained *DLK1*, exons 1–7 of *MEG3*, IG-DMR and MEG3-DMR. The absence of paternally expressed genes results in TS [4, 13]. When transmitted to the fetus, this deletion was of maternal origin and therefore caused KOS [14]. Preimplantation or prenatal genetic diagnosis was recommended for the next pregnancy due to a recurrence risk of 50%.

KOS is characterized by serial prenatal overgrowth of the fetus and placenta and a narrow chest in the infant. On the other hand, TS is characterized by pre- and postnatal growth restriction, as well as other features, including small hands and feet, short stature, hypotonia, early onset of puberty, and mild dysmorphism of the face. In our case, the recurrent manifestations of two affected pregnancies were consistent with the clinical phenotypes of KOS. The woman had TS features of short stature and small hands and feet. The clinical–genetic diagnoses of TS in the woman and KOS in her offsprings were confirmed by molecular cytogenetics and imprinting mechanisms.

We reviewed 27 previous cases of KOS caused by maternal allele deletions of varying sizes in the literature, as shown in Table 1. Among these cases, there was only one prenatal diagnosis [14], while in most postnatal cases, the diagnosis was performed during infancy and early childhood (20/27 cases). Prenatally, the majority of cases had polyhydramnios (25/27 cases), while omphalocele and placentomegaly were reported in 6 and 5 cases, respectively. Three infants died due to respiratory infection or intracranial hemorrhage [5, 16, 17]. Notably, chromosomal microarray analysis (CMA), including array comparative genomic hybridization (aCGH) and SNP array techniques, detected 18 cases, three of which were attributed to deletions inherited from the mother affected by TS [15, 18, 19]. Furthermore, next-generation sequencing methods such as whole genome sequence (WGS) and copy number variant sequencing (CNV-seq) have also been employed for diagnosing KOS [20, 21].

SNP array-based CMA is routinely utilized as a first-line test in the prenatal diagnosis of fetuses with ultrasound abnormalities [20, 28–30]. However, in the application of SNP arrays to detect KOS caused by maternal allele deletions, two important points should be noted. First, copy number variations (CNVs) below the resolution could not be detected. The smallest deletion associated with KOS was only 203 bp, which was far below the detection threshold of the SNP array. However, this deletion was

detected by WGS [21]. Second, SNP array analysis workflow primarily focuses on CNVs that contain genes causing human diseases, particularly those dosage-sensitive genes within the OMIM morbid map. In contrast, CNVs that lack OMIM-morbid genes and dosage-sensitive genes may be underestimated. In our case, despite the presence of an imprinting region in the 14q32 deletion CNV, it does not include any OMIM-morbid genes or dosage-sensitive genes. Therefore, the CNV was missed during the CMA-SNP analysis in the second pregnancy. During the analysis in the third pregnancy, recurrent phenotypes prompted a thorough investigation into the imprinting region, subsequently leading to the detection of the CNV.

Currently, some regions associated with imprinting disorders, such as 15q11.2q13 (related to Prader–Willi syndrome and Angelman syndrome), have received ample attention in CMA analysis [31, 32]. However, regions associated with much rarer imprinting disorders, such as KOS, with an estimated incidence of less than 1 in 1 million [33], tend to be underestimated in CMA analysis.

Conclusions

The absence or reduced expression of maternal genes in the 14q32 imprinted region is associated with KOS. Accurate prenatal diagnosis of this rare imprinting disorder depends on two factors: (1) increasing clinician recognition of the clinical phenotype and related genetic mechanism, and (2) emphasizing the importance of imprinted regions in the CMA workflow for laboratory analysts.

Abbreviations

aCGH	Array comparative genomic hybridization
CMA	Chromosomal microarray analysis
CNV	Copy number variation
DMR	Differentially methylated region
ICR	Imprinting control region
KOS	Kagami–Ogata syndrome
OMIM	Online Mendelian Inheritance in Man
SNP	Single-nucleotide polymorphism
TS	Temple syndrome
WES	Whole exome sequencing
WGS	Whole genome sequence

Acknowledgements

The authors thank AJE (<http://www.aje.cn/>) for the English language review.

Authors' contributions

XTY: analysis and interpretation, data collection, manuscript writing, editing and revision. MML: analysis and interpretation, genetic testing, editing and revision. QWQ: editing and revision. XYZ: editing and revision. NH: editing and revision. YL: study conception and design, analysis and interpretation, data collection, manuscript writing, editing and revision. YLJ: study conception and revision. All authors have read and approved the manuscript.

Funding

This study was supported by the National Key Research and Development Program of China (2022YFC2703302) and the CAMS Innovation Fund for Medical Sciences (CIFMS-2022-I2M-C&T-B-008).

Availability of data and materials

The datasets used and/or analyzed during the current study are available from the corresponding author upon reasonable request.

Data availability

No datasets were generated or analysed during the current study.

Declarations

Ethics approval and consent to participate

The study was approved by the ethics review committee of Peking Union Medical College Hospital (I-23PJ733).

Consent for publication

Written informed consent for publication was obtained from the participants.

Competing interests

The authors declare no competing interests.

Received: 2 March 2024 Accepted: 7 August 2024

Published online: 29 August 2024

References

- Tucci V, Isles AR, Kelsey G, Ferguson-Smith AC. Genomic imprinting and physiological processes in mammals. *Cell*. 2019;176:952–65.
- Takahashi N, Gray D, Strogantsev R, Noon A, Delahaye C, Skarnes WC, et al. ZFP57 and the targeted maintenance of postfertilization genomic imprints. *Cold Spring Harb Symp Quant Biol*. 2015;80:177–87.
- Takahashi N, Coluccio A, Thorball CW, Planet E, Shi H, Offner S, et al. ZNF445 is a primary regulator of genomic imprinting. *Genes Dev*. 2019;33:49–54.
- Prasasya R, Grotheer KV, Siracusa LD, Bartolomei MS. Temple syndrome and Kagami-Ogata syndrome: clinical presentations, genotypes, models and mechanisms. *Hum Mol Genet*. 2020;29:R107–16.
- Kagami M, O'Sullivan MJ, Green AJ, Watabe Y, Arisaka O, Masawa N, et al. The IG-DMR and the MEG3-DMR at human chromosome 14q32.2: Hierarchical interaction and distinct functional properties as imprinting control centers. *PLoS Genet*. 2010;6:e1000992.
- Beygo J, Mertel C, Kaya S, Gillissen-Kaesbach G, Eggermann T, Horsthemke B, et al. The origin of imprinting defects in temple syndrome and comparison with other imprinting disorders. *Epigenetics*. 2018;13:822–8.
- Li F, Liu S, Jia B, Wu R, Chang Q. Prenatal diagnosis of a mosaic paternal uniparental disomy for chromosome 14: a case report of Kagami-Ogata syndrome. *Front Pediatr*. 2021;9:691761.
- Ogata T, Kagami M. Kagami-Ogata syndrome: a clinically recognizable upd(14)pat and related disorder affecting the chromosome 14q32.2 imprinted region. *J Hum Genet*. 2016;61:87–94.
- Huang H, Mikami Y, Shigematsu K, Uemura N, Shinsaka M, Iwatani A, et al. Kagami-Ogata syndrome in a fetus presenting with polyhydramnios, malformations, and preterm delivery: a case report. *J Med Case Rep*. 2019;13:340.
- Wang X, Pang H, Shah BA, Gu H, Zhang L, Wang H. A male case of Kagami-Ogata syndrome caused by paternal uniparental disomy 14 as a result of a robertsonian translocation. *Front Pediatr*. 2020;8:88.
- Louis GMB, Grewal J, Albert PS, Sciscione A, Wing DA, Grobman WA, et al. Racial/ethnic standards for fetal growth: the NICHD fetal growth studies. *Am J Obstet Gynecol*. 2015;213(449):e1–41.
- Fenton TR, Kim JH. A systematic review and meta-analysis to revise the Fenton growth chart for preterm infants. *BMC Pediatr*. 2013;13:59.
- Gillissen-Kaesbach G, Albrecht B, Eggermann T, Elbracht M, Mitter D, Morlot S, et al. Molecular and clinical studies in 8 patients with temple syndrome. *Clin Genet*. 2018;93:1179–88.
- Jung HS, Vallee SE, Dinulos MB, Tsongalis GJ, Lefferts JA. Maternally inherited 133kb deletion of 14q32 causing Kagami-Ogata syndrome. *J Hum Genet*. 2018;63:1231–9.
- Hu J, Zhang Y, Yang Y, Wang L, Sun Y, Dong M. Case report: Prenatal diagnosis of Kagami-Ogata syndrome in a Chinese family. *Front Genet*. 2022;13:959666.

16. Kagami M, Sekita Y, Nishimura G, Irie M, Kato F, Okada M, et al. Deletions and epimutations affecting the human 14q32.2 imprinted region in individuals with paternal and maternal upd(14)-like phenotypes. *Nat Genet.* 2008;40:237–42.
17. Rosenfeld JA, Fox JE, Descartes M, Brewer F, Stroud T, Gorski JL, et al. Clinical features associated with copy number variations of the 14q32 imprinted gene cluster. *Am J Med Genet A.* 2015;167a:345–53.
18. Luk HM. Familial Kagami-Ogata syndrome in Chinese. *Clin Dysmorphol.* 2017;26:124–7.
19. Sabria-Back J, Monteagudo-Sánchez A, Sánchez-Delgado M, Ferguson-Smith AC, Gómez O, Cartada AP, et al. Preimplantation genetic testing for a chr14q32 microdeletion in a family with Kagami-Ogata syndrome and temple syndrome. *J Med Genet.* 2022;59:253–61.
20. Huang R, Yang X, Zhou H, Fu F, Cheng K, Wang Y, et al. Prenatal diagnosis of talipes equinovarus by ultrasound and chromosomal microarray analysis: a Chinese single-center retrospective study. *Genes (Basel).* 2022;13:1573.
21. Kilich G, Hassey K, Behrens EM, Falk M, Vanderver A, Rader DJ, et al. Kagami Ogata syndrome: a small deletion refines critical region for imprinting. *NPJ Genom Med.* 2024;9:5.
22. Classen CF, Rieher V, Landwehr C, Kosfeld A, Heilmann S, Scholz C, et al. Dissecting the genotype in syndromic intellectual disability using whole exome sequencing in addition to genome-wide copy number analysis. *Hum Genet.* 2013;132:825–41.
23. Beygo J, Elbracht M, De Groot K, Begemann M, Kanber D, Platzer K, et al. Novel deletions affecting the MEG3-DMR provide further evidence for a hierarchical regulation of imprinting in 14q32. *Eur J Hum Genet.* 2015;23:180–8.
24. Corsello G, Salzano E, Vecchio D, Antona V, Grasso M, Malacarne M, et al. Paternal uniparental disomy chromosome 14-like syndrome due a maternal de novo 160 kb deletion at the 14q32.2 region not encompassing the IG- and the MEG3-DMRs: patient report and genotype-phenotype correlation. *Am J Med Genet A.* 2015;167a:3130–8.
25. Van Der Werf IM, Buiting K, Czeschik C, Reyniers E, Vandeweyer G, Vanhaesebrouck P, et al. Novel microdeletions on chromosome 14q32.2 suggest a potential role for non-coding RNAs in Kagami-Ogata syndrome. *Eur J Hum Genet.* 2016;24:1724–9.
26. Altmann J, Horn D, Korinth D, Eggermann T, Henrich W, Verlohren S. Kagami-Ogata syndrome: an important differential diagnosis to Beckwith-Wiedemann syndrome. *J Clin Ultrasound.* 2020;48:240–3.
27. Sirera PS, García-Payá E, García JO, Rodríguez RJ, Romero SDH. Maternally inherited deletion encompassing the RTL1as and MEG8 genes of the human 14q32 imprinted region in a patient with a mild Kagami-Ogata syndrome phenotype. *Am J Med Genet A.* 2023;191:2225–31.
28. Huang R, Zhou H, Fu F, Li R, Lei T, Li Y, et al. Prenatal diagnosis of Williams-Beuren syndrome by ultrasound and chromosomal microarray analysis. *Mol Cytogenet.* 2022;15:27.
29. Hu T, Zhang Z, Wang J, Li Q, Zhu H, Lai Y, et al. Prenatal diagnosis of chromosomal aberrations by chromosomal microarray analysis in fetuses with ultrasound anomalies in the urinary system. *Prenat Diagn.* 2019;39:1096–106.
30. Srebniak MI, Boter M, Oudesluijs GO, Cohen-Overbeek T, Govaerts LC, Diderich KE, et al. Genomic SNP array as a gold standard for prenatal diagnosis of foetal ultrasound abnormalities. *Mol Cytogenet.* 2012;5:14.
31. Liu S, Zhang K, Song F, Yang Y, Lv Y, Gao M, et al. Uniparental disomy of chromosome 15 in two cases by chromosome microarray: a lesson worth thinking. *Cytogenet Genome Res.* 2017;152:1–8.
32. Huang W, Li S, Luo H, Wen X, Lin C, Chen S, et al. Application of various genetic techniques for the diagnosis of Prader-Willi syndrome. *Zhonghua Yi Xue Yi Chuan Xue Za Zhi.* 2020;37:875–8.
33. Sakaria RP, Mostafavi R, Miller S, Ward JC, Pivnick EK, Talati AJ. Kagami-Ogata syndrome: case series and review of literature. *AJP Rep.* 2021;11:e65–75.

Publisher's Note

Springer Nature remains neutral with regard to jurisdictional claims in published maps and institutional affiliations.