

Brachycephalia – a bastardisation of what makes cats special

Our consensus is that the basic design of the domestic cat is fundamentally sound. Why mess with it?

This issue of the *Journal of Feline Medicine and Surgery* contains a superb paper by Claudia Schlueter and colleagues on the topographical anatomy of the nasolacrimal drainage system in brachycephalic cats.¹ The authors, a collaborative group from the University of Leipzig, Germany, the Freie Universität Berlin, Germany, and the University of Vienna, Austria, use a variety of complementary techniques following injection of contrast material into the tear ducts. Some techniques are traditional (anatomical dissection and corrosion casting), while others are new (helical computed tomography [CT] with three-dimensional constructs). These meticulous studies show that the cranial skeletal anatomy of the extreme flat-faced ‘type’ is greatly distorted. As a consequence, the tear ducts have a diabolically tortuous path, so much so that it is surprising any tears manage to drain into the nasal cavity at all. Little wonder that epiphora is so common in these flat-faced cats.

Although the problem was obvious, this elegant investigation has demonstrated just how severe the distorted conformation of these cats’ heads has become. The technology has delineated and emphasised the true extent of the problem. As feline clinicians, what have we done to stop this happening? The answer is, sadly, not much! Isn’t it time we did more?

The true value of this study is that it defines irrefutably the severity of the problem and this, hopefully, will prompt action to prevent such severe distortions in the future.

This group of editorialists – an opinionated Aussie vet, a thoughtful pommie vet and a passionate cat lover – have a unified view. Our consensus is that the basic design of the domestic cat is fundamentally sound. Why mess with it? As da Vinci said, ‘The smallest feline is a masterpiece.’ It’s a design that evolved through functionality. Cats needed to

hunt, kill prey, in turn avoid being killed by predators, reproduce and lead a vigorous athletic life. The result is a fit, elegant, lithe animal that should, if fed and housed properly, have few health issues and live a long life.

In contrast, severely brachycephalic cats are a bastardisation of all the things that make cats special. They have a nasolacrimal system that doesn’t work properly, so tears stream down the front of their face causing staining and secondary dermatitis (Fig 1). It doesn’t help that they often have excessive folds of skin that rub against the cornea. Their orbit

is shallow, leading to exophthalmos, the tendency to exposure keratitis and growth of corneal sequestra.² The tear film just can’t stretch that far! Their teeth erupt at such bizarre angles that they cannot masticate properly; the resulting propensity for food to accumulate between the teeth leads to accelerated plaque formation and periodontal disease. And if you pull their canine teeth out incorrectly, you will damage that kinky nasolacrimal duct.

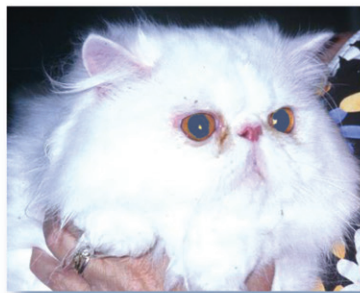

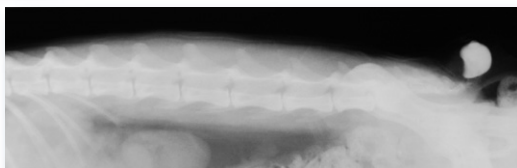
FIG 1 A typical Persian cat. Note the stenotic nares and epiphora. You can't hear the snoring, but it was present and referable to an elongated soft palate. This individual also had polycystic kidney disease. It is by no means the worst example one of the authors (RM) has on file!

But it doesn't stop there. Stenotic nares, stenotic nasal cavities (due to aberrant turbinates) and a soft palate that is too long for the length of the head cause upper airway obstruction, stridulous breathing and possibly obstructive sleep apnoea. Their brain is crammed into the wrong-sized cranial vault, so conceivably we may soon be seeing Budd Chiari-like malformations and syringomyelia, just like in Cavalier King Charles spaniels. To make matters even worse, these cats have long coats that generally require more work to keep in good condition than most owners can expend, so they tend to get knots and mats. In Australia, they need ‘lion clips’ to keep their coat in check, especially in summer, and, believe it or not, ‘Brazilians’ have become popular to make sure they don’t get poo caught under the tail! They are not as efficient at grooming

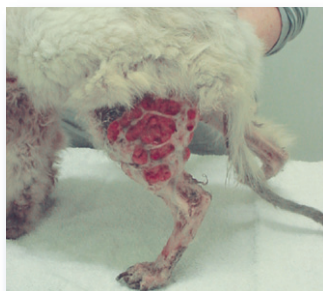

FIG 2
Pseudomycetoma on the hindlimb of a Persian cat with diffuse dermatophytosis due to *Microsporium canis*. Such cats almost certainly have an inherited immune deficiency affecting either innate or cell-mediated immunity

FIG 3 Painful meningocele in a Manx cat with spina bifida and sacrococcygeal dysgenesis. Radiographic contrast medium (iohexol) has been injected into the outpocketing of the meninges. Courtesy of Dr Anne Fawcett



as normal cats, and this means they are more likely to suffer heavy flea burdens, and there are all sorts of adverse gastrointestinal sequelae that result from excessive ingestion of hair.³ Finally, they have some sort of defect in innate or cell-mediated immunity that permits the ubiquitous dermatophyte *Microsporium canis* to invade the dermis to produce disfiguring pseudomycetomas that are notoriously hard to cure (Fig 2).⁴

We likely are preaching to the converted because subscribers to this journal clearly care greatly for feline welfare. There is more than enough diversity in coat colour, coat length, size and personality in domestic moggies and the sound pedigree breeds. There is no need whatsoever to perpetuate the breeding of bizarre mutant cats that could not exist without veterinary interventions. We don't want to go down the path of the canine world, where extreme types (the bulldog, for example) continue to be bred despite obvious defects that greatly compromise their health and longevity.⁵ Plainly, it would be nothing less than cruel.

The solution is obvious: *ban the breeding of these extreme brachycephalic types*. Some have even been so bold as to suggest banning Persian and Exotic shorthairs entirely!

What would be the best way to achieve this end? For sure, we have to change the breed standards. Now. Not next year. Perhaps we need to enlist the help of organisations such as the RSPCA to press cruelty charges on the breeders of these cats – there is no doubt in our minds that many of these cats will have an unhappy life without reconstructive surgery and ongoing veterinary interventions.

Our misgivings are not restricted to these two breeds. We are concerned, too, about Siamese and Oriental cats. A reasonable proportion of Siamese-style cats have congenital wiring faults in their visual neural pathways causing absent stereopsis with

epiphenomena such as strabismus and pendular nystagmus. This has been known since 1971 when it was characterised by Nobel laureates Hubel and Wiesel⁶ – but have we done anything about it? Do we need a quantitative volumetric MRI study to show that breeding for the extreme wedge-shaped head conformation has resulted in microencephaly? There are still countries that permit Scottish Fold cats to be shown and bred – even though most of them develop variably severe arthritis for the whole of their life.⁷ Similarly, Manx cats are prone to spina bifida and associated complications (Fig 3),⁸ which may be irreparable or require surgical intervention. Why would you deliberately breed a cat that doesn't have a tail – a structure so elegant and functional, and so 'catty'?

We applaud the authors of the current study, but remind readers that there is absolutely no point having sophisticated diagnostics, like helical CT, if we are not prepared to complement these with common-sense recommendations about how to breed cats that might be expected to live a long, happy and healthy life with minimum recourse to veterinary interventions.

**Richard Malik DVSc DipVetAn MVetClinStud
PhD FACVSc FASM**

Centre for Veterinary Education,
The University of Sydney, NSW 2006, Australia
E-mail: r.malik@vetc.usyd.edu.au

**Andy Sparkes BVetMed PhD DipECVIM
MRCVS**

The Animal Health Trust, Kentford,
Newmarket CB8 7UU, UK
E-mail: andy.sparkes@aht.org.uk

Claire Bessant BSc
Chief Executive, Feline Advisory Bureau,
Taeselbury, High Street, Tisbury, Wiltshire, UK
E-mail: claire@fabcats.org

References

- Schlueter C, Budras KD, Ludewig E, et al. Brachycephalic feline noses. CT and anatomical study of the relationship between head conformation and the nasolacrimal drainage system. *J Feline Med Surg* 2009; **11**: 891–900.
- Featherstone HJ, Sansom J. Feline corneal sequestra: a review of 64 cases (80 eyes) from 1993 to 2000. *Vet Ophthalmol* 2004; **7**: 213–27.
- Barrs VB, Beatty JA, Tisdall PLC, et al. Intestinal obstruction by trichobezoars in five cats. *J Feline Med Surg* 1999; **1**: 199–207.
- Bond R, Pocknell AM, Toze CE. Pseudomycetoma caused by *Microsporium canis* in a Persian cat: lack of response to oral terbinafine. *J Small Anim Pract* 2008; **42**: 557–60.
- Malik R. Genetic diseases of cats. *J Feline Med Surg* 2002; **3**: 39–44.
- Hubel DH, Wiesel TN. Aberrant visual projections in the Siamese cat. *J Physiol* 1971; **218**: 33–62.
- Malik R, Allan GS, Howlett CR, et al. Osteochondrodysplasia in Scottish Fold cats. *Aust Vet J* 1999; **77**: 85–92.
- DeForest ME, Basrur PK. Malformations and the Manx syndrome in cats. *Can Vet J* 1979; **20**: 304–11.